

Treatment Options for Dupuytren's Disease: Tips and Tricks

Keith A. Denkler, MD*
 Keon Min Park, MD*
 Osaid Alser, MD, MSc (Oxon)†

Background: Dupuytren's disease (DD) is a common fibroproliferative condition of the hand.

Methods: Management of DD includes observation, non-operative management, and operative management. Operative treatments include percutaneous needle fasciotomy (PNF), open fasciotomy (OF), Clostridium collagenase histolyticum (CCH) injections, limited fasciectomy (LF) and dermofasciectomy (DF). The various methods of DD treatment are reviewed.

Results: We summarize the highlights of each treatment option as well as the strengths and weaknesses. PNF has an immediate improvement, but a higher recurrence rate, potential problematic skin tears, and rare tendon or nerve complications. Limited fasciectomy removes the thickened, diseased tissue but has a more prolonged recovery and has a higher rate of significant complications. Dermofasciectomy has the highest complication rate, and the lowest recurrence. Also, secondary fasciectomy after a previous dermofasciectomy has an unexpected amputation rate as high as 8%. Collagenase injections require two visits, have an increased number of minor side effects such as skin tears, and have rare but significant side effects such as tendon rupture.

Conclusions: This article gives an overview of different treatment options for DD and each of their strengths and weaknesses and provides procedural tips.

(*Plast Reconstr Surg Glob Open* 2022;10:e4046; doi: [10.1097/GOX.0000000000004046](https://doi.org/10.1097/GOX.0000000000004046); Published online 27 January 2022.)

INTRODUCTION

Dupuytren's disease (DD) is benign but progressive fibrosis of the hand and digits that leads to flexion deformities that can be disabling to some patients and has vexed surgeons for centuries despite all treatments described.¹ Various nonoperative and operative treatment options are available for the management of DD, but the mainstay of treatment remains limited fasciectomy (LF) surgery.¹ Other treatments include percutaneous needle fasciotomy (PNF), open fasciotomy (OF), Clostridium collagenase histolyticum (CCH) injections, and dermofasciectomy (DF). In this article, we summarize the highlights of each treatment option as well as its strength and weakness. We also describe practical tips with regard to DD surgical management.

Nonsurgical Management

Observation

As DD is a slowly progressive disease, watchful waiting is an option for patients with minimal contracture and without significant functional disability.² Many surgeons suggest an intervention when Hueston's tabletop test is positive, meaning when one cannot put the affected hand down flat on a table facing palm down. Generally, the tabletop test is positive with about a 30-degree metacarpophalangeal joint (MCPJ) contracture. Although the test may be negative with 30-degree proximal interphalangeal joint (PIPJ) contracture due to the ability of the MCPJ to hyperextend. A PIPJ contracture of 5–15 degrees is considered another indication for further intervention.

From the *Dept. of Surgery, Division of Plastic Surgery, University of California San Francisco, Calif.; and †Massachusetts General Hospital, Harvard Medical School, Boston, Mass.

Received for publication May 3, 2021; accepted November 3, 2021.

Copyright © 2022 The Authors. Published by Wolters Kluwer Health, Inc. on behalf of The American Society of Plastic Surgeons. This is an open-access article distributed under the terms of the [Creative Commons Attribution-Non Commercial-No Derivatives License 4.0 \(CCBY-NC-ND\)](https://creativecommons.org/licenses/by-nc-nd/4.0/), where it is permissible to download and share the work provided it is properly cited. The work cannot be changed in any way or used commercially without permission from the journal.

DOI: [10.1097/GOX.0000000000004046](https://doi.org/10.1097/GOX.0000000000004046)

Disclosure: Dr. Denkler was involved in a clinical trial chart review for Endo Pharmaceuticals for six months in 2021. The trial has ended and currently Dr. Denkler has no current contracts with Endo Pharmaceuticals. Dr. Denkler is also on the advisory board of Dale Biotech. Dale is an early-stage Dupuytren's treatment pharmaceutical company and not mentioned in the article. The other authors have no financial interest to declare in relation to the content of this article.

Related Digital Media are available in the full-text version of the article on www.PRSGlobalOpen.com.

Certain patients have clinical features (onset before 50 years old, bilateral disease, ectopic disease, and positive family history) called Dupuytren diathesis, which may predict an aggressive disease course and a higher chance of disease recurrence.³ However, genomic analysis and a weighted genetic risk score are more helpful in predicting disease recurrence than is Dupuytren diathesis.³

Physiotherapy

Physical therapy treatments have had some success in treating established DD contractures.^{4,5} Hand therapy and orthotics are commonly prescribed after corrective DD treatment, but there is a lack of solid evidence to support this intervention.⁵ However, hand therapy after DD treatment allows multiple modalities such as orthoses, exercise, edema control, pain control, and scar management for each individual.⁵

Radiation

Low-dose radiotherapy may halt disease progression via inhibition of myofibroblasts.^{4,6} However, a systematic review of its use showed that the proof of its clinical efficacy is scarce.⁷ Radiation is encouraging for preventing further progression and symptoms of DD, but it does not correct existing contractures.^{7,8} Also, follow-up treatment after radiotherapy needs special consideration by hand surgeons due to operating in a radiated field.

Pharmacologic Treatments

Steroids

Steroid injection can cause regression of nodules and cords found in early DD.⁹ It can be beneficial for treating knuckle pads (Fig. 1).

Antitumor Necrosis Factor (anti-TNF) Agents

Results from the ongoing phase 2 randomized controlled trial in England showed injecting adalimumab, an anti-TNF agent, directly into DD's nodules effectively inhibits the myofibroblasts in a dose-dependent fashion compared with saline control at 2-week follow-up.¹⁰ These results give hope to a biological therapy for DD.

Clostridium Histolyticum Collagenase

This mixture of two collagenases binds, unwinds, and cleaves type I and type III collagen in the cords synergistically while sparing the neurovascular structures. CCH injection has a favorable safety profile with rare severe complications,

Takeaways

Question: What are the treatment options for Dupuytren's disease?

Findings: Percutaneous needle fasciotomy has an immediate improvement but a higher recurrence rate and rare tendon, or nerve complications. Collagenase injections require two visits and have an increased number of minor side effects, with rare tendon injuries. Limited fasciectomy removes the diseased tissue and has a prolonged recovery with a higher complication rate, but has the lowest recurrence rate. Secondary fasciectomy after a previous dermo-fasciectomy has an unexpected amputation rate as high as 8%.

Meaning: There are multiple options available for patients and those treating this disease.

and it especially works well on MCPJ contractures or lower severity disease.^{11–16} The indication for on-label usage is a palpable cord, although private insurance often requires a positive tabletop test for approval to use CCH. Two vial injection allows treatment of two joints or an additional ray at one sitting.¹⁶ There was no clinical difference between delayed three-day manipulation and one-day manipulation.¹⁶ There was also no change in the complication profile with two vial injections, except for more skin tears: 22% versus 9% with a one vial injection.¹⁶ The tendon rupture rate with two vial injections was reduced to 0.1% despite twice the dose.¹⁶

Surgical Management

Percutaneous Needle Fasciotomy

PNF can be performed under local anesthesia in an office and can be repeated multiple times. Although PNF has a high recurrence rate, it has many advantages, including immediate result, fast recovery, low cost, and that it does not preclude any future interventions such as fasciectomy.¹⁷ PNF can be performed on severe contractures and bring the disease back to a less severe stage. Some patients may have excellent long-term results (Fig. 2).

Open Fasciotomy

Dupuytren introduced OF. Single, double, or triple open fasciotomies were performed at the distal palmar crease and the MCPJ/PIPJ creases, and allowed to heal via secondary intention.¹⁸ The success rate was high (93%),

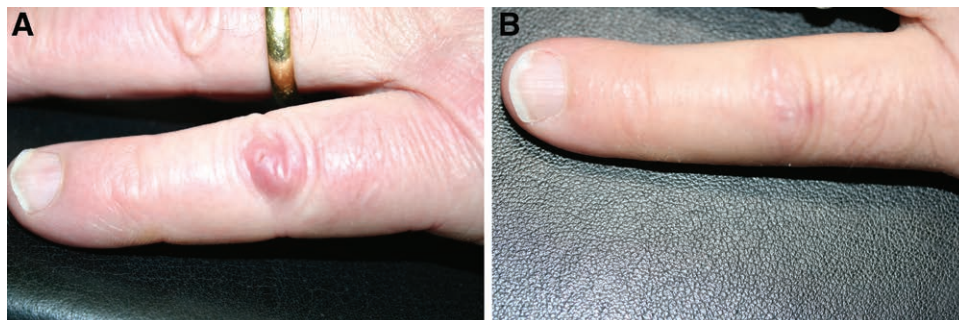


Fig. 1. Triamcinolone injection for a knuckle pad. A, Dupuytren disease knuckle pad. B, Result after a ¼ cm³ of triamcinolone 40 injection at 1 year.

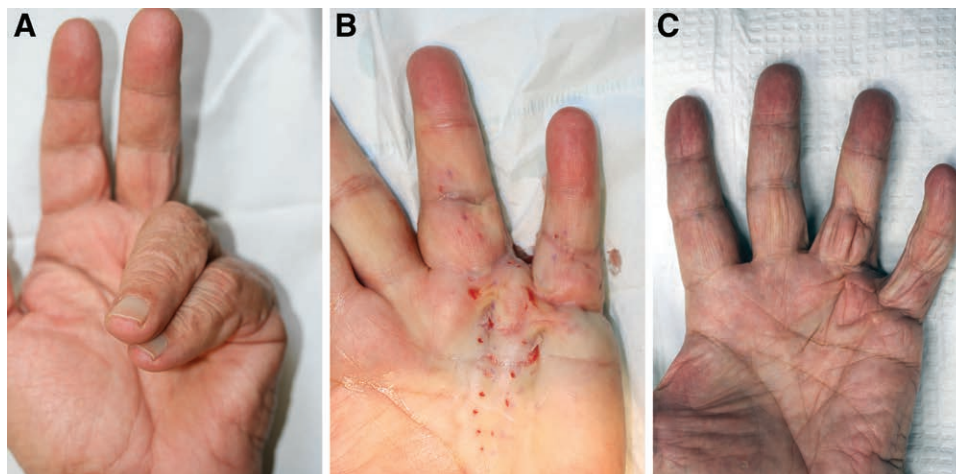


Fig. 2. PNF for severe, recurrent Dupuytren contracture. A, Severe stage IV Dupuytren contracture after a previous fasciectomy. B, Result immediately after PNF. C, Result from a single PNF treatment 13 years later.

and the re-operation rate was only 13.5% at a mean of 46 months.¹⁸ More severe diseases required triple fasciotomies and had more recurrence, whereas MCPJ disease needed only single fasciotomies.¹⁸ The secondary operation of either repeat OF (13%), LF (33%), or DF (54%) was successful in 97%, with no reported complications.¹⁸

Limited Fasciectomy

All affected DD and nodules are removed while the neurovascular bundle is traced out and protected in LF. The recovery is prolonged, and swelling during immobilization can lead to stiffness with flexion. On the other hand, it has a much lower recurrence rate than fasciectomy or CCH injections.^{15,17}

Dermofasciectomy

DF involves removing the affected DD and skin and coverage with a full-thickness skin graft. It has the lowest recurrence rate. A study by Armstrong et al reviewed 143 rays

treated with DF and showed a recurrence rate of 8.4% with a 5.8-year follow-up.¹⁹ Disadvantages include prolonged recovery, skin graft failure, donor site scarring, a higher complication rate, and poor skin color/texture match.

Amputation

The most common cause of elective amputation of the digits is from DD, and it may be recommended in severe, recurrent cases.²⁰ (Fig. 3). DD may recur in an amputation stump and require further treatment (Fig. 4). The use of distraction devices lowers the amputation rate.²¹

Complications

All current treatments may result in devastating complications for the patient.²² Complications of each treatment are summarized in Table 1. The most dangerous procedure is fasciectomy after a previous dermofasciectomy, which has an unplanned amputation rate of 8%.²² This could be due to surgical disruption to the digital

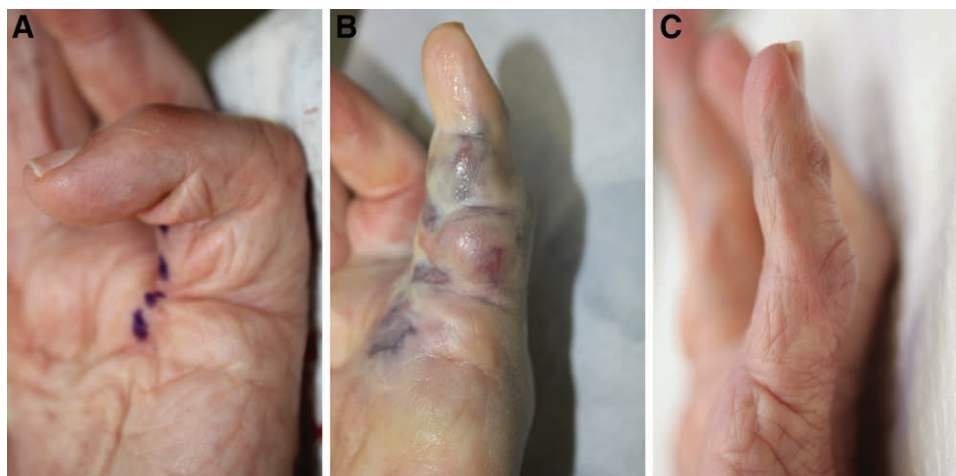


Fig. 3. CCH injections for severe, recurrent Dupuytren contracture. A, This patient with severe PIPJ contracture after a previous fasciectomy had an amputation recommended due to the severity of the contracture. Injection markings for CCH in blue. B, After manipulation. C, Extension at 4-year follow-up.

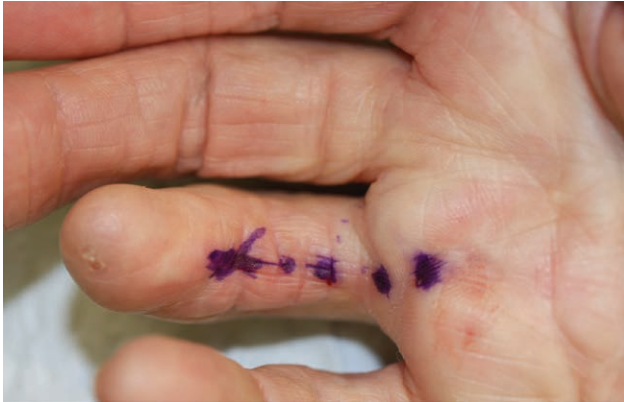

Fig. 4. Markings for CCH injections into recurrent DD in an amputation stump after distal necrosis developed after a previous LF. Before fasciectomy, the surgeon had advised that PNF with blind poking and the risk of tendon damage with CCH were too dangerous.

arteries resulting from dissecting through a scarred surgical bed.³⁶ A small series of severe PIPJ disease treated with LF had an unexpected amputation rate of 5%.³³

All current techniques share the risk of tendon rupture. Skin tears are common after PNF or CCH injections.^{27,37} In some cases, skin tears can be sutured in a horizontal direction, allowing for tissue length to be maintained in a process called diamondplasty.³⁸ Nerve injuries with PNF are rare (0.04%–0.6%).^{28,32} Other severe complications with CCH injections include tendon rupture and anaphylaxis. Mechanical neurapraxia, but not permanent nerve injury occurs with CCH as nerves are composed of type IV collagen and are spared by CCH treatments.

Comparison Studies of Different Treatments

LF versus PNF

A randomized controlled trial with 166 rays treated with either LF or PNF showed that total passive extension deficit was significantly better with LF than PNF (79% versus 63%).³⁹ The rate of complications was higher in the LF group (5% versus 0%) (level of evidence (LOE): 1).³⁹ The follow-up study showed a higher recurrence rate after 5 years in the PNF group (85% versus 21%), and it occurred sooner in the PNF group, with older age groups having a lower recurrence rate (LOE: II).¹⁷

PNF versus CCH

PNF is similar to CCH in results.^{40–42} One study compared PNF with CCH injections in 50 patients with MCPJ disease with a 3-year follow-up and found an initial correction of 100% versus 89%, a recurrence rate of 68% versus 83%, and no difference in the retreatment rate (LOE: 1).⁴⁰ Another study compared PNF with CCH in 50 patients with PIPJ disease with a 3-year follow-up finding an initial correction of 67% versus 69% and a recurrence rate of 43% versus 34% (LOE: 1).⁴¹ CCH injection was not superior to PNF in the treatment of isolated PIPJ contractures regarding the clinical outcome, and it led to more mainly transient complications than PNF (LOE: I).⁴¹ Clinical improvement (reduction in contracture by 50% compared with baseline) was maintained in 29% of PNF patients versus 7% of CCH patients.⁴¹ A more extensive study compared PNF with CCH injection in 152 patients with MCPJ disease and 2-year follow-up, finding an initial correction of 91% versus 90% and a recurrence rate of 21% versus 24% (LOE: 1).⁴² There was no significant difference between CCH and PNF treating MCPJ contractures

Table 1. Complications of Dupuytren’s Disease Treatments

Complications	The Complication Rate for Each Treatment					
	CCH	Two Vial CCH ²³	Primary PNF	Primary LF	Primary DF	Primary and Re-operation (Excluding CCH)
Edema	74% ²⁴	77% ²³	NR	NR	NR	NR
Contusion	54.5%–64% ^{24,25}	59% ²³	NR	NR	NR	NR
Lymph node tenderness	9%–10.3% ^{11,24}	NR	NR	NR	NR	NR
Lymphadenopathy	3%–11.1% ^{24–26}	13% ²³	NR	NR	NR	NR
Pruritus	12.6% ²⁵	15% ²³	NR	NR	NR	NR
Injection site pruritus	5% ^{24,25}	NR	NR	NR	NR	NR
Ecchymosis	17.7% ²⁵	5% ²³	NR	NR	NR	NR
Injection site hemorrhage	34.1% ²⁵	8% ²³	NR	NR	NR	NR
Pain in extremity	26%–36% ^{24,25}	50% ²³	NR	20% ²⁵	NR	NR
Pain intensity	4.9% ²⁶	NR	2.7% ²⁶	NR	NR	NR
Visual Analog Pain Scale						
Wound complications or skin tears	11% ¹²	22% ²³	3.4%–68% ^{27–29}	3%–23% ^{24,30}	0%–25% ²⁵	NR
Surgical site infection	0% ^{25,31}	NR	0.1%–1.5% ^{28,29,32}	2.4%–9.6% ^{24,25,30}	5% ²⁵	2.5%–3.2% ^{21,33}
Neurapraxia or paresthesia	4.4%–5% ^{24,25}	NR	0.1%–1.3% ^{27–29,32}	5–9.4% ^{24,25}	41%–51.3% ²⁵	NR
Nerve injury	0% ^{25,31}	NR	0.04%–0.6% ^{27–29,32}	2%–3.8% ^{24,25,30}	1.5%–25.3% ²⁵	3.3%–3.7% ^{21,34}
Arterial injury	0% ²⁵	NR	NR	3.3%–5.5% ^{25,30}	NR	1.7%–2.5% ^{33,34}
Hematoma	5%–39% ^{25,26}	8% ²³	0% ^{26,27}	2.1% ³⁰	14.9% ²⁵	1.2% ²¹
Stiffness to flexion	NR	NR	NR	5% ³⁰	NR	NR
Blood blister	1.4–14% ^{24–26}	12% ²³	NR	NR	NR	NR
Flare reaction	2% ²⁴	NR	NR	NR	NR	NR
CRPS	0.1–0.5% ^{25,28,31}	NR	0% ^{27,32}	4.5%–5.5% ^{25,30}	2.6% ²⁵	NR
Tendon rupture	0%–0.3% ^{25,26}	0.1% ²³	0%–0.2% ^{26–29,32}	0.1% ²⁵	NR	0.2%–2.5% ^{21,25,33}
Unplanned finger amputation	Two reported cases ³⁵	0% ³²	0.2% ³⁶	0.30% ³⁶	0.42% ³⁶	0.55%–5.1% ^{33,36}
Systemic severe medical complication	NR	0.1% (anaphylaxis) ²³	0% ²⁷	NR	NR	0.78% ³⁶

in range of motion, pain, or QuickDASH score.⁴² Regression and disappearance of the cords occurring in more than 50% of patients at two years follow-up may indicate that resorption of the pathological cord occurs when the tension in the DD cords is diminished.⁴² A study in 132 matched patients compared CCH with LF with a three-month follow-up in a nonrandomized study (LOE: III).²⁴ The residual contracture at the MCPJ was 13 degrees for CCH versus 6 degrees for LF.²⁴ PIPJ contractures showed a minor but significantly worse residual contracture than CCH (25 degrees versus 15 degrees with LF; $p = 0.01$).²⁴ CCH patients had zero serious adverse events, but the LF group had three tenosynovitis cases and one nerve injury ($p = 0.04$).²⁴

Treatment Algorithm and Patient Selection

The senior author feels that patients fall into a simple algorithm ladder of treatment. PNF or CCH injections would be the initial treatment. If recurrence is beyond two years, the initial treatment would be repeated. If recurrence is less than 2 years, an alternative would be offered. If the first treatment was PNF, CCH or LF would be offered. If the first treatment was CCH injections, PNF or LF would be offered. PNF or CCH injections can also be repeated. This technique allows for the successes of simple methods to be captured. Those with double failures of PNF and CCH injections would progress to an LF. Further recurrence would be treated with another LF or a dermofasciectomy. This algorithm allows those that achieve long-term success with minimal treatments to be captured.

Techniques and Pearls

Wide Awake Local Anesthetic No Tourniquet

Wide awake local anesthetic no tourniquet surgery for DD avoids the use of the arm tourniquet and a deeper level of anesthesia.³⁴ For those beginning the procedure and having some trepidation, it is easy to add plain lidocaine to the mixture to dilute the epinephrine concentration in half (1: 200,000) or a fourth (1: 400,000) or even more. However, the epinephrine hemostatic effect wears off more rapidly with the more dilute solutions. Wide awake local anesthetic no tourniquet DD surgery is equivalent to general anesthesia or block anesthesia with a tourniquet.^{34,43} Although current general or regional block anesthesia as currently practiced is exceedingly safe, an extensive review

of over 153,376 DD operations showed significant risks for LF and DF surgeries using these techniques versus strictly local anesthesia PNF.³⁶ Serious systemic complications at 90 days after LF and DF included myocardial infarction (0.88%), acute kidney injury (0.09%), and lower respiratory tract infection (0.22%).³⁶

PNF

Mild to severe extension deficits of the MCPJ or PIPJ is treatable with PNF. Apply topical ice and then place small intradermal wheals of 0.1 to 0.2 mL of 1% lidocaine with epinephrine using a 32-gauge needle to minimize pain for superficial dermal anesthesia. This same numbing technique is helpful for CCH injections. (See Video 1 [online], which displays the fast and straightforward PNF release of the MCPJ. The right little finger, not shown, had two previous fasciectomy elsewhere with a residual 70-degree PIPJ contracture.)

Start distally on the cord with a 21 or 25-gauge needle. PNF generally uses a 5/8 inch 25-gauge needle attached to a 3-mL syringe filled with a local anesthetic. Larger bore needles such as a 21-gauge or 18-gauge needle are useful for thicker cords. Severe contractures need proximal release first to open up the digit. PIPJ contractures with narrow cords will do well with distal to proximal release. During the procedure, check for Tinel signs to prevent nerve injury. The cord is weakened with up and down cutting or pendulum motion using tension on the patient's distal fingertip with the operator's nondominant hand. Insert the needle while flexing and extending the digit to rule out a tendon impingement when in doubt. In general, release distal to proximal for PIPJ contractures. Proximal to the distal palmar crease, PNF is very safe even with a larger bore needle and a numb ray. After PNF, more generous digital blocks or joint anesthesia help reduce forceful extension pain. It is okay to perform hyperextension when straightening the MCPJ, but do not try to hyperextend the PIPJ because it can result in a swan neck deformity. To avoid tendon rupture, one can flex and extend the fingers with the needle in place to make sure you are treating a cord, not a tendon. The goal is to disconnect the nodules and cords and inject antifibrotic agents such as triamcinolone or fluorouracil into the divided tissue. Often, closed collateral ligament releases on one side due to a dominant radial or ulnar cord with an 18-gauge needle may be necessary for difficult

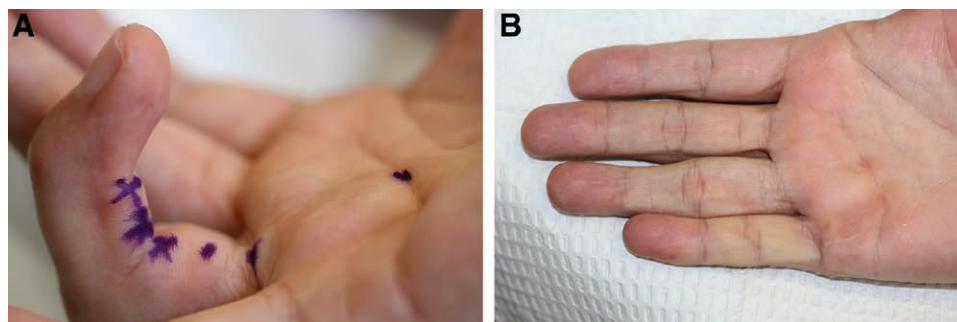


Fig. 5. CCH injections for severe, distal Dupuytren contracture. A, PIPJ of -70 degrees and DIPJ of -50 degrees. Three hand surgeons had stated only LF would work. Small doses of CCH 0.1 mg were placed at the PIPJ and DIPJ. B, Result after this one CCH treatment at 2-year follow-up.

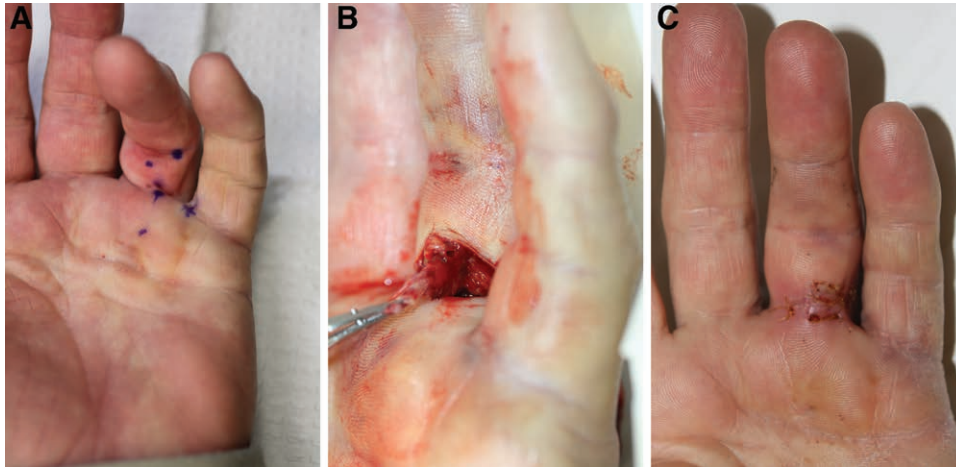


Fig. 6. Management of skin tear with exposed Dupuytren cord. A, Markings for CCH injections. B, Skin tear with exposed cord treated with sterile setup and excision of the exposed tissue. C, At 7-day follow-up.

PIPJ. Morhart and Stromberg (open access) have presented fine articles on PNF technique, and Eaton has an excellent video (See Video 2 [online], which displays the percutaneous needle aponeurotomy of a left ring finger Dupuytren cord with metacarpophalangeal and proximal interphalangeal joint contractures 45 and 65 degrees, respectively).⁴⁴⁻⁴⁶ Advanced PNF techniques are necessary for severe DD. (See Video 3 [online], which displays the advanced PNF technique treating a severe MCPJ and PIPJ contracture.)

CCH

CCH injections can be used as the primary treatment or for recurrences after PNF, OF, LF, or DF. CCH injections are useful for lateral disease and retrovascular cords where PNF and LF treatment is more complicated (Fig. 5). When the CCH is reconstituted, the bottle cap is removed, and a 1.5-inch 25-gauge needle can easily remove the entire volume of CCH. Use 0.58 mg collagenase for the dominant cord. The residual 0.32 mg may

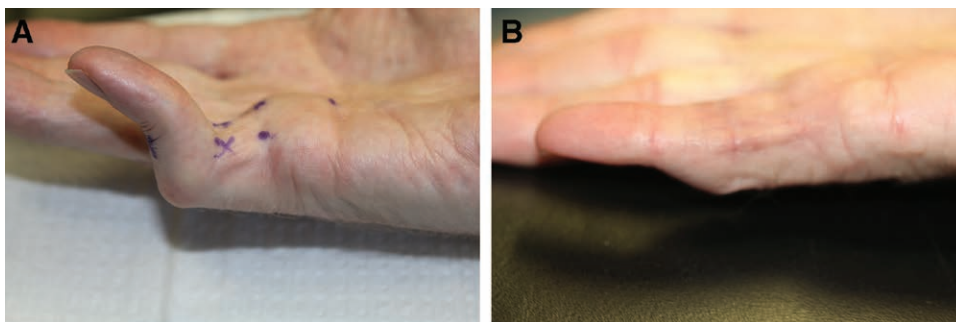


Fig. 7. Treatment with CCH injections in Dupuytren boutonniere deformity. A, Small finger with severe PIPJ flexion contracture and DIPJ hyperextension boutonniere. Markings before collagenase injection. "X" marks indicate injection sites for 0.1 mg, and circular dots indicate injection sites for 0.2 mg of CCH. B, Thirteen-month follow-up with PIPJ extension and DIPJ hyperextension improvement after two volar CCH sessions. There was only one CCH tenotomy injection.

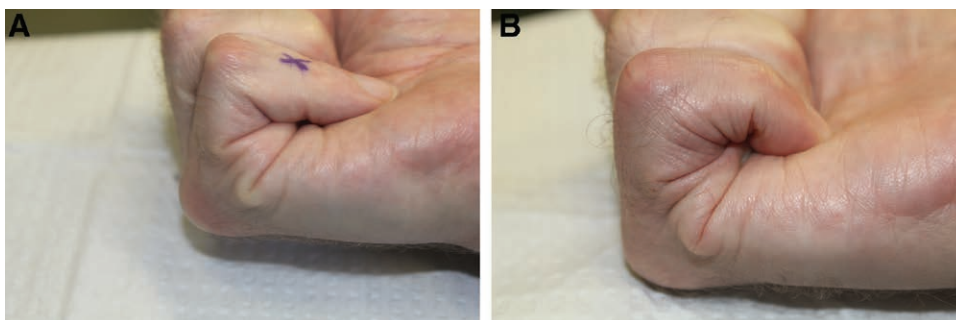


Fig. 8. Distal enzymatic tenotomy for Dupuytren boutonniere deformity. A, Limited distal flexion and injection site of 0.1 mg CCH tenotomy is marked X. B, Markedly improved extension and flexion of the DIPJ after two volar CCH injection sessions, but only one dorsal tenotomy treatment.

be used more proximally or more distally on the affected cord, other cords in another ray, or on natatory ligaments. Manipulation at seven days is safe and effective (LOE: I).⁴⁷ Local anesthesia, digital or wrist block for manipulation, helps immensely. One should stretch, massage the cords, and bend in all directions at manipulation. After a skin tear, it is possible to trim exposed Dupuytren cords with a sterile tray and loupe magnification (Fig. 6). CCH injections as an enzymatic tenotomy is helpful for treatment of Dupuytren boutonniere (Figs. 7, 8).⁴⁸

LF

Removal of thickened and diseased cords is the goal of LF. Detailed understanding of normal and pathologic anatomy is vital. Incision markings are generally zig-zag Bruner with a V to Y advancement or straight line incisions with Z-plasties. LF dissects the NV bundle off of the cord, being careful looking for a spiral nerve. Littler scissors and tenotomy scissors are helpful. A 15 c blade can be pushed and will cut cords under tension and not the softer NV bundle.⁴⁹ Once the NV bundles are exposed, the central, spiral, lateral, and retrovascular cords may be safely cut away. The NV bundle may be proximally located or dissected distally beyond the PIPJ, where it is more superficial. Trickett et al showed the effects of sequential releasing of the variously named cords in 99 rays with DD undergoing limited fasciotomy.⁵⁰ Excision of the central cord corrected 82% of MCPJ contracture and 44% of PIPJ contracture, whereas excision of spiral/lateral cord corrected an additional 12% of the contracture at MCPJ and 19% at PIPJ. The subsequent release of the retrovascular cord and accessory collateral ligament resulted in an extra 23% and 14% correction at PIPJ, showing the complexity of cord structures involved in DD and the need for the release of multiple different cord structures during LF. Look for a spiral nerve when dissecting in fatty areas and identify neurovascular structures before proceeding.⁵¹

The central cord has attachments to the skin at the PIPJ crease and into the A4 pulley.⁵¹ The retrovascular

cord is the leading cause of distal interphalangeal joint (DIPJ) contracture, and it displaces the neurovascular bundle in a volar direction.⁴⁹ The neurovascular bundle should be retracted medially to expose the retrovascular cord.⁴⁹ After releasing the central cord, the MCPJ contracture is usually corrected, but residual PIPJ contracture is common.⁵¹ At the conclusion of a LF, the PIPJ must be evaluated for residual contracture after releasing the involved cords.^{33,51} Dissection of Cleland's and Grayson's ligaments tethering the skin and contracting the PIPJ. These attachments can be directly excised or released with an 18-gauge needle to untether the skin via subcision. Re-stretch the finger for a minute or two. If there is residual bounce-back, or if the correction is incomplete, progress to the next step. Open the flexor tendon sheath via a transverse incision at the distal end of the A2 pulley. Also, release any taut fascial fibers across the cruciate and A3 pulley. Stretch, then reassess. Divide the transverse retinacular ligament. Assess the volar plate and release the check-rein ligaments. Stretch, then reassess. Capsulotomy and release of the collateral ligaments. Stretch, then reassess. Release of the palmar plate up to its insertion at the middle phalanx base. This stepwise process corrected an average of 81 degrees PIPJ contracture to 29 degrees, an improvement of 64%, although 10% of the patients were worse and 3% were unchanged.³³

Recurrence

All current DD treatments have issues with recurrence, and there is no clear definition of recurrence.⁵² When evaluating a recurrent DD patient, a digital Allen test is useful for assessing potential arterial problems. Collagenase dissolves both scar tissue and DD cords, so previous surgery for DD does not affect the efficacy or safety of CCH injections.⁵³ Repeat LF for recurrent DD is as effective as the initial treatment despite a larger extension deficit (LOE: III).⁵⁴ Combination therapy using initial wide-awake LF, then touch-up CCH injections can help provide long-term improvement (Fig. 9). Fat grafting held hope for reducing DD recurrence, but whereas percutaneous aponeurotomy

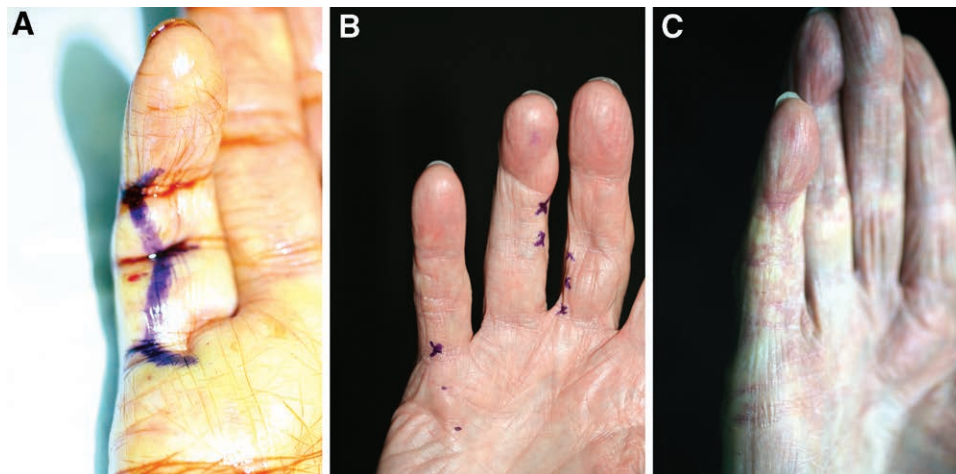


Fig. 9. Use of touch-up CCH injections years later after a previous LF. A, Initial wide awake LF in 2006. B, Touch-up CCH injections (0.5 mg to little finger, 0.1 mg to ring, and 0.3 mg to middle finger) to the right hand in 2011. C, The same hand in 2020.

with lipofilling (PALF) had good results at 1 year, at 5 years, the correction was less durable than those for LF.⁵⁵ Further studies are needed to conclude if fat grating can prevent DD recurrence.

What Patients Should Know

There is a strong association between DD and older age, positive family history, male gender, diabetes mellitus, alcohol (more than three drinks a day), smoking, and manual work with vibration tools.^{56,57} Obesity protects against the development of DD.⁵⁷ In a review of patients receiving DD treatment, about one-fifth had a history of trauma such as a previous surgery or fracture.⁵⁸ Spontaneous regression can occur in 11% of patients with early DD.⁵⁹ DD does not follow a linear progression to contracture.⁶⁰ Millesi followed 150 patients with early signs of DD, finding that 9% showed progression at 1 year, 22% at 3 years, 39% at 5 years, and 48% at 6 or more years.⁶⁰ In 113 patients with unilateral disease that required operation, the rates of DD progression were 19% at 1 year, 37% at 3–5 years, and 46.5% between 6 and 12 years.⁶⁰

Those with DD need to know that there is hope with a variety of options available for treatment. The biggest trade-off in DD treatments is fast recovery with higher recurrence rates versus longer recovery with lower recurrence rates.

Keith A. Denkler, MD
275 Magnolia Ave.
Larkspur, CA 94939
E-mail: kdenkler@gmail.com

REFERENCES

1. Bayat A, McGrouther DA. Management of Dupuytren's disease—clear advice for an elusive condition. *Ann R Coll Surg Engl*. 2006;88:3–8.
2. Rayan GM. Nonoperative treatment of Dupuytren's disease. *J Hand Surg Am*. 2008;33:1208–1210.
3. Riesmeijer SA, Manley OWG, Ng M, et al. A weighted genetic risk score predicts surgical recurrence independent of high-risk clinical features in Dupuytren's disease. *Plast Reconstr Surg*. 2019;143:512–518.
4. Ball C, Izadi D, Verjee LS, et al. Systematic review of non-surgical treatments for early Dupuytren's disease. *BMC Musculoskelet Disord*. 2016;17:345.
5. Turesson C. The role of hand therapy in Dupuytren disease. *Hand Clin*. 2018;34:395–401.
6. Keilholz L, Seegenschmiedt MH, Sauer R. Radiotherapy for prevention of disease progression in early-stage Dupuytren's contracture: initial and long-term results. *Int J Radiat Oncol Biol Phys*. 1996;36:891–897.
7. Kadhum M, Smock E, Khan A, et al. Radiotherapy in Dupuytren's disease: a systematic review of the evidence. *J Hand Surg Eur Vol*. 2017;42:689–692.
8. Seegenschmiedt H, Keilholz L, Wielputz M, et al. In: Eaton C, et al., eds. *Dupuytren's Disease and Related Hyperproliferative Disorders: Principles, Research, and Clinical Perspectives*. Springer; 2012.
9. Yin CY, Yu HM, Wang JP, et al. Long-term follow-up of Dupuytren disease after injection of triamcinolone acetonide in Chinese patients in Taiwan. *J Hand Surg Eur Vol*. 2017;42:678–682.
10. Nanchahal J, Ball C, Davidson D, et al. Anti-tumour necrosis factor therapy for Dupuytren's disease: a randomised dose response proof of concept phase 2a clinical trial. *EBioMedicine*. 2018;33:282–288.
11. Hurst LC, Badalamente MA, Hentz VR, et al.; CORD I Study Group. Injectable collagenase clostridium histolyticum for Dupuytren's contracture. *N Engl J Med*. 2009;361:968–979.
12. Peimer CA, Wilbrand S, Gerber RA, et al. Safety and tolerability of collagenase Clostridium histolyticum and fasciectomy for Dupuytren's contracture. *J Hand Surg Eur Vol*. 2015;40:141–149.
13. Gilpin D, Coleman S, Hall S, et al. Injectable collagenase Clostridium histolyticum: a new nonsurgical treatment for Dupuytren's disease. *J Hand Surg Am*. 2010;35:2027–38.e1.
14. Badalamente MA, Hurst LC, Benhaim P, et al. Efficacy and safety of collagenase clostridium histolyticum in the treatment of proximal interphalangeal joints in Dupuytren contracture: combined analysis of 4 phase 3 clinical trials. *J Hand Surg Am*. 2015;40:975–983.
15. Peimer CA, Blazar P, Coleman S, et al. Dupuytren contracture recurrence following treatment with collagenase Clostridium histolyticum (CORDLESS [Collagenase Option for Reduction of Dupuytren Long-Term Evaluation of Safety Study]): 5-year data. *J Hand Surg Am*. 2015;40:1597–1605.
16. Coleman S, Gilpin D, Kaplan FT, et al. Efficacy and safety of concurrent collagenase clostridium histolyticum injections for multiple Dupuytren contractures. *J Hand Surg Am*. 2014;39:57–64.
17. van Rijssen AL, Ter Linden H, Werker PMN. Five-year results of a randomized clinical trial on treatment in Dupuytren's disease: percutaneous needle fasciotomy versus limited fasciectomy. *Plast Reconstr Surg*. 2012;129:469–477.
18. Stewart CJ, Davidson DM, Hooper G. Re-operation after open fasciotomy for Dupuytren's disease in a series of 1,077 consecutive operations. *J Hand Surg Eur Vol*. 2014;39:553–554.
19. Armstrong JR, Hurren JS, Logan AM. Dermofasciectomy in the management of Dupuytren's disease. *J Bone Joint Surg Br*. 2000;82:90–94.
20. Degreef I, De Smet L. Dupuytren's disease: a predominant reason for elective finger amputation in adults. *Acta Chir Belg*. 2009;109:494–497.
21. Loos B, Puschkin V, Horch RE. 50 years experience with Dupuytren's contracture in the Erlangen University Hospital—a retrospective analysis of 2919 operated hands from 1956 to 2006. *BMC Musculoskelet Disord*. 2007;8:60.
22. Alser O, Craig RS, Lane JCE, et al. Serious complications and risk of re-operation after Dupuytren's disease surgery: a population-based cohort study of 121,488 patients in England. *Sci Rep*. 2020;10:16520.
23. Gaston RG, Larsen SE, Pess GM, et al. The efficacy and safety of concurrent collagenase Clostridium histolyticum injections for 2 Dupuytren contractures in the same hand: a prospective, multicenter study. *J Hand Surg Am*. 2015;40:1963–1971.
24. Zhou C, Hovius SER, Slijper HP, et al. Collagenase clostridium histolyticum versus limited fasciectomy for Dupuytren's contracture: outcomes from a multicenter propensity score matched study. *Plast Reconstr Surg*. 2015;136:87–97.
25. Peimer CA, Wilbrand S, Gerber RA, et al. Safety and tolerability of collagenase Clostridium histolyticum and fasciectomy for Dupuytren's contracture. *J Hand Surg Eur Vol*. 2015;40:141–149.
26. Strömberg J, Ibsen-Sørensen A, Fridén J. Comparison of treatment outcome after collagenase and needle fasciotomy for Dupuytren contracture: a randomized, single-blinded, clinical trial with a 1-year follow-up. *J Hand Surg Am*. 2016;41:873–880.
27. Pess GM, Pess RM, Pess RA. Results of needle aponeurotomy for Dupuytren contracture in over 1,000 fingers. *J Hand Surg Am*. 2012;37:651–656.
28. Herrera FA, Mitchell S, Elzik M, et al. Modified percutaneous needle aponeurotomy for the treatment of Dupuytren's contracture: early results and complications. *Hand (N Y)*. 2015;10:433–437.

29. Molenkamp S, Schouten TAM, Broekstra DC, et al. Early postoperative results of percutaneous needle fasciotomy in 451 patients with Dupuytren disease. *Plast Reconstr Surg*. 2017;139:1415–1421.
30. Denkler K. Surgical complications associated with fasciotomy for Dupuytren's disease: a 20-year review of the English literature. *Eplasty*. 2010;10:e15.
31. Hansen KL, Werlinrud JC, Larsen S, et al. Difference in success treating proximal interphalangeal and metacarpophalangeal joints with collagenase: results of 208 treatments. *Plast Reconstr Surg Glob Open*. 2017;5:e1275.
32. Therkelsen LH, Skov ST, Laursen M, et al. Percutaneous needle fasciotomy in Dupuytren contracture: a register-based, observational cohort study on complications in 3,331 treated fingers in 2,257 patients. *Acta Orthop*. 2020;1-5.
33. Hohendorff B, Spies CK, Müller LP, et al. Supplementary arthrolysis of the proximal interphalangeal finger joint in Dupuytren's contracture: primary operation versus revision. *Arch Orthop Trauma Surg*. 2016;136:435–439.
34. Denkler K. Dupuytren's fasciectomy in 60 consecutive digits using lidocaine with epinephrine and no tourniquet. *Plast Reconstr Surg*. 2005;115:802–810.
35. Wozniczka J, Canepa C, Mirarchi A, et al. Complications following collagenase treatment for Dupuytren contracture. *Hand (N Y)*. 2017;12:NP148–NP151.
36. Alser O, Craig RS, Lane JCE, et al. Serious complications and risk of re-operation after Dupuytren's disease surgery: a population-based cohort study of 121,488 patients in England. *Sci Rep*. 2020;10:16520.
37. Lermusiaux JL, Lellouche H, Badois JF, et al. How should Dupuytren's contracture be managed in 1997? *Rev Rhum Engl Ed*. 1997;64:775–776.
38. Denkler KA, Vaughn CJ, Dolan EL, et al. Evidence-based medicine options for Dupuytren's contracture: Incise, excise, and dissolve. 2017;139:240e-255e.
39. van Rijssen AL, Gerbrandy FS, Ter Linden H, et al. A comparison of the direct outcomes of percutaneous needle fasciotomy and limited fasciectomy for Dupuytren's disease: a 6-week follow-up study. *J Hand Surg Am*. 2006;31:717–725.
40. Scherman P, Jenmalm P, Dahlin LB. Three-year recurrence of Dupuytren's contracture after needle fasciotomy and collagenase injection: a two-centre randomized controlled trial. *J Hand Surg Eur Vol*. 2018;43:836–840.
41. Skov ST, Bisgaard T, Søndergaard P, et al. Injectable collagenase versus percutaneous needle fasciotomy for Dupuytren contracture in proximal interphalangeal joints: A randomized controlled trial. *J Hand Surg Am*. 2017;42:321–328.e3.
42. Strömberg J, Ibsen Sørensen A, Fridén J. Percutaneous needle fasciotomy versus collagenase treatment for Dupuytren contracture: a randomized controlled trial with a two-year follow-up. *J Bone Joint Surg Am*. 2018;100:1079–1086.
43. Nelson R, Higgins A, Conrad J, et al. The wide-awake approach to Dupuytren's disease: fasciectomy under local anesthetic with epinephrine. *Hand (N Y)*. 2010;5:117–124.
44. Morhart M. Pearls and pitfalls of needle aponeurotomy in Dupuytren's disease. *Plast Reconstr Surg*. 2015;135:817–825.
45. Strömberg J. Percutaneous needle fasciotomy for Dupuytren contracture. *JBSJ Essent Surg Tech*. 2019;9:e6.
46. Murphy A, Lalonde DH, Eaton C, et al. Minimally invasive options in Dupuytren's contracture: aponeurotomy, enzymes, stretching, and fat grafting. *Plast Reconstr Surg*. 2014;134:822e–829e.
47. Mickelson DT, Noland SS, Watt AJ, et al. Prospective randomized controlled trial comparing 1- versus 7-day manipulation following collagenase injection for Dupuytren contracture. *J Hand Surg Am*. 2014;39:1933–1941.e1.
48. Denkler KA, Vaughn CJ, Park KM, et al. Collagenase tenotomy for Dupuytren boutonniere. *Plast Reconstr Surg*. 2021;148:764e–768e.
49. Haase SC, Chung KC. Bringing it all together: a practical approach to the treatment of Dupuytren disease. *Hand Clin*. 2018;34:427–436.
50. Trickett RW, Savage R, Logan AJ. Angular correction related to excision of specific cords in fasciectomy for Dupuytren's disease. *J Hand Surg Eur Vol*. 2014;39:472–476.
51. Dias JJ, Aziz S. Fasciectomy for Dupuytren contracture. *Hand Clin*. 2018;34:351–366.
52. Werker PM, Pess GM, van Rijssen AL, et al. Correction of contracture and recurrence rates of Dupuytren contracture following invasive treatment: the importance of clear definitions. *J Hand Surg Am*. 2012;37:2095–2105.e7.
53. Bainbridge C, Gerber RA, Szczypa PP, et al. Efficacy of collagenase in patients who did and did not have previous hand surgery for Dupuytren's contracture. *J Plast Surg Hand Surg*. 2012;46:177–183.
54. Mendelaar NHA, Poelstra R, van Nieuwenhoven CA, et al. Outcome of recurrent surgery in Dupuytren's disease: comparison with initial treatment. *Plast Reconstr Surg*. 2019;144:828e–835e.
55. Selles RW, Zhou C, Kan HJ, et al. Percutaneous aponeurotomy and lipofilling versus limited fasciectomy for Dupuytren's contracture: 5-year results from a randomized clinical trial. *Plast Reconstr Surg*. 2018;142:1523–1531.
56. Mathieu S, Naughton G, Descatha A, et al. Dupuytren's disease and exposure to vibration: systematic review and meta-analysis. *Joint Bone Spine*. 2020;87:203–207.
57. Majeed M, Wiberg A, Ng M, et al. The relationship between body mass index and the risk of development of Dupuytren's disease: a Mendelian randomization study. *J Hand Surg Eur Vol*. 2021;46:406–410.
58. Samulėnas G, Rimdeika R, Braziulis K, et al. Dupuytren's contracture: incidence of injury-induced cases and specific clinical expression. *Medicina (Kaunas)*. 2020;56:E323.
59. Gudmundsson KG, Arngrimsson R, Jónsson T. Eighteen years follow-up study of the clinical manifestations and progression of Dupuytren's disease. *Scand J Rheumatol*. 2001;30:31–34.
60. Millesi H. The clinical and morphological course of Dupuytren's disease. In Hueston J, Tubiana R. (Eds), *Dupuytren's Disease*. 2nd English ed. Edinburgh: Churchill Livingstone. 1985: 114–121.