



## Cohort Study

## Hybrid threshold laser to treat diabetic macular edema: A retrospective analysis single center cohort study

Ameen Marashi <sup>a</sup>, Aya Zazo <sup>b,\*</sup><sup>a</sup> Marashi Eye Clinic, Aleppo, Syria<sup>b</sup> Faculty of Medicine, University of Aleppo, Aleppo, Syria

## ARTICLE INFO

## Keywords:

Diabetic macular edema  
Hybridthreshold  
Laser  
Micropulse

## ABSTRACT

**Background:** Diabetic patients suffers from reduction of vision that one of its main causes is clinically significant macular edema (CSME).

The purpose of this study to determine if hybrid threshold can reduce macular thickness in Diabetic Macular Edema.

**Materials and methods:** This study is a retrospective analysis single center cohort study. 12 eyes in 10 patients diagnosed with diabetic macular edema using SD-OCT treated with Hybridthreshold laser as the leaking microaneurysms were treated with threshold laser on the 5% duty cycle settings.

A complete fundus exam, including best-corrected visual acuity changes, and monthly measuring retinal thickness using SD-OCT for 24 weeks follow up.

**Results:** Reduction of retinal thickness from  $336.58 \pm 86.26 \mu\text{m}$  to  $264.33 \pm 61.41 \mu\text{m}$  ( $p = 0.02$ ) at 24 weeks follow up without significant changes of best-corrected visual acuity from 0.16 LogMAR to 0.08 LogMAR ( $p = 0.2$ ) with minimal scar formation in 24 weeks follow up.

**Conclusion:** 532 nm Hybridthreshold laser reduces macular thickness up to 20% and stabilizes diabetic macular edema for 24 weeks follow up.

## 1. Introduction

Clinically significant macular edema (CSME) cause early-onset reduction of vision in patients with diabetes [1]; however, CSME presented a central including the fovea or noncentral foveal sparing where the former induces reduction of visual acuity (VA). However, noncentral CSME patients presented with good VA, but a VA reduction may occur as Noncentral CSME can progress to central.

The first line therapy treatment of central CSME is an intravitreal injection of AntiVEGF when it is associated with a reduction of vision [2], which has proven its safety and efficacy; however, focal laser photocoagulation may reduce the risk of visual loss, especially in cases of noncentral CSME [3].

Conventional laser treatment induces retinal burns that can damage both retinal pigment epithelium and photoreceptors, which will induce retinal scars that may extend to the fovea and cause visual loss, sub-retinal fibrosis, or choroidal neovascularization.

Inducing retinal tissue reaction by threshold laser burn may limit the destruction of photoreceptors and retinal pigment epithelium, which

interim cause minimal scar that won't expand [4].

Although the subthreshold diode micropulse photocoagulation is safe, it may not resolve the edema completely [5].

In this clinical trial, we will evaluate new laser parameters to treat diabetic macular edema, which we will use both threshold and sub-threshold diode microsecond laser using subthreshold diode 532 nm  $\mu\text{s}$  laser.

## 2. Materials and methods

This study is a retrospective analysis single center cohort study, which follows Helsinki's declaration. The study is registered at [clinicaltrials.gov](https://clinicaltrials.gov) (NCT03226951). The study received approval from the institutional review board. Patients obtained written consent after explaining the possible complications.

## 2.1. Study participant

Inclusion criteria.

\* Corresponding author.

E-mail address: [dr.aya.zazo@gmail.com](mailto:dr.aya.zazo@gmail.com) (A. Zazo).

<https://doi.org/10.1016/j.amsu.2022.104222>

Received 6 May 2022; Received in revised form 13 July 2022; Accepted 20 July 2022

Available online 31 July 2022

2049-0801/© 2022 The Author(s). Published by Elsevier Ltd on behalf of IJS Publishing Group Ltd. This is an open access article under the CC BY-NC-ND license (<http://creativecommons.org/licenses/by-nc-nd/4.0/>).

- 1-Patients with central and noncentral diabetic macular edema and Best-corrected visual acuity is 20/32 or more.
- 2 Macular thickness of more than 300  $\mu\text{m}$ .
- 3-Patients who can come for all follow-ups.

2.1.1. Exclusion criteria

- 1-A significant renal disease is defined as a history of chronic renal failure requiring dialysis or a kidney transplant.
- 2-Myocardial infarction, other acute cardiac event requiring hospitalization, stroke, transient ischemic attack, or treatment for severe congestive heart failure within four months before randomization.
- 3-For women of childbearing potential: pregnant, lactating, or intending to become pregnant within three years.
- 4-Macular edema is present that is considered to be related to ocular surgery such as cataract extraction.
- 5-A substantial cataract that, in the opinion of the investigator, is likely to be decreasing visual acuity by three lines or more
- 6-History of major ocular surgery (including vitrectomy, scleral buckle, intraocular surgery, etc.) in the previous four months or may require ocular intervention within the next six months after randomization.
- 7-Exam evidence of severe external ocular infection, including conjunctivitis, chalazion, or substantial blepharitis.

2.1.2. Treatment protocol

One or both eyes were included in this study, where eyes were treated with a subthreshold microsecond laser done at the baseline after confirming the diagnosis of DME with OCT, which is defined as retinal thickening above 299  $\mu\text{m}$ .

Treating leaking microaneurysms identified by fluorescein angiography using Subthreshold microsecond diode 532 nm laser (LIGHTLas 532 nm LIGHMED ltd.) applied using single spot laser spot size is 125 m with area centralis contact lens, 200 ms duration, and 200 ms interval, where the used power determined by noticing threshold tissue reaction on the settings of 5%.

Then switch back to the subthreshold mode by decreasing half of the threshold power to treat the edema area using low-intensity high-density in a painting fashion protocol covering all the areas of the edema.

AntiVEGF intravitreal injection is considered when edema is increased in thickness or/and vision reduction or vitreous hemorrhage due to complicated proliferative diabetic retinopathy precluding retinal view.

2.2. Follow-up and outcome measures

All patients underwent dilated fundus exam and BCVA (best-corrected visual acuity) at baseline. Then, every four weeks, the Snellen chart was converted to LogMAR to monitor the best-corrected visual acuity changes for 24 weeks.

SD-OCT was obtained at baseline and monthly to evaluate the status of DME, and HbA1C was collected every three months to evaluate glycemic control.

2.3. Statistical methods

Clinical data were obtained and analyzed using MS Excel. The means are used to investigate the variance between the mean six months outcome and mean baseline values for macular thickening and visual acuity.

The processes were established in accordance with STROCSS 2021 guidelines [6].

3. Results

12 eyes out of 10 patients included in this study 4 women and six men mean age  $58.78 \pm 8.4$  Table 1 shows summarized baseline characteristics, all patients received Hybrid subthreshold microsecond laser treatment in the edematous area and followed up for 24 weeks According to Table 2.

The best-corrected visual acuity converted from Snellen to LogMAR for statistical analysis and changes from baseline from 0.16 logMAR (20/28) to 0.08 LogMAR (20/24) at 24 weeks follow up ( $p = 0.2$ ).

Where retinal thickness was decreased from baseline from  $336.58 \pm 86.26 \mu\text{m}$  to  $264.33 \pm 61.41 \mu\text{m}$  to 24 weeks follow up ( $P = 0.02$ ) (Fig. 1),  $72.6 \pm 21.83 \mu\text{m}$  (21.5%) is the mean decrease in retinal thickness reduction from baseline to 24 weeks follow up (Fig. 2).

Three eyes were lost to follow up, and five eyes were treatment success the other four eyes achieved, reduction of retinal thickness in the area of edema, without complete resolution.

However, five eyes did not require additional treatment, and their glycemic control was maintained throughout 24 weeks.

The other four eyes with residual macular edema after 24 weeks follow-up were managed with intravitreal injection of AntiVEGF.

There were no complications from the Hybrid threshold laser. In addition, there was no evidence of extending laser burn scar in the threshold treated area of leaking microaneurysms in clinical examination and fundus images within 24 weeks follow up.

After threshold laser application on leaking microaneurysms, there was minimal scar formation to induce heat closure that didn't extend beyond the original threshold laser burn. In addition, OCT shows that threshold laser burn destruction didn't extend beyond outer retinal layers reduced in scar size within 24 weeks.

4. Discussion

This study evaluated 532 nm hybrid threshold laser efficacy for macular thickness in diabetic macular edema within 24 weeks.

The subthreshold microsecond laser stimulates retinal pigment epithelium to repair the inner blood barrier without causing damage to photoreceptors via sublethal injury by inducing heat shock protein without destroying retinal pigment epithelium and thus upregulating pigment epithelium-derived factor and downregulation of VEGF.

Protection of neural tissue is achieved using subthreshold microsecond laser because energy is delivered in a microsecond envelope with "ON" time 100  $\mu\text{s}$  of micropulse power and "OFF" 1900  $\mu\text{s}$  without power that allow time for the heated tissue to cool down and thus will activate retinal pigment epithelium without causing neural tissue damage. However, because retinal and retinal pigment epithelium is in close proximity, a millisecond laser induces damage to photoreceptors and

**Table 1**  
Characteristics of patients at presentation. According to (Table 1) 10 patients were analyzed with the mean age of patients is  $58.78 \pm 8.4$ , of whom five are Men, and five are Women.

Age, Year (Mean $\pm$ SD)	59.8 $\pm$ 9.86
Sex, N (%)	
Men	5 (50%)
Women	5 (50%)
Eyes: N (%)	
Right	5 (41.66%)
Left	7 (58.33%)
Race: N (%)	
Arab	4 (40%)
Caucasian	6 (60%)
lens: N (%)	
Phakic	9 (75%)
pseudophakic	3 (25%)
HbA1C: (%) (Mean $\pm$ SD) 7.4 $\pm$ 0.5	

**Table 2**

Mean changes in BCVA using LogMAR units and Retinal thickness after Hybridthreshold microsecond 532 nm diode laser treatment from baseline and 24 weeks.

	Baseline	after 6 months	P value	MIN	MAX
BCVA, LogMAR Units	0.16 ± 0.2	0.08 ± 0.13	0.2	0	0.69
Retinal Thickness	336.58 ± 86.26	264.33 ± 61.41	0.02	158	477

retinal pigment epithelium to accomplish a therapeutic effect, as the heat shock may disseminate into the inner retinal tissues [7-8-9].

In a randomized, prospective, single center study, comparing 810 nm laser vs 577 nm subthreshold laser using 5% duty cycle for six-months in 53 eyes with mild DME with central macular thickness less than 400  $\mu\text{m}$ . The 577 nm subthreshold laser for diabetic macular edema, reduced central macular thickness from  $357.8 \pm 46.1$  to  $339.9 \pm 55.7$   $\mu\text{m}$  and from  $340.1 \pm 35.7$   $\mu\text{m}$  to  $335.3 \pm 54.5$   $\mu\text{m}$  in the 810 nm subthreshold laser group. In contrast, in this study, hybrid threshold with 532 nm laser achieved thickness reduction from  $336.58 \pm 86.26$   $\mu\text{m}$  to  $264.33 \pm 61.41$   $\mu\text{m}$  in a 24 weeks follow up [10].

The subretinal scars induced by threshold laser to close the leaking microaneurysm were limited to outer retinal layers without expanding in size nor into inner retinal tissues. In 24 weeks follow-up, the scar size was reduced based on SD-OCT scans and funds images.

This study showed that a Hybrid threshold laser could stabilize the edema with the possibility of thickness reduction up to 20%. This can be beneficial in residual diabetic macular edema cases after injection to reduce injection frequency or in patients who refuse or are contraindicated for injection (Fig. 2). Which may reduce the cost burden for intravitreal injections and office visits especially for cases of DME with thickness less than 400  $\mu\text{m}$ .

**The limitation of this study includes** the short time of follow-up which is only 24 weeks, that hinders the long-term results and durability of diabetic macular edemas with 532 nm Hybrid threshold laser.

Another limitation of this study is that it is a single-center study with a small number of eyes tested with 532 nm hybrid threshold laser. Which it is still not known the results of utilizing the hybrid threshold laser on larger sample of patients in a multicenter setting.

This study lacks both of a control arm and other comparison arms, such as with an intravitreal injection.

So it is imperative to have a long time follow up with a larger sample of patients with multicenter randomized clinical trial comparing hybrid threshold laser with control and other treatment modalities such as intravitreal injections.

## 5. Conclusion

This study showed that a 532 nm hybrid threshold laser effectively stabilizes diabetic macular edema with minimal subretinal scars limited to outer retinal layers.

However, long-term and larger studies are required to evaluate the actual efficacy and durability of the 532 nm Hybridreshold laser.

## Ethical approval

The research was conducted ethically in accordance with the World Medical Association Declaration of Helsinki.

## Sources of funding

There is no source of funding for this paper.

## Author contribution

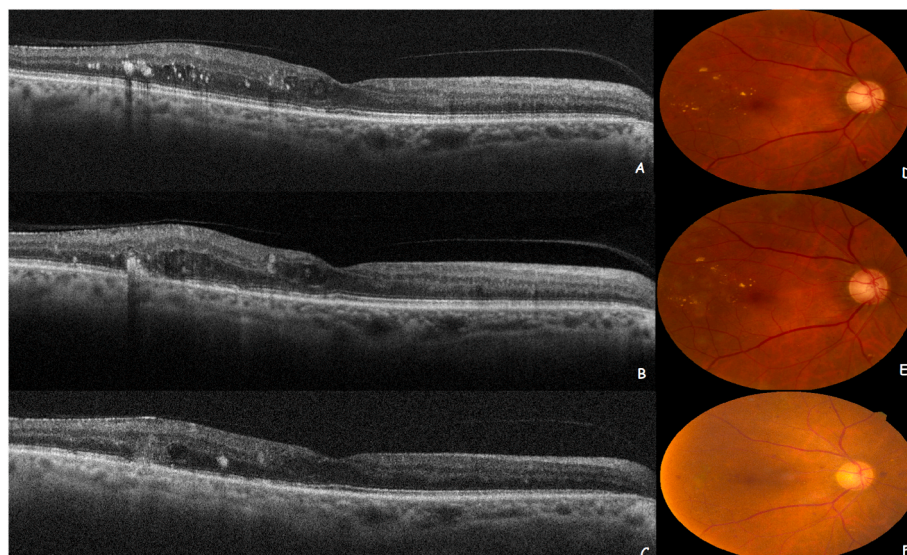
Ameen Marashi designed and drafted the research manuscript and approved final version to be submitted. Aya Zazo analyzed and interpreted the research manuscript and approved final version to be submitted.

## Registration of research studies

You can register any type of research at <http://www.researchregistry.com> to obtain your UIN if you have not already registered. This is mandatory for human studies only. Trials and certain observational research can also be registered elsewhere such as: [ClinicalTrials.gov](http://ClinicalTrials.gov) or [ISRCTN](http://ISRCTN) or numerous other registries.

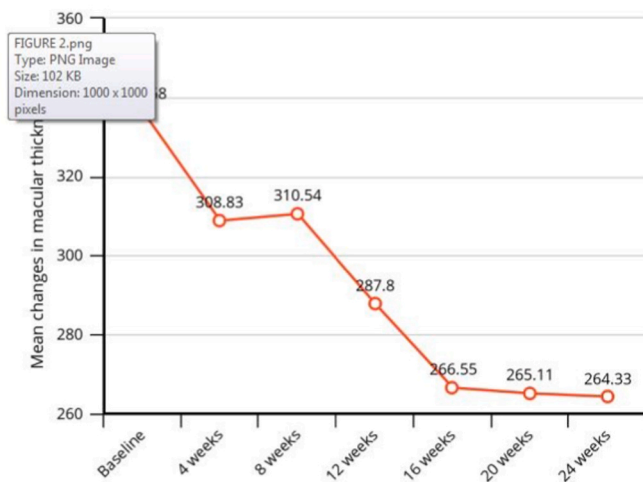
## Consent

The research was conducted ethically in accordance with the World Medical Association Declaration of Helsinki. The patients have given their written informed consent on admission to use their data base and files for research work.



**Fig. 1.** Shows mean changes in central macular thickness within 24 weeks follow up after HT laser treatment.

## HT laser within 24 weeks



Source: Marashi Eye Clinical Center

**Fig. 2.** A) OCT scan at baseline showing diabetic macular edema with hyper-reflective foci resembling hard exudates B) OCT cross-section after one month of hybrid threshold laser showing diabetic macular edema with RPE scar limited to RPE and outer retinal tissue with decreasing of hard exudates C) OCT cross-section after 24 weeks follow up showing reduction of diabetic macular edema thickness and resolved majority of hard exudates and with reduction of scar size D) Fundus image shows a cluster of hard exudates with microaneurysms and diabetic macular edema with non-proliferative diabetic retinopathy E) One day after the hybrid threshold laser showing laser burns application to leaking microaneurysms F) Fundus image 24 weeks follow up shows resolved hard exudates, and scar formation didn't expand in size.

### Guarantor

Dr Ameen Marashi.

### Provenance and peer review

Not commissioned, externally peer-reviewed.

### Declaration of competing interest

The authors declare that there is no conflict of interest.

### Acknowledgments

None.

### Appendix A. Supplementary data

Supplementary data to this article can be found online at <https://doi.org/10.1016/j.amsu.2022.104222>.

### References

- [1] R. Klein, S.E. Moss, B.E. Klein, M.D. Dams, D.L. DeMets, The Wisconsin epidemiologic study of diabetic retinopathy: XI. The incidence of macular edema, *Ophthalmology* 96 (10) (1989) 1501–1510.
- [2] C.W. Baker, A.R. Glassman, W.T. Beaulieu, A.N. Antoszyk, D.J. Browning, K. V. Chalam, S. Grover, L.M. Jampol, C.D. Jhaveri, M. Melia, C.R. Stockdale, Effect of initial management with aflibercept vs laser photocoagulation vs observation on vision loss among patients with diabetic macular edema involving the center of the macula and good visual acuity: a randomized clinical trial, *JAMA* 321 (19) (2019) 1880–1894.
- [3] I.U. Scott, R.P. Danis, S.B. Bressler, N.M. Bressler, D.J. Browning, H. Qin, Effect of focal/grid photocoagulation on visual acuity and retinal thickening in eyes with non-center involved clinically significant diabetic macular edema, *Retina* 29 (5) (2009) 613. Philadelphia, Pa.
- [4] J.P. Wood, M. Plunkett, R.J. Casson, G. Chidlow, Retinal damage profiles and neuronal effects of laser treatment: comparison of a conventional photocoagulator and a novel 3-nanosecond pulse laser, *Investig. Ophthalmol. Vis. Sci.* 54 (3) (2013) 2305–2318.
- [5] A. Marashi, Non-central diabetic clinical significant macular edema treatment with 532nm sub threshold laser, *Adv Ophthalmol Vis Syst* 8 (3) (2018) 151–154.
- [6] G. Mathew, R. Agha Strocck, Strengthening the reporting of cohort, cross-sectional and case-control studies in surgery, *Int. J. Surg.* 96 (2021), Article 106165.
- [7] G. Dorin, Evolution of retinal laser therapy: minimum intensity photocoagulation (MIP). Can the laser heal the retina without harming it?, in: *Seminars in Ophthalmology*, vol. 19 Taylor & Francis, 2004, January, pp. 62–68. No. 1-2.
- [8] A.S. Wilson, B.G. Hobbs, W.Y. Shen, T.P. Speed, U. Schmidt, C.G. Begley, P. E. Rakoczy, Argon laser photocoagulation-induced modification of gene expression in the retina, *Investig. Ophthalmol. Vis. Sci.* 44 (4) (2003) 1426–1434.
- [9] K. Inagaki, T. Shuo, K. Katakura, N. Ebihara, A. Murakami, K. Ohkoshi, Sublethal photothermal stimulation with a micropulse laser induces heat shock protein expression in ARPE-19 cells, *J Ophthalmology* (2015), 2015.
- [10] S. Vujosevic, F. Martini, E. Longhin, E. Convento, F. Cavarzeran, E. Midena, Subthreshold micropulse yellow laser versus subthreshold micropulse infrared laser in center-involving diabetic macular edema: morphologic and functional safety, *Retina* 35 (8) (2015) 1594–1603.