

Young patient with treatment-resistant schizophrenia drastically improved by combination of clozapine and maintenance electroconvulsive therapy: a case report

This article was published in the following Dove Press journal:
International Medical Case Reports Journal

Masashi Ito¹
Yasuto Kunii^{1,2}
Sho Horikoshi¹
Itaru Miura¹
Shuntaro Itagaki¹
Tetsuya Shiga¹
Hirooki Yabe¹

¹Department of Neuropsychiatry, Fukushima Medical University School of Medicine, Fukushima, Japan; ²Department of Neuropsychiatry, Fukushima Medical University School of Aizu Medical Center, Fukushima, Japan

Objectives: Although clozapine is considered the only effective pharmacological option for patients with treatment-resistant schizophrenia (TRS), around 30–40% of patients show clozapine resistance. Modified electroconvulsive therapy augmentation is reportedly clinically effective for clozapine-resistant schizophrenia, but few case reports have described the efficacy of combining clozapine and continuous/maintenance ECT for patients with TRS.

Methods: We present the case of a young patient with TRS who was treated using combination therapy with clozapine and maintenance ECT (m-ECT).

Results: The patient achieved drastic improvement under combination therapy with clozapine and m-ECT. Total Positive and Negative Syndrome Scale (PANSS) score fell markedly by 36 (from 108 to 72) using the combination of clozapine and m-ECT. Behaviors not reflected directly by PANSS score also improved. For example, the problem of being unable to take oral drugs stably because of delusions of poisoning was resolved. Furthermore, the patient maintained improvement under m-ECT, and long-term homestays became possible.

Conclusion: Combination therapy with clozapine and m-ECT proved greatly effective in this case. Further clinical trials of this combination therapy for TRS are needed to confirm the effectiveness. Further studies are also expected to examine effective periods for this therapy.

Keywords: treatment-resistant schizophrenia (TRS), modified electroconvulsive therapy, augmentation, clozapine, maintenance ECT(m-ECT)

Introduction

Although early intervention can shorten the duration of untreated psychosis, and atypical antipsychotics or psychosocial approaches have been developed and widely adopted, about 30% of all patients with schizophrenia are considered antipsychotic-resistant.^{1–3} Clozapine is the most efficacious antipsychotic for patients with treatment-resistant schizophrenia (TRS), but shows several severe side effects, including agranulocytosis. Moreover, around 30–40% of patients with TRS are also clozapine-resistant.^{4–6} For clozapine-resistant schizophrenia, modified electroconvulsive therapy, atypical antipsychotics and antiepileptics (or mood stabilizers) have been tried as augmentation therapies. In particular, previous studies have reported that ECT augmentation shows the most favorable response.^{6–11} Generally, continuous ECT (c-ECT) is initiated only after remission from acute-phase m-ECT, which lasts up to 6 months,

Correspondence: Masashi Ito
Department of Neuropsychiatry,
Fukushima Medical University School of
Medicine, 1 Hikarigaoka, Fukushima city,
Fukushima 960-1295, Japan
Tel +81 24 547 1331
Fax +81 24 548 6735
Email m-ito426@fmu.ac.jp

to prevent relapse. On the other hand, m-ECT is a course that begins after the end of c-ECT and is planned to prevent recurrence of an episode.¹² Only one RCT study (n=45)⁹ listed on PubMed examined the utility of continuous or maintenance ECT, and treatment combining neuroleptics and c-ECT appeared more effective for preventing relapse than the use of either therapy alone. Relapse rates within 6 months were 40% (for combined c-ECT and neuroleptics), 93% (for c-ECT alone), and 93% (for neuroleptics alone), respectively.⁹ However, the neuroleptic used in that RCT was flupenthixol, and no RCT appears to have reported the effectiveness of combining clozapine and c-ECT/m-ECT.

We report herein the case of a young patient with TRS who was treated using a combination of clozapine and m-ECT and achieved drastic improvements.

Case report

The patient was a young man in his early twenties with TRS, who was admitted to the inpatient psychiatry unit at our hospital. He was diagnosed with schizophrenia after he had developed dysmorphophobia, auditory hallucinations, and persecutory delusions. Although he had been treated with several atypical antipsychotics, the response had been poor and psychotic symptoms worsened. In February 2014, he was admitted to a psychiatric hospital with acute psychotic symptoms, such as hallucinations and delusions. After hospitalization for half a year, his symptoms improved temporarily, and

he was able to attend a psychiatric day care program. However, he developed delusions, and auditory hallucinations again, and his thinking became incoherent. Many atypical antipsychotics had been used to improve psychotic symptoms, but had not achieved substantial improvement, while neck dystonia had appeared. After this insufficient antipsychotic treatment, TRS was diagnosed based on the poor response to more than two kinds of atypical antipsychotics, and he was then referred to our hospital for administration of clozapine.

Methods

The clinical course after admission is shown in Figure 1. During initial admission, although olanzapine (up to 20 mg/day), low-dose quetiapine (100 mg/day), and aripiprazole (up to 30 mg/day) were used before clozapine administration, responses to these antipsychotics were poor (Figure 1). We then administered clozapine and increased the dose to 600 mg/day after carefully decreasing the previous drugs, and added lamotrigine (up to 200 mg/day) as augmentation therapy for clozapine but its efficacy was limited and psychotic symptoms repeated with frequent exacerbations. To make matters worse, oral intake of drugs was difficult due to delusions of poisoning. We therefore decided to try augmentation therapy for further improvement and conducted ECT twice a week for 4 weeks, performing a total of eight sessions.

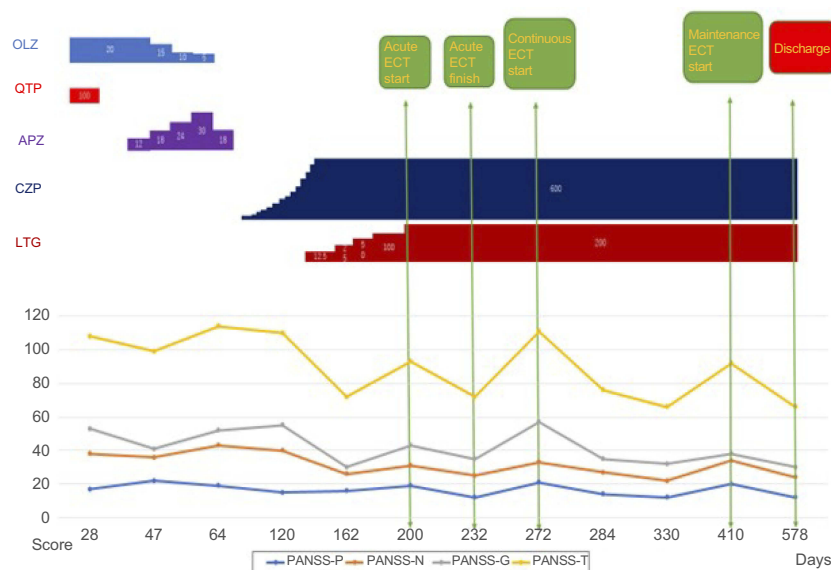


Figure 1 Course of treatment and changes in PANSS score. Hospital day 0 represents the day of admission. Total PANSS score which decreased by the dosage of clozapine rises again, but decreases again by performing acute ECT. Similarly, continuous ECT and maintenance ECT reduce total PANSS score which became the upward trend again later each.

Abbreviations: OLZ, olanzapine; QTP, quetiapine; APZ, aripiprazole; CZP, clozapine; LTG, lamotrigine.

Atropine, propofol, and rocuronium were administered as standard premedication. The electrical dose was titrated to the seizure threshold of the patient at 0.5-ms pulse width, 60-Hz frequency, 7.5-s stimulus duration, and 900-mA current using Thymatron[®] System IV (Somatics LLC, Venice, FL, USA), and bifrontotemporal stimulation was applied. We started ECT with Thymatron[®] at 40% stimulation strength, but finally increased stimulation strength to 80% when no effective convulsions were achieved at the initial stimulation strength. Increasing the stimulation strength to 80% produced an effective seizure duration of 20–40 s.

Informed consent

Before participating, an explanation of the risks and benefits of this therapy procedure was given to the patient and his family, and we obtained informed consent from them. The patient and his family also provided consent for publication of this case.

Ethics statement

This study obeyed the rule of the Ethics Committee of Fukushima Medical University Hospital, and conformed to the provisions of the Declaration of Helsinki.

Results

Total Positive and Negative Syndrome Scale (PANSS) score was markedly reduced by 36, from 108 before combining clozapine and ECT, to 72 at the completion of initial ECT. Consequently, he became able to take part in daily occupational therapy programs in a step-by-step manner after starting clozapine and ECT. Furthermore, he had often refused to take the oral drugs because of the firmly rooted delusion of poisoning during clozapine monotherapy, but became able to take oral drugs in a stable manner. The adverse effect of severe neck dystonia also disappeared. However, about 1 month after the final session of acute-phase ECT, symptoms became unstable again and the patient sometimes presented with a state of hallucination-delusion again, despite continuing to take clozapine. We then began to perform m-ECT once every 1 or 2 weeks with the aim of achieving improvements in this stagnant situation. This combination of clozapine and m-ECT enabled the patient to stay out overnight from our hospital in the acute phase (first 8 sessions) and total PANSS score reduced markedly to a maximum of 66. The patient was undergoing maintenance ECT for half a year once a month when PANSS was

66. The patient was finally able to be discharged from our hospital on day 578 after admission, thanks to additional m-ECT (Figure 1). As of the time of writing, the patient is regularly attending community workshops while receiving m-ECT once a month. As shown in Figure 1, the improvement of negative symptoms was more marked than that of positive symptoms in this patient. Monthly ECT was continued for 7 months. PANSS score was 66 at the time of the last ECT.

Discussion

No clear adverse effects were seen with clozapine and m-ECT combination therapy in this case.

Since the dosing of stimulation is an important factor in the risk of status epilepticus, we started ECT at a stimulation strength of 40% and increased gradually. However, a drop in the convulsion threshold is one side effect of clozapine, and prolonged convulsions are a known adverse effect of ECT. The risk of status epilepticus might thus be increased with this combination therapy compared to each therapy alone. Care regarding the potential for adverse events is therefore warranted. On the other hand, lamotrigine had been used in this case as a mood stabilizer. This might have helped to avoid the development of harmful phenomena. In addition, sufficient monitoring is necessary because cardiovascular diseases such as myocarditis or cardiomyopathy can develop as serious side effects of clozapine, and harmful cardiovascular complications have also been reported with ECT. Furthermore, application of m-ECT considerably increases the number of sessions. The potential for a negative influence on cognitive function is thus another concern. Young TRS patients without complications seem likely to represent a good target population for combination therapy with clozapine and m-ECT when potential complications are considered.

In this case, combination therapy with clozapine and m-ECT proved greatly effective in improving symptoms for this patient. In particular, this regimen was more effective for improving negative symptoms than for improving positive symptoms. In addition, the problem of the patient not taking oral drugs due to a delusion of poisoning was resolved, and the patient was finally able to be discharged from the hospital. Only a small number of studies, mainly case reports, have addressed the combination of clozapine and c-ECT/m-ECT,¹³ and no RCT appears to have reported the effectiveness of the combining clozapine and c-ECT/m-ECT.^{10,11} Further cases of TRS treated using combination therapy with clozapine and continuous/maintenance ECT are needed to confirm

the effectiveness of this approach, and more studies are also strongly recommended to determine whether effective periods for this therapy can be expanded.

Author contributions

All authors contributed to data analysis, drafting and revising the article, gave final approval of the version to be published, and agree to be accountable for all aspects of the work.

Disclosure

The authors report no conflicts of interest in this work.

References

1. Lehman AF, Lieberman JA, Dixon LB, et al. Practice guideline for the treatment of patients with schizophrenia, second edition *Am J Psychiatry*. 2004 Feb;161(2 Suppl):1–56.
2. Taylor M, Perera U. NICE CG178 Psychosis and Schizophrenia in Adults: Treatment and Management - an evidence-based guideline? *Br J Psychiatry*. 2015 May;206(5):357–359. doi:10.1192/bjp.bp.114.155945.
3. Taylor D, Paton C, Kapur S, et al. *The Maudsley Prescribing Guidelines in Psychiatry*. 11th. UK: Wiley-Blackwell; 2012.
4. Englisch S, Zink M Treatment-resistant schizophrenia: evidence-based strategies. *Mens Sana Monogr*. 2012;10(1):20–32. doi:10.4103/0973-1229.91588
5. Sommer IE, Begemann MJH, Temmerman A, Leucht S. Pharmacological augmentation strategies for schizophrenia patients with insufficient response to clozapine: a quantitative literature review. *Schizophr Bull*. 2012;38(5):1003–1011. doi:10.1093/schbul/sbr004.
6. Lally J, Tully J, Robertson D, Stubbs B, Gaughran F, MacCabe JH. Augmentation of clozapine with electroconvulsive therapy in treatment resistant schizophrenia: a systematic review and meta-analysis. *Schizophr Res*. 2016;171(1–3):215–224. doi:10.1016/j.schres.2016.01.024.
7. Shibasaki C, Takebayashi M, Fujita Y, Yamawaki S. Factors associated with the risk of relapse in schizophrenic patients after a response to electroconvulsive therapy: a retrospective study. *Neuropsychiatr Dis Treat*. 2015;11:67–73. doi:10.2147/NDT
8. Petrides G, Malur C, Braga RJ, et al. Electroconvulsive therapy augmentation in clozapine-resistant schizophrenia: a prospective, randomized study. *Am J Psychiatry*. 2014;172:52–58. doi:10.1176/appi.ajp.2014.13060787
9. Chanpattana W, Chakrabhand ML, Sackeim HA, et al. Continuation ECT in treatment-resistant schizophrenia: a controlled study. *J ECT*. 1999;15(3):178–192.
10. Kho KH, Blansjaar BA, Vries S, et al. Electroconvulsive therapy for the treatment of clozapine non-responder suffering from schizophrenia—an open label study. *Eur Arch Psychiatry Clin Neurosci*. 2004;254:372–379. doi:10.1007/s00406-004-0517-y
11. Masoudzadeh A, Khalilian AR. Comparative study of clozapine, electroshock and the combination of ECT with clozapine in treatment-resistant schizophrenic patients. *Pak J Biol Sci*. 2007;10:4287–4290.
12. Motohashi N, Awata S, Isse K, et al. [Recommendations for ECT practice, second edition]. *Seishin Shinkeigaku Zasshi*. 2013;115(6):586–600.
13. Bannour S, Bouhlel S, Krir MW, et al. Combination of maintenance electroconvulsive therapy and clozapine in treating a patient with refractory schizophrenia. *J ECT*. 2014;30(3):e29–e30. doi:10.1097/YCT.0000000000000090

International Medical Case Reports Journal

Dovepress

Publish your work in this journal

The International Medical Case Reports Journal is an international, peer-reviewed open-access journal publishing original case reports from all medical specialties. Previously unpublished medical posters are also accepted relating to any area of clinical or preclinical science. Submissions should not normally exceed 2,000 words or 4

published pages including figures, diagrams and references. The manuscript management system is completely online and includes a very quick and fair peer-review system, which is all easy to use. Visit <http://www.dovepress.com/testimonials.php> to read real quotes from published authors.

Submit your manuscript here: <https://www.dovepress.com/international-medical-case-reports-journal-journal>