

# Effect of Nanoherbal Andaliman (*Zanthoxylum acanthopodium*) and Extra Virgin Olive Oil Combination on Preeclamptic Rats Liver Histology

Putri Cahaya Situmorang<sup>1</sup>, Syafruddin Ilyas<sup>2\*</sup>, Salomo Hutahaean<sup>1</sup>, Rosidah Rosidah<sup>2</sup>

<sup>1</sup>Department of Biology, Faculty of Mathematics and Natural Sciences, Universitas Sumatera Utara, Medan 20155, Indonesia; <sup>2</sup>Faculty of Pharmacy, Universitas Sumatera Utara, Medan 20155, Indonesia

## Abstract

**Citation:** Situmorang PC, Ilyas S, Hutahaean S, Rosidah R. Effect of Nanoherbal Andaliman (*Zanthoxylum Acanthopodium*) and Extra Virgin Olive Oil Combination on Preeclamptic Rats Liver Histology. Open Access Maced J Med Sci. 2019 Jul 30; 7(14):2226-2231. <https://doi.org/10.3889/oamjms.2019.651>

**Keywords:** Zanthoxylum acanthopodium; EVOO; Preeclampsia; Liver

**\*Correspondence:** Syafruddin Ilyas. Department of Biology, Faculty of Mathematics and Natural Sciences, Universitas Sumatera Utara, Medan 20155, Indonesia. E-mail: [syafruddin6@usu.ac.id](mailto:syafruddin6@usu.ac.id)

**Received:** 05-May-2019; **Revised:** 01-Jul-2019; **Accepted:** 12-Jul-2019; **Online first:** 14-Jul-2019

**Copyright:** © 2019 Putri Cahaya Situmorang, Syafruddin Ilyas, Salomo Hutahaean, Rosidah Rosidah. This is an open-access article distributed under the terms of the Creative Commons Attribution-NonCommercial 4.0 International License (CC BY-NC 4.0)

**Funding:** This research was financially supported by the Directorate of research and community service, Directorate general of research and development, Ministry of research, Technology, and Higher education, Indonesia - Grant of PMDSU 2019 (Master's Education towards Doctorate 2019)

**Competing Interests:** The authors have declared that no competing interests exist

**BACKGROUND:** Andaliman (*Zanthoxylum acanthopodium*) is a spice traditional Northern Sumatera, Indonesia and these fruits contain alkaloids, steroids and terpenoids. Extra Virgin Olive Oil (EVOO) contains antioxidants. Combination of this plant have activities to reduce preeclampsia.

**AIM:** To know the safety of the combination of nano herbal andaliman and Extra virgin olive oil (EVOO) on preeclampsia patients' liver.

**METHODS:** Pregnant rats were made to have preeclampsia with 3 ml of NaCl 6% injections. This research consists of 5 groups: K- (negative control): normal pregnant rats, K+: preeclampsia rats; P1: PE rats were given nano herbal andaliman 1 ml EVOO / day / 20 gBW from the 13th to the 19th day of pregnancy, P2: PE rats were given nano herbal andaliman 100 mg/day / 200 gBW from the 13th to the 19th day of pregnancy, P3: PE was given the combination of 1 ml EVOO/day / 200 gBW and andaliman nano herbal 100 mg/day/200 gBW on the 13th day of pregnancy to the 19th day given orally. Then on the 20th day of pregnancy, the subjects were dissected.

**RESULTS:** There were significant differences ( $p < 0.05$ ) on the value of SGOT, SGPT, and the average damage of the hepatocyte cells except parenchymatous degeneration after being given the nano herbal andaliman and EVOO. The compared mean of normal hepatocytes cell, hydropic degeneration and necrosis value between all groups were  $p < 0.05$  and  $p < 0.01$  compared to (K-). The non-significant difference was found in the mean of parenchymatous degeneration between the groups ( $p = 0.058$ ).

**CONCLUSION:** The combination of nano herbal andaliman (*Zanthoxylum acanthopodium*) and EVOO affected the level of necrosis in hepatocyte cells on preeclampsia rats.

## Introduction

Preeclampsia (PE) is a multi-system disorder that is a major cause of maternal morbidity and mortality worldwide. Recent data show that the contribution of preeclampsia is estimated to be about 5 times that of morbidity & maternal-newborn mortality [1]. PE is a life-threatening disease for mother and fetus in Indonesia. According to the Indonesian Demographic and Health Survey in 2007, PE contributed up to 24% of maternal deaths in Indonesia and made it the second leading cause of maternal mortality in Indonesia [2]. The international non-governmental organisation forum on Indonesian Development stated that Indonesia is a country in

Southeast Asia with the highest maternal mortality rate of 359/100.000 births [3].

Andaliman (*Zanthoxylum acanthopodium*) is a spice that is used for traditional Batak cuisine, Northern Sumatera, Indonesia [4]. This plant has been used as a contraceptive for generations as an anti-fertility. Andaliman extract contains chemicals in the form of alkaloids, steroids and terpenoids, which have antioxidant activity and antimicrobial, repellent and kill insects [5], [6], [7]. The content of this plant is thought to have activities to reduce PE because andaliman fruit has also been reported to have anti-inflammatory activity and antioxidant activity [7]. *Extra Virgin Olive Oil* (EVOO) from Olive fruit contains antioxidants, namely Vitamin E, hydroxytyrosol and tyrosol [8].

Nanotechnology is a system that has several

advantages, namely being able to modify the characteristics of the surface, small size, high loading capacity so that it can be given in high concentrations [9]. Constraints that often occur in herbal medicines are difficult active substances to penetrate the lipid membrane of body cells because they have a large molecular size and low solubility in water that causes poor absorption and bioavailability [10]. Changes in drug molecules into nanometer scales provide a significant change in physicochemical properties and can improve the efficacy of these drug molecules [11].

The liver is the largest organ in the body that plays a role in detoxifying poisons in the blood, breaking down or changing the nature of toxic substances so that it can be released through urine. The impact of the combination of these two herbs needs to be seen in the liver in terms of their safety effects in preeclamptic patients.

## Material and methods

### **Nanoherbal Andaliman (*Zanthoxylum acanthopodium*)**

Andaliman fruit used comes from the Dairi District of Northern Sumatera. Andaliman is washed thoroughly; then the fruit is dried for 3 days at room temperature, then blended until smooth and then sized to nano size using *High energy milling* (HEM). Simplicia as a destructive medium is inserted into the jar container and then inserted a ball with a larger diameter size and continued by inserting a small ball and the sample is placed lastly. The total volume of the ball and the sample inserted do not exceed 2 / 3 of the tube volume. The sample was tightly closed and then placed on a tube inside the HEM device, then HEM was turned on for 2 hours [12].

### **Phytochemical screening**

**Alkaloids:** 1 g of nano herbal andaliman was put in a test tube then added 18 ml of distilled water and 2 ml of 2 N hydrochloric acids then heated for 2 minutes. The trial was conducted with Meyer reagent. Positive alkaloids if sediment or turbidity occurs.

**Glycosides:** 3 g of nano herbal andaliman extracted in 30 ml mixture of 7 parts ethanol 96% and 3 parts of distilled water, then added concentrated sulfuric acid and refluxed in 10 minutes. After chilling 20 ml of filtrate added 10 ml of distilled water and 10 ml of lead (II) acetate 0.4 M were shaken and left for 5 minutes. The filtrate that has been filtered in the juice with 20 ml mixture of chloroform and isopropanol (3: 2) to be tested against sugar compounds and non-sugar compounds [13].

**Flavonoids:** 1 g of nano herbal andaliman

mixed in 20 ml of methanol then reflux 10 minutes. After cooling, 10 ml of kerosene ether is added and then shaken and let stand until separation, the methanol layer is taken and then evaporated at 40°C, the remainder is dissolved in ethyl acetate and filtered by filtrate to be tested with 0.5 g zinc powder and 0.1 g powder magnesium [13].

**Saponin:** 1 g of nano herbal andaliman and 20 ml of hot water have been shaken for 20 seconds. The saponin is positive if there is foam in not less than 10 minutes as high as 1-10 cm after adding 2 drops of hydrochloric acid 2 N foam was not lost.

**Steroids/Terpenoids:** 2 g nano herbal andaliman were macerated with 40 ml ether for 2 hours. The filtrate was filtered and evaporated. The remaining 4 drops of Liebermann-Burchard reagent, if there is a red/purple colour changing to blue or blue-green means there is steroid.

**Tanin:** 0.5 g of nano herbal andaliman mixed in 50 ml of distilled water, then filtered, and then added 1 drop of 1% iron (III) chloride solution. If bluish-green was formed, show tannin compounds.

### **Antioxidant test with 1,1-diphenyl-2-picrylhydrazyl (DPPH) method**

Nanoherbal andaliman was dissolved with methanol so that it becomes 250 µg/mL then homogenised for 10 minutes for 4 times then centrifuged to take the clear solution on top. Two mL of DPPH solution was added with 0.5 mL of nano herbal andaliman solution with 3 repetitions for each extract solution 6,25; 12.5; 25 and 50µg mL, then the absorbance was measured against methanol at a wavelength of 517 nm using a UV-Visible spectrophotometer.

### **Animal**

This study used 25 pregnant *Rattus norvegicus*. Rats were mated at the Biology Laboratory animal house, University of Sumatera Utara. Pregnant rats are made into preeclampsia model by injecting 3 ml of 6% NaCl/day/200 gBW at 6 to 12 days gestation subcutaneously. Preeclampsia rats were evaluated by blood pressure more than 125/80 mmHg, MDA levels and proteunaria values more than 3 g/L [14]. This study consisted of 5 groups: K<sup>-</sup> (negative control): Normal pregnant rats; K<sup>+</sup> (positive control): Preeclampsia (PE) pregnant rats, P1: PE rats given 1 ml EVOO/day/200 gBW in pregnancies 13 to 19 pregnancy day orally, P2: PE rats were given nanoherbal andaliman 100 mg/day/200 gBW at 13 to 19 days gestation orally, P3: PE rats were given a combination of 1 ml EVOO/day/200 gBW and nanoherbal andaliman 100 mg/days/200 gBW at 13 to 19 days of gestation orally. Pregnant rats were dissected on the 20th day of pregnancy, for blood and liver to be taken, and then

liver preparations were made with paraffin blocks and *Hematoxylin Eosin* (HE) staining.

### **Examination of Serum Glutamic Oxaloacetic Transaminase (SGOT) and Glutamic Serum Pyruvate Transaminase (SGPT)**

**SGOT:** Blood was centrifuged for  $\pm$  15 minutes at a speed of 5000 rpm. The blood serum then pipetted 200  $\mu$ L aqua dest into the test tube, added 2000  $\mu$ L of SGOT reagent 1 and then incubated for 5 minutes at 37°C. 500  $\mu$ L of reagent 2 SGOT was added after homogeneous absorbance was measured at 365 nm wavelength with a spectrophotometer.

**SGPT:** Blood is centrifuged for  $\pm$  15 minutes at a speed of 5000 rpm. Blood serum piped 200  $\mu$ L aquadest into the test tube then added 2000  $\mu$ L of reagent 1 SGPT, then homogenised. After incubation for 5 minutes at 37°C. We have added 500  $\mu$ L of reagent 2 SGPT then absorbance was measured at a wavelength of 365 nm with a spectrophotometer

### **Analysis of Data**

The data were calculated the average score of liver histopathology changes from five fields of view with the *Manja Roenigk Histopathology Scoring* model. Then data were analysed by Anova test and non-parametric data by *Kruskal Wallis test* in SPSS 22 program.

## **Results**

### **Phytochemical screening and DPPH test**

Based on the research that has been done, andaliman fruit in nanosize has the content of alkaloids, flavonoids, glycosides, steroids and terpenoids. The content of these compounds was similar to the content of andaliman extract in previous studies. DPPH test results on nano herbal andaliman with 3 repetitions for each extract solution 6,25; 12.5; 25 and 50 $\mu$ g / mL is IC<sub>50</sub> 48.5  $\mu$ g / mL. Nanoherbal andaliman have very strong antioxidants.

### **Bodyweight and liver weight**

Based on statistical data, ANOVA test on pregnant rat body weight showed that there was no significant difference in each treatment with  $p > 0.05$  ( $p = 0.060$ ). However, there were significant differences in liver weight ( $p < 0.05$ ). The highest average weight is in K<sup>+</sup> and the lowest group in the K<sup>-</sup> and P1 groups. Based on these data, nano herbal

andaliman, EVOO, and a combination of both can affect the weight of pregnant rat hearts. That means the liver here acts in the detoxification of foreign substances that first entered the body of the rat due to the content of secondary metabolites in the nano herbal andaliman and EVOO. The metabolic process in the liver is the process that affects its weight.

### **SGOT and SGPT**

Based on statistical data on SGOT values in pregnant rats, there were significant differences ( $p < 0.05$ ) in each treatment (Figure 1). However, the highest average value was found in the K<sup>+</sup> group and the lowest in the K<sup>-</sup> and P3 groups. Nanoherbal andaliman can increase SGOT values higher in pregnant rats than EVOO and a combination of both.

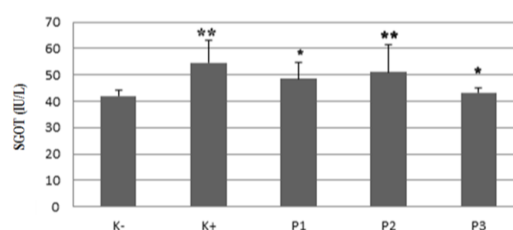


Figure 1: Data are expressed with *Kruskal Wallis test*; *Mann-Whitney test* was applied to compare SGOT value between all groups; \*\* $p < 0.01$  compared to control (K<sup>-</sup>); \* $p < 0.05$  compared to K<sup>+</sup>; K<sup>-</sup>: Pregnant normal; K<sup>+</sup>: PE rats; P1: PE rats after given EVOO; P2: PE rats after given nano herbal andaliman; P3: PE rats after given EVOO and nano herbal andaliman

The SGPT value also has a significant difference with a value of  $< 0.05$ . The highest average SGPT value was found in P2, and the lowest was found in the control group (K<sup>-</sup>). This means that there is a high level of damage in the PE liver treatment there is P2 so that the value of SGOT and SGPT is higher than other treatments. Based on this data nanoherbal andaliman and EVOO can increase the value of SGOT and SGPT in pregnant rats (Figure 2).

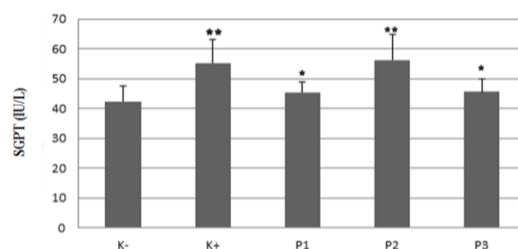


Figure 2: Data are expressed *Kruskal Wallis test*; *Mann-Whitney test* was applied to compare SGPT value between all groups; \*\* $p < 0.01$  compared to control; \* $p < 0.05$  compared to K<sup>+</sup>; K<sup>-</sup>: Pregnant normal; K<sup>+</sup>: PE rats; P1: PE rats after given EVOO; P2: PE rats after given nano herbal andaliman; P3: PE rats after given EVOO and nano herbal andaliman

### Histology of rat's liver

Based on statistical data on normal hepatocyte cell values, parenchymatous degeneration, hydrophilic degeneration and necrosis in pregnant rats using the cruciferous Wallis test there were no significant differences ( $p > 0.05$ ). But based on the highest average normal hepatocyte cells were found in K<sup>-</sup> and P1 while the lowest was in K<sup>+</sup> and P1 (Table 1). However, there was no significant difference in parenchymatous degeneration ( $p > 0.05$ ). The highest parenchymatous degeneration at K<sup>+</sup> and lowest at K<sup>-</sup>. The highest hydroptic degeneration was also found in P1 and P2 while the lowest was K<sup>-</sup>. The data proved significantly with a value of  $p < 0.05$ . The highest necrosis is at K<sup>+</sup> and lowest at K<sup>-</sup> and P3. Based on the statistics of nano herbal andaliman, EVOO and the combination of both causes liver damage with a degree of damage in the form of parenchymatous degeneration, hydrophilic degeneration and necrosis.

**Table 1: Average of normal hepatocytes cells and liver damages on preeclamptic rats**

Treatments	Normal	Parenchymatous Degeneration	Hydropic Degeneration	Necrosis
K <sup>-</sup>	13 ± 1.46	5.52 ± 1.76	5.52 ± 3.20	9.76 ± 3.67
K <sup>+</sup>	5.36 ± 1.49**	8.32 ± 2.69	11 ± 4.72**	27.2 ± 10.00**
P1	12.2 ± 1.31*	5.52 ± 1.94	11.5 ± 2.43	10.88 ± 3.56*
P2	8.56 ± 1.33**	6.72 ± 2.15	11.5 ± 3.43**	16.96 ± 4.21**
P3	11.2 ± 1.48*	7.2 ± 2.45	7.8 ± 3.00*	10.24 ± 4.18*

Kruskal Wallis test and Post-hock test were applied to compare mean of normal hepatocytes cell, hydroptic degeneration and necrosis value between all groups; \* $p < 0.05$  compared to control (K<sup>-</sup>); \*\* $p < 0.01$  compared to K<sup>-</sup>; Non-significant difference was found in the mean of parenchymatous degeneration between the groups ( $p = 0.058$ ).

Based on the average pattern of hepatocyte cell damage in pregnant rats, the greatest damage was found in the K<sup>+</sup> group and also P2, while the lowest damage was found in K<sup>-</sup> and P3 (Figure 3). Based on this data, pregnant women who often want to consume andaliman are better combined with EVOO to prevent liver cell damage.

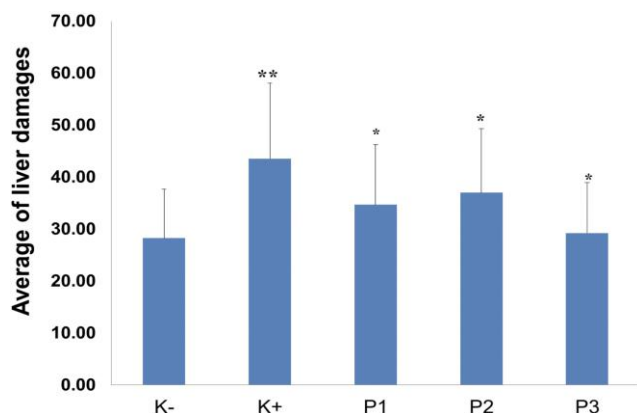


Figure 3: Data are expressed Kruskal Wallis test; Mann-Whitney test was applied to compare trophoblast cells value between all groups; \*\* $p < 0.01$  compared to control; \* $p < 0.05$  compared to K<sup>+</sup>; K<sup>-</sup>: Pregnant normal; K<sup>+</sup>: PE rats; P1: PE rats after given EVOO; P2: PE rats after given nano herbal andaliman; P3: PE rats after given EVOO and nano herbal andaliman

Based on histological observations, it was seen that K<sup>+</sup> (PE) had the greatest damage compared to other treatments. Liver hepatocyte damage was also seen after being given the herbal andaliman EVOO and a combination of both but not as much as K<sup>+</sup> (PE) (Figure 4). This means that the compounds contained in nano herbal andaliman cause liver necrosis. Fat degeneration (parenchymatous degeneration) is also seen in histology such as fat accumulation in the cell cytoplasm where fat in the cytoplasm pushes the cell nucleus to the side, due to interference with hepatocytes so that lipoproteins are not formed. In group P1 there are more parenchymatous degeneration characterised by varied fats and vacuoles but cannot be seen hydrophilic degeneration is also evident in K<sup>+</sup>, P1 and P2 where cell forms are like cell swelling (Figure 4). This degeneration is more severe damage; there are vacuoles containing water and cytoplasm that do not contain fat and glycogen.

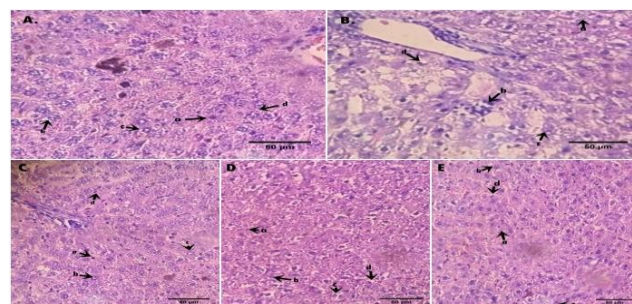


Figure 4: Histology of rats liver; A) K<sup>-</sup> (Pregnant normal); B) K<sup>+</sup>(PE rats); C) P1 (PE rats after given EVOO); D) P2 (PE rats after given nano herbal andaliman); E) P3 (PE rats after given EVOO and nano herbal andaliman); A) Normal; B) Parenchymatous degeneration; C) Hydroptic degeneration; D) Necrosis (H & E) 40x

### Discussion

PE can cause interference with the liver. Liver dysfunction can occur due to vasoconstriction and oedema that shows damage to the liver, muscles, kidneys, pancreas and red blood cells [15]. Liver damage is always associated with necrosis and administration of exogenous antioxidants, may be beneficial in protecting the liver [16]. Natural antioxidants are known to have beneficial effects on hepatitis or liver disorders caused by antitubercular agents [17]. Andaliman possesses unique flavour properties and bioactive compounds. The chemical compound in this herbal was Monoterpenes (46.54%), hydrocarbon monoterpenes (19.75%). The primary volatile compounds in andaliman (relative peak area > 10%) are geranyl acetate (32.04%) and limonene (15.80%) [18]. Andaliman in nanosize also contains alkaloids, flavonoids, glycosides, steroids and terpenoids as well as extracts [5], [6], [7]. Andaliman

fruits and leaves contain terpenoids, alkaloids, flavonoids, and other phenolics, which can function as antioxidants [19]. The ethyl acetate extract of andaliman fruit has antioxidant activity and with an IC50 value of 66.91 ppm and isolating EA.X.6.1 has antioxidant activity and with an IC505.55 ppm value [20]. Andaliman in nanosize has IC50 value of 48.5 µg/mL so that antioxidant properties are very strong compared to extract. Antioxidants are components that can inhibit free radicals and it is estimated that in scala nano can reduce oxidative stress in PE. According to Tensisca *et al.*, [21] andaliman fruit extract with ethanol and hexane has different antioxidant activity which is highest in water systems in emulsion and oily systems though having moderate activity. The content of important compounds is relatively stable during heating, but is heating up to 175°C; it can reduce up to 17%. Andaliman in the form of extract also has different contents and activities when exposed to heat, fluorescent light and ultraviolet [22]. Olive oil is a vegetable oil obtained from olive plants (*Olea europaea*) in the packaging of *Extra Virgin Olive Oil* (EVOO) in low doses can control serum levels of Hsp70, so the process of apoptosis does not occur excessively especially in preeclampsia [23]. The combination of these two plants can reduce hepatocyte cell damage because of the incorporation of antioxidants and vitamin E.

The value of SGPT and SGOT in PE can decrease with the combination of these two herbs (Figure 1 and 2). SGPT and SGOT will come out of liver cells if the liver cells are damaged so that it will cause an increase in SGPT and SGOT levels in blood serum [24], [25]. Increased SGOT treatment is also caused by stress. Hepatocytes are the type of cell that forms most of the liver. These cells are located between sinusoids, which are full of blood, and bile ducts. The liver is often the target organ of toxic substances because most poisons enter the body through the digestive system, then after being absorbed, carried by the portal vein to the liver — the highest parenchymatous degeneration at K<sup>+</sup> and lowest at K<sup>-</sup>. Parenchymatous degeneration is the lightest level of category of degeneration. Cells that become parenchymal degeneration are found in granules in the cytoplasm, due to the deposits that cause the cytoplasm to become cloudy and followed by swelling in cells [26]. The highest hydropic degeneration is also in K<sup>+</sup> (Table 1). Hydropic degeneration is a more severe level of damage. These changes are generally a result of metabolic disorders, such as hypoxia or chemical poisoning. This degeneration is also reversible even though it is possible to be irreversible if the cause of the injury persists [26]. Cells that have been injured can cause damage to the plasma membrane and changes in the nucleus. Pregnant women that often consume andaliman should also consume it with EVOO to prevent damage to the liver cells. EVOO contains vitamin E (tocopherol) that is anti-apoptosis [23]. Olives that are converted to *Extra virgin olive oil*

(EVOO) have analgesic, anti-inflammatory and anticancer properties [27]. So, using andaliman nano herbal is better along with EVOO to reduce necrosis in the liver.

Between P1, P2 and P3, it appears that more damage is found in P2 (Giving nano herbal andaliman only) means that the compounds contained in andaliman nanoherbal cause liver necrosis. Liver disease in PE have a high risk of pregnancy disorder, although no reports of maternal death but the birth of premature infants [28]. Liver disorders in PE diseases may increase liver enzymes, autoimmune, hyperemesis gravidarum, acute fatty liver, and intrahepatic cholestasis [29]. This is in accordance with Emita's study [30], where there was a change in the color and texture of the liver surface, as well as an increase in hepatocyte damage. Liver disorders in PE can increase liver enzymes, low platelets (HELLP), acute fatty liver, hyperemesis gravidarum, intrahepatic cholestasis, and autoimmune liver [29]. Regulations of damaged liver in the metabolic system can cause gestational hypertension during the first pregnancy and can cause PE, hemolysis, increased liver enzymes, and low platelet syndrome (HELLP) [31]. EVOO contains exogenous antioxidants has anti-inflammatory, anticancer and analgesic properties and neuroprotective activities that can fight oxidative damage to the brain [32]. Thus, andaliman in combination with EVOO is better and safer than just andaliman.

In conclusion, the combination of nanoherbal andaliman (*Zanthoxylum acanthopodium*) and *Extra Virgin Olive Oil* (EVOO) can reduce parenchymatous degeneration, hydrophic degeneration and hepatocyte cell necrosis in preeclampsia rats ( $p < 0.05$ ). Further testing with immunohistochemistry is recommended.

## Acknowledgements

Authors are grateful to the Directorate of research and community service, Directorate general of research and development, Ministry of research, Technology, and Higher education have funded our research in Grant of PMDSU 2019 (Master's Education towards Doctorate 2019).

## References

1. Bilano VL, Ota E, Ganchimeg T, Mori R, Souza JP. Risk Factors of Pre-eclampsia/Eclampsia and Its Adverse Outcomes in Low- and Middle-Income Countries: A WHO Secondary Analysis. 2014; 21:9(3):e91198. <https://doi.org/10.1371/journal.pone.0091198> PMID:24657964 PMCID:PMC3962376
2. SKDI. Number of Maternal Mortality. In: RI D, editor. Jakarta: Directorate of Maternal Health, 2007.

3. Menteri of healthy (Kemenkes RI). Situasi Kesehatan Ibu. Pusat Data dan Informasi Kementerian Kesehatan Republik Indonesia. Jakarta: Kementrian Kesehatan Republik Indonesia, 2014
4. Siregar BL. Deskripsi dan Perkecambahan Andaliman (*Zanthoxylum acanthopodium* DC.) di Sumatera Utara. Hayati. 2003; 10:1:38-40.
5. Wijaya CH, Hadiprodjo IT, Apriyantono A. Komponen volatil dan karakterisasi komponen kunci aroma buah andaliman (*Zanthoxylum acanthopodium* DC.). J. Teknologi Industri Pangan. 2001; 12:117-125.
6. Parhusip A, Yasni S, Elisabeth Y. Kajian metode ekstraksi andaliman (*Zanthoxylum acanthopodium* DC.) terhadap mikroba patogen dan merusak pangan. J Ilmu Teknologi Pangan. 2003; 1:112-123.
7. Suryanto E, Sastrohamidjojo H, Raharjo S, Tranggono. Singlet oxygen quenching effect of andaliman. (*Zanthoxylum acanthopodium* DC.). Indonesian Food and Nutrition Progress. 2004; 11:48-55.
8. Satria D, Jansen S, Ginda H, Ilyas S, Anjelisa P. Antioxidant and Antiproliferative Activities of an Ethylacetate Fraction of *Picria Fel-Terrae* Lour. Herbs. Asian Pac J Cancer Prev. 2017; 18(2):399-403.
9. Dewandari KT, Yasni S, Yuliani S. Ekstraksi dan Karakterisasi Nanopartikel Ekstrak Sirih Merah (*Piper Crocatum*). Jurnal Pascapanen. 2013; 10(2):58-65. <https://doi.org/10.21082/jpasca.v10n2.2013.58-65>
10. Saraf S, Ajazuddin A. Applications of Novel Drug Delivery System for Herbal Formulations. Fitoterapia. 2010; 81(7):680-689. <https://doi.org/10.1016/j.fitote.2010.05.001> PMID:20471457
11. Müller D, Schiffer M. Preeclampsia from a renal point of view: Insides into disease models, biomarkers and therapy. World J Nephrol. 2014; 3(4):169-181. <https://doi.org/10.5527/wjn.v3.i4.169> PMID:25374810 PMCID:PMC4220349
12. Situmorang PC, Ilyas S. Description of Testes Histology of *Mus musculus* after giving nano hebal *Rhodomyrtus tomentosa* (Haramonting). Asian J Pharm Clin Res. 2018; 11:11. <https://doi.org/10.22159/ajpcr.2018.v11i11.29042>
13. Departemen Kesehatan RI. Farmakope Indonesia Edisi IV. Jakarta: Departemen Kesehatan RI, 1995
14. Situmorang PC, Ilyas S, Hutahaean S. Study of Combination of Nanoherbal Andaliman (*Zanthoxylum acanthopodium*) and Extra Virgin Olive Oil (EVOO) Effects in the Expression of MDA, HSP-70 and Placental Histology of Preeclamptic Rats. Pharm. Sci. 2019; <https://doi.org/10.1088/1755-1315/305/1/012081>
15. Billington M, Stevenson M. Critical care in childbearing for midwives. Blackwell Publishing; 2007.
16. Pramodh, K, Deval RG, Lakshmayya, Ramchandra SS. Antioxidant and hepatoprotective activity of tubers of *Momordica tuberosa* cogn. Against CCl4 induced liver in rats. Indian J Exp Biol. 2008; 46:510-513.
17. Limsuwan S, Trip EN, Kouwen TR, Piersma S, Hiranrat A, Mahabusarakam W, et al. *Rhodomyrtone*: A new candidate as natural antibacterial drug from *Rhodomyrtus tomentosa*. Phytomedicine. 2009; 16(6):645-651. <https://doi.org/10.1016/j.phymed.2009.01.010> PMID:19303274
18. Wijaya CH, Napitupulu FI, Karnady V, Indariani S. A review of the bioactivity and flavor properties of the exotic spice "andaliman" (*Zanthoxylum acanthopodium* DC.). Food Reviews International. 2018; 1-19. <https://doi.org/10.1080/87559129.2018.1438470>
19. Rana VS and Blazquez MA. Terpenoid Constituents of *Zanthoxylum Acanthopodium* DC. Leaves. J Essen Oil Res. 2008; 20:515-516. <https://doi.org/10.1080/10412905.2008.9700075>
20. Winarti W, Simanjuntak P, Syahidin MF. Identifikasi Senyawa Kimia Aktif antioksidan dari ekstrak etil asetat buah andaliman (*Zanthoxylum acanthopodium* DC). TM Conference Series 01. 2018; 162-166. <https://doi.org/10.32734/tm.v1i3.283>
21. Tensiska C, Hanny W, Nuri. Antioxidative Activity of andaliman fruit extract (*Z. acanthopodium* DC.) on several food system and its antioxidative stability on temperature and pH Influence. Journal of Food Technology and Industry. 2003; 14(1):29-39.
22. Suryanto E, Raharjo S, Hardjono S, Tarnggono. Antioxidant activity and stability of andaliman extract (*Zhantoxylum acanthopodium*) on heating, fluoresent, and ultraviolet light. Jurnal Agritech. 2017; 25(2):63-69.
23. Irianti E, Ilyas S, Rosidah, S Hutahaean Hsp70 Expression Profile in Preeclampsia Model of Pregnant Rat (*Rattus norvegicus*) after Giving the EVOO. IOP Conference Series: Materials Science and Engineering. 2018; 180(1). <https://doi.org/10.1088/1757-899X/180/1/012161>
24. Teixeira RL, Morato RG, Cabello PH, Muniz LM, Moreira AS, Kritski AL, et al. Genetic polymorphisms of NAT2, CYP2E1 and GST enzymes and the occurrence of antituberculosis drug-induced hepatitis in Brazilian tuberculosis patients. Mem Inst Oswaldo Cruz. 2011; 106(6):74-276. <https://doi.org/10.1590/S0074-02762011000600011> PMID:22012226
25. Chatuphonprasert W, Jarukamjorn K. Impact of six fruits-banana, guajava, mangosteen, pineapple, ripe mango, and ripe papaya-on murine hepatic cytochrome P450 activities. J Appl Toxicol. 2012; 32:994-1001. <https://doi.org/10.1002/jat.2740> PMID:22499231
26. Yuningtyaswari Y, Dwi SA. The effects of air freshener exposure at an early age on histological white rat (*Rattus norvegicus*) liver cells. AIP Conf. Proc. 2016; 1744(1):020064-1-020064-4. <https://doi.org/10.1063/1.4953538>
27. Fezai M, Senovilla L, Jemaà M, Ben-Attia M and Ben-Attia M. Analgesic, anti-inflammatory and anticancer activities of extra virgin olive oil. J Lipids. 2013;1-7. <https://doi.org/10.1155/2013/129736> PMID:24455277 PMCID:PMC3884608
28. Situmorang PC, Ilyas S. Study of Preeclampsia in Placenta, Kidney, and Hepatic Dieases. Asian J Pharm Clin Res. 2018; 11(11):21-28. <https://doi.org/10.22159/ajpcr.2018.v11i11.27540>
29. Bremer L, Schramm C, Tiegs G. Immunology of hepatic diseases during pregnancy. Semin. Immunopathol. 2016; 38(6):669-685. <https://doi.org/10.1007/s00281-016-0573-1> PMID:27324237
30. Sabri E, Ilyas S and Prasetiawan E. 2018. The effect of n-hexane extract of andaliman (*Zanthoxylum acanthopodium* DC.) fruit in the liver tissues of mice during post implantation of pregnancy. Published under licence by IOP Publishing Ltd. Journal of Physics: Conference Series. 2018; 1116(5):052056. <https://doi.org/10.1088/1742-6596/1116/5/052056>
31. Tsai HM, Kuo E. From gestational hypertension and preeclampsia to atypical hemolytic uremic syndrome. Obstetrics & Gynecology. 2016; 127(5):907-10. <https://doi.org/10.1097/AOG.0000000000001340> PMID:27054930
32. Amel N, Wafa T, Samia D, Yousra B, Issam C, Cheraif I, et al. Extra virgin olive oil modulates brain docosahexaenoic acid level and oxidative damage caused by 2,4-dichlorophenoxyacetic acid in rats. J Food Sci Technol. 2016; 53:1454-64. <https://doi.org/10.1007/s13197-015-2150-3> PMID:27570270 PMCID:PMC4984713