

## Congenital absence of lumbosacral articular facet joint associated with conjoined nerve root: a case report

Shinji Yoshioka · Koichi Sairyo · Toshinori Sakai · Natsuo Yasui

Received: 24 November 2009 / Accepted: 7 July 2010 / Published online: 29 July 2010  
© The Author(s) 2010. This article is published with open access at Springerlink.com

**Abstract** We report a rare case of congenital absence of the L5-S1 facet joint, which was associated with a conjoined nerve root. Combination of these two anomalies has been quite rarely reported in the literature. A 39-year-old man presented with acute low back pain and right leg radiating pain. Muscle weakness and sensory disturbance of the right leg were also apparent in the region innervated by L5 and S1 nerve roots. Preoperative multidetector three-dimensional computed tomography (3D-CT) showed complete absence of the right S1 superior articular process. Magnetic resonance (MR) images showed lumbar disc herniation at right L5-S1 level that migrated cranially. Intraoperative findings revealed that the right L5 nerve root and S1 nerve root were conjoined, and the conjoined nerve root was compressed by L5-S1 disc herniation, which led to impairment of the conjoined nerve root by a single-level lumbar disc herniation. After removal of the disc herniation, his right leg pain immediately subsided, however muscle weakness and sensory disturbance persisted. Surgeons should be aware of this nerve root anomaly when examining a patient who shows an unusual clinical presentation and/or congenital osseous anomaly.

**Keywords** Conjoined nerve root · Facet joint · Anomaly · Lumbar disc herniation

### Introduction

Congenital absence of the lumbosacral articular facet joint is an uncommon anomaly [1–12]; it is usually asymptomatic and sometimes presents with a concomitant nerve root anomaly. To our knowledge, only three cases of congenital absence of the lumbosacral articular facet joint and a concomitant conjoined nerve root have been reported in the literature [9, 12].

We report a symptomatic case and the outcome of treatment.

### Case report

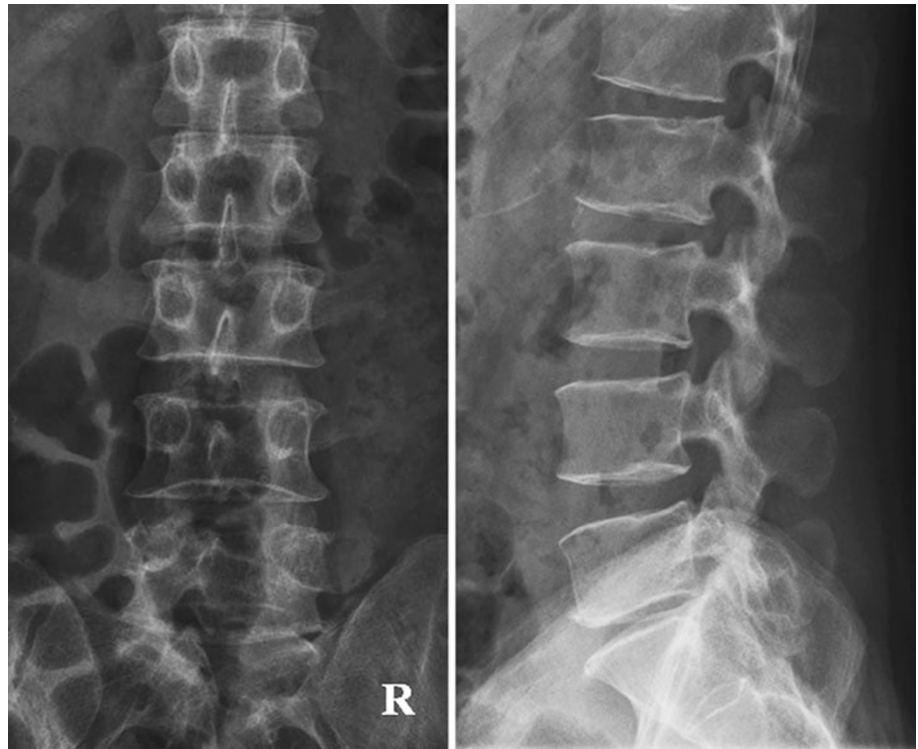
A 39-year-old man presented with acute low back pain and right leg radiating pain. He had no history of trauma or other trigger event. His symptoms had rapidly worsened until he was not able to walk because of right foot drop and severe leg pain. He was diagnosed a lumbar disc herniation at L5-S, and was referred to our hospital for surgical treatment.

Neurological examinations showed a positive straight-leg raising test at 30° on the right side. On manual muscle test (MMT), muscle weakness was found in the right leg: tibialis anterior was 1/5, extensor hallucis longus was 0/5, right flexor hallucis longus was 3/5, and triceps surae was 3/5. The right patella tendon reflex was normal and the right ankle jerk reflex was diminished. Hypoesthesia was noted in the right region innervated by L5 and S1 nerve roots. Neurologically, L5 and S1 nerve roots impairment was indicated. These findings were unusual symptoms of single-level lumbar disc herniation at L5-S1.

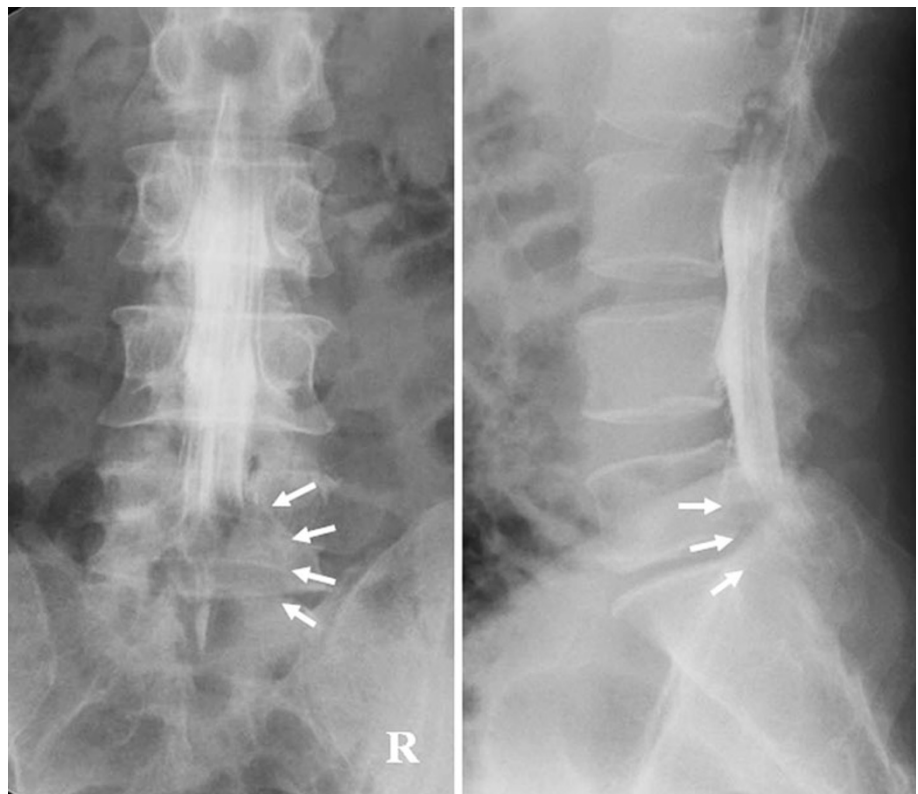
From plain anteroposterior (AP) and lateral radiographs of the lumbar spine, it was difficult to detect some spinal

S. Yoshioka · K. Sairyo (✉) · T. Sakai · N. Yasui  
Department of Orthopedics, Institute of Health Biosciences,  
The University of Tokushima Graduate School,  
3-18-15 Kuramoto-cho, Tokushima 770-8503, Japan  
e-mail: sairyo@hotmail.com

**Fig. 1** Plain AP and lateral radiographs of the lumbar spine. Despite slight disc space narrowing at L5-S1, there was no clear abnormality

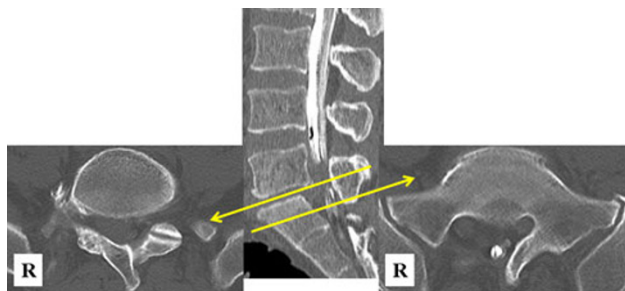


**Fig. 2** Myelograms showing incomplete block at L5 pedicular level, especially on the right side (arrows)

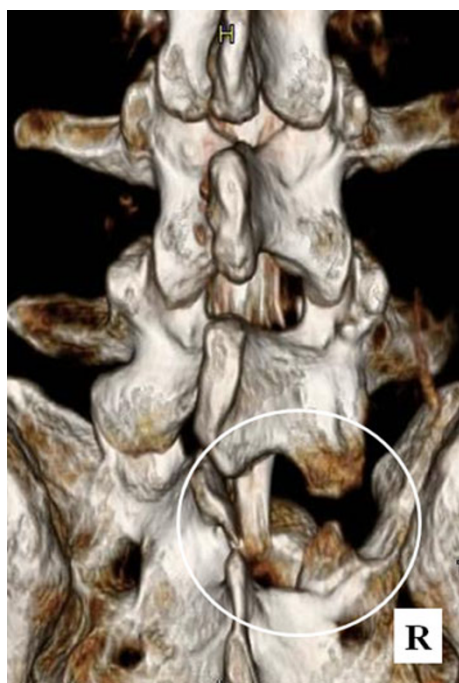


abnormalities. Slight disc space narrowing at L5-S1 was seen on the lateral view (Fig. 1). Myelograms showed incomplete blockade at the L5 pedicular level, especially

on the right side (Fig. 2). Computed tomography (CT) following myelography showed absence of the right L5-S1 facet joint (Fig. 3). Multidetector three-dimensional



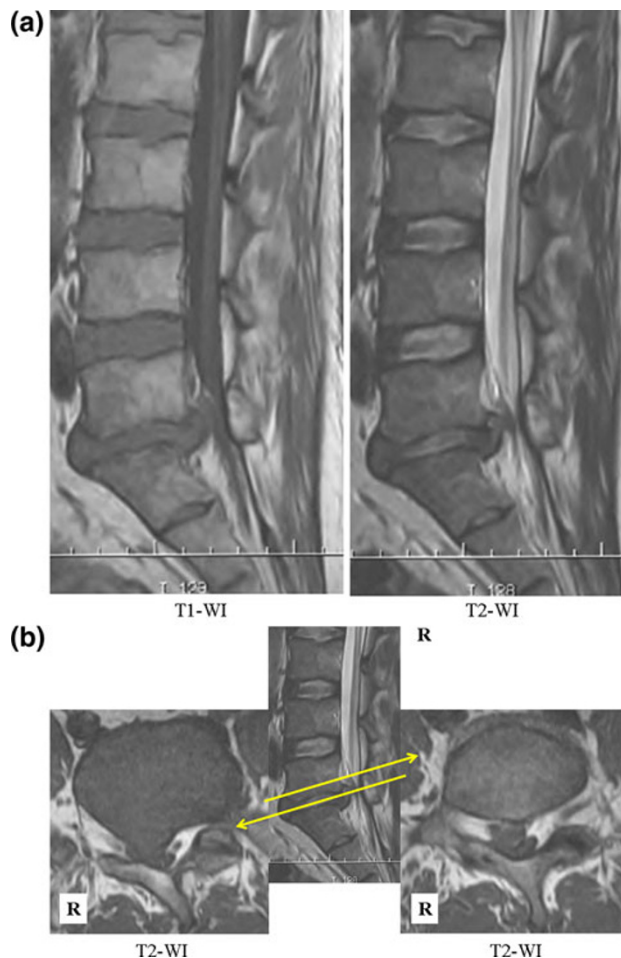
**Fig. 3** CT performed following myelography, showing absence of the right L5-S1 facet joint



**Fig. 4** 3D-CT showing complete absence of the S1 superior articular process (circle)

computed tomography (3D-CT) confirmed the absence of S1 superior articular process (Fig. 4). Magnetic resonance (MR) images showed disc herniation on the right side at the L5-S1 intervertebral disc level (Fig. 5a). Axial MR T2-weighted images at the L5-S disc level showed disc herniation (Fig. 5b, left panel), which migrated cranially (Fig. 5b, right panel). Based on the above neurological and radiological investigations, we diagnosed the patient as having a migrating mass that compressed the L5 nerve root and disc level lumbar disc herniation that compressed the S1 nerve root, causing these symptoms.

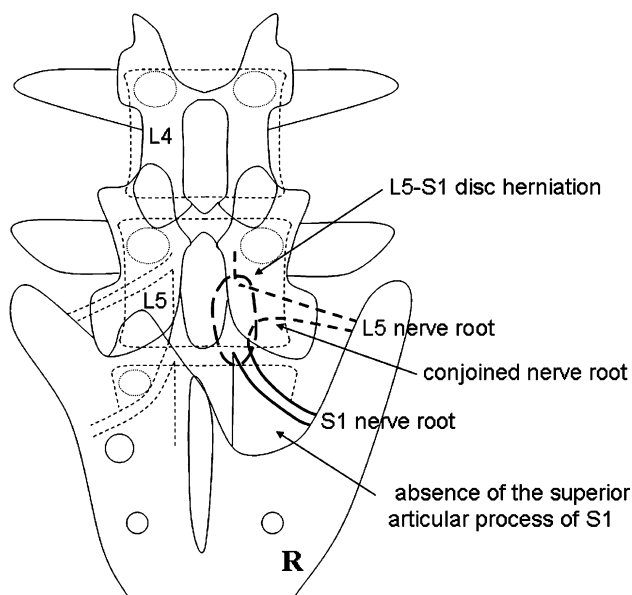
At first, to detect the L5 nerve root, we performed a fenestration at the right L4-5 using a microscope. At the L4-5 level, no nerve root was found, and right L5 hemilaminectomy was additionally conducted.



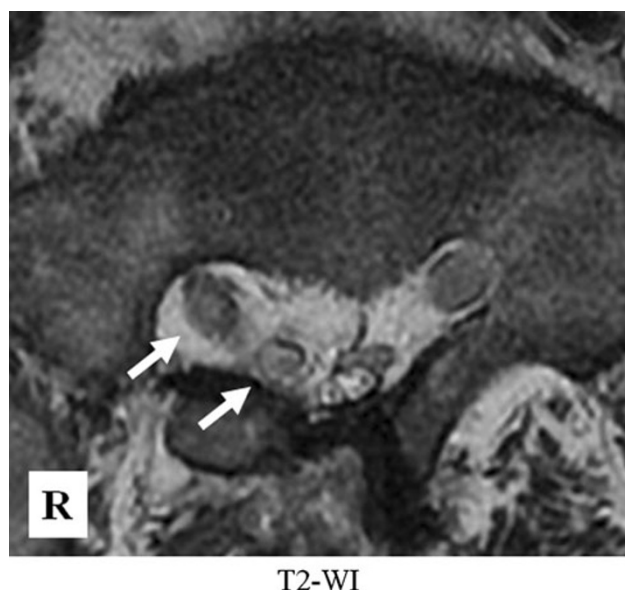
**Fig. 5** a MR sagittal images showing disc herniation at L5-S1 intervertebral disc level. b Axial MR T2-weighted images showing the herniated nucleus pulposus (HNP, left panel), which migrated cranially (b, right panel)

We found that the L5 nerve root originated from the caudal level of the L5 pedicle and conjoined with the S1 nerve root (Fig. 6). The large disc herniation at L5-S1 migrated cranially and was found beneath the abnormal conjoined nerve roots. After removal of the disc herniation and unroofing of the nerve root, no obvious mobility of the conjoined nerve root was obtained.

Postoperatively, leg pain immediately disappeared and muscle weakness slightly improved 3 months later: MMT of the right tibialis anterior and extensor hallucis longus became 2/5, and that of the right flexor hallucis longus and triceps surae became 5/5. At follow-up examination 1 month later, axial MR T2-weighted images from the S1 pedicle level showed the two confluent (L5 and S1) rootlets (Fig. 7). At present, our patient can walk with an ankle-foot orthosis without a cane. The patient was informed that data concerning the case would be submitted for publication, and he consented.



**Fig. 6** Schema of anomalies in this case. The absence of the S1 superior articular processes was obvious, and the L5 and S1 nerve roots were conjoined



**Fig. 7** Sagittal MR images obtained 1 month after the surgery, showing two confluent (L5 and S1) rootlets (arrows)

## Discussion

Congenital absence of the lumbosacral articular facet joint is rare, with only 25 cases reported in the English-language literature [1–12]. In the past cases, the L5-S1 facet joint was mostly affected (80%). Rowe et al. found only one case of congenital absence of the inferior articular process of L5 in 1,539 specimens [11]. Roche et al. studied 4,200 skeletons and failed to find this anomaly [10].

The etiology of this anomaly is generally accepted as follows: there are three primary ossification centers in each vertebra: one center in the vertebral body and two in the neural arches [5, 6, 8, 11, 13]. The facet defect is thought to originate from a failure of these ossification processes. However, the true etiology has not been clarified.

Although congenital absence of the lumbosacral articular facet joint seems to cause spinal instability, in only 3 of 25 cases was spinal fusion performed [5, 7, 13]. Most of the symptomatic patients were treated with conservative therapy and became asymptomatic. Only in severe cases must surgical fusion of the vertebra be performed. Because of the small number of cases, treatment remains controversial.

Conjoined nerve roots are relatively common anomalies of the lumbosacral spine. Numerous cases have been reported in the literature [2, 9, 12, 14–26]. The incidence of lumbosacral conjoined nerve roots varies among reports. Kadish et al. found eight conjoined nerve roots in 100 cadavers (8% incidence) [22]. Recently, Artico et al. reported that 0.25% of 1,200 patients who underwent CT or MRI had conjoined nerve roots [2]. Kadish et al. also reported that conjoined L5 and S1 roots are the most frequent (52.2%) [22]. Postacchini et al. stated that lumbosacral nerve root anomalies were almost asymptomatic and sometimes presented with symptoms by disc herniation [9].

The present case showed both anomalies, i.e., complete absence of the superior articular process of S1 and conjoined L5 and S1 nerve roots, which were symptomatically compressed by a large disc herniation. Osseous anomalies in the lumbosacral spine associated with conjoined nerve roots such as this case have been rarely reported. However, Rask stated that the presence of congenital osseous defects of the lumbosacral spine should indicate presence of nerve

**Table 1** Summary of previous cases of congenital absence of the lumbosacral articular facet joint associated with conjoined nerve root

Case	Authors	Sex, age (years)	Symptoms	Location of anomalies	Conjoined nerve roots	Presence of HNP
1	Postacchini et al. [19]	Unknown	Unknown	L5-S1	L5 & S1	–
2	Savas et al. [24]	Unknown	LBP	L5-S1	L5 & S1	–
3	Savas et al. [24]	Unknown	LBP	L5-S1	L5 & S1	–
Present case	Yoshioka et al.	Male, 39	LBP, leg pain, palsy	L5-S1	L5 & S1	+

HNP herniated nucleus pulposus, LBP low back pain



root anomalies [24]. To our knowledge, there have been 11 cases, including defect or anomaly of the vertebral arch, spondylosis, spondylolisthesis, and bifid sacrum, presenting with conjoined nerve roots [9, 11, 12, 15, 17, 24–26]. Only three previous cases were similar to the present case (Table 1) [9, 12].

In summary, we report a quite rare case of congenital absence of lumbosacral articular facet and conjoined nerve root. Surgeons should be aware of this nerve root anomaly when a patient shows an unusual clinical presentation and/or congenital osseous anomaly.

**Conflict of interest** None.

**Open Access** This article is distributed under the terms of the Creative Commons Attribution Noncommercial License which permits any noncommercial use, distribution, and reproduction in any medium, provided the original author(s) and source are credited.

## References

1. Arcomano JP, Karas S (1982) Congenital absence of the lumbosacral articular processes. *Skeletal Radiol* 8:133–134
2. Artico M, Carloia S, Piacentini M, Ferretti G, Dazzi M, Franchitto S et al (2006) Conjoined lumbosacral nerve roots: observations on three cases and review of the literature. *Neurocirurgia* 17:54–59
3. Downey EF Jr, Whiddon SM, Brower AC (1986) Computed tomography of congenital absence of posterior elements in the thoracolumbar spine. *Spine* 11:68–71
4. Ikeda K, Nakayama Y, Ishii S (1992) Congenital absence of lumbosacral articular process: report of three cases. *J Spinal Disord* 5:232–236
5. Keim HA, Keagy RD (1967) Congenital absence of lumbar articular facets. A report of three cases. *J Bone Joint Surg Am* 49:523–526
6. Klinghoffer L, Murdock MG, Hermel MB (1975) Congenital absence of lumbar articular facets. Report of two cases. *Clin Orthop Relat Res* 106:151–154
7. Pellegrini VD Jr, Hardy JH (1983) The absent lumbosacral articular process. A report of three cases and review of the literature. *Clin Orthop Relat Res* 175:197–201
8. Phillips MR, Keagy RD (1988) Congenital absence of lumbar articular facets with computerized axial tomography documentation. *Spine* 13:676–678
9. Postacchini F, Urso S, Ferro L (1982) Lumbosacral nerve-root anomalies. *J Bone Joint Surg Am* 64:721–729
10. Roche MB, Rowe GG (1951) The incidence of separate neural arch and coincident bone variations: a survey of 4,200 skeletons. *Anat Rec* 109:233–252
11. Rowe GG (1950) Anomalous vertebrae from the lumbosacral column of man. *Anat Rec* 107:171–179
12. Savas R, Calli C, Yuntun N, Alper H (1998) Hypoplastic lumbar pedicle in association with conjoined nerve root MRI demonstration. *Comput Med Imaging Graph* 22:77–79
13. Segal D, Franchi AV (1986) Congenital absence of lumbar facets as a cause of lower-back pain. *Spine* 11:78–80
14. Bernini PM, Wiesel SW, Rothman RH (1980) Metrizamide myelography and the identification of anomalous lumbosacral nerve roots. Report of two cases and review of the literature. *J Bone Joint Surg Am* 62:1203–1208
15. Cannon BW, Hunter SE, Picaza JA (1962) Nerve-root anomalies in lumbar-disc surgery. *J Neurosurg* 19:208–214
16. Keon-Cohen B (1968) Abnormal arrangement of the lower lumbar and first sacral nerves within the spinal canal. *J Bone Joint Surg Br* 50:261–265
17. Davidson D, Rowan R, Reilly C (2006) Lumbosacral nerve root anomaly associated with spondylolisthesis in an adolescent: a case report and review of the literature. *Spine* 31:E718–E721
18. Goffin J, Plets C (1987) Association of conjoined and anastomosed nerve roots in the lumbar region: A case report. *Clin Neurol Neurosurg* 89:117–120
19. Goffin J, Plets C (1987) Unusual combination of anomalies of lumbar nerve roots. *Acta Anat (Basel)* 128:161–163
20. Helms CA, Dorwart RH, Gray M (1982) The CT appearance of conjoined nerve roots and differentiation from a herniated nucleus pulposus. *Radiology* 144:803–807
21. Hoddick WK, Helms CA (1985) Bony spinal canal changes that differentiate conjoined nerve roots from herniated nucleus pulposus. *Radiology* 154:119–120
22. Kadish LJ, Simmons EH (1984) Anomalies of the lumbosacral nerve roots. An anatomical investigation and myelographic study. *J Bone Joint Surg Br* 66:411–416
23. Okuwaki T, Kunogi J, Hasue M (1991) Conjoined nerve roots associated with lumbosacral spine anomalies. A case report. *Spine* 16:1347–1349
24. Rask MR (1977) Anomalous lumbosacral nerve roots associated with spondylolisthesis. *Surg Neurol* 8:139–140
25. Sener RN (1997) Sacral pedicle agenesis. *Comput Med Imaging Graph* 21:361–363
26. Neidre A, Macnab I (1983) Anomalies of the lumbosacral nerve roots. Review of 16 cases and classification. *Spine* 8:294–299