

## The True Malignancy Rate in 135 Patients With Preoperative Diagnosis of a Lateral Neck Cyst

Søren Grønlund, MD; Kristianna Mey, MD, PhD; Elo Andersen, MD, PhD; Eva Rye Rasmussen, MD, PhD

**Objective:** In this study, the true malignancy rate in 135 patients with a preoperative tentative diagnosis of a lateral neck cyst (LNC) was assessed. Furthermore, the sensitivity and specificity of fine needle aspiration of suspected LNC were evaluated and the diagnostic delay was analyzed.

**Study Design:** This study was retrospective in design and included all patients who had undergone surgery for a suspected LNC in four secondary hospitals in the eastern regions of Denmark during the period of 2009 to 2012.

**Methods:** One hundred thirty-five patients were identified and included by means of a search strategy for NOMEKO surgical procedure codes KENB40A+B in the electronic surgical booking systems. Because the procedure codes also include median neck cysts and fistulas, the latter were excluded manually.

**Results:** Of the 135 patients preoperatively diagnosed with LNC, a malignant postoperative histopathological diagnosis was revealed in 19 patients (14.4%). Of these, three individuals were between 35 to 40 years of age. In 17 cases, preoperative fine-needle aspiration biopsy showed benign cytology, whereas histopathology postoperatively proved to be malignant. This renders a sensitivity of 88.8% and a specificity of 60.0% for fine needle aspiration biopsy with regard to LNC diagnostics.

**Conclusion:** This study suggests that, for patients older than 35 years, a cystic lateral neck mass should be considered potentially malignant; by contrast, LNC is a diagnosis of exclusion. Any delay in treatment should be avoided until final histopathological diagnosis has been obtained. Arguably, all patients older than 35 years with a cystic lesion laterally on the neck should be included in the fast-track cancer referral program.

Key Words: Cysts, branchial, metastasis, cervical, malignant, fine needle aspiration.

Level of Evidence: 2b.

### INTRODUCTION

Benign/congenital lateral neck cysts (LNC) are a relatively rare clinical entity, appearing as head and neck masses in children and adults. LNC typically arise from the second branchial arch and most frequently become symptomatic in the second and third decade.<sup>1,2</sup> Of all cervical tumors, the congenital conditions account for 12%; almost one-fourth of these represent LNCs.<sup>3</sup>

This is an open access article under the terms of the Creative Commons Attribution-NonCommercial-NoDerivs License, which permits use and distribution in any medium, provided the original work is properly cited, the use is non-commercial and no modifications or adaptations are made.

From the Department of Otorhinolaryngology, Hillerød Hospital (S.G.), Hillerød, Denmark; Department of Otorhinolaryngology, Head and Neck Surgery and Audiology, Rigshospitalet and Gentofte Hospital (K.M.), University of Copenhagen, Copenhagen, Denmark; Department of Oncology (E.A.), Herlev Hospital, Denmark; and the Department of Otorhinolaryngology, Head and Neck Surgery and Audiology, Rigshospitalet (E.R.R.), University of Copenhagen, Copenhagen East, Denmark

Editor's Note: This Manuscript was accepted for publication 20 May 2016.

K.M. is currently a PhD student supported by a grant from the Oticon Foundation. This study is not a part of her PhD project. The authors have no other funding, financial relationships, or conflicts of interest to disclose.

Data-sharing statement: Interested scientists can obtain the anonymized raw data upon request.

Send correspondence to Eva Rye Rasmussen, Department of Otorhinolaryngology, Head & Neck Surgery and Audiology, Rigshospitalet, University of Copenhagen, Blegdamsvej 9, 2100 Copenhagen East, Denmark. E-mail: eva.rye.rasmussen@dadlnet.dk

DOI: 10.1002/liv.2.23

Clinically, the condition usually appears as a palpable and sometimes fluctuating painless mass in the angle between the mandible and the anterior edge of the sternocleidomastoid muscle.<sup>2</sup>

Malignant tumors of the neck are rare in patients younger than 40 years of age; however, among young nonsmokers, an increasing incidence of human papillomavirus (HPV)-related head and neck squamous cell carcinomas (HNSCC) arising from the lymphatic tissue of Waldeyers ring has been reported.<sup>4,5</sup> A typical debut of HNSCC could be in the form of a cystic metastasis on the lateral aspect of the neck, which clinically resembles LNC.<sup>2, 6-9</sup> Metastases from PTC might also mimic benign lateral and median neck cysts, even in patients younger than 40 years of age.<sup>10</sup>

In the initial clinical assessment, fine needle aspiration biopsy (FNAB), preferably ultrasound-guided, has been considered to be of paramount importance in planning an appropriate treatment and surgery strategy. However, clinico-histopathological discrepancies between FNAB and postoperative histopathology are well documented, rendering preoperative diagnosis challenging, especially in cystic tumors.<sup>11,12</sup>

This study aims to clarify how many of the primary LNC diagnoses in reality represent malignant conditions. Furthermore, we evaluated the diagnostic accuracy of FNAB as a method of preoperative assessment, while also determining a possible preoperative delay.

## MATERIALS AND METHODS

A retrospective search was conducted including all patients who, based on preoperative diagnostic assessment, had undergone surgery for a suspected LNC in four hospitals in the eastern part of Denmark (Capital Region and Zealand Region, with approximately 2.5 million inhabitants) during 2009 to 2012. All of the patients from four of the five general departments of otolaryngology–head and neck surgery in these regions were included. The fifth department was excluded because it is a tertiary referral hospital specializing in cancer treatment. In that department, due to differences in the way surgical bookings are done, some LNC operations are booked as neck dissections. This bias could obscure the initial purpose of the study; primarily to analyze the malignancy rate in initially unsuspecting patients operated in connection with a suspected LNC. One hundred thirty-five patients were identified and included by means of a search for NOMEKO surgical procedure codes KENB40A+B in the ORBIT operation booking system (WM-data, Stockholm, Sweden) at Hillerød and Gentofte Hospital and in the Green System (CSC Scandihealth, Valby, Denmark) at Køge and Slagelse Hospitals, respectively. This coding system holds no information on the location of the neck lesion; thus, patients suffering from median neck cysts and fistulas were excluded manually, together with a few erroneous bookings such as lipomas and atheromas. All age groups were included. Information regarding demographic data, preoperative clinical assessment, FNAB, surgical outcome, and histopathology was extracted from the patients' medical records. Delay was defined as days elapsed since the first hospital consultation until surgery. Microsoft Excel (Microsoft Corp., Redmond, WA) and STATA version 13 (StataCorp LP, College Station, TX) were used for analysis and statistics. Due to the relatively small sample size, Fisher's exact test and difference of proportions test were chosen to assess the findings' statistical significance.

## RESULTS

A total of 135 patients had surgery performed on the basis of an initial diagnosis of LNC in the period covered by this study; demographic data is shown in Table I and age distribution versus diagnosis in Figure 1. There was a small change over time in the malignancy rate,

TABLE I.  
Characterization of the 135 Patients.

	Data
Patients, <i>n</i>	135
Female, <i>n</i>	68
Male, <i>n</i>	67
Female:Male ratio	1:01
Age, years, mean (range)	38.6 (3–80)
Median, years	39
Time elapsed from referral to surgery, mean, days (range)	86.3 (1–810)
Median, days	35

namely 16.1% in 2009 to 2010 versus 10.4% in 2011 to 2012. However, the difference did not reach statistical significance.

## FNAB

One hundred and fifteen patients had a preoperative FNAB performed; the subsequent pathology report diagnosed 85 patients with LNC. It was not possible to record how many of the FNABs were ultrasound-guided. Nine patients had inconclusive preoperative FNAB performed, and 11 patients had no FNAB performed (Fig. 2). The overall malignancy rate was 14.4% (19 of 135 patients). Three of the patients were between 35 to 40 years of age; two patients suffered from papillary thyroid carcinoma (1.5%); and 17 patients were diagnosed with HNSCC (12.6%). Furthermore, immunoreactivity for p16 was described in nine out of 16 postoperative pathology reports. In one pathology report, p16 expression was absent. In 17 of the malignant cases, the preoperative FNAB showed benign cytology; one biopsy was inconclusive; and one was unsuitable for analysis. For FNABs regarding LNC diagnostics, this renders a sensitivity of

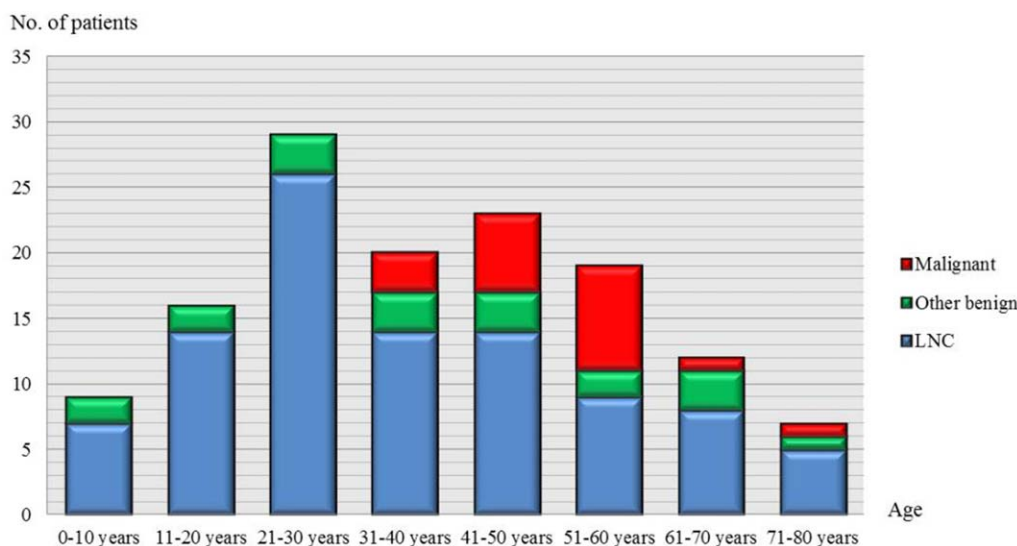


Fig. 1. Age-distribution and final histopathological diagnosis. LNC = lateral neck cyst.

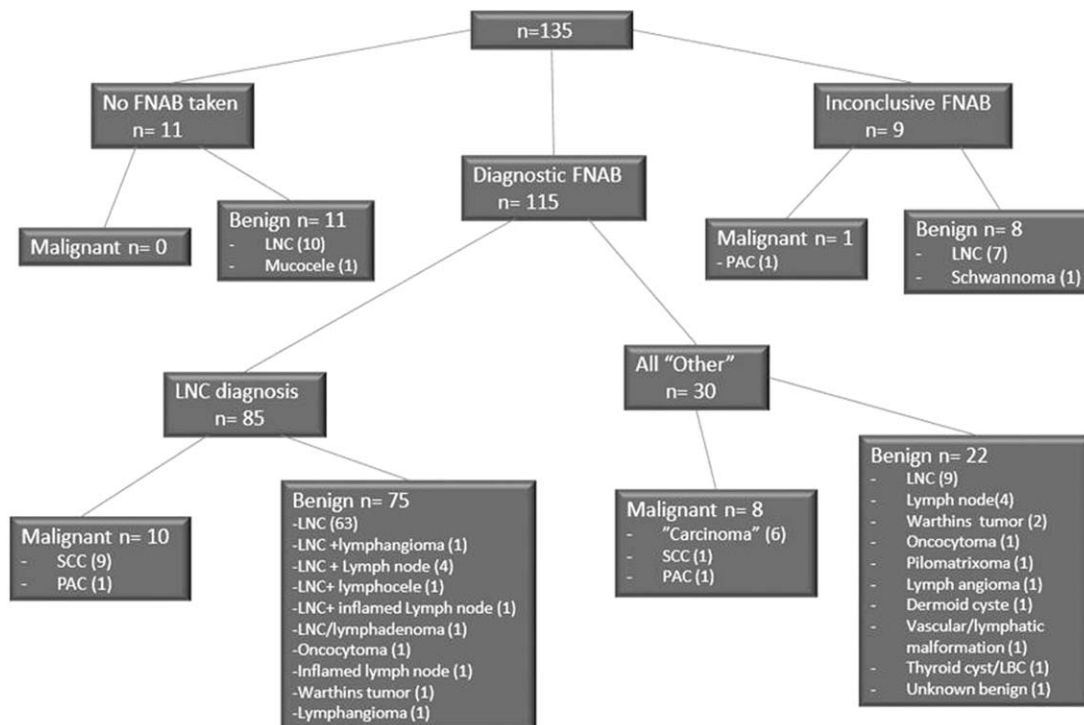


Fig. 2. Fine-needle aspiration biopsy (FNAB) outcome and final histopathological diagnosis in 135 suspected lateral neck cysts (LNC). FNAB = fine-needle aspiration biopsy; LNC = lateral neck cyst; PAC = papillary carcinoma (papillary thyroid cancer); SCC = squamous cell carcinoma.

88.8% and a specificity of 60.0%. The diagnostic odds ratio was 11.8 (95% confidence interval (CI) 4.492–31.173) and the positive likelihood ratio 2.22 (95% CI 1.468–3.354). (For the sensitivity with regard to benign diagnoses, see Table II).

### Treatment Delay

From referral of a patient until surgery was performed, a mean of 86.3 days (range 1–810 *d*) and median of 35 days elapsed (Table I). In the 65 patients over 40 years of age, the mean and median delays were 77.15 (range 1–730 *d*) and 44 days, respectively. In the 19 patients who eventually turned out to have malignant disease, the mean and median delays were 68.2 (range 12–270 *d*) and 51.5 days, respectively (Table III).

TABLE II.

Concordance Between 85 Preoperative Fine-Needle Aspiration Biopsies Suggestive of Lateral Neck Cyst With PostOperative Histology Reports.

Histological diagnosis (postoperative), <i>n</i>	
Lateral neck cyst	71
Malignant metastasis	10
Lymphangioma	1
Oncocytoma	1
Warthins tumor	1
Inflamed lymph node	1

### DISCUSSION

In this study, patients who underwent surgery due to a suspected LNC were assessed. The main objectives were to investigate the malignancy rate, the use of FNAB as a diagnostic tool, and the treatment delay that a false benign diagnosis might cause. HNSCC metastases accounted for most of the 19 malignant tumors (12.6%), but two cases of PTC (1.5%) were also diagnosed. Additional characteristics of the HNSCC metastases showed positive p16 expression in nine out of 16 patients (one report with missing HPV typing). This correlates with the reported increasing incidence of HPV-related HNSCC.<sup>45</sup> Our study emphasizes that both HNSCCs and papillary thyroid carcinomas tend to create cystic metastases on the lateral aspect of the neck.

Few previous studies have been carried out in a similar manner; the cohort of the present study is the largest ever reported. Sira et al. described 29 patients and found a malignancy rate of 6.9%, while Cinberg et al. reported a malignancy rate of 22% in 18 patients.<sup>2,12</sup> The present findings are consistent with previous studies; however, our data was collected from four different hospitals, thus making them more heterogeneous compared to the studies by Sira et al. and Cinberg et al.

All cases of malignancy in the present study occurred in patients 35 years of age or older, but a few cases of cystic metastasis from HNSCC in patients as young as 26 years of age have previously been reported.<sup>13</sup> In total, three patients aged 35 to 40 were postoperatively diagnosed with a malignant disease, despite a preoperative benign FNAB. This highlights the rather low specificity of

TABLE III.

Characterization of Patients Wrongfully Diagnosed With LNC and Postoperatively Diagnosed With Malignant Disease by Means of Histopathological Assessment of Removed Tumor.

	Data	Number of Patients
Age, mean, years (range)	57,7 (35–73)	19
Gender	Male	12
	Female	7
Fine-needle aspiration biopsy result, <i>n</i>	Benign cells	17
	Inconclusive	1
	Not suitable for analysis	1
Time elapsed from referral to surgery, mean, <i>days</i> (range)	62.8 (12–270)	
Time elapsed from referral to surgery, median, <i>days</i>	51.5	
Diagnosis	Squamous cell carcinoma	16
	Papillary thyroid carcinoma	3

60%. Two of these patients suffered from PTC, and one patient suffered from squamous cell carcinoma (SCC) with a primary tumor of unknown origin. In Denmark, no recommendations regarding the use of imaging modalities exist with regard to patients younger than 40 years of age who exhibited a tumor at the usual location of LNC. In general, these patients are considered at low risk of metastatic head and neck cancer; however, we identified three cases of malignant disease in patients between 35 and 40 years of age. Subsequently, this group of patients would have to endure secondary surgery (on an already operated neck) and/or higher doses of radiotherapy due to the risk of residual tumor.<sup>14,15</sup> In addition, when staging and assessing the patient with a primary tumor, secondary inflammation caused by surgery will also make positron emission tomography/computerized tomography (PET/CT) more difficult to interpret.<sup>2,16</sup>

No international consensus exists regarding guidelines for the preoperative clinical diagnostic workup of cystic masses on the lateral neck with an unknown primary tumor in patients younger than 40 years of age. However, for patients older than 40 years of age, the current recommendation is to perform a panendoscopy with tonsillectomy, nasopharyngeal, and base of tongue biopsy in all cases of cystic lesions on the lateral neck. This is in order to avoid unnecessary surgery on metastases with a subsequent need for reoperation, that is, neck dissection. Ultrasound guided FNAB, combined with prebiopsy/preoperative PET/CT and occasionally magnetic resonance imaging, are also advised.<sup>2,15,17</sup> However, radiologists are challenged by the degree of overlap between features seen in malignant and benign cystic head and neck masses, especially in a nonsmoking population younger than 40 years of age.<sup>18–20</sup> Positron emission tomography/CT scans and magnetic resonance imaging have certain limitations regarding small primary tumors; these radiologic modalities are nonetheless useful tools for identify-

ing lymph node metastases and also for discovering primary tumors of a certain size.<sup>21</sup> When PET/CT is performed prior to panendoscopy and biopsies, in order not to cause secondary inflammation and hence a possible false-positive result, 44% to 55% of primary unknown tumors in the head and neck area are likely to be identified.<sup>16,22,23</sup> Hence, FNAB is suggested in addition to neck PET/CT to reduce uncertainties; however, FNAB has a much higher sensitivity and lower false positive rate when handling solid rather than cystic tumors.<sup>5,24–26</sup> When performing a FNAB in a cystic mass, the specimen might contain only fluid—or just a few cells for the pathologist to analyze—hereby often rendering repetitive FNABs inevitable. This creates a treatment delay and thus potential progression of the stage of the tumor. Furthermore, macrophages and squamous cells appearing in the FNAB specimens can resemble not only squamous cell-lined cysts (like an LNC) but also highly differentiated HNSCC metastases.<sup>8,26</sup> Inflamed LNCs may also give rise to dedifferentiated squamous epithelial cells, and a cancer can be erroneously interpreted as such.<sup>9,23,27</sup>

In the literature, only in 50% of HNSCC cases with a metastasis of the neck was a primary tumor found during clinical evaluation. In 10% to 50% of the examined patients, no primary tumor was found at all (primary unknown) because tumors may be only millimeters in size.<sup>5,26</sup> If a definitive diagnosis has not been reached, it is advised either to perform both a second-look panendoscopy and random biopsies; alternatively, to proceed to surgical excision, including perioperatively frozen-section analysis of the cystic mass and neck dissection (if necessary due to malignancy found perioperatively).<sup>17</sup> These patients should be treated at a specialized tertiary referral center.

With regard to the earlier discussed obstacles in diagnosing LNC, the age of the patient has always been of great importance when planning the diagnostic workup. If the patient is older than 40 years, a fast-track cancer referral program is currently advised.<sup>15,17</sup> In Denmark, the fast regimen ensures that patients with cancer of unknown origin, usually presenting as a metastasis of the neck, have a diagnostic delay of maximum 28 days.<sup>17</sup> In our series, however, three patients with metastatic carcinomas fell under this age cutoff. As Gourin et al. argue, age is an arbitrary parameter, but even so it is currently the single most important factor in planning the clinical diagnostic workup.<sup>26</sup> Taking into account the increase in HPV-related HNSCC found in younger nonsmoking patients and the presence of PTC in those under 40, one could propose to lower the age of fast-track regimen to 35 years.<sup>4,6,15</sup>

## CONCLUSION

In the present study, 16% of the 19 malignant tumors identified were found in patients between 35 and 40 years of age. In the majority of guidelines, this is below the cutoff age for the fast-track cancer referral program. This could promote a need for a discussion of the best age cutoff value in these patients, especially with the increasing rate of young, nonsmoking, HPV-associated

HNSCC patients. Fine needle aspiration biopsy is found valuable in the assessment of the cystic tumors of the neck; however, it has a low specificity and a relatively high rate of false-negative results, which may cause significant delays in diagnostic and treatment. In case the diagnosis is unclear, an extirpation can be done, provided that it can be followed up by frozen section diagnosis and subsequent, appropriate neck dissection if malignancy is determined by the frozen section biopsy. For this reason, operations of this kind, especially in patients older than 35 years, should be centralized in a specialized department.

### Acknowledgment

We wish to thank Jacob L. Mey, Professor Emeritus of Linguistics, for his assistance in critically revising this article with regard to the English language.

### BIBLIOGRAPHY

- Bhaskar S, Bernier J. Histogenesis of branchial cysts; a report of 468 cases. *Am J Pathol* 1958;35:407–443.
- Sira J, Makura ZGG. Differential diagnosis of cystic neck lesions. *Ann Otol Rhinol Laryngol* 2011;120:409–413.
- Al-Khateeb TH, Al Zoubi F. Congenital neck masses: a descriptive retrospective study of 252 cases. *J Oral Maxillofac Surg* 2007;65:2242–2247. doi: 10.1016/j.joms.2006.11.039.
- Lajer CB, von Buchwald C. The role of human papillomavirus in head and neck cancer. *APMIS* 2010;118:510–519. doi: 10.1111/j.1600-0463.2010.02624.x.
- Goldenberg D, Begum S, Westra WH, et al. Cystic lymph node metastasis in patients with head and neck cancer: an HPV-associated phenomenon. *Head Neck* 2008;30:898–903. doi: 10.1002/hed.20796.
- McHugh JB. Association of cystic neck metastases and human papillomavirus-positive oropharyngeal squamous cell carcinoma. *Arch Pathol Lab Med* 2009; 133:1798–1803. doi: 10.1043/1543-2165-133.11.1798.
- Goldenberg D, Sciubba J, Koch WM. Cystic metastasis from head and neck squamous cell cancer: a distinct disease variant? *Head Neck* 2006; 28:633–638. doi: 10.1002/hed.20381.
- Regauer S, Mannweiler S, Anderhuber W, et al. Cystic lymph node metastases of squamous cell carcinoma of Waldeyer's ring origin. *Br J Cancer* 1999;79:1437–1442. doi: 10.1038/sj.bjc.6690229.
- Hardee PS, Hutchison IL. Solitary nodal metastases presenting as branchial cysts: a diagnostic pitfall. *Ann R Coll Surg Engl* 1999;81:296–298.
- Pazaitou-Panayiotou K, Alevizaki M, Boudina M, et al. Cervical masses as manifestation of papillary thyroid carcinomas  $\leq 10$  mm in diameter, in patients with unknown thyroid disease. *Thyroid Res* 2008;1:8. doi: 10.1186/1756-6614-1-8.
- Flanagan PM, Roland NJ, Jones AS. Cervical node metastases presenting with features of branchial cysts. *J Laryngol Otol* 1994;108:1068–1071. doi: 10.1016/S0936-6555(05)80524-2.
- Cinberg JZ, Silver CE, Molnar JJ, Vogl SE. Cervical cysts: cancer until proven otherwise? *Laryngoscope* 1982;92:27–30.
- Nordemar S, Hogmo A, Lindholm J, et al. The clinical value of image cytometry DNA analysis in distinguishing branchial cleft cysts from cystic metastases of head and neck cancer. *Laryngoscope* 2002;112:1983–1987. doi: 10.1097/00005537-200211000-00014.
- Adoga AA, Silas OA, Nimkur TL. Open cervical lymph node biopsy for head and neck cancers: any benefit? *Head Neck Oncol* 2009;1:9. doi: 10.1186/1758-3284-1-9.
- Harreus U. Surgical errors and risks—the head and neck cancer patient. *GMS Curr Top Otorhinolaryngol Head Neck Surg* 2013;12: Doc04. doi: 10.3205/cto000096.
- Keller F, Psychogios G, Linke R, et al. Carcinoma of unknown primary in the head and neck: comparison between positron emission tomography (PET) and PET/CT. *Head Neck* 2011;33:1569–1575. doi: 10.1002/hed.21635.
- Dahanca. 2013. Available at: [https://www.dahanca.oncology.dk/Brows\\_Web\\_Guidelines\\_Danish\\_Soc\\_Head\\_Neck\\_Oncol\\_DAHANCA\\_1-30](https://www.dahanca.oncology.dk/Brows_Web_Guidelines_Danish_Soc_Head_Neck_Oncol_DAHANCA_1-30). Accessed on May 2015.
- Hu S, Hu C-H, Yang L, et al. Atypical imaging observations of branchial cleft cysts. *Oncol Lett* 2014;7:219–222. doi: 10.3892/ol.2013.1656.
- Goyal N, Zacharia TT, Goldenberg D. Differentiation of branchial cleft cysts and malignant cystic adenopathy of pharyngeal origin. *AJR Am J Roentgenol* 2012;199:W216–21. doi: 10.2214/AJR.11.8120.
- Corey AS, Hudgins PA. Radiographic imaging of human papillomavirus related carcinomas of the oropharynx. *Head Neck Pathol* 2012;6(suppl 1):S25–S40. doi: 10.1007/s12105-012-0374-3.
- Johansen J, Petersen H, Godballe C, et al. FDG-PET/CT for detection of the unknown primary head and neck tumor. *Q J Nucl Med Mol Imaging* 2011;55:500–508.
- Waltonen JD, Ozer E, Hall NC, et al. Metastatic carcinoma of the neck of unknown primary origin: evolution and efficacy of the modern workup. *Arch Otolaryngol Head Neck Surg* 2009;135:1024–1029. doi: 10.1001/archoto.2009.145.
- Goldenberg D, Sciubba J, Koch WM. Cystic metastasis from head and neck squamous cell cancer: a distinct disease variant? *Head Neck* 2006; 28:633–638. doi: 10.1002/hed.20381.
- Schwarz R, Chan NH, MacFarlane JK. Fine needle aspiration cytology in the evaluation of head and neck masses. *Am J Surg* 1990;159:482–485.
- Tandon S, Shahab R, Benton JII, et al. Fine-needle aspiration cytology in a regional head and neck cancer center: comparison with a systematic review and meta-analysis. *Head Neck* 2008;30:1246–1252. doi: 10.1002/hed.20849.
- Gourin CG, Johnson JT. Incidence of unsuspected metastases in lateral cervical cysts. *Laryngoscope* 2000;110:1637–1641. doi: 10.1097/00005537-200010000-00012.
- Kadhim A L, Sheahan P, Colreavy MP, Timon CV. Pearls and pitfalls in the management of branchial cyst. *J Laryngol Otol* 2004;118:946–950.