



Case report

A case of fatal trauma evaluated using a portable X-ray system at the scene

Youichi Yanagawa¹, Hiromichi Ohsaka¹, Yasumasa Oode¹, and Kazuhiko Omori¹

¹Department of Acute Critical Care Medicine, Shizuoka Hospital, Juntendo University, Japan

Abstract

Objective: To demonstrate the use of a portable X-ray system at the scene.

Patient: A 59-year-old man collapsed under a small power shovel and was discovered by his colleague. The fire department dispatched an ambulance and requested the dispatch of a doctor helicopter (DH) immediately after receiving the emergency call. When the staff of the DH used a portable X-ray system to assess the patient at the rendezvous point, he was found to have experienced a cardiac arrest with deformity of the face. Portable chest X-ray in the ambulance revealed decreased radiolucency of the lung fields without pneumothorax, and tracheal tube insertion was successful. Portable pelvic X-ray also showed no trauma. Portable cranial X-ray revealed orbital fracture. Although we urgently transported the patient to our hospital by the DH, he unfortunately died of circulatory arrest caused by his severe injuries. Based on the portable X-ray findings obtained at the scene, we suspected that the patient's cardiac arrest had been caused by severe head and/or neck injuries.

Conclusion: This portable X-ray system may be able to change and facilitate the management of patients with trauma dramatically by simplifying prehospital diagnoses even in rural areas.

Key words: portable X-ray, physician-staffed helicopter, prehospital

J Rural Med 2019; 14(2): 249–252

Introduction

Chest and pelvic imaging is currently recommended for the evaluation of all patients with blunt trauma who present with a concerning mechanism of injury¹. Chest X-ray is the most common imaging study performed in patients with blunt trauma².

FUJIFILM (Tokyo, Japan) developed a portable X-ray system called the CALNEO Xair[®] (https://fujifilm.jp/business/healthcare/digital_xray_imaging/dr04/calneo_xair/index.html). The X-ray apparatus weighs 3.5 kg and is 144 mm in height, 148 mm in length, and 258 mm in width, excluding the skin guard and hand strap. X-ray dose to the chest is approximately 45 μ Gy per scan. The system requires a

special cassette and notebook-type personal computer to operate and display X-ray images (Figure 1). The fully charged battery lasts for approximately 8 h on standby, but only a few hours when used continually without any re-charge.

Our hospital is the base of a physician-staffed helicopter (called a doctor helicopter [DH] in Japan) in eastern Shizuoka Prefecture, and the DH is dispatched to perform early medical interventions for patients with exogenous and endogenous diseases in the prehospital setting in rural areas³.

We herein report a case of fatal trauma that was evaluated using a portable X-ray system at the scene before transportation of the patient by the DH.

Case

A 59-year-old man was found by his colleague at their worksite (a plant) having collapsed under a small power shovel. The colleague immediately called an ambulance to rescue him at 08:25. The patient lived at home and had commuted to work at the plant. The fire department dispatched an ambulance and requested the dispatch of a DH immediately after receiving the emergency call. When emergency medical technicians (EMTs) examined him at 08:36, he had experienced cardiopulmonary arrest. His initial rhythm was asystole. He underwent insertion of a laryngeal tube with

Received: January 31, 2019

Accepted: April 9, 2019

Correspondence: Youichi Yanagawa, Department of Acute Critical Care Medicine, Shizuoka Hospital, Juntendo University, 1129 Nagaoaka, Izunokuni City, Shizuoka 410-2295, Japan

E-mail: yyanaga@juntendo.ac.jp

This is an open-access article distributed under the terms of the Creative Commons Attribution Non-Commercial No Derivatives

(by-nc-nd) License <<http://creativecommons.org/licenses/by-nc-nd/4.0/>>.






Figure 1 CALNEO Xair[®] developed by FUJIFILM (Tokyo, Japan). (1) Notebook-type personal computer, (2) X-ray irradiating apparatus, (3) Special cassette. The X-ray system is kept inside a warm firefighting conducting car.



Figure 2 The rendezvous point. The staff of the doctor helicopter with a portable X-ray system waiting for an ambulance at the rendezvous point.

mechanical ventilation and device-mediated automated chest compression by the EMTs. He was transported to the rendezvous point in an ambulance at 08:58 (Figure 2). When the staff of the DH checked the patient using a portable X-ray system in the ambulance at the rendezvous point, his electrocardiogram was still asystole, and his face seemed severely deformed. We promptly performed tracheal intubation and administered adrenaline into the trachea. Thoracotomy for direct cardiac massage was quickly performed to check for the presence of cardiac tamponade or tension pneumothorax. Neither of these critical conditions had occurred. The patient's heart did not recover macroscopically after thoracotomy. Abdominal ultrasound did not show fluid collection in the abdomen. Portable chest X-ray showed a bilateral decrease in the radiolucency of the lung fields without pneumothorax and successful tracheal tube insertion (Figure 3). Portable pelvic X-ray also showed no trauma (Figure 4). Portable cranial X-ray showed orbital fracture (Figure 5). It took a few minutes after setting up the device to confirm the X-ray images. The patient was then transferred from the ambulance to the DH at 09:25. While he was being transported by the DH to our hospital, cardiopulmonary resuscitation was continued. He underwent infusion of 1 mg of adrenaline 6 times every 4 min via the femoral venous sheath, and successful ventilation was achieved. However, he failed to obtain spontaneous circulation.

After arriving at our hospital at 09:43, we ceased resuscitation at 09:50. Post-mortem whole-body computed tomography revealed craniofacial bony fracture, acute cervical epidural hematoma, and bilateral lung edema, probably due to negative pressure pulmonary edema caused by upper airway obstruction.

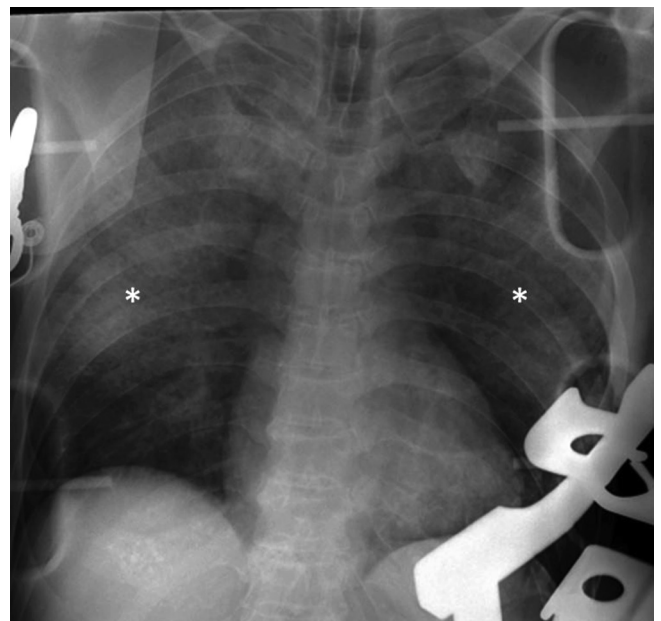


Figure 3 A portable chest X-ray image of the present case. Portable chest X-ray showed decreased radiolucency of both lung fields (*) without pneumothorax and successful tracheal intubation.

Discussion

Plain X-ray remains important for establishing medical diagnoses. Blunt chest injuries are common encounters in the emergency department. The majority of blunt chest injuries are minor contusions or abrasions; however, life-threatening injuries, including tension pneumothorax, hemothorax, aortic rupture, cardiac contusion, and blunt

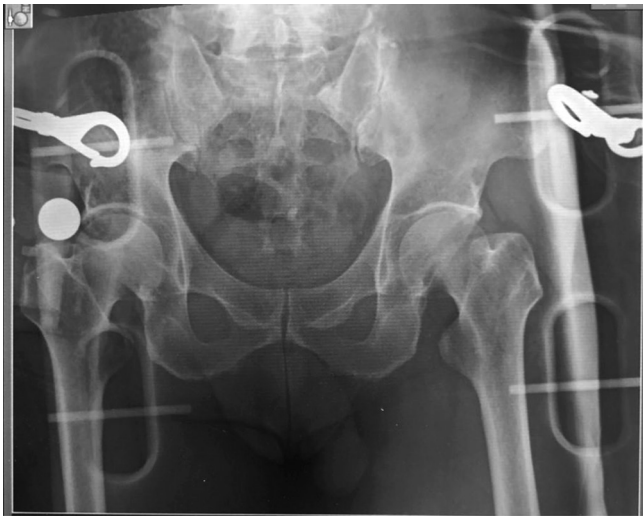

Figure 4 A portable pelvic X-ray image of the present case. The X-ray revealed no abnormalities.

diaphragmatic injury, can occur and must be recognized early^{4, 5}). Chest X-ray can provide diagnostic indications about such injuries. Meanwhile, severe pelvic trauma is a challenging condition. Injuries to the pelvis can cause multifocal hemorrhaging status that is not easily compressible nor managed by traditional surgical methods, such as tying off blood vessels or removing an organ⁶). Its treatment often requires the re-approximation of bony structures, damage control resuscitation, assessment for associated injuries, and triage of investigations, as well as multimodality hemorrhaging control (e.g., external fixation, preperitoneal packing, trans-catheter arterial embolization, and resuscitative endovascular balloon occlusion of the aorta by multidisciplinary trauma specialists). Pelvic X-ray can also provide information regarding severe pelvic fractures. Accordingly, the evaluation of the chest and pelvis using a portable X-ray system at the scene can facilitate proper anatomical triage during mass casualty events, proper prehospital treatment, and the selection of an appropriate medical facility for transport. Unfortunately, this patient did not survive. However, physicians who were dispatched to the scene were able to understand the severity of the patient's condition and identified the cause of his cardiac arrest. This system may aid in establishing prehospital medical diagnoses, guiding treatment, and facilitating changes to the management of patients with trauma.

There are several limitations associated with the use of this portable X-ray system in rural areas. First, the X-ray apparatus is not waterproof and so cannot be used during rainy weather or in wet areas. Second, the special cassette is not built to withstand particularly cold temperatures ($<7^{\circ}\text{C}$), so we had to use the X-ray system inside the warm ambulance during the winter. Third, as with traditional X-ray systems,

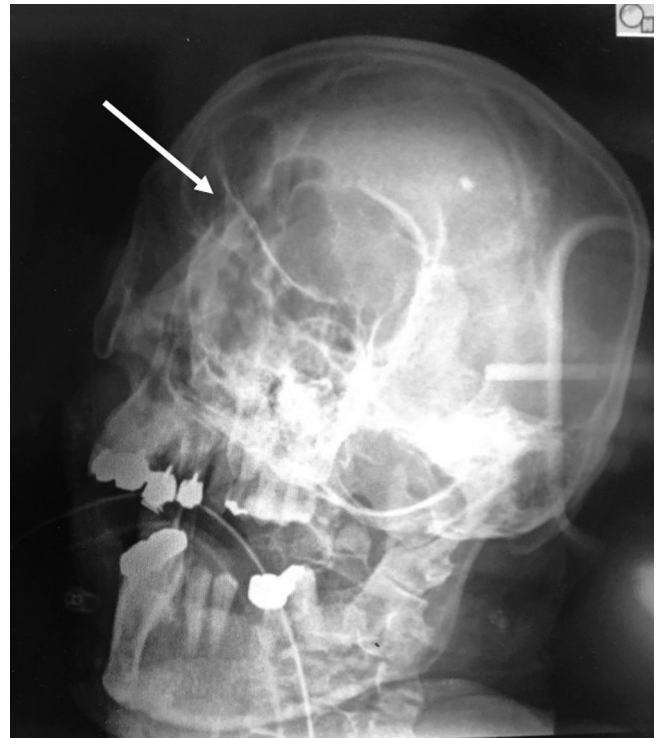


Figure 5 A portable cranial X-ray image of the present case. The X-ray showed left orbital fracture (arrow).

the examiner should be careful about undue radiation exposure in humans. Fourth, the interior of the DH is quite cramped, and a distance of at least 1 m between the subject and the X-ray apparatus is necessary for the examination, so X-ray studies cannot be performed in-flight. Therefore, after the further development of this system, future studies will need to assess the utility of this system.

Conclusion

We demonstrated the usefulness of a portable X-ray system before transportation in a DH. This system may help facilitate the management of patients with trauma by making prehospital diagnosis possible even in rural areas.

Conflicts of interest: The authors declare no conflicts of interest in association with this study.

Acknowledgements

The authors received financial support from the Ministry of Education, Culture, Sports, Science and Technology (MEXT)-Supported Program for the Strategic Research Foundation at Private Universities, 2015–2019 concerning “The constitution of total researching system for comprehensive disaster, medical management, corresponding to wide-scale disaster.”

References

1. American College of Surgeons Advanced Trauma Life Support for Doctors: Student Course Manual. 7. Chicago, American College of Surgeons; 2008.
2. Rodriguez RM, Langdorf MI, Nishijima D, *et al.* Derivation and validation of two decision instruments for selective chest CT in blunt trauma: a multicenter prospective observational study (NEXUS Chest CT). *PLoS Med* 2015; 12: e1001883. [[Medline](#)] [[CrossRef](#)]
3. Omori K, Ohsaka H, Ishikawa K, *et al.* Introduction of a physician-staffed helicopter emergency medical service in eastern Shizuoka prefecture in Japan. *Air Med J* 2014; 33: 292–295. [[Medline](#)] [[CrossRef](#)]
4. Morley EJ, Johnson S, Leibner E, *et al.* Emergency department evaluation and management of blunt chest and lung trauma (Trauma CME). *Emerg Med Pract* 2016; 18: 1–20. [[Medline](#)]
5. McGillicuddy D, Rosen P. Diagnostic dilemmas and current controversies in blunt chest trauma. *Emerg Med Clin North Am* 2007; 25: 695–711, viii–ix. [[Medline](#)] [[CrossRef](#)]
6. Skitch S, Engels PT. Acute management of the traumatically injured pelvis. *Emerg Med Clin North Am* 2018; 36: 161–179. [[Medline](#)] [[CrossRef](#)]