

# A Case of Novel Coronavirus Disease 19 in a Chronic Hemodialysis Patient Presenting with Gastroenteritis and Developing Severe Pulmonary Disease

Antoney J. Ferrey<sup>a-c</sup> Grace Choi<sup>a-c</sup> Ramy M. Hanna<sup>a-c</sup>  
Yongen Chang<sup>a-c</sup> Ekamol Tantisattamo<sup>a-c</sup> Kaushik Ivaturi<sup>a-c</sup>  
Elisa Park<sup>a-c</sup> Lawrence Nguyen<sup>a-c</sup> Brian Wang<sup>a-c</sup> Sam Tonthat<sup>a-c</sup>  
Connie M. Rhee<sup>a-d</sup> Uttam Reddy<sup>a-c</sup> Wei Ling Lau<sup>a-d</sup> Susan S. Huang<sup>e</sup>  
Shruti Gohil<sup>e</sup> Alpesh N. Amin<sup>f</sup> Lanny Hsieh<sup>h</sup> Timmy T. Cheng<sup>g</sup>  
Richard A. Lee<sup>g</sup> Kamyar Kalantar-Zadeh<sup>a-d, g</sup>

<sup>a</sup>Department of Medicine, Division of Nephrology, Hypertension and Kidney Transplantation, University of California Irvine Medical Center, Orange, CA, USA; <sup>b</sup>Harold Simmons Center for Kidney Disease Research and Epidemiology, University of California Irvine School of Medicine, Orange, CA, USA; <sup>c</sup>Division of Nephrology, Hypertension and Kidney Transplantation, Department of Medicine, University of California Irvine School of Medicine, Orange, CA, USA; <sup>d</sup>Department of Medicine, Nephrology Section, Tibor Rubin Veterans Affairs Long Beach Healthcare System, Long Beach, CA, USA; <sup>e</sup>Division of Infectious Diseases, University of California Irvine School of Medicine, Epidemiology and Infection Prevention Program, UC Irvine Health, Orange, CA, USA; <sup>f</sup>Department of Medicine, Hospitalist Program, University of California Irvine Medical Center, Orange, CA, USA; <sup>g</sup>Department of Medicine, Division of Pulmonology and Critical Care, University of California Irvine Medical Center, Orange, CA, USA; <sup>h</sup>Department of Medicine, Hospitalist Program and Division of Infectious Disease, University of California Irvine Medical Center, Orange, CA, USA

## Keywords

Novel coronavirus disease 19 · End-stage renal disease · Acute respiratory distress syndrome · Renin-angiotensin-aldosterone system blockade · Viral sepsis

## Abstract

Novel coronavirus disease 2019 (COVID-19) is a highly infectious, rapidly spreading viral disease with an alarming case fatality rate up to 5%. The risk factors for severe presentations are concentrated in patients with chronic kidney disease, particularly patients with end-stage renal disease (ESRD) who are dialysis dependent. We report the first US case of a 56-year-old nondiabetic male with ESRD secondary

to IgA nephropathy undergoing thrice-weekly maintenance hemodialysis for 3 years, who developed COVID-19 infection. He has hypertension controlled with angiotensin receptor blocker losartan 100 mg/day and coronary artery disease status-post stent placement. During the first 5 days of his febrile disease, he presented to an urgent care, 3 emergency rooms, 1 cardiology clinic, and 2 dialysis centers in California and Utah. During this interval, he reported nausea, vomiting, diarrhea, and low-grade fevers but was not suspected of COVID-19 infection until he developed respiratory symptoms and was admitted to the hospital. Imaging

A.J.F. and G.C. contributed equally to this work.

studies upon admission were consistent with bilateral interstitial pneumonia. He was placed in droplet-eye precautions while awaiting COVID-19 test results. Within the first 24 h, he deteriorated quickly and developed acute respiratory distress syndrome (ARDS), requiring intubation and increasing respiratory support. Losartan was withheld due to hypotension and septic shock. COVID-19 was reported positive on hospital day 3. He remained in critical condition being treated with hydroxychloroquine and tocilizumab in addition to the standard medical management for septic shock and ARDS. Our case is unique in its atypical initial presentation and highlights the importance of early testing.

© 2020 S. Karger AG, Basel

## Introduction

The novel coronavirus disease (COVID-19), also known as COVID-19 (and SARS-Cov2) by the World Health Organization, is a rapidly evolving pandemic [1]. It is believed that this virus evolved from an unknown species of bat at a Wuhan “wet” animal market in Southern China [2]. COVID-19 is estimated to have a case fatality rate of 2–3%, but a wide range of mortality rates between 0.2 and 8% has been reported, likely reflecting variable background implementation of public health interventions [3]. The outbreak is expected to infect a large portion of the world population [4], and a case fatality rate of 1–3% represents a significant mortality and healthcare burden [5]. The long-term pulmonary complications in individuals who recover from moderate and severe COVID-19 infections remain unclear [6].

A matter of great interest is the wide spectrum of COVID-19 symptomatology and disease manifestation, ranging from completely asymptomatic carriers [17] to critical respiratory failure, multiorgan dysfunction, and death. The severe presentations with often fatal outcomes have consistently been associated with several comorbidities including cardiovascular disease and advanced age [7]. There is likely an immunologic explanation, given our current understanding of weakened immune system in diabetics and individuals with advanced age. It is not clear whether dialysis-dependent patients with end-stage renal disease (ESRD) are at greater risk for severe disease manifestations and poorer outcomes. We present a case of COVID-19 in the United States in a long-term dialysis-dependent ESRD patient reported thus far in the 2020 COVID-19 pandemic.

## Case Report

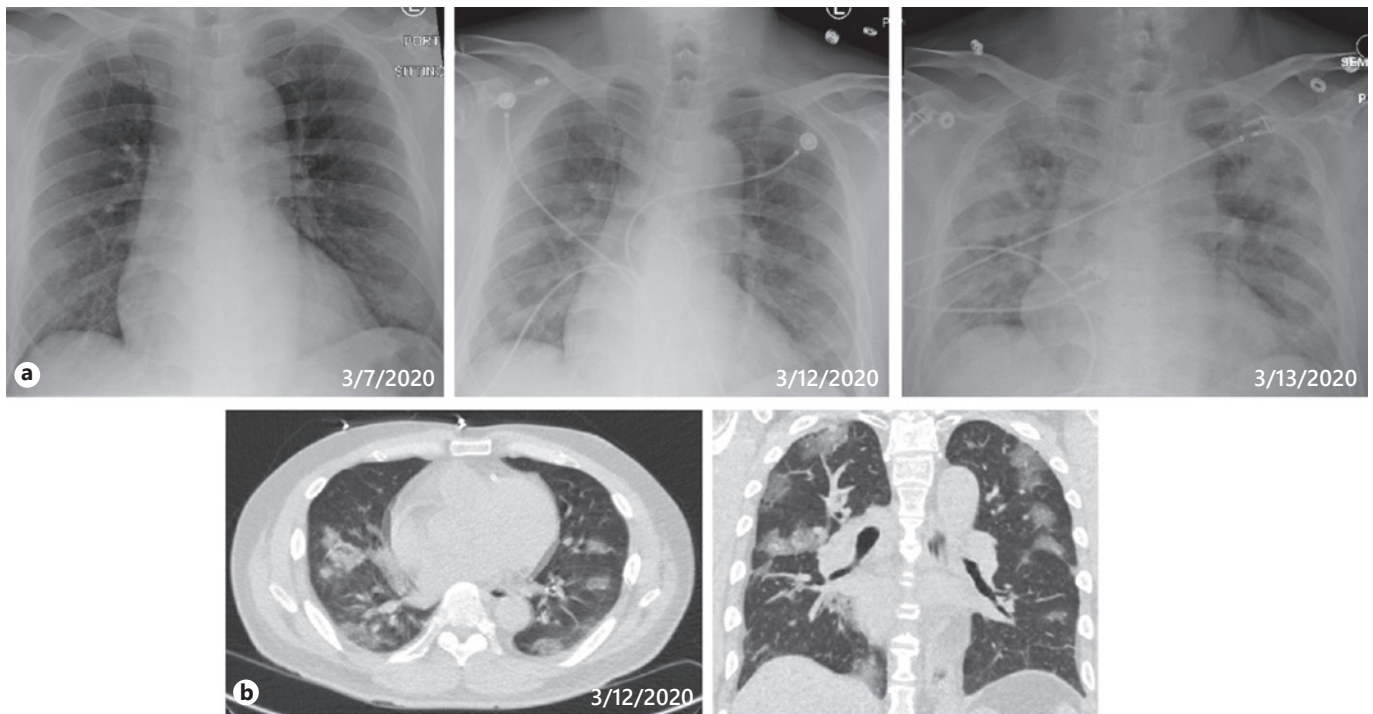
Our patient is a 56-year-old male with ESRD secondary to biopsy-proven IgA nephropathy on hemodialysis since late 2016. He has known coronary artery disease with ischemic cardiomyopathy, and he underwent percutaneous coronary intervention to left anterior descending and right coronary arteries shortly after initiation of dialysis. He had an improvement in his cardiac ejection fraction, from 44% in 2016 to 52% on optimal medical therapy. He was initiated on losartan at 25 mg daily when diagnosed with ischemic cardiomyopathy, which was increased to the maximum tolerated dose of 100 mg daily about 12 months prior to this admission. He is a working professional, remains active, and compliant to his prescribed medications and treatments. Up to this point, he has been actively listed for a renal transplant.

The patient had recently traveled to South Korea in early January 2020 and had returned to the United States by late January but before the surge of COVID-19 epidemic in Daegu, South Korea, was identified. He remained in good health without any notable symptoms until early March 2020.

Five days prior to his admission, he presented to a local urgent care for evaluation of nausea, vomiting, abdominal cramps, and subjective fevers; notably, he had no respiratory complaints. He was diagnosed with viral gastroenteritis, given recommendations for symptom management and discharged home. That same evening, he presented to our emergency department with similar complaints. He was noted to have a low-grade temperature to 100.2°F. His laboratory tests, including electrolytes, liver function tests, lactic acid, and blood counts, were unremarkable. His chest X-ray at that time showed no significant focal consolidation, but mild patchy increased interstitial markings at the bilateral lung bases were noted and described as possible atelectasis. His nausea improved while in the emergency department, and his symptoms were again attributed to a viral gastroenteritis from some “bad sushi” he had reported eating a day prior. Following discharge from the emergency department, he went home and noted that he was feeling better except that he had developed some loose stools.

Two days later, he attended his routine outpatient hemodialysis treatment, where he reported feeling better since discharge from the emergency department but continued to have intermittent loose stools approximately 2 times per day. He did not report cough or respiratory symptoms at that time. At the end of dialysis, he was noted to be febrile to 100.4°F and blood cultures were sent which showed no bacterial growth. He was seen in Cardiology clinic later that morning after dialysis treatment for an elective appointment, where he was noted to be coughing in the waiting room and given strict precautions, given his intent to travel for essential reasons.

The following day the patient traveled by commercial airline from Southern California to Utah where he presented to an emergency department for continued intermittent vomiting and fevers but was now reporting mild congestion and cough. A new chest X-ray at that time in Utah noted “mild interstitial prominence and vague infiltrate in the right lung base.” His influenza testing was reported negative, and he was prescribed azithromycin given the chest X-ray findings. The next day, he attended his scheduled hemodialysis as a transient visitor in a community dialysis facility in Utah where he reported fever and malaise but was eager to return to California given his acute sickness. He returned to Southern California that evening earlier than planned using commercial air-



**Fig. 1.** Imaging demonstrating progression of interstitial pneumonitis due to COVID-19 resulting in ARDS. **a** Chest X-ray sequence with interval increasing patchy opacities in both lungs consistent with evolving infectious process. **b** Chest CT showing new multifocal bilateral patchy groundglass opacities with a predominantly peripheral distribution. There is mild bibasal septal and centrilobular thickening. No evidence of pleural effusion or pneumotho-

rax. There are small biapical subpleural blebs and mild centrilobular pulmonary emphysema in the upper lobes. No evidence of atelectasis. These findings are more consistent with atypical pneumonia which may be secondary to viral infection. Please correlate clinically. Differential considerations include pulmonary edema.

line, because he was feeling quite ill with continued fevers and gastrointestinal symptoms. Furthermore, his respiratory symptoms, which were initially minimal, had progressed rapidly and he was becoming more short-of-breath.

Shortly after returning to Southern California, he presented to our emergency department for further reevaluation. In the ED, a repeat chest X-ray (Fig. 1) demonstrated subtle patchy opacities in both lungs, new from prior X-ray 5 days ago. A CT (Fig. 1) of the chest revealed multifocal bilateral patchy ground glass opacities predominantly with peripheral distribution concerning for atypical pneumonia and possibly viral infection. COVID-19 testing was performed, the result of which was expected 48 h later, along with standard chemistry and hematology labs, which again revealed no abnormalities with the exception of an elevated procalcitonin level. An evaluation for other causes of atypical pneumonia was simultaneously sent, without additional findings thus far.

He was admitted to the hospital on droplet – eye precautions. Initially, he was noted to have a temperature of 100.6°F, but with otherwise normal vital signs. He was initiated on antimicrobial therapy with ceftriaxone and azithromycin. Over the next 24 h, he was febrile to 101°F and respiratory status rapidly deteriorated. His repeat chest X-rays demonstrated evolution of the bilateral multifocal opacities consistent with the atypical pneumonia, and there was concern for superimposed pulmonary edema. He underwent

dialysis the evening of hospital day 2; he tolerated the treatment poorly, developing new atrial fibrillation with rapid ventricular rate despite only minimal ultrafiltration. His respiratory condition continued to rapidly decline during the night, and he had to be intubated and transferred to the intensive care unit (ICU) for acute hypoxic respiratory failure and shock. His pulmonary condition continued to deteriorate to acute respiratory distress syndrome (ARDS) requiring continued mechanical ventilation with high PEEP >10 cm and FiO<sub>2</sub> >60% as well as pressor support. In an effort to maintain close control of his volume status and metabolic parameters, we have initiated him on continuous veno-venous hemodiafiltration. In the setting of ESRD, he has been deemed not a candidate for *remdesivir* compassionate use trial and was started on hydroxychloroquine and on hospital day 6 he was started on tocilizumab given continued hemodynamic instability with elevated inflammatory markers including interleukin (IL)-6. With the inability to rule out superimposed infection he has also been on broad-spectrum antibiotic coverage with vancomycin and piperacillin-tazobactam since hospital day 6. His clinical course is being followed closely by a multispecialist team, and depending on his trajectory, he may require paralysis as well as more aggressive pulmonary and hemodynamic support with proning and extracorporeal membrane oxygenation. At the current time, his vasopressor requirement remains variable, as does his PaO<sub>2</sub>/FiO<sub>2</sub> ratio, while

**Table 1.** Timeline of ESRD patient with COVID-19 presentation

Date	Location	Facility	Symptoms
1–13 Jan 2020	South Korea	N/A	None
24 Feb 2020	Southern California	Dialysis center	None
4 Mar 2020	Southern California	Dialysis center	None
7 Mar 2020 a.m.	Southern California	ER 1	Nausea, vomiting, subjective fever
7 Mar 2020 p.m.	Southern California	ER 2*	Nausea, vomiting, fever
9 Mar 2020 a.m.	Southern California	Dialysis center	Fever, diarrhea/loose stools
9 Mar 2020 a.m.	Southern California	Outpatient clinic	Cough, fever
10 Mar 2020 a.m.	Utah	ER 3	Cough, congestion, nausea, fever
11 Mar 2020 a.m.	Utah	Dialysis center	Cough, congestion, nausea, fever
12 Mar 2020 a.m.	Southern California	ER 2* inpatient	Cough, congestion, SOB, fever, nausea, myalgias
13 Mar 2020 p.m.	Southern California	Inpatient	Hypoxic respiratory failure Atrial fibrillation with RVR
14 Mar 2020 a.m.	Southern California	Intensive care unit	ARDS; shock

\* Patients visited “ER 2” twice including upon hospital admission.

ESRD, end-stage renal disease; COVID-19, novel coronavirus disease 2019; N/A, not applicable.

he remains in critical condition for the past 5 days. Table 1 summarizes timeline. Figure 1 shows chest X-ray and CT scans demonstrating interstitial pneumonitis due to COVID 19.

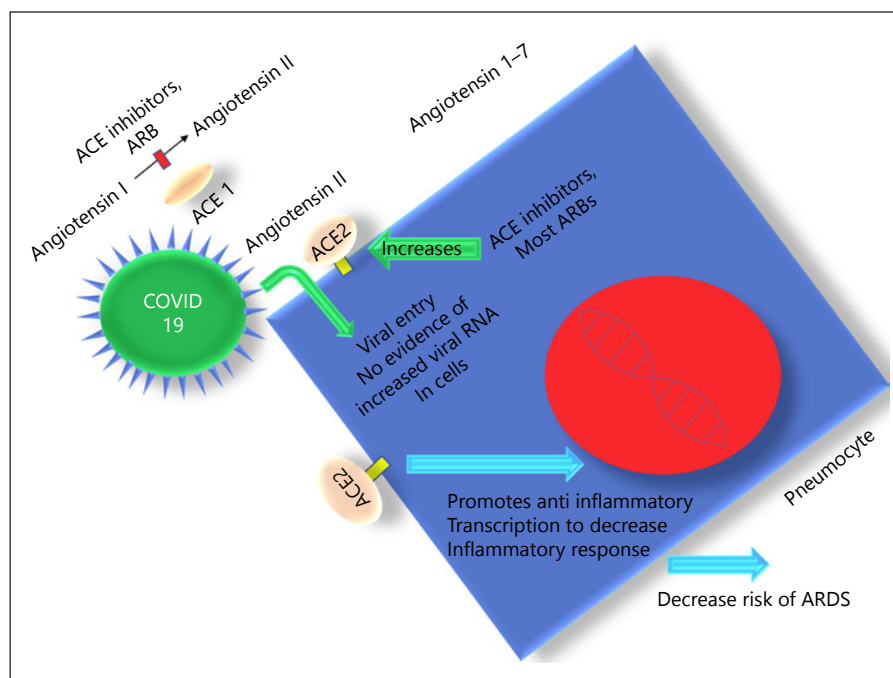
## Discussion

COVID-19 infection is a rapidly developing field, and we should expect more infected dialysis patients’ case reports and analyses. In a recent research letter by Arentz et al. [8], clinical characteristics of 21 patients including 2 long-term dialysis admitted to an ICU in Washington State were described. A unique feature of our reported case is the potentially long incubation period, assuming this patient contracted the infection in South Korea in early January 2020, which was 6 weeks prior to the first presentation, but we cannot be certain. Alternatively he could be one of the first community spread cases identified in southern California. The delayed diagnosis for the first 5 days was likely because it was not recognized by the treating centers that gastrointestinal manifestation may be a part of COVID-19 infection. Our reported dialysis-dependent patient is notably healthier and younger than the average dialysis patients in the United States and without diabetes but with a history of hypertension and cardiac disease. Yet, he developed ARDS and has required ventilatory support. This case report highlights the importance of considering COVID-19 infection in a variety of clinical presentation that may not initially include typical respiratory symptom to prevent ongoing exposure of potentially affected individuals to the general population. It also highlights the need for rapidly available testing for all patients

who present to healthcare setting with even nonsevere and atypical symptoms. This patient with community spread disease traveled from Southern California to Utah for 2 days using public airports, commercial flights, and public transportation, potential exposures which could have been avoided if testing supplies and public health recommendations would have been different. The consequences of this exposure remain unclear, but the United States has since had a rapidly increasing number of cases.

The gastrointestinal presentation our patient is somewhat unusual and delayed initiation of COVID-19 diagnostic workup by 5 days. Notably, however, the first case of COVID-19 infection confirmed in the United States reported a 2-day history of nausea and vomiting on admission followed by loose stools on hospital day 2 [9], and COVID-19 viral nucleic acids of loose stool and respiratory specimens were reported positive. In a recent report from Hubei, China, 204 COVID-19-infected patients were studied, and the authors reported that digestive symptoms are not uncommon in patients with COVID-19 [10]. Patients who presented with gastrointestinal symptoms had a longer time from onset to admission, evidence of longer coagulation, and higher liver enzyme levels. Hence, clinicians including nephrologists should recognize that digestive symptoms, such as diarrhea, may be among the presenting features of COVID-19 infection, and that the index of suspicion may need to be raised earlier in at-risk patients presenting with digestive symptoms [10].

COVID-19 is a challenge to the existing health systems due to its novelty, rapidity of spread, asymptomatic shedding, variable manifestations, and poor outcomes in multimorbid or elderly persons [3]. The mortality rate is cur-



**Fig. 2.** The complex interplay between Angiotensin Receptor 2 and Renin-angiotensin-aldosterone system blockade in pneumocytes. ACE, angiotensin-converting enzyme; ARB, angiotensin receptor blockers; ARDS, acute respiratory distress syndrome; COVID-19, novel coronavirus 2019; DNA, deoxyribonucleic acid.

rently estimated to be between 10 and 30 times as lethal as influenza, though as the incidence of the disease rises this may change [5]. This pandemic has resulted in a massive effort worldwide to quarantine suspected individuals and isolate the affected patients, unparalleled in modern history. The plan to “flatten the curve” is presumed only way our health system is expected to cope with the crisis by reducing demand for hospital and ICU beds [11].

The reason for higher incidence and mortality of COVID-19 infection in individuals with several comorbidities including cardiovascular disease is still unknown [7]. Prior studies suggested that angiotensin-converting enzyme 2 (ACE2)-binding capacity is strongly associated with coronavirus infectivity and disease severity. ACE2 may be differentially upregulated by ACEi, ARB, and aldosterone antagonists [12–14]. It is postulated that the expression of ACE2 may be increased with the use of ACEi, ARB, and aldosterone antagonists, particularly in diabetic patients, and therefore it has been suggested that increased expression of ACE2 may facilitate infection by COVID-19. It is important to note, however, that higher ACE2 levels have been shown to have a protective effect against acute lung injury and reduce progression of lung injury to ARDS in animal studies. As a result, there are ongoing investigations for ACE2 as potential new therapy for inflammatory lung disease [15]. ACE2 has been noted to decrease with age, and COVID-19 has consistently demonstrated higher mortality and morbidity in the older population. Figure 2

shows the pathophysiological interplay between viral entry and lung physiology centered around ACE2.

Currently, treatment has increasingly centered around 3 agents including chloroquine-based agents like hydroxychloroquine [16]. These antimalarial agents have shown potent antiviral activity in vitro, especially hydroxychloroquine [16]. Lopinavir-ritonavir is also being used clinically [17]; however, whereas an emerging agent for COVID-19 infection is remdesivir [18], unfortunately patients with ESRD are excluded from current trials. Tocilizumab is an antagonist of the IL-6 receptor an agent that has been used to treat cytokine-release syndrome a severe but anticipated toxicity with CAR-T-cell therapy in different malignancies. Similarly in severe infections with hyperinflammation immunosuppression may improve survival, and there are preliminary reports from China regarding patients with elevated IL-6 levels and COVID-19 pneumonia. Given clinical deterioration in our patient and concern for hyperinflammation with elevated IL-6 levels, we have started tocilizumab.

While working on treatment for severely ill patient, this pandemic has required and continues to require broad attention of public health official to implement social distancing to mitigate the rapid spread of this highly contagious and potentially life-threatening novel virus. Vaccine development is anticipated but may take time and if successful will help establish herd immunity to protect the noninfected population at large.

As the scientific and medical community faces the unknown surge of COVID-19, some of our most vulnerable populations are already gathered for routine treatments in limited space; for example, infusion centers and dialysis centers placing them at great risk for exposure. The importance of rapid use of clinical publication data is paramount to making progress and spreading innovation. We have reported one of the first patients with ESRD undergoing hemodialysis with COVID-19 infection. This scenario presents various epidemiological challenges as far as containing infectious spread in a dialysis unit. This scenario also suggests that home dialysis maybe a protective intervention in the face of such a rapidly infectious pandemic.

### Acknowledgment

We acknowledge dedicated healthcare professionals at University of California Irvine Medical Center including nurses and staff in critical care units for their hard work and support for this and other critically ill patients.

### Statement of Ethics

This research work does not contain human subject research material.

### References

- 1 He F, Deng Y, Li W. Coronavirus Disease 2019 (COVID-19): what we know? *J Med Virol*. 2020, Epub ahead of print.
- 2 Rothan HA, Byrareddy SN. The epidemiology and pathogenesis of coronavirus disease (COVID-19) outbreak. *J Autoimmun*. 2020, Epub ahead of print.
- 3 Cascella M, Rajnik M, Cuomo A, Dulebohn SC, Di Napoli R. Features, Evaluation and Treatment Coronavirus (COVID-19). *StatPearls Treasure Island*; 2020.
- 4 Chen X, Yu B. First two months of the 2019 Coronavirus Disease (COVID-19) epidemic in China: real-time surveillance and evaluation with a second derivative model. *Glob Health Res Policy*. 2020 Mar;5:7.
- 5 Wilson N, Kvalsvig A, Barnard LT, Baker MG. Case-Fatality Risk Estimates for COVID-19 Calculated by Using a Lag Time for Fatality. *Emerg Infect Dis*. 2020 Mar 13;26(6).
- 6 Zhou S, Wang Y, Zhu T, Xia L. CT Features of Coronavirus Disease 2019 (COVID-19) Pneumonia in 62 Patients in Wuhan, China. *AJR Am J Roentgenol*. 2020, Epub ahead of print.
- 7 Ruan Q, Yang K, Wang W, Jiang L, Song J. Clinical predictors of mortality due to COVID-19 based on an analysis of data of 150 patients from Wuhan, China. *Intensive Care Med*. 2020, Epub ahead of print.
- 8 Arentz M, Yim E, Klaff L, Lokhandwala S, Riedo FX, Chong M, et al. Characteristics and Outcomes of 21 Critically Ill Patients With COVID-19 in Washington State. *JAMA*. 2020, Epub ahead of print.
- 9 Holshue ML, DeBolt C, Lindquist S, Lofy KH, Wiesman J, Bruce H, et al.; Washington State 2019-nCoV Case Investigation Team. First Case of 2019 Novel Coronavirus in the United States. *N Engl J Med*. 2020, Epub ahead of print.
- 10 Pan L, Mu M, Yang P, Sun Y, Wang R, Yan J, et al. Clinical characteristics of COVID-19 patients with digestive symptoms in Hubei, China: a descriptive, cross-sectional, multicenter study *Am J Gastroenterol*. 2020, Epub ahead of print.
- 11 Fisher D, Heymann D. Q&A: The novel coronavirus outbreak causing COVID-19. *BMC Med*. 2020 Feb;18(1):57.
- 12 Naicker S, Yang CW, Hwang SJ, Liu BC, Chen JH, Jha V. The Novel Coronavirus 2019 Epidemic and Kidneys. *Kidney Int*. 2020, Epub ahead of print.
- 13 Xie X, Chen J, Wang X, Zhang F, Liu Y. Age- and gender-related difference of ACE2 expression in rat lung. *Life Sci*. 2006 Apr;78(19):2166–71.
- 14 Bernardi S, Michelli A, Zuolo G, Candido R, Fabris B. Update on RAAS Modulation for the Treatment of Diabetic Cardiovascular Disease. *J Diabetes Res*. 2016;2016:8917578.
- 15 Li Y, Zeng Z, Cao Y, Liu Y, Ping F, Liang M, et al. Angiotensin-converting enzyme 2 prevents lipopolysaccharide-induced rat acute lung injury via suppressing the ERK1/2 and NF- $\kappa$ B signaling pathways. *Sci Rep*. 2016 Jun;6(1):27911.
- 16 Colson P, Rolain JM, Lagier JC, Brouqui P, Raoult D. Chloroquine and hydroxychloroquine as available weapons to fight COVID-19. *Int J Antimicrob Agents*. 2020 Mar;105932.
- 17 Young BE, Ong SWX, Kalimuddin S, Low JG, Tan SY, Loh J, et al.; Singapore 2019 Novel Coronavirus Outbreak Research Team. Epidemiologic Features and Clinical Course of Patients Infected With SARS-CoV-2 in Singapore. *JAMA*. 2020, Epub ahead of print.
- 18 Dong L, Hu S, Gao J. Discovering drugs to treat coronavirus disease 2019 (COVID-19). *Drug Discov Ther*. 2020;14(1):58–60.

### Disclosure Statement

The authors have no conflicts of interest to disclose.

### Funding Sources

K.K.-Z. is supported by the National Institutes of Health-National Institute of Diabetes, Digestive and Kidney Disease grant K24-DK091419 as well as philanthropist grants from Mr. Harold Simmons, Mr. Louis Chang, Dr. Joseph Lee, and AVEO.

C.M.R. is supported by research grants from the National Institutes of Health/National Institutes of Diabetes and Digestive and Kidney Diseases K23-DK102903, R03-DK114642, and R01-DK122767 and philanthropist grants from Dr. Joseph Lee.

### Ethical Permission/Consent for Publication

Written consent for publication has been obtained by the immediate family members of the patient.

### Availability of Data and Materials

Not applicable, no data.

### Sponsorship

This work was not sponsored.