

Contents lists available at [ScienceDirect](https://www.sciencedirect.com)

American Journal of Ophthalmology Case Reports

journal homepage: www.ajocasereports.com/

A unique case of Paracentral Acute Middle Maculopathy with associated cystoid macular oedema post uncomplicated pterygium surgery

Waseem Henein^{a,b,c,*}, Ario Wilson-Pogmore^{a,b}, Fraser Imrie^a

^a Department of Ophthalmology, Gold Coast University Hospital, Southport, Queensland, 4215, Australia

^b Discipline of Clinical Ophthalmology and Eye Health, University of Sydney, Camperdown, New South Wales, 2016, Australia

^c Bond University School of Medicine, Bond University, Robina, Queensland, 4226, Australia

ARTICLE INFO

Keywords:

Paracentral acute middle maculopathy
Cystoid macular oedema
Pterygium surgery

ABSTRACT

Purpose: To present a unique and unusual case of Paracentral Acute Middle Maculopathy (PAMM) with associated cystoid macular oedema (CMO) following ocular surface surgery in a low risk patient.

Observations: This observational case report describes the presentation of a single case of Paracentral Acute Middle Maculopathy following pterygium surgery. The patient harboured no risk factors and underwent uncomplicated pterygium surgery with no perioperative complications. Post-operatively the patient demonstrated marked visual acuity loss to count fingers only to the operated eye. Optical Coherence Tomography demonstrated hyper-reflective band-like lesions affecting the middle layers of the retina, pathognomonic for PAMM. Unusually, cystoid macular oedema was also evident. He was managed on topical and oral therapy, with limited visual recovery.

Conclusions and importance: We report a rare and unique case of PAMM with associated cystoid macular oedema occurring in a patient deemed low risk following pterygium surgery resulting in significant permanent visual loss. To our knowledge, this is the first reported incidence of PAMM following ocular surface surgery.

1. Introduction

Paracentral Acute Middle Maculopathy (PAMM) is a recently described Optical Coherence Tomography (OCT) finding characterized acutely by hyper-reflective, band-like lesions affecting the middle layers of the retina at the junction of the Inner Nuclear Layer (INL) and Outer Plexiform Layer (OPL).^{1,2} The pathophysiology is hypothesized as secondary to Intermediate (ICP) and Deep Capillary Plexus (DCP) ischaemia. It is often identified in patients with systemic or retinal vascular pathologies including retinal artery or vein occlusions, diabetic retinopathy, hypertensive retinopathy and Purtscher's retinopathy.^{2,3} The legacy of PAMM ultimately results in atrophy of the INL resulting in a permanent central scotoma.¹ We report a unique case of PAMM with associated cystoid macular oedema (CMO) identified on OCT post uncomplicated pterygium surgery, in a low risk patient, presenting with central scotoma and severe vision loss.

2. Case

A 73-year-old Caucasian male presented with a left pterygium measuring 4mm from limbus to apex causing 6 dioptres of corneal astigmatism. His past ocular history included uncomplicated right pterygium surgery twenty-years prior. Past medical history only included dyslipidemia managed with a statin. Pre-operatively best corrected visual acuity (BCVA) was excellent at 6/6 in both eyes.

He underwent pterygium excision with superior conjunctival autograft under subtenon's anaesthesia (5mL of 50:50 mixture of ropivocaine 1% and lignocaine 2%). There was no adrenaline in the anaesthetic mixture and no pre-operative compression with Honan's balloon. No ocular or systemic complications were identified perioperatively and surgery was completed uneventfully.

At routine one-week post-operative review, the patient reported significant loss of central vision in the operated eye, with BCVA of counting fingers at 1 m, not improving with pinhole. His corneal epithelial defect was healing, and the conjunctival graft was securely placed. There was a mild left relative afferent pupil defect. Posterior pole

* Corresponding author. Department of Ophthalmology, Gold Coast University Hospital, Southport, Queensland, 4215, Australia.

E-mail addresses: waseem.henein@gmail.com, waseem.henein@health.qld.gov.au (W. Henein), Aawp86@gmail.com (A. Wilson-Pogmore), Fraser.imrie@health.qld.gov.au (F. Imrie).

<https://doi.org/10.1016/j.ajoc.2020.100925>

Received 27 May 2019; Accepted 9 September 2020

Available online 23 September 2020

2451-9936/Crown Copyright © 2020 Published by Elsevier Inc.

This is an open access article under the CC BY-NC-ND license

(<http://creativecommons.org/licenses/by-nc-nd/4.0/>).

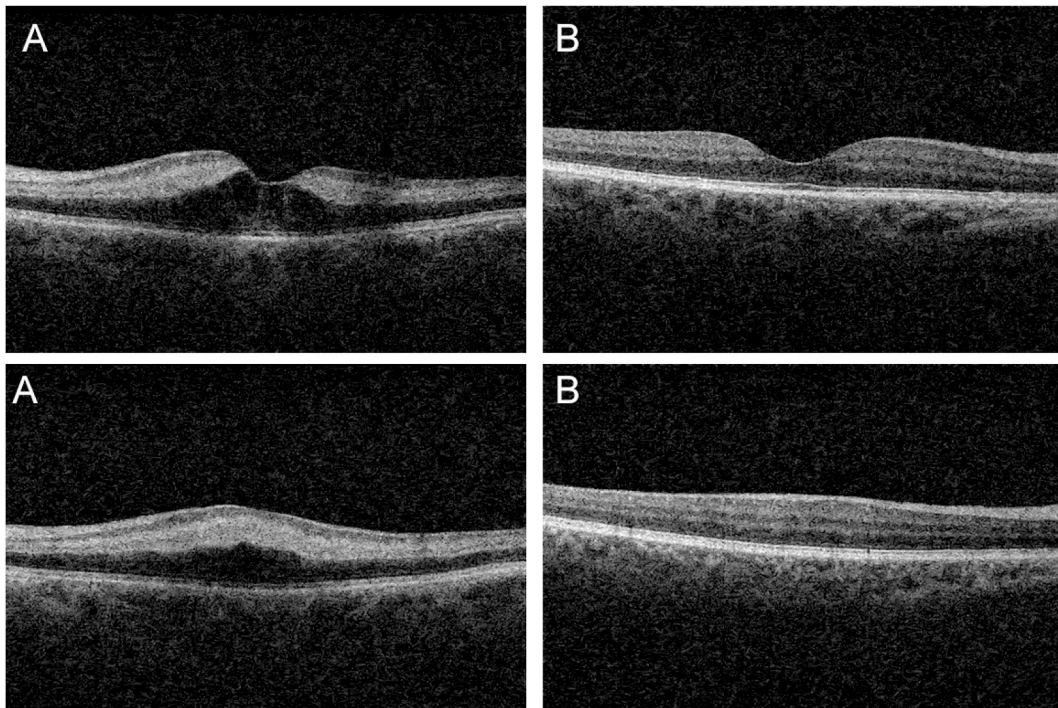


Fig. 1. Optical Coherence Tomography at 1-week post-operative review A) Left eye demonstrating cystoid macular oedema and associated hyper-reflectivity of the inner nuclear and outer plexiform layers pathognomonic for Paracentral Acute Middle Maculopathy at fovea & superior to fovea. B) Right eye demonstrating normal macula.

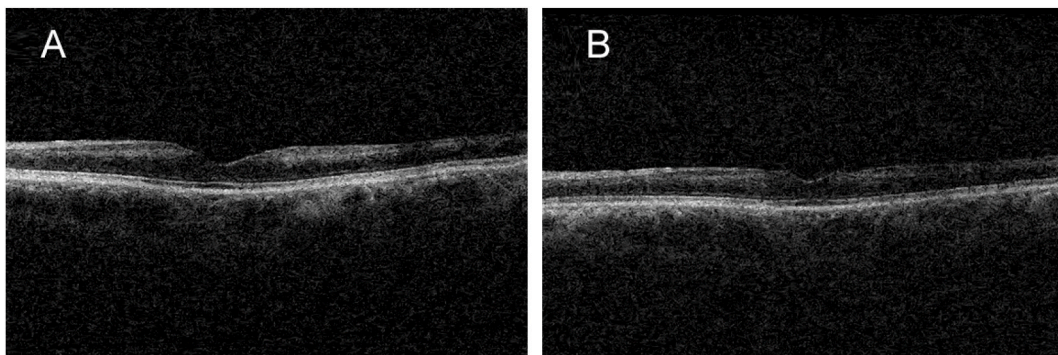


Fig. 2. Optical Coherence Tomography of the left eye A) 3 weeks post-operative review demonstrating resolution of CMO, ongoing hyper-reflectivity of middle retinal layers B) 6 month review demonstrating atrophy of middle retinal layers.

examination demonstrated mild perifoveal pallor. No emboli were identified. OCT demonstrated hyper-reflectivity and thickening of the middle retinal layers consistent with PAMM. Unusually, there was also significant CMO (See Fig. 1). Fundus fluorescein angiography was performed which demonstrated no vascular occlusion or leak. The patient was treated as PAMM, with associated post-operative inflammatory CMO and prescribed oral prednisolone 25mg daily in addition to prednisolone acetate 1% (prednefrin forte) and ketorolac (Acular) eye drops. Cardiovascular workup, including carotid doppler ultrasound, were unremarkable. He was commenced on Aspirin as secondary prophylaxis for presumed ischaemic pathology.

Follow-up OCT 3 weeks post-operatively demonstrated resolution of the CMO but ongoing increased reflectivity from the middle retinal layers (see Fig. 2A). Review six months later demonstrated atrophy of the middle retinal layers on OCT (see Fig. 2B) with vision unchanged at count fingers.

3. Discussion

Paracentral Acute Middle Maculopathy is a clinical finding first reported in 2013 by Sarraf et al. as a possible superficial variant of Acute Macular Neuroretinopathy.⁴ Despite similarities, PAMM is now widely accepted as an independent abnormality with distinct differences including demographics and pathophysiology.² PAMM is commonly identified in males in the fifth to sixth decade of life, and can often herald underlying associated systemic or retinal vascular diseases warranting further investigation.² PAMM is primarily identifiable on OCT demonstrating pathognomonic hyperreflective band-like lesions at the INL and OPL of the retina.¹ Similar to management of central retinal artery occlusion (CRAO), the treatment of PAMM is to address underlying vascular risk factors. Visual recovery is prognostically poor with atrophy of the middle retinal layers resulting in permanent visual deficits.¹

PAMM has recently been implicated in severe vision loss post cataract surgery by phacoemulsification in a case series by Creese et al.¹ The

exact pathogenesis remains unclear, however it has been hypothesized that postoperative retinal ischaemia may be secondary to spasm or occlusion of the central retinal artery due to either: mechanical compression from sub-tenon's anaesthesia; or vasoconstriction if adrenaline is used in anaesthetic mixture.¹ Honan's balloon has been considered a potential contributing factor as it further raises IOP.¹ Lack of documented retinal ischaemic events post ocular surgery with use of topical anaesthesia supports this hypothesis.¹

Our patient harboured no significant risk factors for ischaemia, and no adrenaline or mechanical compressive devices were utilized intra-operatively. The post-operative findings in our case of combined CMO with underlying typical features of PAMM is unusual and we postulate this presentation was due to an element of inflammation of the peri-foveal capillaries in addition to ischaemia.

To the best of our knowledge, this is the first reported case of PAMM with associated CMO following pterygium surgery. To date, there has only been one reported case of PAMM occurring post pterygium, however this was in the context of associated CRAO.⁵ Our case highlights the need to consider PAMM even in low risk patients with significant vision loss post ocular surgery and aims to document an unusual case of PAMM presenting with associated CMO.

Patient Consent

- The patient has consented to publication of the case both written and orally.

Acknowledgement and disclosures

- No funding or grant support

Authorship

- All authors attest that they meet the current ICMJE criteria for Authorship

Declaration of competing interest

- The following authors have no financial disclosures: WH, AW, FI

Acknowledgements

None

References

1. Creese K, Ong D, Sandhu S, et al. Paracentral acute middle maculopathy as a finding in patients with severe vision loss following phacoemulsification cataract surgery. *Clin Exp Ophthalmol*. 2017;45(6):598–605.
2. Rahimy E, Kuehlewein L, Satta S, Sarraf D. Paracentral acute middle maculopathy. *Retina*. 2015;35(10):1921–1930.
3. Dansingani K, Freund K. Paracentral acute middle maculopathy and acute macular Neuroretinopathy: related and distinct entities. *Am J Ophthalmol*. 2015;160(1):1–3. e2.
4. Sarraf D, Rahimy E, Fawzi A, et al. Paracentral acute middle maculopathy. *JAMA Ophthalmol*. 2013;131(10):1275.
5. O'Day R, Harper C, Wickremasinghe S. Central retinal artery occlusion showing features of paracentral acute middle maculopathy following uncomplicated pterygium surgery. *Clin Exp Ophthalmol*. 2018.