

Pathology of autoimmune hepatitis

Claudia Covelli¹,  Diana Sacchi²,  Samantha Sarcognato²,  Nora Cazzagon³,  Federica Grillo⁴,
Francesca Baciocchi², Daniela Fanni⁵, Matilde Cacciatore², Valeria Maffei²,  Maria Guido^{2,6}

¹ Pathology Unit, Fondazione IRCCS Casa Sollievo della Sofferenza, San Giovanni Rotondo, Italy; ² Pathology Department Azienda ULSS 2 Marca Trevigiana, Treviso, Italy; ³ Department of Surgery, Oncology and Gastroenterology, University of Padova, Padova, Italy; ⁴ Unit of Anatomic Pathology, Department of Surgical Sciences and Integrated Diagnostics (DISC), University of Genova and Ospedale Policlinico San Martino IRCCS, Genoa, Italy; ⁵ Pathology Unit, Department of Medical Sciences, University of Cagliari, Cagliari, Italy; ⁶ Department of Medicine-DIMED, University of Padova, Padova, Italy

Summary

Autoimmune hepatitis (AIH) is a relatively rare non-resolving chronic liver disease, which mainly affects women. It is characterized by hypergammaglobulinemia, circulating autoantibodies, interface hepatitis on liver histology and a favourable response to immunosuppression. The putative mechanism for the development of autoimmune hepatitis is thought to be the interaction between genetic predisposition, environmental triggers and failure of the native immune system.

AIH still remains a major diagnostic and therapeutic challenge, mainly because it is a very heterogeneous disease. Prompt and timely diagnosis is crucial since, if left untreated, AIH has a high mortality rate. Histological demonstration of hepatitis is required for the diagnosis of AIH and, therefore, liver biopsy is mandatory in the initial diagnostic work-up, before treatment. In this review, we summarize the histological features of AIH with the main aim of highlighting the most important clinical-pathological hallmarks useful in the routine diagnostic practice.

Key words: autoimmune hepatitis, histology, liver biopsy, interface hepatitis

Introduction

Autoimmune hepatitis (AIH) is a chronic progressive liver disease of unknown etiology. The pathogenesis of AIH is complex and involves interactions between tolerant liver, environmental triggers, and dysregulated immunological mechanisms. Genetic factors influence an individual's susceptibility to developing AIH ^{1,2}.

Originally considered a disease of young women, AIH may also occur in children and the elderly (about 30% of cases occur over 60 years of age). Both sexes (about 30% are males) and all ethnic groups are involved, and recent epidemiological studies indicate an increasing trend in AIH prevalence worldwide, especially in men ³. If untreated, AIH leads to cirrhosis and associated complications, with a small (1-2% per year) but significant risk of hepatocellular carcinoma development ^{4,5}. Characteristic laboratory features include hypergammaglobulinemia, with elevation of immunoglobulin G (IgG) in the majority of cases, and presence of non-organ specific autoantibodies ⁶.

Diagnosis is often challenging, since no single feature is reliable. Therefore, careful clinical-pathological integration is required for the exclusion of other causes of liver disease and a confident diagnosis of AIH. An early diagnosis is, however, critical for timely initiation of life-saving immunosuppressive therapy.

Received and accepted: December 14, 2020

Correspondence

Claudia Covelli
Fondazione IRCCS Casa Sollievo della Sofferenza, 71013, San Giovanni Rotondo, Italy
Tel.: +39 0882 835505
Fax: +39 0882 410411
E-mail: cla.covelli85@gmail.com

Conflict of interest

The Authors declare no conflict of interest.

How to cite this article: Covelli C, Sacchi D, Sarcognato S, et al. Pathology of autoimmune hepatitis. *Pathologica* 2021;113:185-193. <https://doi.org/10.32074/1591-951X-241>

© Copyright by Società Italiana di Anatomia Patologica e Citopatologia Diagnostica, Divisione Italiana della International Academy of Pathology



OPEN ACCESS

This is an open access journal distributed in accordance with the CC-BY-NC-ND (Creative Commons Attribution-NonCommercial-NoDerivatives 4.0 International) license: the work can be used by mentioning the author and the license, but only for non-commercial purposes and only in the original version. For further information: <https://creativecommons.org/licenses/by-nc-nd/4.0/deed.en>

Current guidelines recommend liver biopsy as a prerequisite for the diagnosis of AIH¹. Liver biopsy is also useful for treatment management, to determine disease severity and distinguish acute vs. chronic presentation.

This review focuses on the current role of liver biopsy and describes characteristic histological lesions which contribute to AIH diagnosis.

Overview on laboratory and clinical features

Liver function tests typically show a hepatocellular pattern of injury, with an increase in aminotransferases, that can be mildly elevated or up to 50 times the upper normal value. Alanine aminotransferase (ALT) is typically higher than Aspartate aminotransferase (AST). Cholestatic enzymes are usually normal or mildly elevated unless there is an overlap with primary biliary cholangitis (PBC) or primary sclerosing cholangitis (PSC)⁷⁻¹³. Increase in serum globulins (serum γ -globulin or IgG level) is evident in 90% of patients. This prevalence seems to be lower in patients with an acute onset, among which a proportion of cases, ranging from 25 to 39%, has normal IgG levels^{14,15}. IgA and IgM are usually normal, and their increased levels should prompt the exclusion of different etiologies, such as alcoholic steatohepatitis and PBC, respectively¹.

Circulating autoantibodies are considered the hallmark of AIH and have been used to subclassify AIH into type 1, or classic autoimmune hepatitis, and type 2. Type 1 AIH is defined by the presence of antinuclear antibody (ANA) and/or anti-smooth muscle antibody (ASMA). Antibody titers more than 1:40 are considered significant in adults. Type 2 AIH is less common and mainly affects pediatric patients. It is characterized by the presence of antibodies against liver/kidney microsomes (LKM1) and/or liver cytosol antigen (LC1). The validity of such subclassification in clinical practice has been questioned¹. Autoantibodies may not be detected, particularly in cases of severe acute presentation (autoantibody negative AIH)¹⁶. Noteworthy, is that the presence of autoantibodies always needs careful interpretation, as they can be found in healthy patients as well as in other, non-autoimmune, hepatopathies. In asymptomatic blood donors, ANA prevalence of any titer has been found to vary between 4% and 26%, with nearly 15% of cases positive at a 1:40 dilution, and up to 10% of pregnant women are ANA positive¹⁷⁻¹⁹. ANA are found in approximately 5% of individuals with HCV, showing titers more than 1:100²⁰. The presence of autoantibodies is common

also in patients with Non-alcoholic fatty liver disease (NAFLD): in a multicenter study in United States, significant titers of autoantibodies were detectable in 21% of adult NAFLD patients, with no association with advanced histological features or presence of steatohepatitis²¹.

The spectrum of clinical presentation of AIH ranges from asymptomatic elevation of serum liver enzymes, to fulminant hepatitis. The most common clinical presentation is characterized by a slow disease onset and progression with non-specific complaints such as fatigue and malaise, which explains why AIH is in advanced stages of fibrosis at the time of diagnosis in around a third of patients. Acute onset of AIH occurs in about one third of patients. It may represent an acute exacerbation of unrecognized AIH with pathological evidence of chronic hepatitis or a genuine newly developed acute AIH, without previous clinical-pathological findings of chronic liver disease. Acute onset is clinically indistinguishable from acute hepatitis of other causes²²⁻²⁴. Moreover, in some of these patients, IgG levels may be within the normal range and ANA and/or SMA may be negative at the first screening^{10,25-28}, thus leading to a challenging diagnosis.

The role of liver biopsy in AIH

Liver biopsy is recommended by the American Association for the Study of Liver diseases (AASLD) and the European Association for the Study of the Liver (EASL) guidelines to help establish the diagnosis, exclude other causes of liver disease, and guide treatment choice^{1,26}.

The diagnostic criteria for AIH have been codified in 1993, revised in 1999 by the International Autoimmune Hepatitis Group (IAHG)^{7,8} and more recently simplified for clinical use (Table I)⁹. In the simplified system, as in the previous ones, liver histology is included among the parameters required to confirm clinical diagnosis of AIH. Indeed, the system comprises four parameters: autoantibodies, serum IgG, results of viral hepatitis work-up and AIH histology, which is coded as absent, typical or compatible (Table II).

Once a diagnosis of AIH is made, liver biopsy is the gold standard for grading and staging AIH and provides crucial information for patient management and treatment decisions²⁹. Persistence of any degree of inflammation, particularly interface hepatitis, and presence of plasma cells in biopsy samples taken under treatment, are strong predictors of AIH-relapse if immunosuppression is stopped.

Liver biopsy is particularly important for the differential diagnosis of AIH, as it may lead to an alternative

Table I. Simplified diagnostic criteria for autoimmune hepatitis (from Hennes et al., 2009, adapt.)⁹.

Feature	Cutoff	Points
ANA or SMA	≥ 1:40	1
ANA or SMA	≥ 1:80	2*
or LKM	≥ 1:40	
or SLA	Positive	
IgG	> Upper normal limit	1
	> 1.10 times upper normal limit	2
Liver histology (evidence of hepatitis is a necessary condition)	Compatible with AIH	1
	Typical AIH	2
Absence of viral hepatitis	Yes	2

Interpretation of aggregated scores: ≥ 6: probable AIH; ≥ 7: definite AIH

*Addition of points achieved for all autoantibodies (maximum, 2 points).

ANA, Antinuclear antibody; SMA, smooth muscle antibody; LKM, liver-kidney microsomal antibody; SLA/LP, soluble liver antigen/liver pancreas antibody, AIH, autoimmune hepatitis.

Table II. Histological categories for grading histology in the simplified system for autoimmune hepatitis (from Hennes et al., 2009, adapt.)⁹.

Histological Categories	Morphological features
Typical for AIH	Interface hepatitis, with lymphocytic/lymphoplasmocytic infiltrate in portal tracts extending into the lobule Emperipolesis Hepatic rosette formation (All three features have to be present)
Compatible with AIH	Chronic hepatitis pattern of injury with lymphocytic infiltration Lack of all the features considered typical
Atypical for AIH	Signs suggestive of other diagnosis

AIH, Autoimmune hepatitis.

etiology³⁰. Moreover, it may identify possible concurrent disorders, especially fatty liver disease, considering the epidemic proportion of risk factors for the metabolic syndrome. Finally, liver biopsy is considered mandatory in cases of AIH with overlapping features of autoimmune biliary disorders. Liver biopsy at presentation should be performed prior to beginning treatment since immunosuppression may rapidly clear inflammation on liver biopsy, with the risk of a “false negative” diagnosis.

Histopathology of AIH

Despite the pivotal role of liver biopsy for diagnosis, no morphological feature is pathognomonic of AIH. However, there is a characteristic picture in many patients before treatment. The typical aspect of AIH is that of a severe chronic hepatitis with intense portal and lobular inflammation, severe interface hepatitis, and much hepatocyte damage.

Portal inflammation is composed of mononuclear cells, mainly lymphocytes, with a variable amount of plasma cells. Some eosinophils and neutrophils may be seen (Fig. 1). Plasma cells are considered typical for AIH, but they are neither sufficient nor necessary to

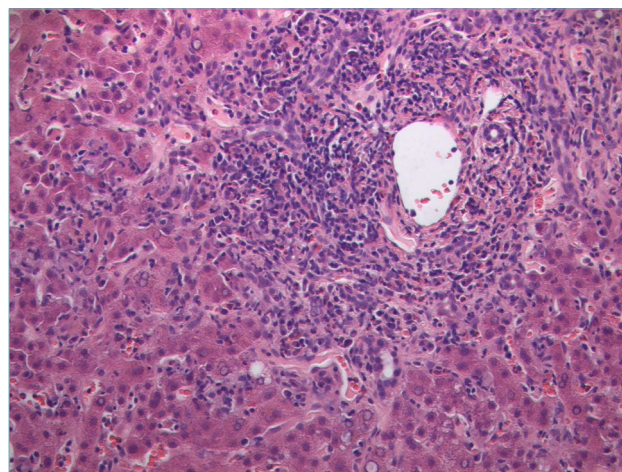


Figure 1. Severe portal inflammation, mainly composed of lymphocytes, and interface hepatitis. Several necro-inflammatory foci are visible in the adjacent lobular parenchyma (H&E; original magnification 40x).

make a diagnosis since they are rare/absent in about one third of cases. However, detection of plasma cells in clusters (Fig. 2) is highly suggestive of AIH. In a recent critical appraisal concerning the histological

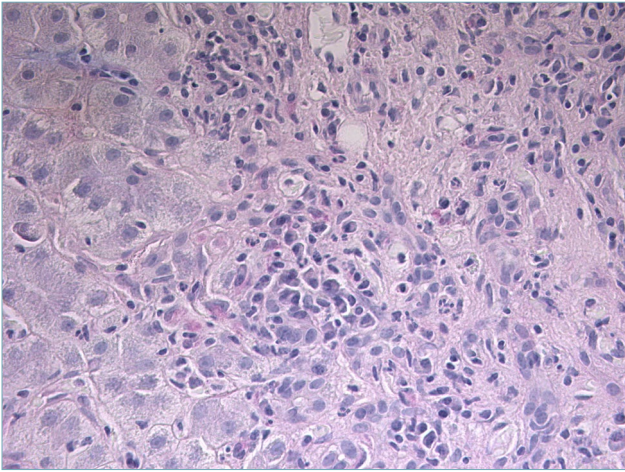


Figure 2. A cluster of plasma cells is visible close to the portal tract (H&E; original magnification 40x).

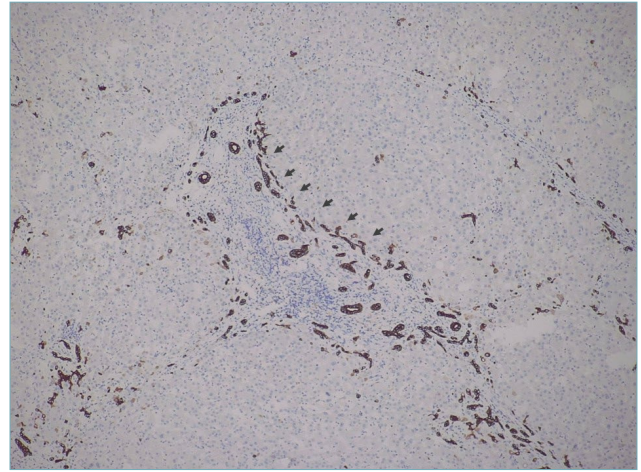


Figure 4. Ductular reaction (arrows) around an inflamed portal tract (immunostain for CK7; original magnification 20x).

features of AIH³¹, the presence of plasma cell clusters (defined as a collection of ≥ 5 plasma cells) in the lobule was the most sensitive diagnostic finding. Immunohistochemical stains for multiple myeloma-1 (MUM-1) or CD38 may help to highlight number and distribution pattern of plasma cells (Fig. 3)³².

Although not specific, *interface hepatitis* is considered the hallmark of AIH. It is characterized by the extension of portal inflammation beyond the limiting plate into the adjacent lobule with damage and progressive loss of hepatocytes at the portal-lobular interface (Fig. 1). It is observed in up to 98% of AIH and is usu-

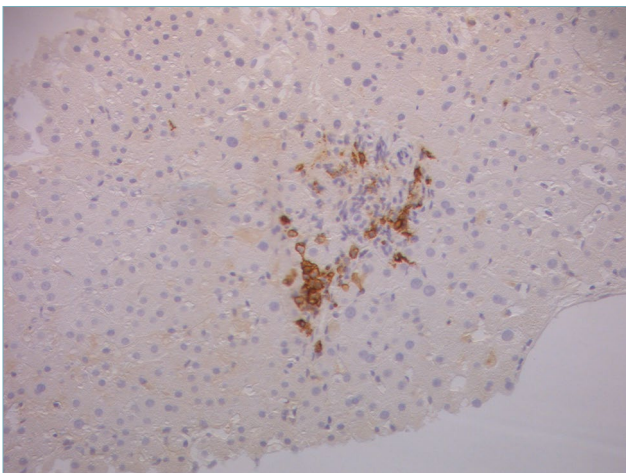


Figure 3. Immunostain with CD38 helps in identifying a cluster of plasma cells. This is a pediatric case with mild portal inflammation within an otherwise typical clinical presentation (original magnification 20x).

ally more prominent compared to interface hepatitis of other causes³³. According to the 2008 simplified criteria, the presence of interface hepatitis, even in the absence of all the other typical features, is in agreement with the diagnosis of AIH⁹.

Severe portal and interface hepatitis are usually associated with *ductular reaction* (DR). It consists of bile ductules with poorly defined lumina at the portal-parenchymal interface, arranged in anastomosing cords, and lined by small CK7-positive cells (Fig. 4). Ductular reaction is a regenerative phenomenon, which represents proliferation and bidirectional differentiation of facultative hepatic stem cells in a variety of acute and chronic liver diseases. In AIH, DR correlates with the severity of portal-periportal inflammation, as in other liver diseases³⁴.

Lobular changes are dominated by necro-inflammatory damage, ranging from spotty to confluent necrosis. Apoptotic bodies are commonly seen. Multiple necro-inflammatory foci may be associated with hepatocyte ballooning and sinusoidal inflammation, giving the appearance of lobular disarray (Fig. 5) which resembles what is seen in patients with acute viral hepatitis. Bridging necrosis (portal to portal and portal to central) is not uncommon and may represent the deep extension of interface hepatitis into the lobules. Confluent necrosis and inflammation may be seen in perivenular areas. In most cases, it is associated with the typical portal peri-portal inflammation. However, there are few patients affected by AIH in whom the major feature at presentation is the isolated centrilobular necro-inflammation, with spared portal tract (Fig. 6). This is thought to be an early feature of AIH that precedes overt portal-dominant (classic)

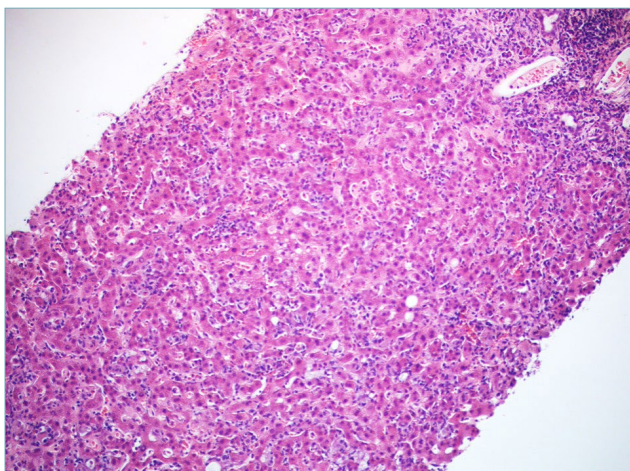


Figure 5. Several foci of “spotty” necrosis, giving the appearance of lobular disarray (H&E; original magnification 20x).

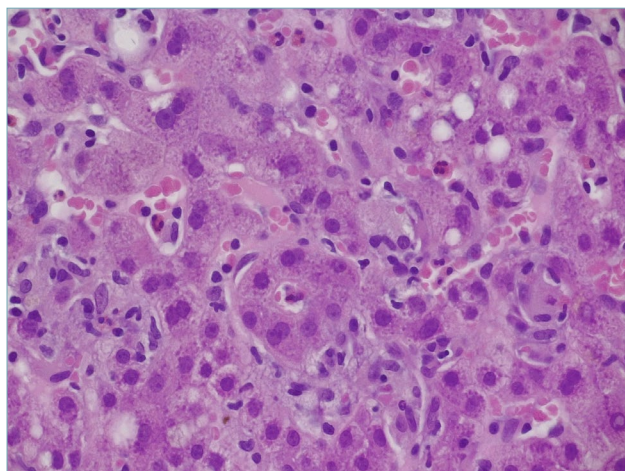


Figure 7. Typical hepatocyte rosette, representing a regenerative phenomenon in a heavily inflamed liver (H&E; original magnification 60x).

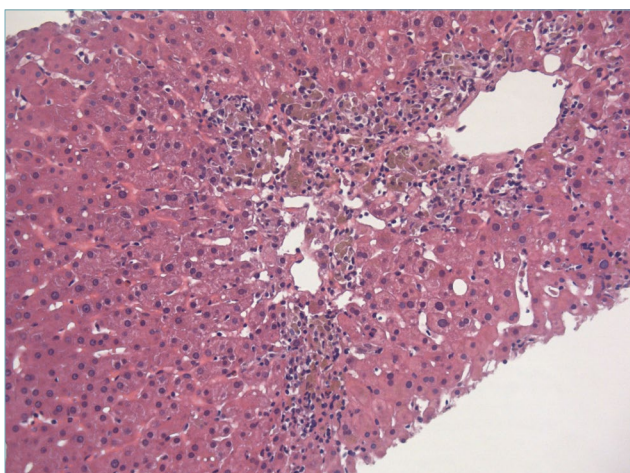


Figure 6. Centrilobular necro-inflammation in a case of true acute AIH presentation. Portal tracts were completely spared in this case. Toxic damage is the main differential diagnosis (H&E; original magnification 40x).

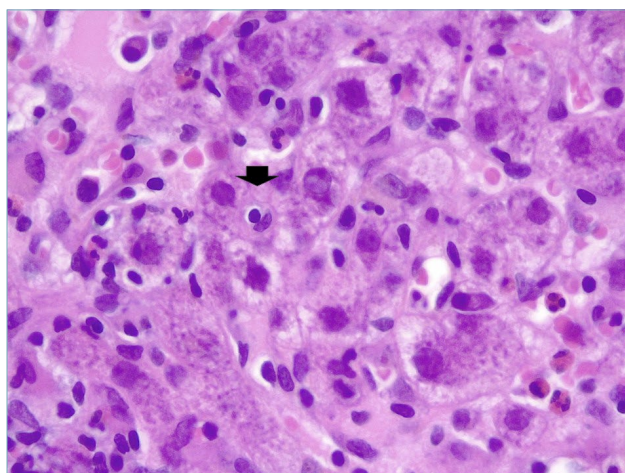


Figure 8. Emperipolesis (arrow) appears as a lymphocyte within the hepatocyte cytoplasm (H&E; original magnification 60x).

AIH³⁵. Indeed, this pattern of necrosis is commonly seen in patients with acute disease onset³⁶. In rare cases, a massive-panlobular necrosis may occur, leading to liver failure.

Much emphasis has been given to the presence of *rosettes* (Fig. 7) and *emperipolesis* (Fig. 8) as classic changes of AIH. Indeed, they have been considered as typical histological AIH-features in the 2008 simplified scoring system for adults and they are a required item to get score 2 (Tab. II)⁹. Rosettes are defined as hepatocytes arranged around a central lumen and

represent a regenerative response to the necro-inflammatory damage. Emperipolesis is characterized by the presence of a mononucleated inflammatory cell (lymphocyte or plasma cell) within the cytoplasm of hepatocytes and it is reported in 65-78% of AIH cases. Emperipolesis and rosette formation have been considered better histological predictors of AIH, when compared to plasma cells and interface hepatitis³⁷. However, such superiority is still controversial and it has been shown that emperipolesis is associated with the severity of activity rather than the etiology³⁸. Moreover, emperipolesis is difficult to be reliably as-

essed in routine practice with light microscopy, and it is best evaluated by electron microscopy.

Bile duct injury can be identified in up to 83% of AIH patients^{34,39,40}, often in a PBC-like pattern, even after the exclusion of an overlap syndrome. Therefore, some degree of biliary involvement in AIH does not necessarily lead to a change in diagnosis! A major problem is that how much bile duct damage is diagnostic of biliary disease is still not established. In routine practice, it is reasonable to suggest a possible concomitant biliary disease when bile duct damage is seen in the majority of portal tracts. The bile ducts are not the target of damage in AIH, and probably their inflammatory damage represents collateral injury of the conspicuous inflammatory process, as demonstrated by their subsiding after immunosuppressive therapy³⁴. Therefore, an evident bile duct destruction (ductopenia) is not a feature of AIH and warrants consideration of primary biliary cholangitis. Moreover, copper-associated protein accumulation and/or CK7-positive periportal hepatocytes are recognized features of chronic cholestasis and their presence should prompt to consider an alternative diagnosis or an overlap condition. It is noteworthy to highlight that these features of chronic cholestasis no longer have their diagnostic value when severe fibrosis or cirrhosis is present. In such cases, nonspecific copper-associated protein accumulation and CK7 positivity can be seen, notwithstanding the etiology. The practical value of taking in consideration results of copper-associated protein and CK7 stains in the histological features has been evaluated in a recent study⁴¹. In this study, histological criteria codified in the 2008 simplified score proposed by the IAHG (Tab. II) were reviewed and new parameters were proposed. The new criteria (Tab. III) were based on interface/lobular inflammatory activity, number of plasma cells, biliary features, and copper-as-

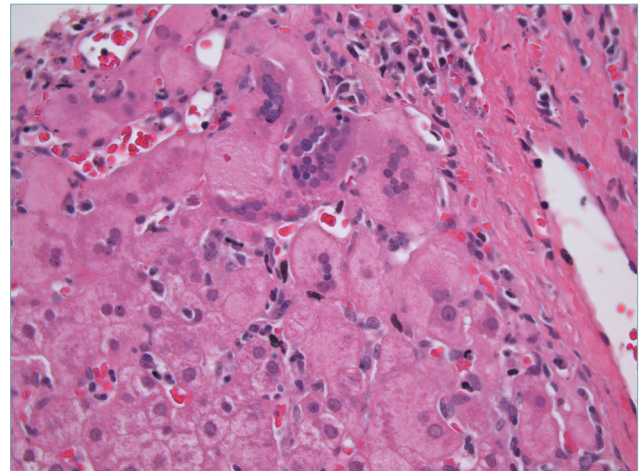


Figure 9. Giant cell transformation in autoimmune hepatitis (H&E; original magnification 40x).

sociated protein/CK7 stains, and demonstrated higher sensitivity for the diagnosis of AIH. These results should be validated in prospective series.

Cholestasis is usually not observed in AIH, but a mild degree may be seen in cases with marked lobular inflammation.

Giant cell transformation may be rarely seen in adults with AIH (Fig. 9). This represents an unusual regenerative or degenerative hepatocyte reaction to various injuries, and it is a common response in the newborn liver diseases. Post infantile giant cell hepatitis is a rare, non-specific subtype of hepatitis, which can be seen in a wide variety of inflammatory and cholestatic liver diseases, among which AIH represents the most common cause⁴².

Recently, PAS positive-diastase resistant *hyaline droplets in Kupffer cells*, resembling Russell bodies of

Table III. Proposed criteria for the histologic scoring of autoimmune hepatitis (from Balitzer et al., 2017, adapt.)⁴¹.

Histologic score	Morphological features
Score 0	Features not observed in AIH (e.g. florid duct lesion, bile duct loss, or copper/CK7 positivity, if applicable*)
Score 1**	1. Hepatitis with mild or moderate necro-inflammatory activity, with any of the following: (a) Ishak A2 (mild/moderate interface activity) (b) Ishak B1 (focal confluent necrosis) (c) Ishak C2 (2-4 foci of lobular activity x 10) 2. CK7 and copper stains negative (if applicable*)
Score 2	Hepatic pattern with any of the following: 1. Plasma cells numerous or in clusters 2. High necroinflammatory activity with at least one of the following: (a) Ishak score A3 or higher (at least moderate interface activity) (b) Ishak B2 or higher (confluent necrosis in zone 3 or beyond) (c) Ishak C3 or higher (5 or more foci of lobular activity x 10)

*Applicable only in cases without any bridging fibrosis.

**Both 1 and 2 are necessary for histologic score 1, except in cases with acute presentation.

AIH, Autoimmune hepatitis.

plasma cells, have been described as specific feature in AIH⁴³. However, little information is known on this and, therefore, it is still controversial to consider this feature as a reliable histological sign of AIH.

Histological grading and staging

Since no specific grading and staging systems for AIH have been developed, grading of the inflammatory activity and staging of the fibrosis can be performed borrowing the systems used for chronic viral hepatitis such as the Scheuer⁴⁴, Ishak⁴⁵, and Metavir⁴⁶ systems. This is reasonable since both chronic viral hepatitis and AIH have a similar pattern of necro-inflammatory damage and share the morphogenesis of fibrosis. The choice of grading/staging system is arbitrary and depends on the pathologist's preference and tradition, and on agreement with the local hepatologists. As in viral hepatitis, it is important to clearly specify the name of the used system in the final histological report, without which the scores lose their significance. Patients often consult different clinicians; therefore, this information is crucial for a proper interpretation of the histological report.

Grading and staging have prognostic and therapeutic implications and are required, since ALT values do not properly correlate with the disease severity and non-invasive tests for the assessment of fibrosis have not been fully validated in AIH¹.

According to EASL guidelines, treatment withdrawal is considered when biochemical remission is reached, but it requires histological remission, defined as normal histology or minimal hepatitis (Hepatitis Activity Index score/HAI < 4 or equivalent)¹.

Differential diagnosis

Since the pattern of injury and typical features of AIH are non-specific, the spectrum of histological differential diagnosis is very broad and an accurate integration with all clinical and laboratory features is required to reach a correct diagnosis.

VIRAL HEPATITIS

All acute and chronic viral hepatitis can appear similar to AIH and neither plasma cells nor the other histological findings, which are more typically seen in AIH, are sensitive or specific enough. However, viral infection can be easily excluded by serological testing which are mandatory in all patients in whom a diagnosis of AIH is considered. A special attention should be paid to hepatitis E virus (HEV), since non-specific autoan-

tibodies associated to AIH are frequently found during acute HEV infection. Clinicians and pathologists should be aware of this and always exclude HEV infection before diagnosing and treating AIH, as immunosuppression can lead to chronic HEV disease⁴⁷. A broad and highly variable spectrum, related to the clinical context, of histopathological findings can be observed in livers of patients infected with HEV, making the histopathological diagnosis very challenging⁴⁸. Immunohistochemistry for HEV pORF2 protein is a helpful histopathological tool⁴⁹.

DRUG INDUCED LIVER INJURY

Drug induced liver injury (DILI) represents the most challenging differential diagnosis, not only because it can mimic the clinical, biochemical, serological and morphological phenotype of AIH (AIH-like-DILI), but also because drugs may trigger latent or induce a *de novo* AIH⁵⁰⁻⁵³. The distinction between DILI and AIH by histology can be extremely difficult (sometimes impossible), due to the absence of histological features pathognomonic of either DILI or AIH. Severe portal plasma cell-rich inflammation, prominent intralobular plasmacells and eosinophils, rosette formation, absence of cholestasis and presence of fibrosis have been suggested as features that are in favor of the diagnosis of AIH⁵⁴. The absence of cirrhosis, or advanced fibrosis, at presentation mainly suggests AIH-like DILI. A detailed clinical information is crucial, and the patient's history should focus on recent exposure to drugs that can induce AIH-DILI. Fortunately, AIH-DILI usually responds to high doses of steroids as severe AIH usually does, but differently from true AIH that always relapses, steroid treatment can be discontinued without a DILI relapse¹.

PRIMARY BILIARY CHOLANGITIS

Differential diagnosis between AIH and classical PBC is not difficult. PBC is a chronic cholestatic syndrome showing a distinctive serological profile of positive antimitochondrial antibodies (AMAs), often associated with intense pruritus. Increase in serum IgM and alkaline phosphatase (ALP) levels with a normal or slightly elevated bilirubin level and only a mild elevation of ALT is typically observed at earlier stages. PBC may show moderate to severe portal inflammatory infiltrate with many plasma cells and even interface hepatitis, but prominent florid duct lesions and bile duct loss (not seen in AIH) are typically found in liver biopsies. Moreover, PBC does not show a hepatitic pattern of lobular injury, which is common in AIH. AMA-negative PBC may occur in about 10% of cases, but the histological scenario does not differ from the typical AMA-positive PBC. As already highlighted, stains for copper-asso-

ciated protein and/or CK7 may be useful to recognize signs of chronic cholestasis in early stage disease⁴¹. Diagnosis of AIH-PBC overlap is discussed in another review in this special issue of *Pathologica*.

WILSON'S DISEASE

Wilson's disease can show similar (or even identical) histologic findings to AIH and should always be considered among the differential diagnoses, particularly in younger patients. In most cases, it can be excluded based on serum ceruloplasmin levels and 24-hour urine copper. Rhodanin stain for copper detection in liver biopsy may be useful (bearing in mind that it can be negative even in Wilson disease, particularly in early stages)⁵⁵.

Conclusions

Liver biopsy is crucial for the establishment of a definite AIH diagnosis and it is recommended by the current guidelines at the time of presentation, to support the diagnosis and provide information about disease severity. Histology of AIH is typical in most cases (i.e. presence of interface hepatitis, plasma cell predominance in the portal inflammatory infiltrate, regenerative rosettes and emperipolesis), but it is considered in agreement with the possible AIH diagnosis when at least interface hepatitis is observed. Different conditions may mimic AIH at histology. Therefore, pathologists require all clinical and laboratory data, as well as imaging, which have to be provided by hepatologists. Once more, the most important aspect for an optimal patient management is communication between clinician and pathologist.

References

- European Association for the Study of the Liver. EASL Clinical Practice Guidelines: autoimmune hepatitis. *J Hepatol* 2015;63:971-1004. <https://doi.org/10.1016/j.jhep.2015.06.030>. Erratum in *J Hepatol* 2015;63:1543-1544.
- Assis DN. Immunopathogenesis of autoimmune hepatitis. *Clin Liver Dis (Hoboken)* 2020;15:129-132. <https://doi.org/10.1002/cld.873>
- Tanaka A. Autoimmune hepatitis: 2019 update. *Gut Liver* 2020;14:430-438. <https://doi.org/10.5009/gnl19261>
- Yeoman AD, Al-Chalabi T, Karani JB, et al. Evaluation of risk factors in the development of hepatocellular carcinoma in autoimmune hepatitis: implications for follow-up and screening. *Hepatology* 2008;48:863-870. <https://doi.org/10.1002/hep.22432>
- Wong RJ, Gish R, Frederick T, et al. Development of hepatocellular carcinoma in autoimmune hepatitis patients: a case series. *Dig Dis Sci* 2011;56:578-585. <https://doi.org/10.1007/s10620-010-1444-6>
- Czaja AJ. Diagnosis and management of autoimmune hepatitis. *Clin Liver Dis* 2015;19:57-79. <https://doi.org/10.1016/j.cld.2014.09.004>
- Johnson PJ, McFarlane IG. Meeting report: International Autoimmune Hepatitis Group. *Hepatology* 1993;18:998-1005. <https://doi.org/10.1002/hep.1840180435>
- Alvarez F, Berg PA, Bianchi FB, et al. International Autoimmune Hepatitis Group Report: review of criteria for diagnosis of autoimmune hepatitis. *J Hepatol* 1999;31:929-938. [https://doi.org/10.1016/s0168-8278\(99\)80297-9](https://doi.org/10.1016/s0168-8278(99)80297-9)
- Hennes EM, Zeniya M, Czaja AJ, et al. Simplified criteria for the diagnosis of autoimmune hepatitis. *Hepatology* 2008;48:169-176. <https://doi.org/10.1002/hep.22322>
- Zachou K, Muratori P, Koukoulis GK, et al. Review article: autoimmune hepatitis - Current management and challenges. *Aliment Pharmacol Ther* 2013;38:887-913. <https://doi.org/10.1111/apt.12470>
- Muratori P, Granito A, Quarneti C, et al. Autoimmune hepatitis in Italy: the Bologna experience. *J Hepatol* 2009;50:1210-1218. <https://doi.org/10.1016/j.jhep.2009.01.020>
- Al-Chalabi T, Underhill JA, Portmann BC, et al. Impact of gender on the long-term outcome and survival of patients with autoimmune hepatitis. *J Hepatol* 2008;48:140-147. <https://doi.org/10.1016/j.jhep.2007.08.013>
- Floreani A, Niro G, Rosa Rizzotto E, et al. Type I autoimmune hepatitis: clinical course and outcome in an Italian multicenter study. *Aliment Pharmacol Ther* 2006;24:1051-1057. <https://doi.org/10.1111/j.1365-2036.2006.03104.x>
- Fujiwara K, Fukuda Y, Yokosuka O. Precise histological evaluation of liver biopsy specimen is indispensable for diagnosis and treatment of acute onset autoimmune hepatitis. *J Gastroenterol* 2008;43:951-958. <https://doi.org/10.1007/s00535-008-2254-x>
- Yasui S, Fujiwara K, Yonemitsu Y, et al. Clinicopathological features of severe and fulminant forms of autoimmune hepatitis. *J Gastroenterol* 2011;46:378-390. <https://doi.org/10.1007/s00535-010-0316-3>
- Czaja AJ. Autoantibody-negative autoimmune hepatitis. *Dig Dis Sci* 2012;57:610-624. <https://doi.org/10.1007/s10620-011-2017-z>
- Zeman MV, Hirschfield GM. Autoantibodies and liver disease: uses and abuses. *Can J Gastroenterol* 2010;24:225-231. doi:10.1155/2010/431913
- Wijeyesinghe U, Russell AS. Outcome of high titer antinuclear antibody positivity in individuals without connective tissue disease: a 10-year follow-up. *Clin Rheumatol* 2008;27:1399-402. <https://doi.org/10.1007/s10067-008-0932-y>
- Kavanaugh A, Tomar R, Reveille J, et al. Guidelines for clinical use of the antinuclear antibody test and tests for specific autoantibodies to nuclear antigens. *American College of Pathologists. Arch Pathol Lab Med* 2000;124:71-81. [https://doi.org/10.1043/0003-9985\(2000\)124<0071:GFCUOT>2.0.CO;2](https://doi.org/10.1043/0003-9985(2000)124<0071:GFCUOT>2.0.CO;2)
- Cassani F, Cataleta M, Valentini P, et al. Serum autoantibodies in chronic hepatitis C: comparison with autoimmune hepatitis and impact on the disease profile. *Hepatology* 1997;26:561-6. <https://doi.org/10.1002/hep.510260305>
- Vuppalanchi R, Gould RJ, Wilson LA, et al. Clinical significance of serum autoantibodies in patients with NAFLD: results from the nonalcoholic steatohepatitis clinical research network. *Hepatology* 2012;6:379-385. <https://doi.org/10.1007/s12072-011-9277-8>
- Takahashi H, Zeniya M. Acute presentation of autoimmune hepatitis: Does it exist? A published work review. *Hepatology Res* 2011;41:498-504. <https://doi.org/10.1111/j.1872-034X.2011.00808.x>

- 23 Miyake Y, Iwasaki Y, Terada R, et al. Clinical characteristics of fulminant-type autoimmune hepatitis: an analysis of eleven cases. *Aliment Pharmacol Ther* 2006;23:1347-1353. <https://doi.org/10.1111/j.1365-2036.2006.02894.x>
- 24 Abe M, Mashiba T, Zeniya M, et al. Present status of autoimmune hepatitis in Japan: a nationwide survey. *J Gastroenterol* 2011;46:1136-1141. <https://doi.org/10.1007/s00535-011-0421-y>
- 25 Lohse AW, Mieli-Vergani G. Autoimmune hepatitis. *J Hepatol* 2011;55:171-182. <https://doi.org/10.1016/j.jhep.2010.12.012>
- 26 Manns MP, Czaja AJ, Gorham JD, et al. Diagnosis and management of autoimmune hepatitis. *Hepatology* 2010;51:2193-2213. <https://doi.org/10.1002/hep.23584>
- 27 Gleeson D, Heneghan MA. British Society of Gastroenterology (BSG) guidelines for management of autoimmune hepatitis. *Gut* 2011;60:1611-1629. <https://doi.org/10.1136/gut.2010.235259>
- 28 Czaja AJ. Autoimmune hepatitis in special patient populations. *Best Pract Res Clin Gastroenterol* 2011;25:689-700. <https://doi.org/10.1016/j.bpg.2011.09.011>
- 29 Tiniakos DG, Brain JG, Bury YA. Role of histopathology in autoimmune hepatitis. *Dig Dis* 2015;33 Suppl 2:53-64. <https://doi.org/10.1159/000440747>
- 30 Guindi M. Histology of autoimmune hepatitis and its variants. *Clin Liver Dis* 2010;14: 577-590. <https://doi.org/10.1016/j.cld.2010.07.003>
- 31 Gurung A, Assis DN, McCarty TR, et al. Histologic features of autoimmune hepatitis: a critical appraisal. *Hum Pathol* 2018;82:51-60. <https://doi.org/10.1016/j.humpath.2018.07.014>
- 32 Rubio CA, Truskaite K, Rajani R, et al. A method to assess the distribution and frequency of plasma cells and plasma cell precursors in autoimmune hepatitis. *Anticancer Res* 2013;33:665-669.
- 33 Washington MK, Manns MP. Autoimmune hepatitis. In: Burt AD, Portmann B, Ferrel L, eds. *MacSween's Pathology of the Liver*. Edinburgh: Churchill Livingstone 2012, pp 467-490.
- 34 Verdonk RC, Lozano MF, van den Berg AP, et al. Bile ductal injury and ductular reaction are frequent phenomena with different significance in autoimmune hepatitis. *Liver Int* 2016 Sep;36(9):1362-1369. <https://doi.org/10.1111/liv.13083>
- 35 Okano N, Yamamoto K, Sakaguchi K, et al. Clinicopathological features of acute-onset autoimmune hepatitis. *Hepatol Res* 2003;25:263-270. [https://doi.org/10.1016/s1386-6346\(02\)00274-7](https://doi.org/10.1016/s1386-6346(02)00274-7)
- 36 Hofer H, Oesterreicher C, Wrba F, et al. Centrilobular necrosis in autoimmune hepatitis: a histological feature associated with acute clinical presentation. *J Clin Pathol* 2006;59:246-249. <https://doi.org/10.1136/jcp.2005.029348>
- 37 de Boer YS, van Nieuwkerk CM, Witte BI, et al. Assessment of the histopathological key features in autoimmune hepatitis. *Histopathology* 2015;66:351-362. <https://doi.org/10.1111/his.12558>
- 38 Miao Q, Bian Z, Tang R, et al. Emperipolesis mediated by CD8 T cells is a characteristic histopathologic feature of autoimmune hepatitis. *Clin Rev Allergy Immunol* 2015;48(2-3):226-235. <https://doi.org/10.1007/s12016-014-8432-0>
- 39 Czaja AJ, Carpenter HA. Autoimmune hepatitis with incidental histologic features of bile duct injury. *Hepatology* 2001;34(4 Pt 1):659-665. <https://doi.org/10.1053/jhep.2001.27562>
- 40 Zen Y, Harada K, Sasaki M, et al. Are bile duct lesions of primary biliary cirrhosis distinguishable from those of autoimmune hepatitis and chronic viral hepatitis? Interobserver histological agreement on trimmed bile ducts. *J Gastroenterol* 2005;40:164-170. <https://doi.org/10.1007/s00535-004-1514-7>
- 41 Balitzer D, Shafizadeh N, Peters MG, et al. Autoimmune hepatitis: review of histologic features included in the simplified criteria proposed by the international autoimmune hepatitis group and proposal for new histologic criteria. *Mod Pathol* 2017;30:773-783. <https://doi.org/10.1038/modpathol.2016.267>
- 42 Bihari C, Rastogi A, Sarin SK. Postinfantile giant cell hepatitis: an etiological and prognostic perspective. *Hepat Res Treat* 2013;2013:601290. <https://doi.org/10.1155/2013/601290>
- 43 Tucker SM, Jonas MM, Perez-Atayde AR. Hyaline droplets in Kupffer cells: a novel diagnostic clue for autoimmune hepatitis. *Am J Surg Pathol* 2015;39:772-778. <https://doi.org/10.1097/PAS.0000000000000395>
- 44 Scheuer PJ. Classification of chronic viral hepatitis: a need for reassessment. *J Hepatol* 1991;13: 372-374. [https://doi.org/10.1016/0168-8278\(91\)90084-o](https://doi.org/10.1016/0168-8278(91)90084-o)
- 45 Ishak K, Baptista A, Bianchi L, et al. Histological grading and staging of chronic hepatitis. *J Hepatol* 1995;22:696-699. [https://doi.org/10.1016/0168-8278\(95\)80226-6](https://doi.org/10.1016/0168-8278(95)80226-6)
- 46 The French METAVIR cooperative study group. Intraobserver and interobserver variations in liver biopsy interpretation in patients with chronic hepatitis C. *Hepatology* 1994;20:15-20.
- 47 Fujiwara S, Yokokawa Y, Morino K, et al. Chronic hepatitis E: a review of the literature. *J Viral Hepat* 2014;21:78-89. <https://doi.org/10.1111/jvh.12156>
- 48 Lenggenhager D, Pawel S, Honcharova-Biletska H, et al. The histologic presentation of hepatitis E reflects patients' immune status and pre-existing liver condition. *Mod Pathol* 2021;34:233-248. <https://doi.org/10.1038/s41379-020-0593-1>
- 49 Lenggenhager D, Weber A. Clinicopathologic features and pathologic diagnosis of hepatitis E. *Hum Pathol* 2020;96:34-38. <https://doi.org/10.1016/j.humpath.2019.10.003>
- 50 Kleiner DE. Recent Advances in the histopathology of drug-induced liver injury. *Surg Pathol Clin* 2018;11:297-311. <https://doi.org/10.1016/j.path.2018.02.009>
- 51 Garcia-Buey L, Garcia-Monzon C, Rodriguez S, et al. Latent autoimmune hepatitis triggered during interferon therapy in patients with chronic hepatitis C. *Gastroenterology* 1995;108:1770-1777. [https://doi.org/10.1016/0016-5085\(95\)90139-6](https://doi.org/10.1016/0016-5085(95)90139-6)
- 52 Takahashi A, Kanno Y, Takahashi Y, et al. Development of autoimmune hepatitis type 1 after pulsed methylprednisolone therapy for multiple sclerosis: a case report. *World J Gastroenterol* 2008;14:5474-5477. <https://doi.org/10.3748/wjg.14.5474>
- 53 Kleiner DE. Histopathological challenges in suspected drug-induced liver injury. *Liver Int* 2018 38:198-209. <https://doi.org/10.1111/liv.13584>
- 54 Suzuki A, Brunt EM, Kleiner DE, et al. The use of liver biopsy evaluation in discrimination of idiopathic autoimmune hepatitis versus drug-induced liver injury. *Hepatology* 2011;54:931-939. <https://doi.org/10.1002/hep.24481>
- 55 Schilsky ML. Wilson disease: genetic basis of copper toxicity and natural history. *Semin Liver Dis* 1996;16:83-95. <https://doi.org/10.1055/s-2007-1007221>