



CASE REPORT

REVISED Case Report: Secondary bilateral parkinsonism and dystonia treated with dronabinol [version 3; peer review: 2 approved]

Natalia Szejko ¹⁻³, Florian Burger⁴, Victoria Sidoroff⁵, Gregor K. Wenning⁵

¹Department of Neurology, Medical University of Warsaw, Warsaw, 02091, Poland

²Department of Bioethics, Medical University of Warsaw, Warsaw, 02091, Poland

³Division of Neurocritical Care, Department of Neurology, Yale University, New Haven, Connecticut, 06519, USA

⁴District Hospital Kufstein, Kufstein, Austria

⁵Department of Neurology, Medical University of Innsbruck, Innsbruck, Austria

V3 First published: 21 Sep 2020, 9:1162
<https://doi.org/10.12688/f1000research.26476.1>
 Second version: 23 Oct 2020, 9:1162
<https://doi.org/10.12688/f1000research.26476.2>
 Latest published: 06 Aug 2021, 9:1162
<https://doi.org/10.12688/f1000research.26476.3>

Abstract

Drug abuse may damage basal ganglia that are essential for planning and execution of movements. We report about the case of a 38-year old patient with ischemic lesions of the basal ganglia presenting with bilateral painful dystonia and parkinsonism caused by polyintoxication. Dronabinol resulted in improvement of pain and gait disturbance, suggesting a novel therapeutic strategy in these challenging patients.

Keywords

dronabinol, secondary parkinsonism, dystonia, intoxication, ischemic stroke

Open Peer Review

Reviewer Status

	Invited Reviewers	
	1	2
version 3		
(revision)		
06 Aug 2021		report
version 2		
(revision)		
23 Oct 2020	report	report
version 1		
21 Sep 2020	report	

1. **Jose Luis Lopez-Sendon Moreno** , Hospital Ramón y Cajal, Madrid, Spain
2. **Giovanni Defazio**, University of Cagliari, Cagliari, Italy
- Tommaso Ercoli**, University of Cagliari, Cagliari, Italy

Any reports and responses or comments on the article can be found at the end of the article.

Corresponding author: Natalia Szejko (natalia.szejko@gmail.com)

Author roles: **Szejko N:** Conceptualization, Formal Analysis, Methodology, Writing – Original Draft Preparation, Writing – Review & Editing; **Burger F:** Conceptualization, Writing – Original Draft Preparation, Writing – Review & Editing; **Sidoroff V:** Writing – Review & Editing; **Wenning GK:** Supervision, Writing – Review & Editing

Competing interests: No competing interests were disclosed.

Grant information: The author(s) declared that no grants were involved in supporting this work.

Copyright: © 2021 Szejko N *et al.* This is an open access article distributed under the terms of the [Creative Commons Attribution License](#), which permits unrestricted use, distribution, and reproduction in any medium, provided the original work is properly cited.

How to cite this article: Szejko N, Burger F, Sidoroff V and Wenning GK. **Case Report: Secondary bilateral parkinsonism and dystonia treated with dronabinol [version 3; peer review: 2 approved]** F1000Research 2021, 9:1162
<https://doi.org/10.12688/f1000research.26476.3>

First published: 21 Sep 2020, 9:1162 <https://doi.org/10.12688/f1000research.26476.1>

REVISED Amendments from Version 2

In this version, we have included more references regarding differences between primary and secondary movement disorders and explained more about clinical examination of the patient. We have also corrected some typos.

Any further responses from the reviewers can be found at the end of the article

Introduction

Drug abuse is an important health issue, not only affecting the social surrounding of a patient but also the cerebral integrity. Besides a number of different somatic abnormalities provoked by an intoxication, certain drugs may damage areas of the brain, such as basal ganglia or cortex, which are essential for the movement onset and coordination¹⁻³.

In this case report, we present a 38-year-old male patient with a long-lasting history of drug misuse, including the abuse of cocaine, cannabinoids, benzodiazepines, opiates, methadone and amphetamines. As a result of the multi-intoxication induced bilateral ischaemic lesions to the basal ganglia, the patient presented with secondary bilateral dystonia and parkinsonism. It is not certain whether the cause of ischemia could be related to any specific drug or combinations thereof. However, it is clear that primary and secondary movement disorders have different pathophysiology and, therefore, require different treatments⁴⁻⁶. Cocaine and its metabolites are known to cause cerebral vasospasm that could lead to ischemic infarctions in the whole brain^{1,7,8} or can provoke haemorrhagic stroke³. Heroin causes ischemia more often in the globus pallidus⁹. Amphetamines are known as the second most frequent cause of ischemia after cocaine, especially in younger patients due to their vasoconstrictive effect¹⁰. Although it is not clear whether cannabinoids and its metabolites can cause cerebrovascular

events, there is evidence that cannabis can increase the risk for haemorrhagic stroke¹¹. Opioids may not have a direct toxic impact on the neurons, but ischaemic lesions or necrosis can be triggered by recurrence of drug-induced hypoxia¹².

The aim of this case report is to show the possible use of dronabinol for a multi-intoxicated patient with ischemia of the basal ganglia in order to temper his pain and improve gait.

Case report

We present a case of a 27-year-old Caucasian man who was admitted to the Intensive Care Unit (ICU) after multi-intoxication. Drug screening on admission identified the following substances: opiates, benzodiazepines, cannabinoids, crack cocaine, methadone and amphetamine. Due to the history of drug abuse he was unemployed. During the first days the patient was in coma, with Glasgow Coma Scale of 5 points. After slow amelioration of his status he presented with severe dysarthria, dysphagia, as well as bilateral parkinsonism and dystonia of his extremities. The neurological examination showed a bilateral positive Babinski sign, global rigidity in all extremities as well as symmetrical hyperreflexia. Furthermore, he suffered from high fever that resolved after treatment with benzodiazepines. Therefore, vegetative symptoms accompanying the patient on admission were interpreted as drug withdrawal syndrome. Both, CT and MRI showed bilateral hypoxic infarction of the basal ganglia and boundary zone (Figure 1). Those changes could be the consequence of the mixed intoxication or could be attributed to only one harmful substance, especially crack cocaine or amphetamine. During the hospitalization he developed a tracheobronchitis and respiratory insufficiency due to acute respiratory distress syndrome (ARDS). Moreover, because of severe dysphagia he was nourished via percutaneous endoscopic gastrostomy. Further consequences of his primary condition included post ischemic epilepsy treated with levetiracetam (1000mg).

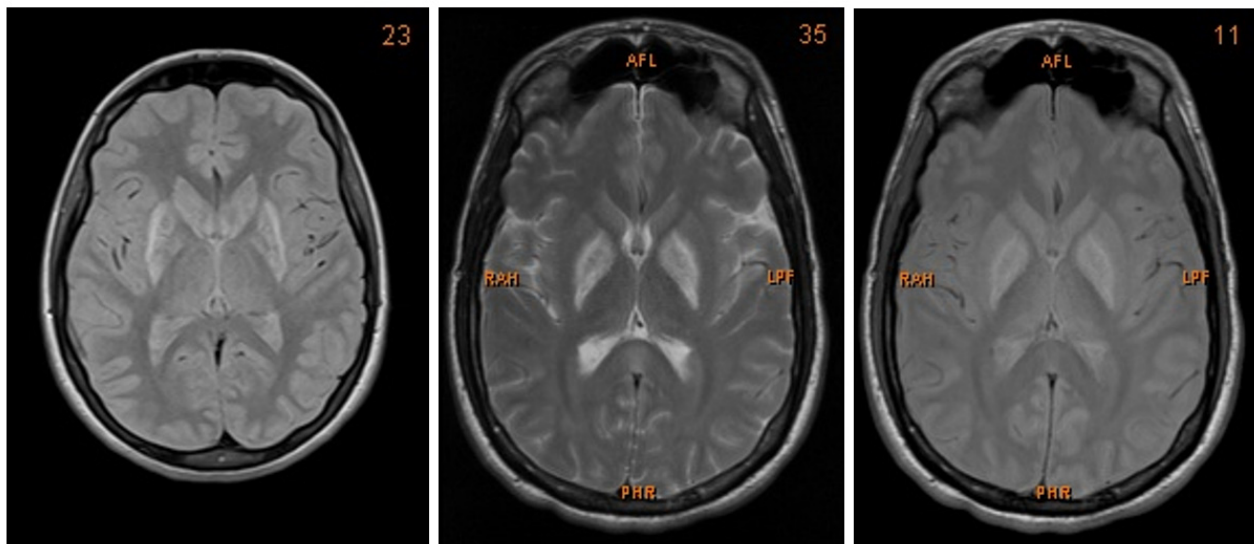


Figure 1. MRI images showing bilateral post-ischaemic lesions of the basal ganglia.

After six months of intensive care, the patient was discharged from the hospital.

During the next five years the patient was treated with levodopa (titrated up to 800mg/day), apomorphine (up to 100 mg/day), selegiline (10mg/day) and baclofen (75mg/day). Further up-titration of levodopa was not possible because of subsequent side effects, such as hallucinations. Due to sleeping problems and agitation he was treated with trazodone (150mg/day) and quetiapine (250mg/day). The substitution dose of buprenorphine 20mg/day was tapered off constantly to keep the patient in a drug naive state. Nonetheless, he showed aggressive behaviour under the influence of alcohol and was admitted to psychiatric ward several times due to delusional disorder and recurrent addictive behaviours. After several months of psychiatric treatment, his addiction and hallucinations resolved. In spite of intense treatment, both parkinsonism as well as dystonia persisted for years and additional symptoms such as generalized pain as well as gait disturbances occurred.

During the examination in our outpatient clinic, 11 years after the hospitalization in the ICU, the patient was still experiencing moderate dysarthria, bilateral dystonia of all extremities, bilateral akinetic-rigid parkinsonism, camptocormia and freezing. In particular, dystonia was limited to dystonic posturing of the fingers and painful dystonia of the toes. Due to those symptoms and increased anxiety as well as painful dystonia as well as unsuccessful treatment with evidence-based agents the patient was treated with dronabinol by his psychiatrist (capsules slowly up titrated to 20mg/day).

After two months of dronabinol treatment, the patient reported subjective improvement of the dystonic pain and a moderate improvement of freezing of gait as well as less falls. We examined the patient at two timepoints: after two months and after six months of dronabinol therapy. Importantly, the medication used at both timepoints remained stable, which excludes confounding contribution of other agents. Results of clinical assessments after two and six months of dronabinol administration are shown in Table 1. The baseline Unified Parkinson's Disease Rating Scale and Unified Dystonia Rating Scale results cannot be provided as the data were not collected. Although the patient reported the subjective improvement of his symptoms, this was not confirmed in the neurological examination or in the UPDRS and UDRS assessments. Particularly, there was no minimal clinically important differences for UPDRS nor UDRS, although there was an improvement in sleep quality according to ESS. It can therefore be concluded that dronabinol had subjective analgesic and calming effect and, as a consequence, also improved sleep and general performance. Although he self-reported gait amelioration, it is not clear whether the patient exhibited any motor improvement. All in all, all positive effects were subjective and the final conclusion about the effectiveness of dronabinol cannot be reached.

Table 1. Results of clinical assessments two and six months after therapy with dronabinol.

Scale	Examination after two months	Examination after six months
UPDRS I	0	0
UPDRS II	18	14
UPDRS III	26	24
UPDRS IV	0	0
H-Y	2.5	2.5
Schwab and England	80%	90%
UDRS	2	2
PDSS-2	1	12
ESS	1	5
BDI	11	10

UPDRS, Unified Parkinson's Disease Rating Scale; H-Y, Modified Hoehn and Yahr Staging; PDSS-2, Parkinson Disease Sleep Scale-2; UDRS, Unified Dystonia Rating Scale; ESS, Epworth Sleepiness Scale; BDI, Beck Depression Inventory.

Discussion

While there is some evidence that cannabis-based medicine (CBM) could improve both motor and non-motor symptoms in Parkinson's disease (PD)^{13,14}, the effectiveness of CBM in secondary parkinsonism as well as dystonia is unknown. Recently, Peball *et al.*¹⁵ reported the potential efficacy of nabilone for PD patients with disturbing non-motor symptoms, which appears to be driven by positive effects on anxious mood and night-time sleep problems. Moreover, a number of other open label studies and case reports demonstrated efficacy of CBM in treatment of movement disorders^{16–18}. Small randomized trials in Tourette syndrome confirmed efficacy of tetrahydrocannabinol (THC) for tic reduction^{19,20}. Therefore, CBM might be a useful therapeutic alternative for therapy resistant patients with movement disorders. However, systematic reviews and meta-analysis in this group of patients demonstrated conflicting results, due to methodological limitations of studies with CBM^{21,22}.

In the case of our patient, his condition improved only subjectively, but this was not confirmed with objective neurological testing. Moreover, the use of cannabinoids in this case is controversial as the patient had a positive medical history for cannabis misuse. Additionally, long-term effectiveness should also be investigated with accuracy. Potential psychotic effects could be dangerous, therefore the dosage in our patient was slowly increased. Nevertheless, safety profile of CBM in movement disorders reported in previous studies was favorable, with the most common side effects being sedation, dizziness and sensation of "being high"^{21,22}. Also, no

baseline assessments, prior to dronabinol administration, were available. Finally, almost all previous reports regarding the application of CBM in movement disorders were limited to primary and not secondary disorders. As mentioned in the introduction, the pathophysiology of both disorders is totally different. In case of our patient the suspected mechanism is suspected to be vasospasm provoked by drug abuse that, in turn, provoked ischemia and, finally, abnormal pattern of movements. Results of international randomized, double-blind controlled trials with CBM in PD might offer more scientific

rationales for discussion of potential usefulness of CBM in other movement disorders.

Data availability

All data underlying the results are available as part of the article and no additional source data are required.

Consent

Written informed consent for publication of their clinical details and clinical images was obtained from the patient.

References

- Büttner A: **Review: The neuropathology of drug abuse.** *Neuropathol Appl Neurobiol.* 2011; **37**(2): 118–34.
[PubMed Abstract](#) | [Publisher Full Text](#)
- Büttner A: **The neuropathology of drug abuse.** *Curr Opin Behav Sci.* 2017; **13**: 8–12.
[Publisher Full Text](#)
- Martin-Schild S, Albright KC, Hallevi H, et al.: **Intracerebral hemorrhage in cocaine users.** *Stroke.* 2010; **41**(4): 680–4.
[PubMed Abstract](#) | [Publisher Full Text](#) | [Free Full Text](#)
- Kojovic M, Pareés I, Kassavetis P, et al.: **Secondary and primary dystonia: pathophysiological differences.** *Brain.* 2013; **136**(Pt 7): 2038–49.
[PubMed Abstract](#) | [Publisher Full Text](#)
- Korczyński AD: **Vascular parkinsonism—characteristics, pathogenesis and treatment.** *Nat Rev Neurol.* 2015; **11**(6): 319–26.
[PubMed Abstract](#) | [Publisher Full Text](#)
- Belvisi D, Pellicciari R, Fabbrini A, et al.: **Risk factors of Parkinson disease: Simultaneous assessment, interactions, and etiologic subtypes.** *Neurology.* 2020; **95**(18): e2500–e2508.
[PubMed Abstract](#) | [Publisher Full Text](#) | [Free Full Text](#)
- Vidal SGM, Hornik A, Morgan C: **Cocaine induced hippocampi infarction.** *BMJ Case Rep.* 2012; **2012**: bcr0320125998.
[PubMed Abstract](#) | [Publisher Full Text](#) | [Free Full Text](#)
- Farrell CM, Cucu DF: **Cocaine-Related Acute Spinal Cord Infarction.** *R I Med J (2013).* 2018; **101**(1): 28–9.
[PubMed Abstract](#)
- Vila N, Chamorro A: **Ballistic movements due to ischemic infarcts after intravenous heroin overdose: report of two cases.** *Clin Neurol Neurosurg.* 1997; **99**(4): 259–62.
[PubMed Abstract](#) | [Publisher Full Text](#)
- Lappin JM, Darke S, Farrell M: **Stroke and methamphetamine use in young adults: a review.** *J Neurol Neurosurg Psychiatry.* 2017; **88**(12): 1079–91.
[PubMed Abstract](#) | [Publisher Full Text](#)
- El Mesbahy J, Chraa M, Louhab N, et al.: **Hemorrhagic stroke after cannabis use in a young man.** *Rev Neurol (Paris).* 2017; **173**(10): 666–668.
[PubMed Abstract](#) | [Publisher Full Text](#)
- Ryste ST, Engelsen BA, Naess H: **Codeine is associated with poor prognosis in acute stroke.** *Brain Behav.* 2017; **7**(12): e00869.
[PubMed Abstract](#) | [Publisher Full Text](#) | [Free Full Text](#)
- Balash Y, Bar-Lev Schleider L, Korczyn AD, et al.: **Medical Cannabis in Parkinson Disease: Real-Life Patients' Experience.** *Clin Neuropharmacol.* 2017; **40**(6): 268–72.
[PubMed Abstract](#) | [Publisher Full Text](#)
- Peres FF, Lima AC, Hallak JEC, et al.: **Cannabidiol as a Promising Strategy to Treat and Prevent Movement Disorders?** *Front Pharmacol.* 2018; **9**: 482.
[PubMed Abstract](#) | [Publisher Full Text](#) | [Free Full Text](#)
- Peball M, Krismer F, Knaus HG, et al.: **Non-Motor Symptoms in Parkinson's Disease are Reduced by Nabilone.** *Ann Neurol.* 2020; **88**(4): 712–722.
[PubMed Abstract](#) | [Publisher Full Text](#) | [Free Full Text](#)
- Mascia MM, Carmagnini D, Defazio G: **Cannabinoids and dystonia: an issue yet to be defined.** *Neurol Sci.* 2020; **41**(4): 783–787.
[PubMed Abstract](#) | [Publisher Full Text](#)
- Kindred JH, Li K, Ketelhut NB, et al.: **Cannabis use in people with Parkinson's disease and Multiple Sclerosis: A web-based investigation.** *Complement Ther Med.* 2017; **33**: 99–104.
[PubMed Abstract](#) | [Publisher Full Text](#)
- Whiting PF, Wolff RF, Deshpande S, et al.: **Cannabinoids for Medical Use: A Systematic Review and Meta-analysis.** *JAMA.* 2015; **313**(24): 2456–73.
[PubMed Abstract](#) | [Publisher Full Text](#)
- Müller-Vahl KR, Schneider U, Prevedel H, et al.: **Delta 9-tetrahydrocannabinol (THC) is effective in the treatment of tics in Tourette syndrome: a 6-week randomized trial.** *J Clin Psychiatry.* 2003; **64**(4): 459–65.
[PubMed Abstract](#) | [Publisher Full Text](#)
- Müller-Vahl KR, Schneider U, Koblenz A, et al.: **Treatment of Tourette's syndrome with Delta 9-tetrahydrocannabinol (THC): a randomized crossover trial.** *Pharmacopsychiatry.* 2002; **35**(2): 57–61.
[PubMed Abstract](#) | [Publisher Full Text](#)
- Lim K, See YM, Lee J: **A Systematic Review of the Effectiveness of Medical Cannabis for Psychiatric, Movement and Neurodegenerative Disorders.** *Clin Psychopharmacol Neurosci.* 2017; **15**(4): 301–312.
[PubMed Abstract](#) | [Publisher Full Text](#) | [Free Full Text](#)
- Bougea AM, Koros C, Simitsi A, et al.: **Medical cannabis as an alternative therapeutics for Parkinsons' disease: Systematic review.** *Complement Ther Clin Pract.* 2020; **39**: 101154.
[PubMed Abstract](#) | [Publisher Full Text](#)

Open Peer Review

Current Peer Review Status:  

Version 3

Reviewer Report 20 August 2021

<https://doi.org/10.5256/f1000research.59283.r91415>

© 2021 Defazio G et al. This is an open access peer review report distributed under the terms of the [Creative Commons Attribution License](#), which permits unrestricted use, distribution, and reproduction in any medium, provided the original work is properly cited.



Giovanni Defazio

Department of Medical Sciences and Public Health, University of Cagliari, Cagliari, Italy

Tommaso Ercoli

Department of Medical Sciences and Public Health, University of Cagliari, Cagliari, Italy

The authors answered all questions raised by these referees.

Competing Interests: No competing interests were disclosed.

Reviewer Expertise: Movement disorders

We confirm that we have read this submission and believe that we have an appropriate level of expertise to confirm that it is of an acceptable scientific standard.

Version 2

Reviewer Report 28 July 2021

<https://doi.org/10.5256/f1000research.30251.r89189>

© 2021 Defazio G et al. This is an open access peer review report distributed under the terms of the [Creative Commons Attribution License](#), which permits unrestricted use, distribution, and reproduction in any medium, provided the original work is properly cited.



Giovanni Defazio

Department of Medical Sciences and Public Health, University of Cagliari, Cagliari, Italy

Tommaso Ercoli

Department of Medical Sciences and Public Health, University of Cagliari, Cagliari, Italy

The authors reported an interesting and challenging case of secondary bilateral parkinsonism and dystonia. Treatment with dronabinol resulted in improvement of pain and gait disturbance.

Major concerns:

1. Pain improvement was not supported by score change in a specific scale.
2. Likewise, improvement in gait disturbance was not supported by consistent UPDRS/UDRS score change. Subjective improvement of gait was attributed to moderate (subjective?) improvement of freezing of gait, with less falls. However, UPDRS does not assess freezing of gait, and a scale specifically assessing freezing of gait was not administered.
3. The authors should provide a quantitative assessment of the number/time of falls occurred before and after dronabinol.

In conclusion, this report neither support nor discourage the therapeutic use of dronabinol in secondary movement disorders.

Minor points:

1. Introduction:

I would suggest changing the introduction starting with a paragraph that briefly describes dystonia and parkinsonism. Some relevant references to be cited:

- Kojovic *et al.* (2013¹)
- Defazio *et al.* (2020²)
- Korczyn *et al.* (2015³)
- Belvisi *et al.* (2020⁴)

2. Case report:

- Please better describe the neurological examination, in particular please provide more information on dystonia. Was the cranial region involved? Does the patient develop a sensory trick?
- Please correct this typo providing the right timing info: "We examined the patient at two timepoints: after two months and after two months of dronabinol therapy."

3. Discussion:

- I would suggest adding a short paragraph describing the possible mechanisms of the ischemic event and the relationship between the drug abuse and the MRI findings.

References

1. Kojovic M, Pareés I, Kassavetis P, Palomar FJ, et al.: Secondary and primary dystonia: pathophysiological differences. *Brain*. 2013; **136** (Pt 7): 2038-49 [PubMed Abstract](#) | [Publisher Full Text](#)
2. Defazio G, Fabbrini G, Erro R, Albanese A, et al.: Does acute peripheral trauma contribute to idiopathic adult-onset dystonia?. *Parkinsonism Relat Disord*. **71**: 40-43 [PubMed Abstract](#) | [Publisher Full Text](#)

3. Korczyn AD: Vascular parkinsonism--characteristics, pathogenesis and treatment. *Nat Rev Neurol*. 2015; **11** (6): 319-26 [PubMed Abstract](#) | [Publisher Full Text](#)
4. Belvisi D, Pellicciari R, Fabbrini A, Costanzo M, et al.: Risk factors of Parkinson disease. *Neurology*. 2020; **95** (18): e2500-e2508 [Publisher Full Text](#)

Is the background of the case's history and progression described in sufficient detail?

Partly

Are enough details provided of any physical examination and diagnostic tests, treatment given and outcomes?

Partly

Is sufficient discussion included of the importance of the findings and their relevance to future understanding of disease processes, diagnosis or treatment?

Partly

Is the case presented with sufficient detail to be useful for other practitioners?

Yes

Competing Interests: No competing interests were disclosed.

Reviewer Expertise: Movement disorders

We confirm that we have read this submission and believe that we have an appropriate level of expertise to confirm that it is of an acceptable scientific standard, however we have significant reservations, as outlined above.

Author Response 04 Aug 2021

Natalia Szejko, Medical University of Warsaw, Warsaw, Poland

Thank you so much for reviewing our manuscript. We provide answers to reviewer's suggestions below:

Major points:

- *Pain improvement was not supported by score change in a specific scale.*
- **Response:** We do agree that this would provide more objective results regarding the pain improvement, however, at the moment of examination none pain scales were administered. Unfortunately, we cannot provide these data.
- *Likewise, improvement in gait disturbance was not supported by consistent UPDRS/UDRS score change. Subjective improvement of gait was attributed to moderate (subjective?) improvement of freezing of gait, with less falls. However, UPDRS does not assess freezing of gait, and a scale specifically assessing freezing of gait was not administered.*
- **Response:** We also agree with this suggestion, however, similarly to the previous point, we did not use any scale to assess the freezing of gait.

- *The authors should provide a quantitative assessment of the number/time of falls occurred before and after dronabinol.*
- **Response:** Again, this was not inquired during the patient's visits, but the patient reported about general improvement in this domain. Moreover, now it is impossible to gain this information due to recall bias.
- *In conclusion, this report neither support nor discourage the therapeutic use of dronabinol in secondary movement disorders.*
- **Response:** We agree with this statement and reformulated the conclusions appropriately: "All in all, all positive effects were subjective and the final conclusion about the effectiveness of dronabinol cannot be reached"

Minor points:

- *Introduction: I would suggest changing the introduction starting with a paragraph that briefly describes dystonia and parkinsonism. Some relevant references to be cited: Kojovic et al. (2013¹), Defazio et al. (2020²), Korczyn et al. (2015³), Belvisi et al. (2020⁴)*
- **Response:** We appreciate this suggestion and have included a new paragraph in the introduction: "However, it is clear that primary and secondary movement disorders have different pathophysiology and, therefore, require different treatments [4-6]"
- *Case report: Please better describe the neurological examination, in particular please provide more information on dystonia. Was the cranial region involved? Does the patient develop a sensory trick?*
- **Response:** We also appreciate this suggestion and have explained it in more detail: "In particular, dystonia was limited to dystonic posturing of the fingers and painful dystonia of the toes."
- *Please correct this typo providing the right timing info: "We examined the patient at two timepoints: after two months and after two months of dronabinol therapy."*
- **Response:** We have corrected this typo accordingly and now it states: "We examined the patient at two timepoints: after two months and after six months of dronabinol therapy".
- *Discussion: I would suggest adding a short paragraph describing the possible mechanisms of the ischemic event and the relationship between the drug abuse and the MRI findings.*
- **Response:** Thank you, we have included paragraph describing possible pathophysiology of these findings: "In case of our patient the suspected mechanism is suspected to be vasospasm provoked by drug abuse that, in turn, provoked ischemia and, finally, abnormal pattern of movements".

Competing Interests: No competing interests were disclosed.

Reviewer Report 27 October 2020

<https://doi.org/10.5256/f1000research.30251.r73627>

© 2020 Lopez-Sendon Moreno J. This is an open access peer review report distributed under the terms of the [Creative Commons Attribution License](#), which permits unrestricted use, distribution, and reproduction in any medium, provided the original work is properly cited.



Jose Luis Lopez-Sendon Moreno 

Neurology Department, Hospital Ramón y Cajal, Madrid, Spain

I believe that the amendments are correct and the article is ready for indexing.

Is the background of the case's history and progression described in sufficient detail?

Yes

Are enough details provided of any physical examination and diagnostic tests, treatment given and outcomes?

Yes

Is sufficient discussion included of the importance of the findings and their relevance to future understanding of disease processes, diagnosis or treatment?

Yes

Is the case presented with sufficient detail to be useful for other practitioners?

Yes

Competing Interests: No competing interests were disclosed.

Reviewer Expertise: Clinical research. Cannabinoids.

I confirm that I have read this submission and believe that I have an appropriate level of expertise to confirm that it is of an acceptable scientific standard.

Version 1

Reviewer Report 05 October 2020

<https://doi.org/10.5256/f1000research.29232.r71804>

© 2020 Lopez-Sendon Moreno J. This is an open access peer review report distributed under the terms of the [Creative Commons Attribution License](#), which permits unrestricted use, distribution, and reproduction in any medium, provided the original work is properly cited.



Jose Luis Lopez-Sendon Moreno 

Neurology Department, Hospital Ramón y Cajal, Madrid, Spain

The authors describe an interesting case about a patient with secondary dystonia and

parkinsonism and an aparent improvement with dronabinol.

The case is relevant since it provides insight into the treatment of a disabling condition. Also, the use of cannabinoids in the setting of movement disorders is a promising field.

The case is well described but I have several comments to make:

- Do the authors have information on other similar cases treated with dronabinol in which no improvement (or perhaps secondary effects) were noted? If so, please comment in order to avoid "publication bias".
- Is the mechanism of action of the parkinsonism isquemic? perhaps the toxicity could be due to other mechanisms (toxic, inflammatory...) Could other "over the counter" substances contribute to the toxicity?
- The authors comment on the lack of structured data on the neurological exploration before treatment. Gait improvement is based on the subjective experience alone. However, could this improvement be quantitatively reflected (Eg. was able to walk unaided, use of support, falls....). If not, then the abstract and conclusions could be overstated. Please correct.
- The improvement was noted after two months. Please comment why the delay, since the effect should have happened earlier.
- Some information on the text should be clarified (was the patient six months in intensive care or was that the total time of hospitalization?).
As well is repeated twice in the same sentence. Please correct.
The examination was done after two months twice (in the text, not in the table), please correct.
- There is some evidence (RCT and good reviews) in the use of CBM in mov disorders. Please consider adding further references.

I believe that the case report should be of interest to the readers and should be indexed with some changes.

Is the background of the case's history and progression described in sufficient detail?

Yes

Are enough details provided of any physical examination and diagnostic tests, treatment given and outcomes?

Yes

Is sufficient discussion included of the importance of the findings and their relevance to future understanding of disease processes, diagnosis or treatment?

Yes

Is the case presented with sufficient detail to be useful for other practitioners?

Yes

Competing Interests: No competing interests were disclosed.

Reviewer Expertise: Clinical research. Cannabinoids.

I confirm that I have read this submission and believe that I have an appropriate level of expertise to confirm that it is of an acceptable scientific standard, however I have significant reservations, as outlined above.

Author Response 09 Oct 2020

Natalia Szejko, Medical University of Warsaw, Warsaw, Poland

Thank you so much for your valuable comments, we would like to address them below. We have also submitted the new version of the manuscript in the effort to address your comments.

As for other cases of the movement disorders treated with cannabis based medicine, there is already extensive evidence in this area, reporting also about the side effects. We discuss it in the paper, but have included more references and more extensive description, as suggested.

When it comes to the exact mechanism of ischemia in this case, it is not entirely clear. However, we suspect it was both toxic and secondary due to vasoconstriction.

We have updated the information about the gait improvement, as the patient experienced less falls after treatment with dronabinol.

We would like to comment on the time of assessments. The first follow-up was performed after two months and we do not consider it too long, taking into consideration previous reports, this is an adequate time of evaluation.

We have checked the manuscript for the timing and updated it accordingly.

Finally, we have included more references reporting about the use of CBM in treatment of movement disorders.

Competing Interests: No competing interests were disclosed.

The benefits of publishing with F1000Research:

- Your article is published within days, with no editorial bias
- You can publish traditional articles, null/negative results, case reports, data notes and more
- The peer review process is transparent and collaborative
- Your article is indexed in PubMed after passing peer review
- Dedicated customer support at every stage

For pre-submission enquiries, contact research@f1000.com

F1000Research