

Sporadic non-ampullary duodenal adenoma with low-grade dysplasia: Natural history and clinical management



Authors

Yohei Ikenoyama^{1,2}, Shoichi Yoshimizu¹, Ken Namikawa¹, Yoshitaka Tokai¹, Yusuke Horiuchi¹, Akiyoshi Ishiyama¹, Toshiyuki Yoshio¹, Toshiaki Hirasawa¹, Junko Fujisaki¹

Institutions

- 1 Department of Gastroenterology, Cancer Institute Hospital, Japanese Foundation for Cancer Research, Tokyo, Japan
- 2 Department of Endoscopy, Mie University Graduate School of Medicine, Mie, Japan

submitted 9.6.2021

accepted after revision 17.9.2021

Bibliography

Endosc Int Open 2022; 10: E254–E261

DOI 10.1055/a-1672-3797

ISSN 2364-3722

© 2022. The Author(s).

This is an open access article published by Thieme under the terms of the Creative Commons Attribution-NonDerivative-NonCommercial License, permitting copying and reproduction so long as the original work is given appropriate credit. Contents may not be used for commercial purposes, or adapted, remixed, transformed or built upon. (<https://creativecommons.org/licenses/by-nc-nd/4.0/>)

Georg Thieme Verlag KG, Rüdigerstraße 14,
70469 Stuttgart, Germany

Corresponding author

Shoichi Yoshimizu, MD, Department of Gastroenterology, Cancer Institute Hospital of the Japanese Foundation for Cancer Research, 3-8-31 Ariake, Koto-ward, Tokyo 135-8550, Japan

Fax: +81-3-3520-0141

shoichi.yoshimizu@jfcrr.or.jp

ABSTRACT

Background and study aims Management strategies for sporadic non-ampullary duodenal adenoma with low-grade dysplasia (LGD) are not well established. This study aimed to analyze progression factors and determine suitable treatment strategies for LGD lesions.

Patients and methods We retrospectively analyzed consecutive LGD lesions (n=125) in patients followed up for ≥ 6 months (median, 45 months) and evaluated the changes in clinicopathological features during follow-up. All LGD lesions were classified into two groups: stable LGD (no increase or <5 mm increase in tumor size, with unchanged histological dysplasia grade) and progressive LGD (≥5 mm increase in tumor size and/or progression to high-grade dysplasia or adenocarcinoma).

Results Eighty-six LGD were classified as stable and 39 as progressive. Location on the oral side of the papilla of Vater, large initial tumor size (≥ 10 mm), macroscopically complex type, red color, and nodularity were significantly frequent in progressive LGD than in stable LGD. In multivariate analysis, large initial tumor size (odds ratio [OR], 10.2; 95% confidence interval [CI], 3.3–32.1; *P*<0.001) and location on the oral side of the papilla of Vater (OR: 1.8, 95% CI: 1.4–12.5; *P*=0.012) were significant factors for progression. Moreover, initial tumor size <5 mm rarely progressed (0%–3.9%); however, initial tumor size ≥20 mm and 10–19 mm located on the oral side of the papilla of Vater had a high-risk progression rate (75.0–85.7%).

Conclusions According to the risk stratification of progression factors by initial tumor size and location, we can determine suitable treatment indications for LGD lesions.

Introduction

According to autopsy studies, non-ampullary duodenal epithelial tumors and sporadic non-ampullary duodenal adenomas (SNDAs) are extremely rare, with a prevalence of 0.02% to 0.5% [1–4]. However, the detection rate of SNDAs has gradually increased in recent years along with the increase in routine esophagogastroduodenoscopy (EGD) and improvements in endoscopic technology [5].

Endoscopic resection (ER), including endoscopic mucosal resection (EMR) and endoscopic submucosal dissection (ESD), was previously used as a treatment to remove superficial non-ampullary duodenal epithelial tumors (SNADETs), including SNDAs. However, there is a significantly higher risk of adverse events such as intraprocedural perforation, delayed perforation, and delayed bleeding in the duodenum owing to its thin wall and narrow lumen [6–12]. Recently, cold snare polypectomy (CSP) and underwater EMR (UEMR) are increasingly used as

low-risk treatments. However, these treatment methods target relatively small tumors and have problems such as a low R0 resection rate [13, 14]. Given that the duodenum experiences more serious adverse events than other parts of the gastrointestinal tract, it would be preferable to follow-up patients with SNDA lesions that have a low malignant potential. Follow-up may be a crucial treatment option, especially in the elderly and patients with various comorbidities.

As per the revised Vienna classification, SNDAs are divided according to the degree of dysplasia as follows: low-grade dysplasia (LGD) is classified as category 3 and high-grade dysplasia (HGD) is classified as category 4.1 [15]. We previously reported that HGD lesions had a high risk of progression to adenocarcinoma (Ad-Ca) with a progression rate of 33.3% within the mean follow-up period of 14 months [16]. These lesions require immediate resection, similar to the treatment for Ad-Ca. In contrast, LGD lesions showed a low risk of progression to Ad-Ca with a progression rate of 4.7% within the mean follow-up period of 29 months [16]. It was demonstrated that a certain number of LGD lesions can be followed up without treatment. However, the natural history of LGD lesions and the characteristics involved in their progression remain unknown, as well as the optimal approach for the clinical management of these lesions. Therefore, this study aimed to analyze the factors associated with progression and determine suitable treatment indications for LGD lesions.

Patients and methods

Study design and patients

Between April 2005 and December 2018, 70,879 patients underwent a total of 234,949 EGD procedures. Overall, 240 patients (0.34%) were diagnosed with SNDA with LGD using endoscopic biopsy at our institution. Patients who met the following criteria were excluded: immediate resection (18 LGD lesions); follow-up <6 months (32 patients); tumors involving the papilla of Vater (45 patients); synchronous lesions (7 patients); history of familial adenomatous polyposis (6 patients); and history of chemotherapy and/or abdominal radiation therapy (7 patients). In total, we retrospectively analyzed 125 lesions in 125 consecutive patients who were followed up for ≥ 6 months and evaluated the clinicopathological features during the follow-up period. At our institution, patients with LGDs were followed up every 6 to 12 months; however, patients with a strong desire for treatment immediately underwent resection. For follow-up patients who did not undergo resection, endoscopic biopsies were often performed when each endoscopist deems it necessary. Endoscopic biopsies were performed by extracting only a small volume sample using pediatric forceps to avoid scarring and fibrosis of the lesion, which may complicate subsequent ER. Moreover, resection was recommended for patients with an increase of ≥ 5 mm in tumor size and/or progression of the histological dysplasia grade during the follow-up period. In addition, from January 2018, the number of resection cases was increasing due to low-risk treatments such as CSP and UEMR.

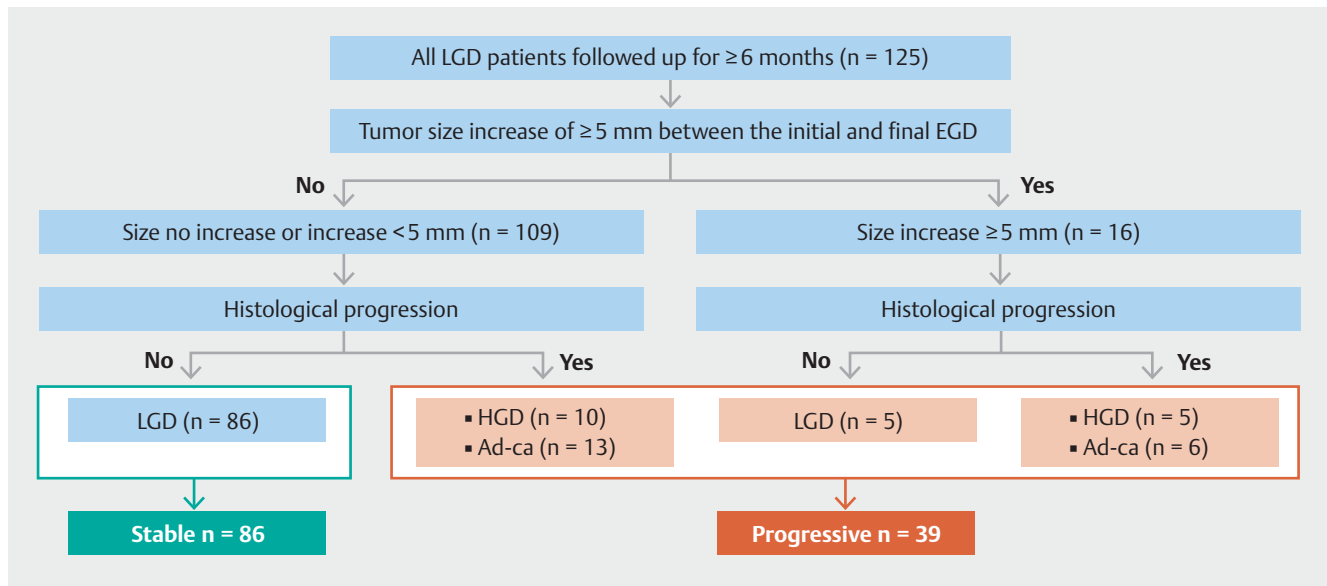
For the 125 LGD lesions, we determined the presence or absence of an increase of ≥ 5 mm in tumor size between the initial

and final EGDs and evaluated the progression of dysplasia grade in the final histological diagnosis. Based on these findings, LGDs were classified into the stable and progressive groups (► **Fig. 1**). Stable LGD was defined as no increase or an increase of <5 mm in tumor size with an unchanged histological dysplasia grade, whereas progressive LGD was defined as an increase of ≥ 5 mm in tumor size and/or progression of the histological dysplasia grade to HGD (category 4.1) or Ad-Ca (category 4.2). Cases without resected specimens or final biopsy were classified as stable or progressive only based on the change in tumor size. After assigning patients to the stable LGD and progressive LGD groups, we stratified the risk of developing progressive LGD into the following three categories: low risk (progression rate, <5%), moderate risk (progression rate, 5%–49%), and high risk (progression rate, $\geq 50\%$). We used the standard routine endoscope (GIF-H290Z and GIF-H260; Olympus Medical Systems, Tokyo, Japan) and standard endoscopic video systems (EVIS LUCERA CV-260/CLV-260 and EVIS LUCERA ELITE CV-290/CLV-290SL; Olympus Medical Systems). Before undergoing EGD, all patients provided comprehensive written informed consent. This study was approved by the Institutional Review Board of the Cancer Institute Hospital of Japanese Foundation for Cancer Research (No. 2018-1114) and has been performed in accordance with ethical standards laid down in the 1964 Declaration of Helsinki and its later amendments.

Clinical and endoscopic evaluation

Patients' clinical data on age, sex, atrophic gastritis, and history of other malignant diseases were obtained. Previous studies have reported that SNADETs are associated with the status of atrophic gastritis [17, 18]. According to the Kimura-Takemoto classification [19], which is widely used to evaluate gastric mucosal atrophy in Japan, we classified patients judged to have C-1 atrophic gastritis or higher as atrophic gastritis regardless of the presence of *Helicobacter pylori*. The EGD data were assessed during the follow-up period, including the number of EGDs and biopsies. The first follow-up EGDs were performed within 6 to 12 months after the initial diagnosis. Subsequent EGDs were performed every 6 to 12 months. The follow-up period was defined as the period from the date of the initial diagnosis of LGD to the final EGD diagnosis.

Endoscopic features such as tumor size, location, macroscopic type, color, nodularity, presence of milk white mucosa, and erosion or ulcer were evaluated with the original report blinded to two experienced endoscopists (Y.I and S.Y). The tumor size was measured using an endoscopic ruler (endoscopic measuring device) or by comparison with the size of the biopsy forceps. The size change was calculated by comparing the initial and final tumor size. The macroscopic type of each lesion was classified based on the Paris endoscopic classification [20]: (i) classified into five categories: protruded type (0-Ip, 0-I_s), elevated type (0-IIa), flat type (0-IIb), depressed type (0-IIc), and mixed elevated and depressed type (0-IIa + IIc) or (ii) classified into two categories: simple type (protruded, elevated, flat, and depressed type) and complex type (mixed elevated and depressed type). The color was described as reddish, whitish, or isochromatic based on the color of the largest area of the tu-



► **Fig. 1** Flowchart for the selection of study participants. LGD, low-grade dysplasia; EGD, esophagogastroduodenoscopy; HGD, high-grade dysplasia; Ad-Ca, adenocarcinoma

mor. Location was classified into (1) four sections (bulbs, descending part [oral-papilla of Vater], descending part [anal-papilla of Vater], and horizontal part) or (2) two areas (oral side and anal side of the papilla of Vater). The change in tumor size between the initial and final endoscopic examination was classified into the following three groups: an increase of ≥ 5 mm, unchanged or an increase of < 5 mm, and shrank or disappeared after biopsies. These data were obtained from medical records and endoscopic findings.

Histopathological evaluation

The histopathological diagnosis was conducted by biopsy or with the resected specimen after follow-up. The final histology was defined as either resected specimen for resected cases or biopsy specimen for non-resected cases. Endoscopic biopsy specimens were collected from the areas that were suggested to be the most dysplastic portion of the lesion, using pediatric forceps. According to the revised Vienna classification, all lesions were classified as LGD (category 3), HGD (category 4.1), or Ad-Ca (category 4.2). The histopathological assessment data were obtained from the original reports diagnosed by two pathologists, including an expert gastrointestinal pathologist.

Statistical analysis

We evaluated the relationship between the clinicopathological parameters using the Mann-Whitney U test, Pearson's chi-square test, or Fisher's exact test. Multivariate analysis was performed for variables with $P < 0.05$ using logistic regression analysis. The cumulative incidence rate of progressive LGD during the follow-up period was calculated according to the Kaplan-Meier method, and the log-rank test was performed for the analysis. All P values were two-tailed, and $P < 0.05$ was considered significant. All calculations were performed using EZR,

version 1.27 (Saitama Medical Center, Jichi Medical University, Japan) [21].

Results

Baseline patient and lesion characteristics

The clinical characteristics of the 125 patients with LGD lesions are shown in ► **Table 1**. The median patient age was 65 years (range, 41–88); 79.2% of the patients were men, and the median follow-up period was 45 months (range, 6–155). The tumors were predominantly located in the descending part (80.0%), of which 66.0% were on the anal side of the papilla of Vater. The median initial tumor size was 6 mm (range, 2–40), and the most frequent macroscopic type was the elevated type (64.0%). Most patients (74.4%) were followed up without treatment, and the remaining 25.6% of patients underwent treatment such as ER or surgical resection (SR) after being followed up for ≥ 6 months. There were 8 lesions (6.4%) that required SR, all of which were local resection including laparoscopic and endoscopic cooperative surgery (LECS) [22]. The reasons for SR were large size (> 20 mm) in four lesions and poor endoscopic maneuverability in four lesions. The final histology was evaluated from biopsy specimens of 50 lesions (40.0%), resected specimens of 32 lesions (25.6%), and no resection and biopsy done in 43 lesions (34.4%). Among the 50 lesions diagnosed from biopsy specimens, 14 lesions were non-neoplastic, eight of which entailed sampling error due to inadequate sample size, and 6 were lesions that disappeared according to the previous biopsies during the study period. Final histology showed progression to HGD or Ad-Ca in 34 lesions (27.2%), and an increase in tumor size of ≥ 5 mm in 16 lesions (12.8%). Five lesions with HGD or Ad-Ca by biopsy and five lesions of tumor size increase ≥ 5 mm were not resected due to patient age, sur-

► **Table 1** Clinical characteristics of the 125 LGD lesions in 125 patients.

Patient characteristics	
Age, median (years), (range)	65 (41–88)
Sex, n (%)	
▪ Male	99 (79.2)
▪ Female	26 (20.8)
Gastric atrophy, n (%)	70 (57.6)
Other malignant diseases, n (%)	76 (60.8)
Lesion characteristics	
▪ Follow-up period, median (months), (range)	45 (6–155)
▪ Number of EGDs, median (range)	5 (2–17)
▪ Number of biopsies, median (range)	2 (1–14)
Location (portion of the duodenum), n (%)	
▪ Bulbs	13 (10.4)
▪ Descending part (oral papilla of Vater)	34 (27.2)
▪ Descending part (anal papilla of Vater)	66 (52.8)
▪ Horizontal part	12 (9.6)
Tumor size, median (mm) (range)	6 (2–40)
▪ Tumor size ≥ 10 mm, n (%)	41 (32.8)
▪ Tumor size < 10 mm, n (%)	84 (67.2)
Macroscopic type, n (%)	
▪ Protruded (0-Is, 0-Ip)	11 (8.8)
▪ Elevated (0-IIa)	80 (64.0)
▪ Flat (0-IIb)	6 (4.8)
▪ Depressed (0-IIc)	19 (15.2)
▪ Mixed elevated and depressed (0-IIa + IIc)	9 (7.2)
Color, n (%)	
▪ White/isochromatic	103 (82.4)
▪ Red	22 (17.6)
Nodularity, n (%)	
▪ Yes	16 (12.8)
▪ No	109 (87.2)
Erosion or ulcer, n (%)	
▪ Yes	3 (2.4)
▪ No	122 (97.6)
Treatment method, n (%)	
▪ Follow-up without treatment	93 (74.4)
▪ Endoscopic resection	24 (19.2)
▪ Surgical resection	8 (6.4)

► **Table 1** (Continuation)

Patient characteristics			
Final histology, n (%)	Biopsy	Resection	Total
▪ LGD (category 3)	31 (24.8)	3 (2.4)	34 (27.2)
▪ HGD (category 4.1)	3 (2.4)	12 (9.6)	15 (12.0)
▪ Ad-Ca (category 4.2)	2 (1.6)	17 (13.6)	19 (15.2)
▪ Non-neoplastic lesion	14 (11.2)	0 (0)	14 (11.2)
No biopsy and resection done			43 (34.4)
Tumor size increase, n (%)			
▪ No change or increase of < 5 mm			80 (64.0)
▪ Increase of ≥ 5 mm			16 (12.8)
▪ Shrank or disappeared after biopsies			29 (23.2)
EGD, esophagogastroduodenoscopy; LGD, low-grade dysplasia; HGD, high-grade dysplasia; Ad-Ca, adenocarcinoma.			

gical tolerance, and patient refusal of treatment. There was no case of submucosal invasive carcinoma.

Comparison of clinical characteristics between stable and progressive LGD

Among 125 patients, 86 patients were classified into the stable LGD group and 39 patients into the progressive LGD group. The results of univariate analysis between stable and progressive LGD groups are summarized in ► **Table 2**. There were no significant differences in age, sex, other malignant diseases, erosion, or ulcer findings between the two groups. Gastric atrophy was significantly less frequent in the progressive LGD group than in the stable LGD group (37.2% vs. 59.0%, $P=0.019$). The median follow-up period was significantly longer in the stable LGD group than in the progressive LGD group (58 vs. 32 months, $P<0.001$), and the number of EGDs was significantly higher in the stable LGD group than in the progressive LGD group (6 vs. 4, $P=0.009$). The initial median tumor size was significantly larger in the progressive LGD group than in the stable LGD group (10 mm vs. 5 mm, $P<0.001$). Tumor location on the oral side of the papilla of Vater (61.5% vs. 26.7%, $P<0.001$), large initial tumor size (≥ 10 mm) (71.8% vs. 15.1%, $P<0.001$), macroscopically complex type (20.5% vs. 1.2%, $P<0.001$), red color (33.3% vs. 10.5%, $P=0.042$), and nodularity (30.8% vs. 4.7%, $P<0.001$) were all significantly more frequent in the progressive LGD group than in the stable LGD group.

The results of multivariate analysis are summarized in ► **Table 3**. Large initial tumor size (≥ 10 mm) (odds ratio [OR], 10.20; 95% confidence interval CI, 3.25–32.10; $P<0.001$) and tumor location on the oral side of the papilla of Vater (OR, 1.83, 4.13; 95% CI, 1.36–12.50; $P=0.012$) were significant factors for progression. There were no significant differences in the frequency of gastric atrophy, red color, complex type, or nodularity.

► **Table 2** Clinical characteristics of stable LGD vs. progressive LGD

	Stable LGD (n = 86)	Progressive LGD (n = 39)	P value
Patient characteristics			
Age, median (years), (range)	65 (41–88)	63 (44–85)	0.36
Sex, n (%)			
▪ Male	69 (80.2)	30 (76.9)	0.81
▪ Female	17 (19.8)	9 (23.1)	
Gastric atrophy, n (%)	54 (62.8)	16 (41.0)	0.019¹
Other malignant diseases, n (%)	55 (64.0)	21 (53.8)	0.33
Lesion characteristics			
▪ Follow-up period, median (months), (range)	58 (8–155)	32 (6–140)	<0.001¹
▪ Number of EGDs, median (range)	6 (2–17)	4 (2–12)	0.006¹
▪ Number of biopsies, median (range)	2 (1–11)	3 (1–14)	0.007¹
Location relative to the papilla of Vater, n (%)			
▪ Oral side	23 (26.7)	24 (61.5)	<0.001¹
▪ Anal side	63 (73.3)	15 (38.5)	
Tumor size, median (mm) (range)	5 (2–20)	10 (3–40)	<0.001¹
▪ Tumor size ≥ 10, n (%)	13 (15.1)	28 (71.8)	<0.001¹
▪ Tumor size < 10, n (%)	73 (84.9)	11 (28.2)	
Macroscopic type, n (%)			
▪ Simple type	85 (98.8)	31 (79.5)	<0.001¹
▪ Complex type	1 (1.2)	8 (20.5)	
Color, n (%)			
▪ White/isochromatic	77 (89.5)	26 (66.7)	0.004¹
▪ Red	9 (10.5)	13 (33.3)	
Nodularity, n (%)			
▪ Yes	4 (4.7)	12 (30.8)	<0.001¹
▪ No	82 (95.3)	27 (69.2)	
Erosion or ulcer, n (%)			
▪ Yes	1 (1.2)	2 (5.1)	0.23
▪ No	85 (98.8)	37 (94.9)	

LGD, low-grade dysplasia; EGD, esophagogastroduodenoscopy.
¹ Statistically significant values.

Risk stratification of stable and progressive LGD by initial tumor size and location

► **Table 4** summarizes the rate of progression by the initial tumor size and location. From these results, the risk of progression was stratified as follows:

- Low risk (progression rate, <5%): all LGD lesions measuring <5 mm
- Moderate risk (progression rate, 5%–49%): all LDG lesions measuring 5–9 mm, and LGD lesions measuring 10–19 mm located on the anal side of the papilla of Vater
- High risk (progression rate, ≥50%): LGD lesions measuring 10–19 mm located on the oral side of the papilla of Vater and all LGD lesions measuring ≥20 mm

► **Table 3** Multivariate analysis of the risk factors for progression.

	Odds ratio	95% CI	Pvalue
No gastric atrophy	2.23	0.76–6.57	0.14
Size ≥ 10 mm	10.20	3.25–32.10	<0.001 ¹
Oral side of the papilla of Vater	4.13	1.36–12.50	0.012 ¹
Macroscopically complex type	8.66	0.83–90.70	0.071
Red color	3.01	0.79–11.50	0.11
Nodularity	2.63	0.61–11.40	0.20

CI, confidence interval.
¹ Statistically significant values.

► **Table 4** Progression rate of LGD lesions by initial tumor size and location.

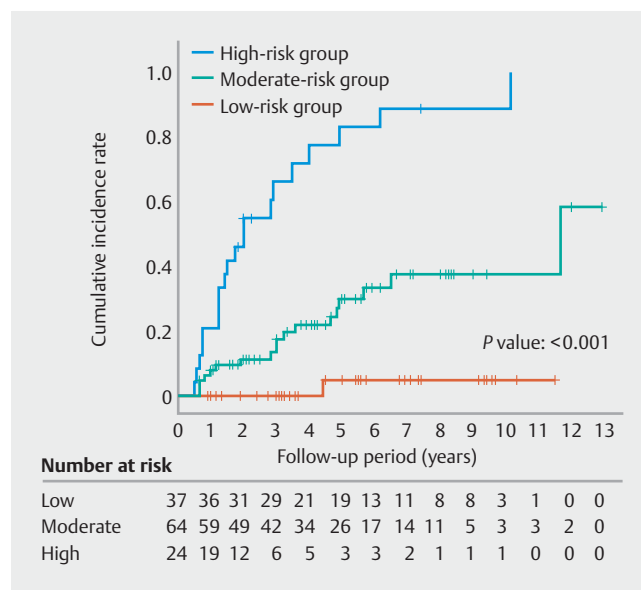
	<5 mm	5–9 mm	10–19 mm	≥20 mm
Oral side of the papilla of Vater, % (n/N)	0% (0/8)	36.8% (7/19)	85.7% (12/14)	83.5% (5/6)
Anal side of the papilla of Vater, % (n/N)	3.4% (1/29)	10.7% (3/28)	47.1% (8/17)	75.0% (3/4)
Total, % (n/N)	2.7% (1/37)	21.3% (10/47)	64.5% (20/31)	80.0% (8/10)

LGD, low-grade dysplasia; n, number of progressive LGD lesions; N, number of total LGD lesions.

When stratified according to the above definitions, there were 37, 64, and 24 cases in the low-risk, moderate-risk, and high-risk groups, respectively. The cumulative incidence of progressive LGD at 1 and 3 years in the low-risk group was both 0%, while in the moderate-risk and high-risk groups, it was 7.9% (95% CI, 3.4–17.9%) and 17.5% (95% CI, 9.7–30.3%), as well as 20.8% (95% CI, 9.2–43.0%) and 66.1% (95% CI, 46.3–84.8%), respectively. There was a significant difference in the incidence of LGD progression among the low-risk, moderate-risk, and high-risk groups ($P < 0.001$) (► **Fig. 2**). In the moderate-risk group, all cases that had progressed at 1 year were treated by complete resection of the tumor with ER (4 HGDs and 1 Ad-Ca).

Discussion

The natural history of SNDAs has not been studied in detail. In our previous study of 68 cases of SNDAs, we reported that SNDAs measuring ≥20 mm and HGD lesions at initial biopsy were prognostic factors for the development of Ad-Ca [16]. In another study comparing the histological results of preoperative biopsies with the results of SNADET resection specimens, the dysplasia grade was upgraded in 36% of the resected specimens, most of which were changed from HGD to Ad-Ca [23]. This suggests that HGD lesions should be aggressively resected because there is a higher possibility that HGD lesions exhibit the Ad-Ca component, in addition to the risk of progression to Ad-Ca. In contrast, LGD lesions were reported to progress to HGD or Ad-Ca; however, the frequency was estimated to be lower than that of HGA. In the present study, we analyzed 125 patients with LGD lesions who were followed up for ≥6 months,



► **Fig. 2** Cumulative incidence of progressive LGD. a High-risk group (blue line) vs. moderate-risk group (green line) vs. low-risk group (red line). Rates of 1-year incidence are 0%, 7.9% (95% CI, 3.4–17.9%), and 20.8% (95% CI, 9.2–43.0%) for the low-, moderate-, and high-risk groups, respectively. Similarly, the 3-year incidence rates are 0%, 17.5% (95% CI, 9.7–30.3%), and 66.1% (95% CI, 46.3–84.8%) for the low-, moderate-, and high-risk groups, respectively. There is a significant difference in the incidence of progression among the low-, moderate-, and high-risk groups with the log-rank test ($P < 0.001$). LGD, low-grade dysplasia; CI, confidence interval.

and the progression rate was 31% (39/125) during a median follow-up period of 45 months. This is a valuable study to analyze the natural history of LGD lesions.

In several other digestive tract diseases, there is an established consensus on the indication for resection of adenomas. With regard to colorectal adenomas, resecting all adenomas reduced the mortality rate from colorectal cancer by 53% and improved the prognosis. Therefore, resection is typically recommended for all adenomas [24]. In contrast, gastric adenomas have different clinical management strategies depending on the dysplasia grade. It was reported that gastric HGD lesions have a high risk of progression to invasive Ad-Ca; therefore, resection of HGD lesions is usually recommended. Conversely, gastric LGD lesions have a very low risk of progression; hence, regular follow-up is recommended [25, 26]. As with gastric adenomas, resection is recommended for duodenal HGD lesions, whereas the current treatment indication for duodenal LGD lesions is controversial because the progression risk of LGD lesions is unclear. Duodenal ER is technically difficult and risky compared with ER for other gastrointestinal tumors, owing to the thin wall, narrow lumen, and poor endoscopic maneuverability [6–12]. Therefore, the benefits of resecting all LGD lesions may be small. It is preferable to first consider whether patients with LGD lesions are suitable for follow-up, and if not, then resection should be offered.

Goda et al. [5] previously described the endoscopic features of LGDs, such as tumor size, location, color, and macroscopic type. Consistent with this report, our study showed that a high proportion of LGD lesions located in the descending part were isochromatic or white and were of the macroscopically elevated type (0-IIa). In our study, tumors measuring ≥ 10 mm and located on the oral side of the papilla of Vater were significant predictors of progressive LGD. Previous studies have reported that tumor size was associated with the degree of dysplasia [5]; in particular, a tumor measuring ≥ 10 mm was reported as a factor for predicting HGD/Ad-Ca [27], findings that were consistent with those of our report. The malignancy of SNADEts differed between tumors on the oral side and the anal side of the papilla of Vater. Although various tumors with gastric phenotype were located on the oral side of the papilla of Vater, rather than on the anal side, immunohistochemical analysis revealed that tumors with gastric phenotype have a higher proportion of Ad-Ca than those with intestinal phenotype [28]. Therefore, SNADEts on the oral side of the papilla of Vater were more frequently seen to possess high malignancy potential [28–31]. In our study, LGD lesions on the oral side showed significant progression when compared with those on the anal side. In the future, we plan to conduct detailed histopathological research, including immunohistochemical staining, to reveal whether the tumor immunophenotype correlates with LGD lesion malignancy. Furthermore, we will analyze whether an immunohistochemical evaluation in preoperative biopsy can be used as a predictor of the risk of tumor progression. The present study will serve as a foundation for subsequent research in this field.

As ER of duodenal tumors is associated with a high risk of adverse events, as described above, it is crucial to consider the risks and benefits of this treatment. We classified risk progres-

sion as “low risk,” “moderate risk,” and “high risk” by considering the initial tumor size and location, which were independent variables predictive of progression as per the results of the multivariate analysis (► **Table 3**). The cumulative incidence of progressive LGD at 1 and 3 years in the “low-risk” group was 0% and 0%, respectively. Therefore, for the low-risk group, especially in elderly patients with multiple comorbidities, we believe that aggressive resection of all LDG lesions is unnecessary, and patients can be followed up without undergoing resection. Considering the occidental healthcare system, the low-risk group has a progressive risk $< 5\%$; therefore, follow-up endoscopy may be performed once every 3 years. The moderate-risk group did not have a high progression risk; hence, it will be a good target for CSP and UEMR, which are highly safe ER procedures. Follow-up may be an option; however, routine EGDs are critical. Meanwhile, resection of the tumor in the high-risk group is warranted because almost all LGD lesions in this category had the possibility of progression at some point.

This study had some limitations. First, in this study, biopsy was performed when necessary to evaluate progression. Previously, biopsy diagnosis was the standard method; however, recent studies have reported that endoscopic diagnosis is as accurate as or better than biopsy diagnosis [5, 32]. In the future, follow-up without biopsy may become the standard strategy. Second, the final histology was diagnosed in both biopsy and resected specimens. Third, several cases were classified as stable or progressive only by size change. This could underestimate progressive LGD. Fourth, this was a non-randomized, retrospective, single-center study. Therefore, biases may be present; the follow-up interval and measurement method of the tumor size were not unified in the study period. Fifth, the median observation period of this study was 45 months. Therefore, the follow-up results over a longer term, such as > 5 years, cannot be predicted. To reduce these biases, it will be necessary to establish unified diagnostic criteria and a multicenter randomized controlled trial is needed.

Conclusions

In conclusion, the present study demonstrated that large initial tumor size (≥ 10 mm) and location on the oral side of the papilla of Vater were significant progression factors for LGD lesions. According to the risk stratification of progression factors by size and location, all LGD lesions with a tumor measuring < 5 mm rarely progressed; therefore, follow-up of patients without treatment is acceptable. All LGD lesions with tumors measuring ≥ 20 mm and 10 to 19 mm located on the oral side of the papilla of Vater have a high risk of progression, and immediate resection is, therefore, recommended.

Competing interests

The authors declare that they have no conflict of interest.

References

- [1] Darling RC, Welch CE. Tumors of the small intestine. *N Engl J Med* 1959; 260: 397–408
- [2] Hoffman BP, Grayzel DM. Benign tumors of the duodenum. *Am J Surg* 1945; 70: 394–400
- [3] Shukla SK, Elias EG. Primary neoplasms of the duodenum. *Surg Gynecol Obstet* 1976; 142: 858–860
- [4] Murray MA, Zimmerman MJ, Ee HC. Sporadic duodenal adenoma is associated with colorectal neoplasia. *Gut* 2004; 53: 261–265
- [5] Goda K, Kikuchi D, Yamamoto Y et al. Endoscopic diagnosis of superficial non-ampullary duodenal epithelial tumors in Japan: Multicenter case series. *Dig Endosc* 2014; 26: 23–29
- [6] Takahashi T, Ando T, Kabeshima Y et al. Borderline cases between benignancy and malignancy of the duodenum diagnosed successfully by endoscopic submucosal dissection. *Scand J Gastroenterol* 2009; 44: 1377–1383
- [7] Nonaka S, Oda I, Tada K et al. Clinical outcome of endoscopic resection for nonampullary duodenal tumors. *Endoscopy* 2015; 47: 129–135
- [8] Hoteya S, Kaise M, Iizuka T et al. Delayed bleeding after endoscopic submucosal dissection for non-ampullary superficial duodenal neoplasias might be prevented by prophylactic endoscopic closure: Analysis of risk factors. *Dig Endosc* 2015; 27: 323–330
- [9] Hoteya S, Furuhashi T, Takahito T et al. Endoscopic submucosal dissection and endoscopic mucosal resection for non-ampullary superficial duodenal tumor. *Digestion* 2017; 95: 36–42
- [10] Yahagi N, Kato M, Ochiai Y et al. Outcomes of endoscopic resection for superficial duodenal epithelial neoplasia. *Gastrointest Endosc* 2018; 88: 676–682
- [11] Kato M, Ochiai Y, Fukuhara S et al. Clinical impact of closure of the mucosal defect after duodenal endoscopic submucosal dissection. *Gastrointest Endosc* 2019; 89: 87–93
- [12] Yamamoto Y, Yoshizawa N, Tomida H et al. Therapeutic outcomes of endoscopic resection for superficial non-ampullary duodenal tumor. *Dig Endosc* 2014; 26: 50–56
- [13] Maruoka D, Matsumura T, Kasamatsu S et al. Cold polypectomy for duodenal adenomas: a prospective clinical trial. *Endoscopy* 2017; 49: 776–783
- [14] Kiguchi Y, Kato M, Nakayama A et al. Feasibility study comparing underwater endoscopic mucosal resection and conventional endoscopic mucosal resection for superficial non-ampullary duodenal epithelial tumor < 20 mm. *Dig Endosc* 2020; 32: 753–760
- [15] Dixon MF. Gastrointestinal epithelial neoplasia: Vienna revisited. *Gut* 2002; 51: 130–131
- [16] Okada K, Fujisaki J, Kasuga A et al. Sporadic nonampullary duodenal adenoma in the natural history of duodenal cancer: a study of follow-up surveillance. *Am J Gastroenterol* 2011; 106: 357–364
- [17] Kakushima N, Ono H, Yoshida M et al. Characteristics and risk factors for sporadic non-ampullary duodenal adenocarcinoma. *Scand J Gastroenterol* 2017; 52: 1253–1257
- [18] Kawai T, Takeuchi M, Fukuzawa M. Gastric atrophy prevent from incidence of duodenal tumor? *J Clin Biochem Nutr* 2017; 60: 219
- [19] Kimura K, Takemoto T. An endoscopic recognition of the atrophic border and its significance in chronic gastritis. *Endoscopy* 1969; 1: 87–97
- [20] Participants in the Paris Workshop. The Paris endoscopic classification of superficial neoplastic lesions: esophagus, stomach, and colon: November 30 to December 1, 2002. *Gastrointest Endosc* 2003; 58: S3–S43
- [21] Kanada Y. Investigation of the freely available easy-to-use software “EZR” for medical statistics. *Bone Marrow Transplant* 2013; 48: 452–458
- [22] Nunobe S, Ri M, Yamazaki K et al. Safety and feasibility of laparoscopic and endoscopic cooperative surgery for duodenal neoplasm: a retrospective multicenter study. *Endoscopy* 2020; doi:10.1055/a-1327-5939
- [23] Kakushima N, Ono H, Takao T et al. Method and timing of resection of superficial non-ampullary duodenal epithelial tumors. *Dig Endosc* 2014; 26: 35–40
- [24] Zauber AG, Winawer SJ, O'Brien MJ et al. Colonoscopic polypectomy and long-term prevention of colorectal-cancer deaths. *N Engl J Med* 2012; 366: 687–696
- [25] Taniyama D, Taniyama K, Kuraoka K et al. Long-term follow-up study of gastric adenoma; tumor-associated macrophages are associated to carcinoma development in gastric adenoma. *Gastric Cancer* 2017; 20: 929–939
- [26] Yamada H, Ikegami M, Shimoda T et al. Long-term follow-up study of gastric adenoma/dysplasia. *Endoscopy* 2004; 36: 390–396
- [27] Kakushima N, Yoshida M, Iwai T et al. A simple endoscopic scoring system to differentiate between duodenal adenoma and carcinoma. *Endosc Int Open* 2017; 5: E763–E768
- [28] Yoshida M, Shimoda T, Abe M et al. Clinicopathological characteristics of non-ampullary duodenal tumors and their phenotypic classification. *Pathol Int* 2019; 69: 398–406
- [29] Minatsuki C, Yamamichi N, Inada KI et al. Expression of gastric markers is associated with malignant potential of nonampullary duodenal adenocarcinoma. *Dig Dis Sci* 2018; 63: 2617–2625
- [30] Ushiku T, Arnason T, Fukayama M et al. Extra-ampullary duodenal adenocarcinoma. *Am J Surg Pathol* 2014; 38: 1484–1493
- [31] Yoshimizu S, Kawachi H, Yamamoto Y et al. Clinicopathological features and risk factors for lymph node metastasis in early-stage non-ampullary duodenal adenocarcinoma. *J Gastroenterol* 2020; 55: 754–762
- [32] Kakushima N, Kanemoto H, Sasaki K et al. Endoscopic and biopsy diagnoses of superficial, nonampullary, duodenal adenocarcinomas. *World J Gastroenterol* 2015; 21: 5560–5567