

Pharmacological Evaluation of Hepatoprotective Activity of AHPL/AYTAB/0613 Tablet in Carbon Tetrachloride-, Ethanol-, and Paracetamol-Induced Hepatotoxicity Models in Wistar Albino Rats

Sanjay U. Nipanikar, Sohan S. Chitlange¹, Dheeraj Nagore

R and D Center, Ari Healthcare Private Limited, Hinjewadi, ¹Department of Pharmaceutical Chemistry and Quality Assurance Tech, Padmashree Dr. D. Y. Patil Institute of Pharmaceutical Sciences and Research, Pune, Maharashtra, India

ABSTRACT

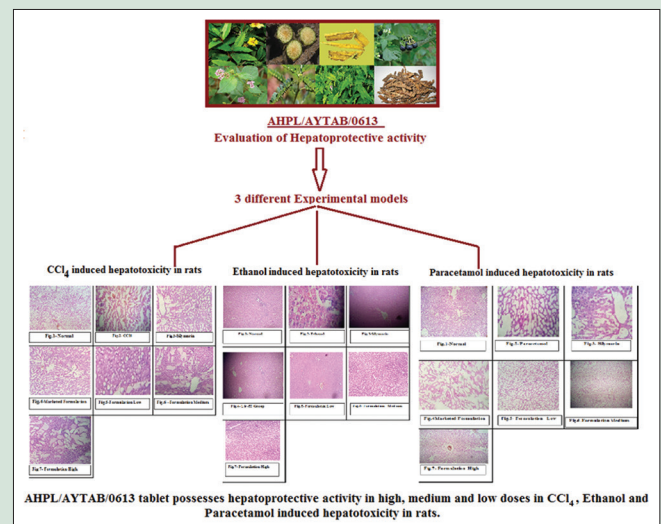
Background: Hepatotoxicity ultimately leads to liver failure. Conventional treatment options for hepatotoxicity are limited and not safe. **Objective:** Formulation AHPL/AYTAB/0613 is developed to provide safer and effective hepatoprotective drug of natural origin. A study was conducted to evaluate hepatoprotective activity of AHPL/AYTAB/0613 (three dosages) in comparison with marketed formulations in carbon tetrachloride (CCl₄), ethanol, and paracetamol-induced hepatotoxicity in Wistar albino rats. **Materials and Methods:** Three separate studies were conducted in models of CCl₄, ethanol, and paracetamol-induced hepatotoxicity. Seven groups of animals were studied comparatively to evaluate the efficacy of AHPL/AYTAB/0613 in low, medium, and high dosage in comparison with silymarin and a marketed polyherbal formulation. The drugs were orally administered to rats for 10 days in CCl₄ model and for 14 days in ethanol and paracetamol models. Animals were weighed periodically. After the study period, blood was tested for serum glutamic-oxaloacetic transaminase (SGOT), serum glutamic pyruvic transaminase (SGPT), alkaline phosphatase (ALP), total bilirubin, and total protein levels. Liver tissue of sacrificed animals was examined histopathologically. **Results:** All the test formulations including all three dosages of AHPL/AYTAB/0613, significantly reduced levels of SGOT, SGPT, ALP, total bilirubin, in CCl₄, ethanol, and paracetamol-induced hepatotoxicity models. There was significant increase in total protein level in all the tested formulations. All the test formulations effectively preserved the structural integrity of the hepatocellular membrane and liver cell architecture damaged by CCl₄, ethanol, and paracetamol. When compared between groups, no statistically significant difference was observed. It can be concluded that AHPL/AYTAB/0613 possesses hepatoprotective activity in CCl₄, ethanol, and paracetamol-induced hepatotoxicity in rats. **Conclusion:** AHPL/AYTAB/0613 can be effectively used as a hepatoprotective agent in the management of hepatitis caused due to various toxins.

Key words: AHPL/AYTAB/0613, carbon tetrachloride, ethanol, hepatoprotective, paracetamol, polyherbal

SUMMARY

A polyherbal formulation AHPL/AYTAB/0613 containing *Bhringaraja* - *Eclipta alba* extract, *Guduchi* - *Tinospora cordifolia* extract, *Daruharidra* - *Berberis aristata* extract, *Kakamachi* - *Solanum nigrum* extract, *Punarnava* - *Boerhaavia diffusa* extract, *Bhumyamalaki* - *Phyllanthus niruri* extract, *Kutki* - *Picrorhiza kurroa* extract, and *Kalmegha* - *Andrographis paniculata* extract was assessed for its hepatoprotective activity. This activity was tested in carbon tetrachloride (CCl₄), ethanol, and paracetamol-induced hepatotoxicity models in Wistar albino rats in comparison with two marketed formulations. It was observed that AHPL/AYTAB/0613 significantly reduced levels of serum glutamic-oxaloacetic transaminase, serum glutamic pyruvic transaminase, alkaline phosphatase, total bilirubin and also significantly increased total protein level. All the test

formulations effectively preserved the structural integrity of the hepatocellular membrane and liver cell architecture damaged by CCl₄, ethanol, and paracetamol. When compared between groups, no statistically significant difference was observed. Therefore, it was concluded that AHPL/AYTAB/0613 possesses hepatoprotective activity in CCl₄, ethanol, and paracetamol-induced hepatotoxicity in rats.



Abbreviations Used: CCl₄: Carbon tetrachloride, SGOT: Serum glutamic-oxaloacetic transaminase, SGPT: Serum glutamic pyruvic transaminase, ALP: Alkaline phosphatase, UDCA: Ursodeoxycholic acid, US: United States, FDA: Food and Drug Administration, PBC: Primary biliary cirrhosis, GSTA1: Glutathione S-transferase A1, GSH: Glutathione, GPx: Glutathione peroxidase, GST: Glutathione S-transferases.

Correspondence:

Dr. Sanjay U. Nipanikar,
R and D Center, Ari Healthcare Private Limited,
Unit No. 401, International Biotech Park,
BTS 2 Building, Chrysalis Enclave, 4th Floor,
Plot No. 2A, MIDC Phase II, Hinjewadi,
Pune - 411 057, Maharashtra, India.
E-mail: sanjay.n@arihealthcare.in
DOI: 10.4103/pr.pr_44_17

Access this article online

Website: www.phcogres.com

Quick Response Code:



INTRODUCTION

Liver is the largest organ in the human body. It performs more than 500 metabolic functions. Synthesis, storage, transformation, and clearance of various chemical compounds and their metabolites are important metabolic functions performed by liver that also make it highly susceptible to injury caused by any of them. It produces a substance called bile that is excreted outside body through intestinal tract. Bile carries various toxic substances produced in the metabolism

This is an open access article distributed under the terms of the Creative Commons Attribution-NonCommercial-ShareAlike 3.0 License, which allows others to remix, tweak, and build upon the work non-commercially, as long as the author is credited and the new creations are licensed under the identical terms.

For reprints contact: reprints@medknow.com

Cite this article as: Nipanikar SU, Chitlange SS, Nagore D. Pharmacological evaluation of hepatoprotective activity of AHPL/AYTAB/0613 tablet in carbon tetrachloride-, ethanol-, and paracetamol-induced hepatotoxicity models in Wistar albino rats. Phcog Res 2017;9:S41-7.

that needs to be timely removed out of the body. Hence, any damage to the liver cells hampers formation of bile and removal of such toxic substances through it. Their accumulation ultimately leads to further damage to the liver and whole body.^[1]

Hepatotoxicants are chemicals that cause liver cell injury. These could be industrial chemicals, natural chemicals, overdose of certain medicinal drugs, and dietary supplements or even pesticides. Some drugs may cause liver damage even when used within therapeutic range.^[2] Hepatotoxic response is expressed in the characteristic form of cell death in specific zones of acinar regions in liver. Liver injury in hepatotoxicity may include patterns such as zonal necrosis, hepatitis, cholestasis, steatosis, granuloma, vascular lesions, neoplasm and veno-occlusive diseases. These patterns give rise to the manifestation of symptoms such as jaundice, pruritus, severe abdominal pain, nausea, vomiting, continuous bleeding, skin rashes, generalized itching, weakness, severe fatigue, dark urine, and light-colored stool.^[1]

The available synthetic drugs to treat liver disorders in this condition may further worsen the liver damage as they too need to get metabolized in previously damaged liver.^[3] This increases the load on liver function and desired action of drug may not be observed. Steroids, vaccines, and antiviral drugs used as therapies for liver pathologies have potential adverse effects, especially if administered chronically or sub-chronically.^[4] Hence, developing pharmacologically effective agents from natural products has become a necessity by virtue of its comparatively low toxicity or fewer side effects. There are few plant-derived drugs in the market which are used in liver disorders.

AHPL/AYTAB/0613 tablet is a polyherbal formulation conceptualized and developed by Ari Healthcare Private Limited as a hepatoprotective agent for the management of jaundice, hepatitis and alcoholic liver disease. It contains *Bhringaraja - Eclipta alba* extract (*Asteraceae*), *Guduchi - Tinospora cordifolia* extract (*Menispermaceae*), *Daruharidra - Berberis aristata* extract (*Berberidaceae*), *Kakamachi - Solanum nigrum* extract (*Solanaceae*), *Punarnava - Boerhaavia diffusa* extract (*Nyctaginaceae*), *Bhumyamalaki - Phyllanthus niruri* extract (*Euphorbiaceae*), *Kutki - Picrorhiza kurroa* extract (*Plantaginaceae*), and *Kalmegh - Andrographis paniculata* extract (*Acanthaceae*). All ingredients have demonstrated hepatoprotective activities in isolation.

The present study was planned to evaluate the hepatoprotective activity of AHPL/AYTAB/0613 in comparison with marketed formulations in three different experimental models, i.e., carbon tetrachloride (CCl₄)-induced hepatotoxicity, ethanol-induced hepatotoxicity, and paracetamol-induced hepatotoxicity in experimental animals.

MATERIALS AND METHODS

Ethical considerations

The study was conducted at Padmashree Dr. D. Y. Patil Institute of Pharmaceutical Sciences and Research, Pimpri, Pune - 411 018. The Institutional Animal Ethics Committee (IAEC) had approved the study in the meeting held on 30th December 2014. The protocol no. approved was DYPIPSR/IAEC/14-15/P-02.

Methodology

90 male albino wistar rats weighing 200-250 g were selected for the study. All these rats were divided into seven groups to include in all the three models of hepatotoxicity induced with CCl₄, ethanol and paracetamol. Among the seven groups, Group I animals served as normal control, animals belonging to Group II served as positive control, animals belonging to Group III served as standard I and

animals belonging to Group IV served as Standard II. Rest of the groups received different doses (low dose, mid dose, and high dose) of test formulation (AHPL/AYTAB/0613). All the groups were orally administered formulations as given in Table 1.

Hepatotoxicity was induced in rats by administering 30% CCl₄ (1 ml/kg) orally for 10 days, oral administration of 50% ethanol (2 ml) for 14 days, orally administering paracetamol (2 g/kg body weight) for 10 days period in respective models of hepatotoxicity [Table 1].

All the animals were weighed before (day 1), during (day 5/7), and after (day 10/14) the drug treatment. After completion of the treatment, animals were anaesthetized under light ether anesthesia. Blood was collected by retro-orbital plexus puncture. Biochemical estimations of various parameters such as total proteins, total bilirubin, serum glutamic-oxaloacetic transaminase (SGOT), serum glutamic pyruvic transaminase (SGPT), and alkaline phosphatase (ALP) using serum were assessed. Animals were sacrificed, and liver was removed, weighed and perfused in ice-cold saline solution for histopathology studies.

RESULTS

Effect of various formulations on body weight in carbon tetrachloride induced hepatotoxicity in rats

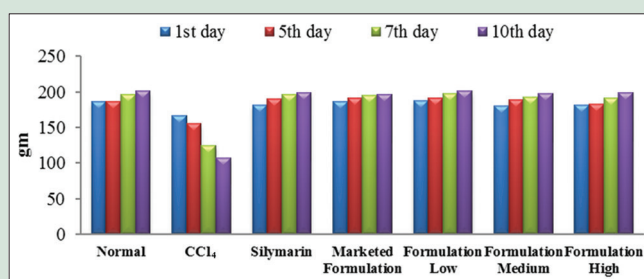
The animals from normal control group showed gradual increase in weight over the period of 10 days whereas those intoxicated with CCl₄ showed significant weight reduction throughout the study period. All other groups, where medication was given along with CCl₄ significantly improved the body weight of animals which was close to the body weight of animals of normal control group. When compared between the formulation groups, no statistically significant difference was noted [Graph 1].

Effect of various formulations on body weight in ethanol-induced hepatotoxicity in rats

It is evident from the results of the study that the mean body weight of the rats in ethanol group increased significantly over the period of 14 days when compared to animals of normal group. No such significant weight gain was observed in animals of formulation group when compared to ethanol group. When compared between formulation groups no significant difference was observed [Graph 2].

Effect of various formulations on body weight in paracetamol-induced hepatotoxicity in rats

It was observed from the results of the study that, the rate of weight gain on day 7 was slower in paracetamol group when compared to normal group. However, no significant difference was observed on day 14. All the formulation groups showed significant increase in mean body weight when compared to paracetamol and normal group on 7th day of treatment.

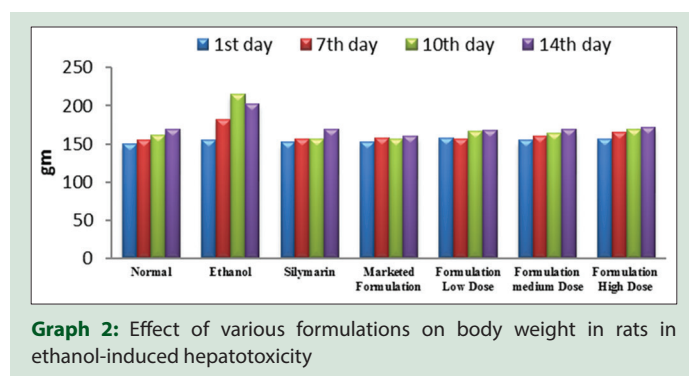


Graph 1: Effect of various formulations on body weight in rats in carbon tetrachloride-induced hepatotoxicity

Table 1: Dosage of orally administered drugs in various groups in carbon tetrachloride-, ethanol- and paracetamol-induced hepatotoxicity models

Groups	Treatment in CCl ₄ model (10 days)	Treatment in ethanol model (14 days)	Treatment in paracetamol model (14 days)
I (normal control)	Saline water	Saline water	Saline water
II (positive control)	30% CCl ₄ (1 ml/kg) for 10 days	50% ethanol (2 ml)	Paracetamol (2 g/kg body weight)
III (standard I)	Silymarin (25 mg/kg body weight) + 30% CCl ₄ (1 ml/kg)	Silymarin (25 mg/kg body weight) + 50% ethanol (2 ml)	Silymarin (25 mg/kg body weight) + paracetamol (2 g/kg body weight)
IV (standard II)	Marketed formulation (54 mg/kg body weight) + 30% CCl ₄ (1 ml/kg)	Marketed formulation (54 mg/kg body weight) + 50% ethanol (2 ml)	Marketed formulation (54 mg/kg body weight) + paracetamol (2 g/kg body weight)
V (formulation low dose)	Formulation low dose (110 mg/kg body weight) + 30% CCl ₄ (1 ml/kg)	Formulation low dose (110 mg/kg body weight) + 50% ethanol (2 ml)	Formulation low dose (110 mg/kg body weight) + paracetamol (2 g/kg body weight)
VI (formulation medium dose)	Formulation medium dose (220 mg/kg body weight) + 30% CCl ₄ (1 ml/kg)	Formulation medium dose (220 mg/kg body weight) + 50% ethanol (2 ml)	Formulation medium dose (220 mg/kg body weight) + paracetamol (2 g/kg body weight)
VII (formulation high dose)	Formulation high dose (440 mg/kg body weight) + 30% CCl ₄ (1 ml/kg)	Formulation high dose (440 mg/kg body weight) + 50% ethanol (2 ml)	Formulation high dose (440 mg/kg body weight) + paracetamol (2 g/kg body weight)

CCl₄: Carbon tetrachloride



Graph 2: Effect of various formulations on body weight in rats in ethanol-induced hepatotoxicity

No significant difference was observed on 14th day of treatment. All the formulations were able to maintain normal body weight [Graph 3].

Effect of various formulations on liver weight in various hepatotoxicity models

All the animals in groups treated with CCl₄, ethanol, and paracetamol showed increase in liver weight when compared to that of normal control group in respective studies. This is in line with the fact that CCl₄, ethanol, and paracetamol give rise to fatty changes in liver that lead to increase in liver weight. Such weight gain was not observed in any of the formulation groups in any model. Moreover, the liver weight in all the formulation groups was close to the normal control group of respective studies, and no statistically significant difference was noted when compared between the formulation groups [Table 2].

Effect of various formulations on serum glutamic pyruvic transaminase, serum glutamic-oxaloacetic transaminase, and alkaline phosphatase in various hepatotoxicity models

CCl₄, ethanol, and paracetamol being the hepatotoxic agents injure the hepatic cells and cause significant damage to the liver. As a result of this SGPT, SGOT and ALP levels in the groups treated with these hepatotoxic agents were found significantly increased when compared to normal control group in respective studies [Table 2].

All the formulations in all three studies successfully reduced SGPT, SGOT, and ALP levels when compared to CCl₄, ethanol, and paracetamol groups in respective study. When compared between the formulation groups, no significant difference was visible.

Effect of various formulations on total bilirubin in various hepatotoxicity models

Total bilirubin level was increased to 4.42±0.13 g/dl in CCl₄ group. This four-fold increase compared to normal control group indicates significant liver damage due to CCl₄. Similarly, total bilirubin was increased to 5.32 ± 0.07 g/dl in ethanol group and 5.46±0.006 g/dl in paracetamol group when compared to normal group indicating five-fold increase than normal limits. This indicated impairment in liver function by CCl₄, ethanol, and paracetamol [Table 2].

It is evident from the results that none of the formulation groups increased the bilirubin level. In fact, all the formulation groups were successful in reducing the total bilirubin level close to the normal. Comparison between the formulation groups shows no statistically significant difference.

Effect of various formulations on total protein in various hepatotoxicity models

Damage to the liver cells results in impairment in liver's function of protein synthesis. The same is indicated by the results of the study, wherein total protein level in CCl₄, ethanol, and paracetamol groups is reduced to almost half of that in normal control groups. However, all the formulation groups in all the studies effectively increased the total protein level which was close to the normal control group. Statistically, there was no significant difference when compared between the groups [Table 2].

Effect of various formulations on histopathological parameters of liver in various hepatotoxicity models

In the histopathological examination of the liver tissue, normal control group showed normal cellular architecture with distinct hepatic cells, sinusoidal spaces, and central vein. There were no signs of inflammation and fibrosis. Blood vessels were normal with no signs of hemorrhage. Whereas CCl₄-, ethanol-, and paracetamol-treated liver tissues showed signs of toxicity such as necrotic cells, inflammation, hemorrhage, and even fibrosis or fatty changes. Blood vessels appeared normal in CCl₄ group and congested in ethanol and paracetamol group.

In a group treated with silymarin, these signs of toxicity such as necrosis, inflammation, hemorrhage, and fibrosis were not demonstrated. However, fatty changes were found.

In the group of marketed formulation, all these signs of toxicity were absent, the tissue showed normal architecture, but fatty changes were noted like that of silymarin. Occasional inflammatory signs in this group were observed in ethanol-induced hepatotoxicity model.

In CCl₄-induced hepatotoxicity, all the groups of AHPL/AYTAB/0613 formulation, i.e., low, medium and high dose, no signs of toxicity were found barring congested blood vessels in medium dose group. However, this finding can also be seen in normal control liver tissue, and hence, it could be considered as a nonsignificant finding. Moreover, except the low-dose formulation group, liver tissues of other two groups were devoid of any sort of fatty changes. And therefore, it can be stated that medium- and high-dose formulation groups are better than any other groups when the histopathology of liver tissue is concerned [Figure 1].

No signs of toxicity were found in any of the groups of AHPL/AYTAB/0613 formulation (i.e low, medium and high dose) in ethanol-induced hepatotoxicity model. Fibrotic and fatty changes were also totally absent in all the three groups. Blood vessels in the medium dose group were dilated, which is also a finding with the marketed formulation group. However, this cannot be taken as a very significant finding as there were no hemorrhage and fibrosis [Figure 2].

In paracetamol-induced hepatotoxicity model, no signs of necrosis were found in any group of AHPL/AYTAB/0613 formulation (i.e. low, medium and high dose). Scanty inflammatory changes were observed in low- and medium-dose groups, however, hemorrhage and fibrosis were absent in both of them. High-dose formulation group displayed signs

of hemorrhage and fibrosis, but no inflammatory changes were seen. Blood vessels were congested in low- and high-dose formulation group while normal in medium dose formulation group. Fatty changes were not observed in any of these three formulation groups [Figure 3].

DISCUSSION

In the modern era, human beings are exposed to multiple chemicals directly or indirectly that may cause injury to liver cells and impair the liver function. Symptoms and clinically significant disease follow only when the damage leads to impairment of liver function.^[1,5] Hepatotoxicity may lead to various diseases such as hepatitis, cirrhosis, nonalcoholic fatty liver disease, hepatocellular carcinoma, sclerosing cholangitis, and Wilson's disease.^[5] Affected individual may land into acute or chronic liver failure due to hepatotoxicity and subsequent liver damage.

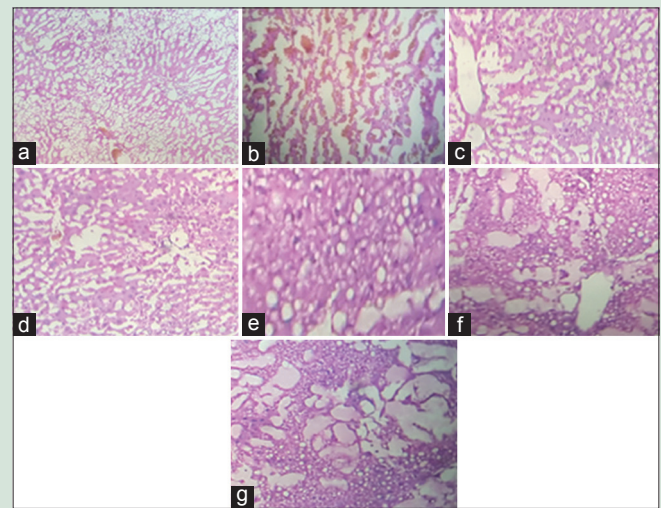
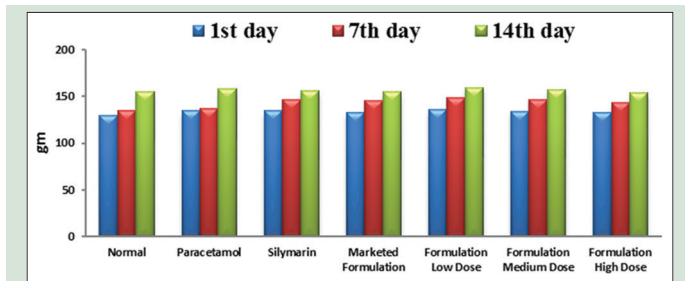


Figure 1: Histopathological representation of liver in carbon tetrachloride induced liver injury in rat treated with various formulations (H and E stain, x40) (a) Normal, (b) carbon tetrachloride, (c) silymarin, (d) marketed formulation, (e) formulation low dose, (f) formulation medium dose, (g) formulation high dose



Graph 3: Effect of various formulations on body weight in rats in paracetamol-induced hepatotoxicity

Table 2: Effect of test formulations on various parameters in carbon tetrachloride-, ethanol-, and paracetamol-induced hepatotoxicity models

Parameters	Models	Group I (normal control)	Group II (positive control)	Group III (standard I)	Group IV (standard II)	Group V (formulation low dose)	Group VI (formulation medium dose)	Group VII (formulation high dose)
Liver weight	CCl ₄	3.29±0.22	4.38±0.24 [#]	3.22±0.01 ^{**}	3.31±0.03 ^{**}	3.36±0.23 ^{**}	3.34±0.02 ^{**}	3.32±0.01 ^{**}
	Ethanol	3.15±0.07	5.6±0.23 [#]	3.47±0.49 ^{**}	3.52±0.11 ^{**}	3.43±0.55 ^{**}	3.33±0.44 ^{**}	3.21±0.11 ^{**}
	Paracetamol	3.90±0.43	6.3±0.44 [#]	3.20±0.66 ^{**}	3.23±0.23 ^{**}	3.33±0.36 ^{**}	3.27±0.33 ^{**}	3.25±0.11 ^{**}
SGPT	CCl ₄	45.06±0.03	88.61±0.44 [#]	48.83±0.51 ^{**}	53.2±0.76 ^{**}	56.2±0.06 ^{**}	53.8±0.43 ^{**}	51.38±0.83 ^{**}
	Ethanol	48.16±0.21	117.78±0.08 [#]	52.68±0.06 ^{**}	53.2±0.04 ^{**}	55.2±0.03 ^{**}	51.10±0.043 ^{**}	50.4±0.05 ^{**}
	Paracetamol	31.81±0.20	177.12±0.038 [#]	32.58±0.02 ^{**}	35.26±0.09 ^{**}	38.81±0.32 ^{**}	36.22±0.03 ^{**}	34.31±0.02 ^{**}
SGOT	CCl ₄	26.5±0.74	62.6±0.25 [#]	27.1±1.16 ^{**}	31.4±0.29 ^{**}	33.2±0.22 ^{**}	30.7±0.07 ^{**}	28.6±0.10 ^{**}
	Ethanol	25.8±0.020	95.6±0.19 [#]	30.6±0.18 ^{**}	33.15±0.45 ^{**}	36.6±0.015 ^{**}	31.17±0.01 ^{**}	29.76±0.08 ^{**}
	Paracetamol	15.38±0.16	53.17±0.20 [#]	15.13±0.18 ^{**}	17.65±0.27 ^{**}	19.50±0.24 ^{**}	16.52±0.41 ^{**}	16.18±0.78 ^{**}
ALP	CCl ₄	69.29±0.06	115.6±0.59 [#]	67.84±0.05 ^{**}	72.32±0.03 ^{**}	74.11±0.03 ^{**}	73.34±0.24 ^{**}	65.41±0.31 ^{**}
	Ethanol	66.86±0.10	168.54±0.03 [#]	68.85±0.03 ^{**}	72.16±0.24 ^{**}	70.78±0.02 ^{**}	68.18±0.13 ^{**}	65.02±0.06 ^{**}
	Paracetamol	47.16±0.46	95.86±1.64 [#]	49.20±0.29 ^{**}	53.11±0.20 ^{**}	54.85±0.09 ^{**}	53.50±0.036 ^{**}	52.57±0.09 ^{**}
Total bilirubin	CCl ₄	0.98±0.14	4.42±0.13 [#]	0.99±0.12 ^{**}	1.12±0.13 ^{**}	1.18±0.12 ^{**}	1.16±0.18 ^{**}	1.14±0.14 ^{**}
	Ethanol	1.02±0.086	5.32±0.07	1.12±0.006 ^{**}	1.46±0.03 ^{**}	1.34±0.04 ^{**}	1.15±0.03 ^{**}	1.10±0.05 ^{**}
	Paracetamol	1.15±0.003	5.46±0.006 [#]	1.20±0.004 ^{**}	1.33±0.006 ^{**}	1.48±0.063 ^{**}	1.38±0.02 ^{**}	1.20±0.005 ^{**}
Total protein	CCl ₄	5.46±0.06	2.30±0.024 [#]	5.48±0.04 ^{**}	6.17±0.12 ^{**}	6.11±0.02 ^{**}	5.65±0.08 ^{**}	5.17±0.06 ^{**}
	Ethanol	5.16±0.003	2.61±0.015 [#]	5.11±0.002 ^{**}	5.14±0.005 ^{**}	4.98±0.04 ^{**}	5.03±0.11 ^{**}	5.12±0.02 ^{**}
	Paracetamol	7.12±0.002	2.65±0.004 [#]	7.14±0.006 ^{**}	7.14±0.006 ^{**}	6.98±0.01 ^{**}	7.01±0.03 ^{**}	7.11±0.004 ^{**}

^{**}P < 0.01 when all groups except normal were compared with CCl₄, ethanol or paracetamol group; [#]P < 0.01, when CCl₄, ethanol or paracetamol group compared with normal. SGOT: Serum glutamic-oxaloacetic transaminase; SGPT: Serum glutamic pyruvic transaminase; ALP: Alkaline phosphatase; CCl₄: Carbon tetrachloride

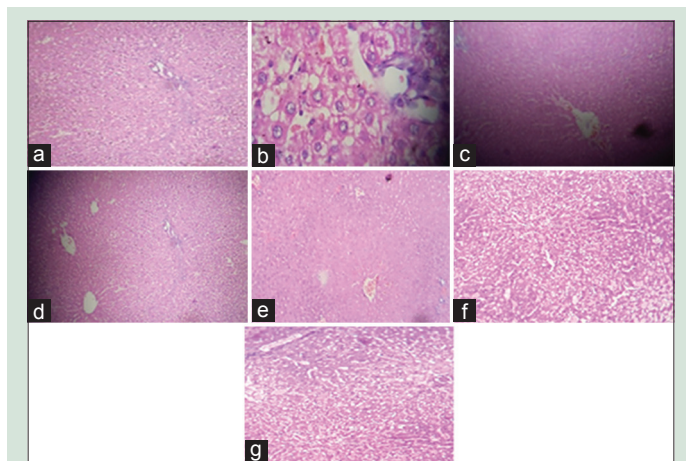


Figure 2: Histopathological representation of liver in ethanol-induced liver injury in rats treated with various formulations (H and E stain, ×40) (a) Normal, (b) ethanol, (c) silymarin, (d) marketed formulation, (e) formulation low dose, (f) formulation medium dose, (g) formulation high dose

Currently, UDCA is the only allopathic drug approved by the US FDA for hepatoprotection or the treatment of primary biliary cirrhosis (PBC). Although UDCA is reported to have hepatoprotective activity, its use beyond PBC is unjustified because of observed findings such as liver cell failure, mutagenic effects, hepatitis, ascites, immune suppression, increased association with hepatocellular carcinoma in PBC, and even death. Moreover, there is very narrow range between its therapeutic and toxic dose.^[6]

Liver transplant indicated in end-stage liver disease due to hepatotoxicity also carries potential adverse outcomes. Graft rejection, vascular and biliary complications, sepsis, and short-term survival rates are some of the confounding factors for acceptance of liver transplant.^[7] Besides, its high cost and necessary ultramodern nursing care make it unsuitable option for general population.

Therefore, there is immense need of safer and effective hepatoprotective agents that can prevent the damage and improve the liver functions. In this context, a lot of attention has been focused on use of herbs that can provide hepatoprotective function with minimal side effects and better acceptability. Since thousands of years, various herbs have been used in the Traditional system of medicine such as Ayurveda to treat jaundice and other liver disorders. Many of them possess hepatoprotective activity and beneficial effects in liver disorders. Hence, efforts are being taken to formulate drugs from these herbs to provide safe, cost effective, well tolerated, and potential hepatoprotective agent.

With this background, Ari Healthcare Pvt. Ltd. has conceptualized and developed AHPL/AYTAB/0613 tablet which is a polyherbal formulation of herbs with proven hepatoprotective activity. Therefore, three separate studies were conducted to evaluate the hepatoprotective activity of AHPL/AYTAB/0613 in comparison with silymarin and marketed formulation in CCl_4 , ethanol, and paracetamol-induced hepatotoxicity models in rats. Silymarin is a well-recognized hepatoprotective agent known to neutralize the toxic effects produced by CCl_4 , acetaminophen, ethanol, and galactosamine-induced hepatotoxicity models in rats.^[8] The activity of AHPL/AYTAB/0613 tablet was studied in three doses - high, medium, and low. All these formulations were compared with each other and with normal control and positive control.

All the three groups of test formulation significantly reduced the serum level of SGOT, SGPT, ALP, and total bilirubin in all three studies. Formulation groups also significantly improved total protein levels in all the studies.

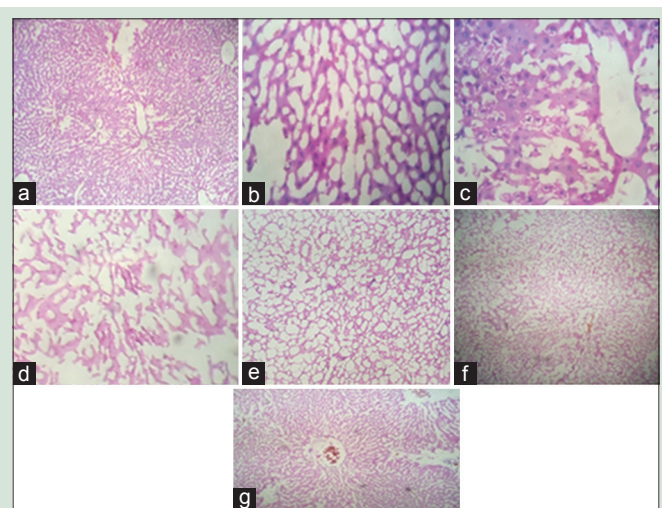


Figure 3: Histopathological representation of liver in paracetamol-induced liver injury in rat treated with various formulations (H and E stain, ×40) (a) Normal, (b) paracetamol, (c) silymarin, (d) marketed formulation, (e) formulation low dose, (f) formulation medium dose, (g) formulation high dose

The overall body weight of rats in formulation groups was increased while the liver weight was significantly reduced by all the formulation groups in CCl_4 , ethanol, and paracetamol-induced hepatotoxicity models in rats. This indicates the prevention of hepatotoxicity-related fatty changes in liver and improvement in liver function which leads to overall enhancement in metabolism and health by all the formulation groups.

When the liver tissues from all the groups were subjected to histopathological examination, it was observed that liver tissues of normal control group showed normal cellular architecture with distinct hepatic cells, sinusoidal spaces, and central vein. Whereas CCl_4 , ethanol and paracetamol-treated liver tissues showed signs of toxicity as necrotic cells, inflammation, hemorrhage, fibrosis, and even fatty changes. In standard control and in the group of marketed formulation, these signs of toxicity were not demonstrated; the tissues showed normal architecture, but fatty changes were noted in Silymarin group.

In all the groups of AHPL/AYTAB/0613 formulation, i.e., low, medium and high dose, successfully preserved the normal cellular architecture of liver and prevented the cellular damage caused by CCl_4 , ethanol, and paracetamol. Therefore, from the results, we could conclude that all the formulations have been successful in preventing the pathological changes generated by CCl_4 , ethanol, and paracetamol.

All the above findings suggest that high, medium, and low-dose formulation groups show significant hepatoprotective activity in terms of reduction in serum levels of liver enzymes such as SGOT, SGPT, and ALP that are usually released in response to the damage to hepatic parenchyma. Lowering of total bilirubin indicates improvement in liver function. All these effects are highly significant in CCl_4 , ethanol, and paracetamol groups, establishing its hepatoprotective activity.

AHPL/AYTAB/0613 tablet contains, *Bhringaraja* extract – *E. alba* (Asteraceae), *Guduchi* extract – *T. cordifolia* (Menispermaceae), *Daruharidra* extract – *B. aristata* (Berberidaceae), *Kakamachi* extract – *S. nigrum* (Solanaceae), *Punarnava* extract – *B. diffusa* (Nyctaginaceae), *Bhumyamalaki* extract – *P. niruri* (Euphorbiaceae), *Kutaki* extract – *P. kurroa* (Plantaginaceae) and *Kalamegha* extract – *A. paniculata* (Acanthaceae).

In Ayurveda, *Bhringaraja* (*E. alba*) is used in the treatment of various liver disorders. It aids in digestion and improves the liver function.

It is also a rejuvenator drug.^[9] In preclinical studies, it is reported to improve liver function of experimental animals suggested by reduction in serum transaminases levels.^[10] The role of *E. alba* as an effective hepatoprotective agent has also been reported by various studies conducted on experimental models of CCl₄, ethanol, and paracetamol-induced hepatotoxicity as evidenced by the regulation of levels of hepatic microsomal drug metabolizing enzymes.^[11-13]

Since thousands of years in the Indian system of medicine, *Guduchi* has been used as rejuvenator and tonic. The drug is well known Indian bitter and prescribed in fever, jaundice, dyspepsia, skin disease, diabetes, and urinary problems.^[14] The stem of *Guduchi* also stimulates bile secretion, allays thirst, burning sensation, vomiting, enriches the blood and cures jaundice.^[15]

In various research studies conducted in experimental animals, it has been observed that oral administration of *T. cordifolia* significantly reduces the serum SGPT, SGOT, ALP and bilirubin levels while treating the liver toxicity. In a research study, *T. cordifolia* improved the Kupffer cell function in a model of chronic liver disease.^[16] The hepatoprotective action of *Tinospora* was reported in one of the experiment, in which goats treated with *T. cordifolia* have shown significant clinical and hepato-biochemical improvement in CCl₄-induced hepatopathy. Extract of *T. cordifolia* has also exhibited *in vitro* inactivating property against hepatitis B and E surface antigens.^[17] *T. cordifolia* also has significant anti-oxidant properties.^[17]

Daruharidra (*B. aristata*) is one such herb used in Ayurveda in the treatment of indigestion, jaundice, and hepatosplenomegaly.^[18] Berberin, an alkaloid from this herb has been extensively studied and known to possess cholagogue, antiprotozoal, antibacterial, anti-inflammatory and antitumor activities.^[19] Prophylactic dose of berberine in CCl₄ and acetaminophen induced-liver toxicity decreased serum aminotransferase and ALP levels indicating its hepatoprotective activity. Whereas selective curative role of berberine as post treatment dose in acetaminophen-induced hepatotoxicity is also reported in the study.^[19]

Kakamachi (*S. nigrum*) is one of the important rejuvenator drugs used in Ayurvedic system of medicine. Its role is widely accepted in the treatment of chronic hepatomegaly, ascites, hematemesis (due to liver cirrhosis), and various other liver diseases.^[20] Results of one experimental study show that extract of *S. nigrum* possesses hepatoprotective activity in CCl₄-induced oxidative damage in rats manifested by reduction in the serum levels of hepatic enzymes and prevention of histopathological damage induced by CCl₄. This could be contributed to its anti-oxidant, free radical scavenging, and modulation of detoxification enzyme effects.^[21] *S. nigrum* has demonstrated hepatoprotective effects against ethanol-induced injury both *in vitro* and *in vivo* and can protect the integrity of hepatocytes and thus reduce the release of liver glutathione S-transferase (GST) A1, which contributes to improve liver detoxification.^[22]

In traditional Ayurvedic system, *Punarnava* (*B. diffusa*) has been used as rejuvenator (*Rasayana*).^[23,24] In all over the world, the roots of *B. diffusa* have been widely used for the treatment of dyspepsia, jaundice, enlargement of spleen, and abdominal pain.^[25] In a research study, it has been observed that an aqueous extract of thinner roots of *B. diffusa* at a dose of 2 mg/kg exhibited the remarkable protection of various enzymes such as SGOT, SGPT, and bilirubin in serum against hepatic injury in rats.^[24] Many other experimental studies also evidenced a beneficial activity of the *Punarnava* root for the treatment of the jaundice.^[24] The *B. diffusa* also has adaptogenic and anti-oxidant properties.^[24]

In Ayurveda, *Kutki* (*P. kurroa*) is used to treat indigestion, disorders of the liver, upper respiratory tract infections, and fever.^[26,27] The plant has also been used to cure heart ailments, abdominal pain, stomach disorders, anemia, jaundice, and for promoting bile secretion.^[28]

The oral administration of extract of dried rhizomes and roots of *Kutki* is claimed as a cure for human viral hepatitis.^[28] In a research study conducted in experimental rats, it has been observed that oral administration of *P. kurroa* decreases the oxidative stress and acts as membrane-stabilizing agent in antitubercular drugs (isoniazid and rifampicin)-induced hepatitis.^[29] The oral administration of *P. kurroa* enhances the activities of glutathione (GSH), GSH-dependent antioxidant enzymes (GSH peroxidase and GST), and antiperoxidative enzymes during oxidative stress. *P. kurroa* also prevents hepatotoxicity by its membrane-stabilizing and antioxidant properties.^[28]

Kalamegha (*A. paniculata*) is commonly known as “king of bitters,” “*Bhui-neem*.” It has strong bitter taste and has been used as tonic in weakness and poisoning.^[30] *A. paniculata* is extensively used as a hepato-stimulant and hepatoprotective agent in the Indian systems of medicine.^[31]

A. paniculata also showed benefits against liver damage caused by agents with different hepatotoxic mechanisms, suggesting *A. paniculata* might have broad-spectrum hepatoprotective effects.^[30] Andrographolide is an active constituent of *A. paniculata* and a single-oral dose of andrographolide has protective effect on CCl₄-induced hepatic microsomal lipid peroxidation. In several clinical studies, it has been observed that *A. paniculata* has protective effects against ethanol-induced increase in serum transaminases.^[30] In a preclinical study, it has been observed that *Andrographolide*, a major bioactive compound of *A. paniculata* is found to be more antihepatotoxic against drug (paracetamol)-induced liver damage in rats.^[31]

Bhumyamalaki (*P. niruri*) is widely used in the treatment of hepatitis, hepatosplenomegaly, fever and various liver diseases in Ayurveda.^[32] Studies have proved its hepatoprotective activity in CCl₄-induced hepatotoxicity in experimental rats manifested by reduction in serum level of SGOT, SGPT, and ALP. Its antioxidant potential has also been validated in the study.^[33]

It is obvious from the above discussion that all the ingredients of AHPL/AYTAB/0613 tablet possess hepatoprotective activity individually; the hepatoprotective activity exhibited by this combination could be considered to be the synergistic effect of all the constituents.

CONCLUSION

It can be concluded from the results of the present study that AHPL/AYTAB/0613 tablet possesses hepatoprotective activity in high, medium and low doses in CCl₄, ethanol and paracetamol-induced hepatotoxicity in rats. No signs and symptoms of toxicity in any group were observed, and all the formulations tested were well tolerated by the rats. Although high- and low-dose formulations are also effective as hepatoprotective agents, medium dose formulation of AHPL/AYTAB/0613 is recommended for potent hepatoprotective effect in humans.

Acknowledgement

Authors sincerely thank all trial site staff at Padmashree Dr. D. Y. Patil Institute of Pharmaceutical Sciences and Research, Pune - 411 018 for their contribution in conduct of the present study. Authors are extremely grateful to Mr. Sanjeevan Kanjilal (Managing Director) and Dr. Anisha Kanjilal (Director) of Ari Healthcare Pvt. Ltd., for providing all the research facilities, guidance, courage, and moral support.

Financial support and sponsorship

This study was financially supported by Mr. Sanjeevan Kanjilal (Managing Director) and Dr. Anisha Kanjilal (Director) - Ari Healthcare Pvt. Ltd., Pune.

Conflicts of interest

There are no conflicts of interest.

REFERENCES

- Singh A, Bhat TK, Sharma OP. Clinical biochemistry of hepatotoxicity. *J Clin Toxicol* 2011;S4:1.
- Pandit A, Sachdeva T, Bafna P. Drug-induced hepatotoxicity: A review. *J Appl Pharm Sci* 2012;2:233-43.
- Kumar A. A review on hepatoprotective herbal drugs. *IJRPC* 2012;2:92-102.
- Seeff LB, Lindsay KL, Bacon BR, Kresina TF, Hoofnagle JH. Complementary and alternative medicine in chronic liver disease. *Hepatology* 2001;34:595-603.
- Dhingra M, Nain P, Nain J, Malik M. Hepatotoxicity v/s hepatoprotective agents - A pharmacological review. *IRJP* 2011;2:31-7.
- Kotb MA. Molecular mechanisms of ursodeoxycholic acid toxicity & side effects: Ursodeoxycholic acid freezes regeneration & induces hibernation mode. *Int J Mol Sci* 2012;13:8882-914.
- Ikegami T, Masuda Y, Ohno Y, Mita A, Kobayashi A, Urata K, *et al.* Prognosis of adult patients transplanted with liver grafts <35% of their standard liver volume. *Liver Transpl* 2009;15:1622-30.
- Pandey G, Sahni YP. A review on hepatoprotective activity of silymarine. *IJRAP* 2011;2:75-9.
- Pandit Bhavmishra. Commentary by Dr. Chunekar KC, Bhavaprakash Nighantu. Varanasi: Chaukhambha Bharati; 2006. p. 414.
- Jahan R, Al-Nahain A, Majumder S, Rahmatullah M. Ethnopharmacological significance of *Eclipta alba* (L.) Hassk. (*Asteraceae*). *Int Sch Res Notices* 2014;2014:22.
- Thirumalai T, David E, Therasa SV, Elumalai EK. Restorative effect of *Eclipta alba* in CCl₄ induced hepatotoxicity in male albino rats. *Asian Pac J Trop Med* 2011;4:304-7.
- Arun K, Balasubramanian U. Comparative study on hepatoprotective activity of *Aegle marmelos* and *Eclipta alba* against alcohol induced in albino rats. *Int J Environ Sci* 2011;2:389-402.
- Prabu K, Kanchana N, Sadiq AM. Hepatoprotective effect of *Eclipta alba* on paracetamol induced liver toxicity in rats. *J Microbiol Biotechnol Res* 2011;1:75-9.
- Sinha K, Mishra NP, Singh J, Khanuja SP. *Tinospora cordifolia* (Guduchi): A reservoir plant for therapeutic applications: A review. *Indian J Trad Know* 2004;3:257-70.
- Singla A. Review of Biological Activities of "*Tinospora Cordifolia*". *WebmedCentral Pharmaceutical Sciences* 2010;1:1-13.
- Upadhyay AK, Kumar K, Kumar A, Mishra HS. *Tinospora cordifolia* (Willd.) Hook. f. and Thoms. (Guduchi) - Validation of the Ayurvedic pharmacology through experimental and clinical studies. *Int J Ayurveda Res* 2010;1:112-21.
- Snakhala LN, Saini RK, Saini BS. A review on chemical and biological properties of *Tinospora cordifolia*. *Int J Med Aromat Plants* 2012;2:340-4.
- Pandit Bhavmishra. Commentary by Dr. Chunekar KC, Bhavaprakash Nighantu. Varanasi: Chaukhambha Bharati; 2006. p. 114-8.
- Janbaz KH, Gilani AH. Studies on preventive and curative effects of berberine on chemical-induced hepatotoxicity in rodents. *Fitoterapia* 2000;71:25-33.
- Pandit Bhavmishra. Commentary by Dr. Chunekar KC, Bhavaprakash Nighantu. Varanasi: Chaukhambha Bharati; 2006. p. 423-4.
- Lin HM, Tseng HC, Wang CJ, Lin JJ, Lo CW, Chou FP. Hepatoprotective effects of *Solanum nigrum* Linn extract against CCl₄-induced oxidative damage in rats. *Chem Biol Interact* 2008;171:283-93.
- Liu FP, Ma X, Li MM, Li Z, Han Q, Li R, *et al.* Hepatoprotective effects of *Solanum nigrum* against ethanol-induced injury in primary hepatocytes and mice with analysis of glutathione S-transferase A1. *J Chin Med Assoc* 2016;79:65-71.
- Pandit Bhavmishra. Commentary by Dr. Chunekar KC, Bhavaprakash Nighantu. Varanasi: Chaukhambha Bharati; 2006. p. 423.
- Rajpoot K, Mishra RN. *Boerhavia diffusa* roots (Punarnava mool) - Review as Rasayan (rejuvenator/anti-aging). *Int J Res Pharm Biomed Sci* 2011;2:1451-60.
- Mishra S, Aeri V, Gaur PK, Jachak SM. Phytochemical, Therapeutic, and Ethnopharmacological Overview for a Traditionally Important Herb: *Boerhavia diffusa* Linn. *BioMed Research International* 2014;2014:808302. doi:10.1155/2014/808302.
- Pandit Bhavmishra. Commentary by Dr. Chunekar KC, Bhavaprakash Nighantu. Varanasi: Chaukhambha Bharati; 2006. p. 70-1.
- Picrorhiza kurroa*. Monograph. *Alternative Medicine Review* 2001;6:319-21. [PubMed].
- Jeyakumar R, Rajesh R, Meena B, Rajaprabhu D, Ganesan B, Buddhan S, *et al.* Antihepatotoxic effect of *Picrorhiza kurroa* on mitochondrial defense system in anti-tubercular drugs (isoniazid and rifampicin)-induced hepatitis in rats. *J Med Plants Res* 2008;2:17-9.
- Rajaprabhu D, Rajesh R, Jeyakumar R, Buddhan S, Ganesan B, Anandan R. Protective effect of *Picrorhiza kurroa* on antioxidant defense status in adriamycin-induced cardiomyopathy in rats. *J Med Plant Res* 2007;1:80-5.
- Rajalakshmi G, Jothi KA, Venkatesan R, Jegatheesan K. Hepatoprotective activity of *Andrographis paniculata* on paracetamol induced liver damage in rats. *J Pharm Res* 2012;5:2983-6.
- Akbar S. *Andrographis paniculata*: A review of pharmacological activities and clinical effects. *Altern Med Rev* 2011;16:66-77.
- Pandit Bhavmishra. Commentary by Dr. Chunekar KC, Bhavaprakash Nighantu. Varanasi: Chaukhambha Bharati; 2006. p. 446.
- Harish R, Shivanandappa T. Antioxidant activity and hepatoprotective potential of *Phyllanthus niruri*. *Food Chem* 2006;95:180-5.