



Case Report

Use of dual-energy computed tomography post endovascular treatment of cerebral aneurysm

Mitchell Stanton, Gian Sparti

Department of Neurosurgery, Gold Coast University Hospital, Southport, Qld, Australia.

E-mail: *Mitchell Stanton - mitchellstanton86@gmail.com; Gian Sparti - gian.sparto@health.qld.gov.au



*Corresponding author:

Mitchell Stanton,
Department of Neurosurgery,
Gold Coast University Hospital,
Southport, Qld, Australia.

mitchellstanton86@gmail.com

Received : 17 January 2021

Accepted : 30 March 2021

Published : 17 May 2021

DOI

10.25259/SNI_41_2021

Quick Response Code:



ABSTRACT

Background: Along with surgical clipping, endovascular management is one of the mainstay treatment options for cerebral aneurysms. However, immediate post procedural imaging is often hard to interpret due to the presence of contrast material. Dual-energy computed tomography (CT) allows differentiation between contrast extravasation and intracranial hemorrhage and this case illustrates the importance of this following endovascular treatment of an unruptured cerebral aneurysm.

Case Description: A patient presented with acute ophthalmoplegia secondary to mass effect from an intracavernous ICA fusiform aneurysm. The patient underwent an endovascular flow diverting stent to treat this aneurysm. Post procedure, the patient had a reduced level of consciousness and underwent a conventional CT showing diffuse subarachnoid hyperdensity of the left hemisphere. Dual-energy CT allowed accurate differentiation and illustrated diffuse contrast material extravasation, allowing patient to continue on dual antiplatelets and therapeutic anticoagulation to reduce the risk of ischemic injury post endovascular stent.

Conclusion: Use of dual-energy CT in the setting of endovascular management of intracranial aneurysms allows accurate diagnosis of any postoperative complications. Specifically, differentiating between subarachnoid hemorrhage and contrast extravasation is vital in these patients due to the significant consequences to their ongoing management in regard to continuation or cessation of antiplatelets or anticoagulation. With increasing access to this technology, its use should become standard practice in the post-operative investigation of these patients undergoing endovascular treatment.

Keywords: Aneurysm, Computed tomography, Contrast extravasation, Dual-energy computed tomography, Endovascular, Subarachnoid hemorrhage

INTRODUCTION

The concept of dual-energy computed tomography (CT) was first described in the 1970s, however, it was not until computational power advanced to the point where clinical implementation was possible in the early 2000s.^[5,11,12] Dual-energy CT has the ability to differentiate materials based on their differential attenuation when imaged at two different energy levels.^[5] This has multiple clinical applications but specifically this article describes the use of dual-energy CT in differentiating intracranial hemorrhage from contrast extravasation following endovascular treatment of an unruptured cerebral aneurysm. This differentiation being of paramount importance in the setting of a flow diverting stent, where the decision to continue or cease dual antiplatelet therapy will significantly impact the outcome for the patient.

This is an open-access article distributed under the terms of the Creative Commons Attribution-Non Commercial-Share Alike 4.0 License, which allows others to remix, tweak, and build upon the work non-commercially, as long as the author is credited and the new creations are licensed under the identical terms.

©2021 Published by Scientific Scholar on behalf of Surgical Neurology International

The prevalence of cerebral aneurysms is estimated to be around 3.2% of the population, with rate of rupture among all aneurysms to be approximately 1.3% per year.^[7,17] Along with surgical clipping, endovascular treatment is one of the mainstay treatment options for cerebral aneurysm.^[1,13] Endovascular treatment carries risks including both subarachnoid hemorrhage from aneurysm rupture and contrast leak causing encephalopathy and cerebral edema.^[1] Both complications may result in similar clinical presentations with reduced level of consciousness and neurological deficit, however acute management varies significantly. Therefore, when required, post-procedural imaging has traditionally been difficult to interpret with hyperdensity on CT potentially reflecting subarachnoid hemorrhage or contrast medium extravasation.^[15]

On review of the currently available literature, the use of dual-energy CT has been shown to be an accurate method to differentiate between intracranial hemorrhage and contrast medium extravasation in acute stroke patients following intra-arterial revascularization.^[15] However, there is limited literature illustrating the use of this technology in management of aneurysmal subarachnoid hemorrhage or peri-endovascular treatment of unruptured aneurysms. This case illustrates the use of dual-energy CT in the setting post-endovascular treatment of an unruptured aneurysm with a flow diverting stent and describes the clinical implications associated in the postoperative period.

CASE PRESENTATION

A female presented with acute onset left ophthalmoplegia secondary to mass effect of a newly diagnosed intracavernous left ICA fusiform aneurysm. This unruptured, partially thrombosed aneurysm was confirmed on diagnostic cerebral angiography, [Figure 1]. On examination, the patient did have evidence of partial third, fourth, and sixth nerve palsies and

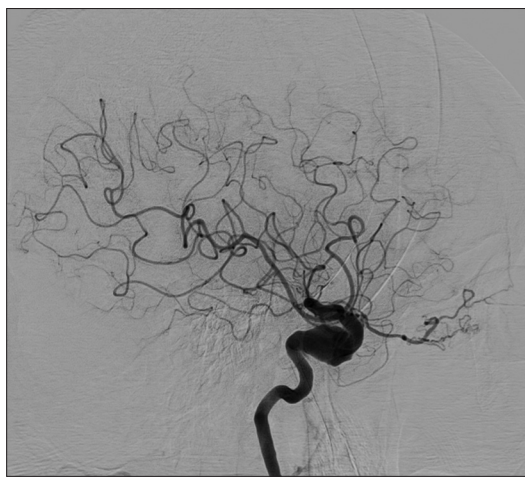


Figure 1: Cerebral angiogram of the left ICA, showing the 18 mm intracavernous fusiform aneurysm.

altered sensation in ophthalmic division of trigeminal nerve, consistent with a compressive pathology in the cavernous sinus. The patient had no clinical or radiographic evidence of carotico-cavernous fistula.

The patient underwent endovascular pipeline shield flow diverting stent treatment of the 18 mm unruptured aneurysm. The patient had been appropriately loaded preoperatively with dual antiplatelets and given a single-dose IV heparin as per department protocol. Nil intraprocedural concerns were identified, with early flow diversion and good parent vessel reconstruction noted. However, the patient was found to have decreased level of consciousness and dysphasia post procedure.

The patient was subsequently taken for an urgent conventional unenhanced CT, which is standard first-line radiographic assessment to assess for a postoperative complication. CT showed diffuse subarachnoid hyperdensity of the left cerebral hemisphere, shown in [Figure 2]. Unfortunately, it is quite difficult to differentiate hemorrhage from contrast medium extravasation on CT within the first 24 h post digital subtraction angiography.^[15] This is because of similar Hounsfield densities of iodine and hemorrhage.^[11,15] Definitive diagnosis is often only made on follow-up imaging 24 h later, when the contrast material extravasation has resolved.^[15]

However, in this clinical setting, the decision was made to repeat imaging using dual-energy CT to help differentiate between contrast medium extravasation and subarachnoid hemorrhage due to the significant impact that correct diagnosis would have on the acute management of this patient. The use of dual-energy CT is illustrated in [Figure 3]. [Figure 3a] shows conventional CT images, whereas [Figure 3b] illustrates the iodine map. Iodine map identifies any iodine contrast as this has a single density that differs to that of hemorrhage. Iodine contrast can then be removed to

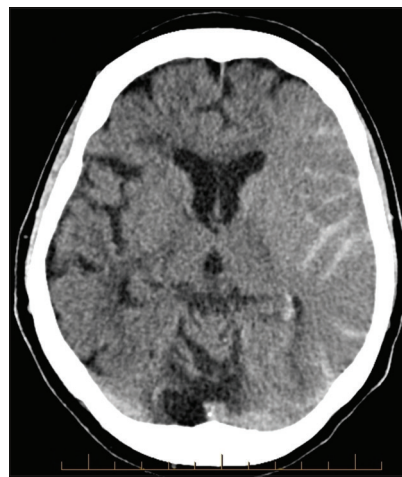

Figure 2: Conventional unenhanced CT showing diffuse subarachnoid hyperdensity of the left cerebral hemisphere.

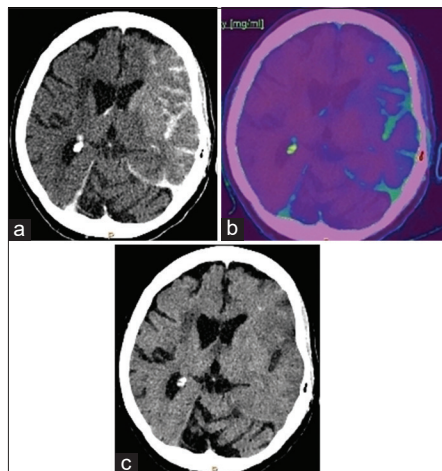


Figure 3: (a) Images from dual-energy CT. Conventional CT images again illustrating diffuse subarachnoid hyperdensity of the left cerebral hemisphere. (b) Iodine map, illustrating the ability to isolate only iodine contrast material as this has a single density that differs to that of hemorrhage. (c) Virtual nonenhanced image, where iodine contrast material identified on iodine map has been removed. Therefore, as showing no residual hyperdensity, this illustrates that it was all contrast material extravasation.

create a virtual nonenhanced image, shown in [Figure 3c]. This example subsequently shows that all the hyperdensity evident on conventional CT imaging were contrast medium extravasation and no evidence of subarachnoid hemorrhage.

Follow-up conventional CT imaging shown in [Figure 4] was performed the following day and confirmed this diagnosis, as all hyperdensity had resolved, in keeping with contrast medium extravasation. In the setting of subarachnoid hemorrhage, it would not be expected for such diffuse hyperdensity to have resolved within 24 h. Significant cerebral edema was also present, which would be secondary to this contrast leak, contributing initially to the patient's poor level of consciousness postprocedure.

Allowing accurate differentiation in this early post procedure period allowed continuation of antiplatelets and therapeutic anticoagulation, subsequently reducing the risk of ischemia following flow-diverting stent.^[14] Without the use of dual-energy CT, it would not be possible to acutely distinguish between contrast extravasation and hemorrhage, and subsequently, the patient would have had to cease these agents until the diagnosis was confirmed on follow-up imaging 24h later, increasing the risk of ischaemic complication.

Despite continuation of therapeutic anticoagulation and dual antiplatelet medications, the patient still suffered a left frontal ischemic infarct affecting Broca's area and causing severe expressive dysphasia. This likely occurred at the time of procedure from an embolic source. Her ongoing inpatient admission was further complicated by gastrointestinal bleeding secondary to diffuse upper gastrointestinal angiodysplasia in the

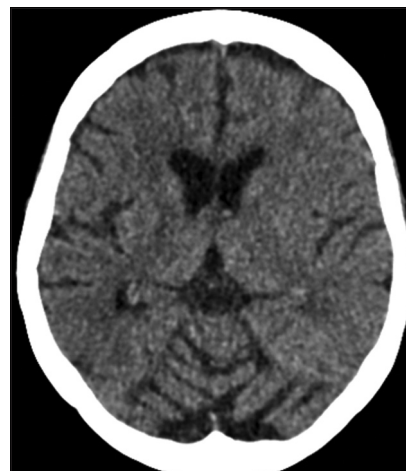


Figure 4: Conventional unenhanced CT performed 24 h post procedure showing resolution of hyperdensity.

setting of dual antiplatelet medications, with no surgical or endovascular treatment options. The patient has subsequently recovered but has been left with ongoing speech disturbance.

DISCUSSION

Endovascular intervention of cerebral aneurysms is a mainstay treatment to prevent the risk of subarachnoid hemorrhage. The decision regarding which aneurysms to treat is quite complex and there are many factors that come into play in this decision process. However, the focus of this case is not to discuss risk factors and patient selection but instead to illustrate the use of dual-energy CT to assist in the management of patients who have undergone endovascular treatment of cerebral aneurysms.

The ability for early differentiation of contrast medium extravasation and intracranial hemorrhage has become possible through the emerging availability of dual-energy CT. Dual-energy CT involves image reconstruction from two different X-ray spectra at different kilovoltages instead of one single kilovoltage as used with conventional CT.^[3,11,15] Two different energy spectra can be produced using two different X-ray sources simultaneously or fast kilovoltage switching, in which X-ray tube changes energy spectra in <0.5 ms.^[3,11,15] Two common selected energy levels are 80 kV and 140 kV.^[3,11,15] Characterization becomes possible due to different attenuation characteristics between iodine and blood at the two selected energy levels.^[3,11,15] Iodine maps can then be reconstructed, allowing a virtual unenhanced noncontrast image to be formed.^[3,11,15] Dual-energy CT has been well documented in its use in acute stroke patients who have undergone intra-arterial revascularization.^[4,6,15] Gupta has shown that dual-energy CT has high sensitivity and specificity in differentiating hemorrhage from iodinated contrast material extravasation.^[6]

This differentiation between contrast extravasation and hemorrhage is critical in the acute management of patients following endovascular treatment because the use of an endovascular flow-diverting stent to treat an unruptured aneurysm has a significant risk of cerebral ischemia secondary to in-stent thrombosis or distal thromboembolic events.^[1] Therefore, pre- and post-procedure dual antiplatelet therapy is considered the standard of care for all flow-diverting stent procedures.^[14] Subsequently, it is well documented that discontinuation of these agents increases this ischemic risk, especially in the peri-procedural setting.^[14] However, in the setting of intracranial hemorrhage, these agents need to be ceased to prevent further hemorrhage. Subsequently, the ability of dual-energy CT to accurately differentiate between contrast extravasation and hemorrhage allows appropriate acute management of these patients and in this case allowed continuation of dual antiplatelets and anticoagulation to reduce the risk of ischemia.

There is limited literature available regarding the use of dual-energy CT in the setting of subarachnoid hemorrhage. Ni *et al.*^[10] discussed the role of dual-energy CT in assessment of acute subarachnoid hemorrhage, both supporting its use to identify hemorrhage and a bone removal CTA technique to detect the intracranial aneurysm. Brockmann *et al.*^[2] showed in a small number of patients the effectiveness of dual-energy CT in differentiating peri-procedural rebleeding following aneurysmal subarachnoid hemorrhage. Dual-energy CT has also been shown to be superior to standard CTA in detecting aneurysm adjacent to skull base.^[19]

Karcaaltincaba also discusses other uses of dual-energy CT in the neuroradiology setting.^[8] This includes removal of bone and calcium from CTA to further assess cerebral vasculature, allowing increased accuracy in identifying cerebral aneurysms.^[8,16,20] Zhang has shown that dual-energy CTA has high diagnostic accuracy of detecting intracranial aneurysms at lower radiation dose when compared to the gold standard digital subtraction angiography.^[20] Uotani *et al.* also discussed its role in quantification of calcified carotid stenosis and discussed comparable results with DSA.^[16] This could potentially then have a role in preoperative planning for patient undergoing endovascular management of intracranial aneurysms. Furthermore, Kim *et al.*^[9] reported that dual-energy CT can be used in detection of underlying tumors within an intracranial hemorrhage.^[9,18]

The early differentiation between hemorrhage and contrast extravasation illustrated in this case allowed continuation of dual antiplatelets. The same clinical decisions are relevant in the setting of acute stroke patients who have undergone intra-arterial thrombectomy. The utility of dual-energy CT has been well documented in this scenario post intra-arterial thrombectomy for stroke patients, allowing for differentiation between contrast medium extravasation and hemorrhagic

transformation.^[4,6,15] This then allows appropriate clinical decisions to be made regarding the use of antiplatelets or anticoagulation. Furthermore, the use of dual-energy CT has been used in the setting following liquid embolization of arteriovenous malformations and dural arteriovenous fistulas. The use of dual-energy CT in this setting allowing accurate diagnosis of any intra-procedural hemorrhage.

CONCLUSION

Use of dual-energy CT in the setting of endovascular management of intracranial aneurysms allows accurate diagnosis of any post-operative complications through its ability to differentiate between contrast extravasation and intracranial hemorrhage. Differentiating between subarachnoid hemorrhage and contrast extravasation is vital in these patients due to the significant consequences to their ongoing management in regard to continuation or cessation of antiplatelets or anticoagulation. With increasing access to this technology, its use should become standard practice in the postoperative investigation of these patients undergoing endovascular treatment.

Declaration of patient consent

Patient's consent not required as patients identity is not disclosed or compromised.

Financial support and sponsorship

Nil.

Conflicts of interest

There are no conflicts of interest.

REFERENCES

1. Brinjikji W, Murad MH, Lanzino G, Cloft HJ, Kallmes DE. Endovascular treatment of intracranial aneurysms with flow diverters: A meta-analysis. *Stroke* 2013;44:442-7.
2. Brockmann C, Scharf J, Nölte IS, Seiz M, Groden C, Brockmann MA. Dual-energy CT after peri-interventional subarachnoid haemorrhage. *Clin Neuroradiol* 2010;20:231-5.
3. Chellini D, Kinman K. Dual-energy CT principles and applications. *Radiol Technol* 2020;91:561CT-76CT.
4. Ebashi R, Ogata A, Nishihara M, Inoue K, Yoshioka F, Takase Y, *et al.* Significance of simulated conventional images on dual energy CT after endovascular treatment for ischemic stroke. *J Neurointerv Surg* 2019;11:898-902.
5. Gibney B, Redmond CE, Byrne D, Mathur S, Murray N. A review of the applications of dual-energy CT in acute neuroimaging. *Can Assoc Radiol J* 2020;71:253-65.
6. Gupta R, Phan CM, Leidecker C, Brady TJ, Hirsch JA, Nogueira RG, *et al.* Evaluation of dual-energy CT for differentiating intracerebral hemorrhage from iodinated

- contrast material staining. *Radiology* 2010;257:205-11.
7. Juvela S, Poussa K, Porras M. Factors affecting formation and growth of intracranial aneurysms: A long-term follow-up study. *Stroke* 2001;32:485-91.
 8. Karcaaltincaba M, Aktas A. Dual-energy CT revisited with multidetector CT: Review of principles and clinical applications. *Diagn Interv Radiol* 2011;17:181-94.
 9. Kim SJ, Lim HK, Lee HY, Choi CG, Lee DH, Suh DC, *et al.* Dual-energy CT in the evaluation of intracerebral hemorrhage of unknown origin: Differentiation between tumor bleeding and pure hemorrhage. *AJNR Am J Neuroradiol* 2012;33:865-72.
 10. Ni QQ, Tang CX, Zhao YE, Zhou CS, Chen GZ, Lu GM, *et al.* Single phase dual-energy CT angiography: One-stop-shop tool for evaluating aneurysmal subarachnoid hemorrhage. *Sci Rep* 2016;6:26704.
 11. Postma AA, Das M, Stadler AAR, Wildberger JE. Dual-energy CT: What the neuroradiologist should know. *Curr Radiol Rep* 2015;3:16.
 12. Postma AA, Hofman PA, Stadler AA, van Oostenbrugge RJ, Tijssen MP, Wildberger JE. Dual-energy CT of the brain and intracranial vessels. *Am J Roentgenol* 2012;199:26-33.
 13. Ries T, Groden C. Endovascular treatment of intracranial aneurysms: Long-term stability, risk factors for recurrences, retreatment and follow-up. *Clin Neuroradiol* 2009;19:62-72.
 14. Shin DS, Carroll CP, Elghareeb M, Hoh BL, Kim BT. The evolution of flow-diverting stents for cerebral aneurysms; historical review, modern application, complications, and future direction. *J Korean Neurosurg Soc* 2020;63:135-52.
 15. Tijssen MP, Hofman PA, Stadler AA, van Zwam W, Graaf RD, van Oostenbrugge RJ, *et al.* The role of dual energy CT in differentiating between brain haemorrhage and contrast medium after mechanical revascularisation in acute ischaemic stroke. *Eur Radiol* 2014;24:834-40.
 16. Uotani K, Watanabe Y, Higashi M, Nakazawa T, Kono AK, Hori Y, *et al.* Dual-energy CT head bone and hard plaque removal for quantification of calcified carotid stenosis: Utility and comparison with digital subtraction angiography. *Eur Radiol* 2009;19:2060-5.
 17. Vlak MH, Algra A, Brandenburg R, Rinkel GJ. Prevalence of unruptured intracranial aneurysms, with emphasis on sex, age, comorbidity, country, and time period: A systematic review and meta-analysis. *Lancet Neurol* 2011;10:626-36.
 18. Watanabe Y, Tsukabe A, Kunitomi Y, Nishizawa M, Arisawa A, Tanaka H, *et al.* Dual-energy CT for detection of contrast enhancement or leakage within high-density haematomas in patients with intracranial haemorrhage. *Neuroradiology* 2014;56:291-5.
 19. Watanabe Y, Uotani K, Nakazawa T, Higashi M, Yamada N, Hori Y, *et al.* Dual-energy direct bone removal CT angiography for evaluation of intracranial aneurysm or stenosis: Comparison with conventional digital subtraction angiography. *Eur Radiol* 2009;19:1019-24.
 20. Zhang LJ, Wu SY, Niu JB, Zhang ZL, Wang HZ, Zhao YE, *et al.* Dual-energy CT angiography in the evaluation of intracranial aneurysms: Image quality, radiation dose, and comparison with 3D rotational digital subtraction angiography. *Am J Roentgenol* 2010;194:23-30.

How to cite this article: Stanton M, Sparti G. Use of dual-energy computed tomography post endovascular treatment of cerebral aneurysm. *Surg Neurol Int* 2021;12:225.