

Guillain-Barré syndrome after COVID-19 vaccination

Norma McKean,^{1,2} Charmaine Chircop^{1,2}

¹Department of Neurosciences, Mater Dei Hospital, Msida, Malta

²Department of Medicine, University of Malta, Msida, Malta

Correspondence to

Dr Norma McKean;
norma.mckean@gov.mt

Accepted 12 July 2021

SUMMARY

We report a case of Guillain-Barré syndrome (GBS) occurring soon after the first dose of Vaxzevria (previously known as COVID-19 vaccine AstraZeneca). Thus far, there has been no evidence of an increased risk of GBS resulting from either COVID-19 infection nor from COVID-19 vaccines; however, individual cases and population cohorts should be scrutinised, in order to ensure the constant evaluation of such risks. It is as yet not possible to draw conclusions about any significant association between COVID-19 vaccination and GBS. A temporal correlation does not imply, and should not be deemed to signify, causality. However, it is important to remain vigilant, so that any potential increased risk is properly evaluated. The specific presentation of bifacial weakness as the initial symptom may be a characteristic feature of GBS in the context of recent COVID-19 vaccination.

BACKGROUND

This case of Guillain-Barré syndrome (GBS), which was temporally related to the Vaxzevria vaccine, adds to the body of literature that is currently available and may reflect a possible link. Currently, this is a highly topical subject in the midst of the ongoing pandemic and the efforts to achieve herd immunity.

CASE PRESENTATION

We report a case of GBS which occurred following the first dose of Vaxzevria (previously known as COVID-19 vaccine AstraZeneca), in Malta. The patient is a 48-year-old man, with dyslipidaemia and no other relevant medical history. He had no history of infections and presented 10 days after receiving the first dose of the Vaxzevria vaccine with left-sided lower motor neuron facial weakness, initially House Brackmann grade III. He was diagnosed with Bell's palsy and treated with an oral steroid taper (prednisolone starting at 60 mg), eye drops and eye care, and physiotherapy referral.

The patient also noted severe mid-thoracic back pain, which was unrelenting and unresponsive to simple analgesics.

The facial weakness progressed over the next 24 hours and also started to involve the right side of his face. He presented again to the neurology department on the 13th day post-vaccine, with a House Brackmann grade V paralysis bilaterally. He also still reported severe back pain. There was otherwise no neurological deficit that the patient reported or that was elicited on examination. Notably, he had normal cognitive function, normal cranial nerve examination excluding facial weakness, with full extraocular movements, normal tone, full power grade 5 on 5 on the modified Medical Research Council (MRC) Scale, all peripheral reflexes 2+ bilaterally, downgoing plantar responses bilaterally, normal sensory examination and normal gait.

The patient was admitted for investigation. CT of the brain and MRI of the brain were normal (see [figure 1](#)); and blood investigations, including a vasculitic screen, viral screen and syphilis serology were all normal. COVID-19 swab was negative. Lumbar puncture was performed, which revealed a high protein level (1264 mg/L) and $8 \times 10^6/L$ lymphocytes. Anti-ganglioside antibodies, as well as oligoclonal bands, were negative.

The patient was diagnosed with GBS. He remained stable over the next 3 days, with facial weakness showing marked improvement. The decision to continue oral prednisolone and to discharge him with close follow-up and physiotherapy was made. However, over the next 24 hours, he developed ascending paraesthesia and bilateral progressive lower limb weakness. He returned to the emergency department where he was found to have significant lower limb weakness with foot drop and inability to weight bear, moderately severe hand weakness and loss of his lower limb reflexes. Sensation to pain was also impaired in a glove and stocking distribution (see [table 1](#) and [video 1](#)). Again, he was COVID-19 negative.

Intravenous immunoglobulins (IVIgs) were commenced (dose of 2 g/kg intravenously over 5 days) and oral prednisolone was kept on board in view of almost complete resolution of the facial weakness. By this time, the patient was areflexic in the lower limbs, with bilateral foot drop and bilateral lower limb weakness. He was only able to mobilise with a rollator frame and help of one.

Nerve conduction studies were performed which showed a severe, multifocal sensorimotor demyelinating polyneuropathy, with reduced compound motor action potentials throughout, reflecting likely hypoexcitability (see [figure 2](#)).

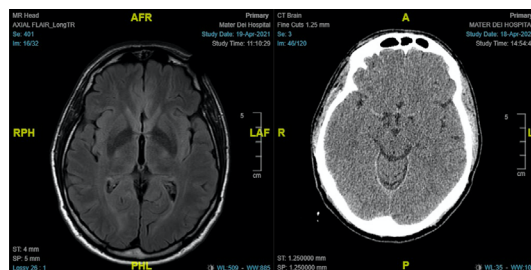


Figure 1 Normal CT and MRI of the brain. CT, Computed tomography; MRI, Magnetic resonance imaging.

Check for updates

© BMJ Publishing Group Limited 2021. No commercial re-use. See rights and permissions. Published by BMJ.

To cite: McKean N, Chircop C. *BMJ Case Rep* 2021;**14**:e244125. doi:10.1136/bcr-2021-244125

Table 1 Modified MRC Scale grading of power on re-presentation


	Right	Left
Upper limbs		
Deltoid	5	5
Triceps	5	5
Biceps	5	5
Wrist extensors	5	5
Finger extensors	4	4
First dorsal interosseous	3	3
Abductor digiti minimi	3	3
Abductor pollicis brevis	3	3
Lower limbs		
Iliopsoas	3	3
Quadriceps	4	3
Hamstrings	4	4
Tibialis anterior	2	2
Extensor hallucis longus	2	2

MRC, Medical Research Council.

The patient showed rapid improvement following the course of IVIg, with improvement in muscle power, paraesthesia and complete resolution of facial weakness. His respiratory function remained stable throughout the admission (negative inspiratory force monitoring throughout his hospital stay was persistently above 60 cm H₂O). He underwent intensive physiotherapy and can now mobilise independently and was discharged home. On outpatient review 2 months since presentation, he has only mild residual weakness of modified MRC Scale 4 on 5 of the hand intrinsic muscles bilaterally, hyporeflexia 1+ bilaterally in all upper limb reflexes, full power in the lower extremities, apart from grade 4 on 5 in the extensor hallucis longus bilaterally. Ankle reflexes remain absent and sensation to all modalities is intact.

INVESTIGATIONS

- ▶ CT of the brain and MRI of the brain: normal.



Video 1 Bilateral foot drop

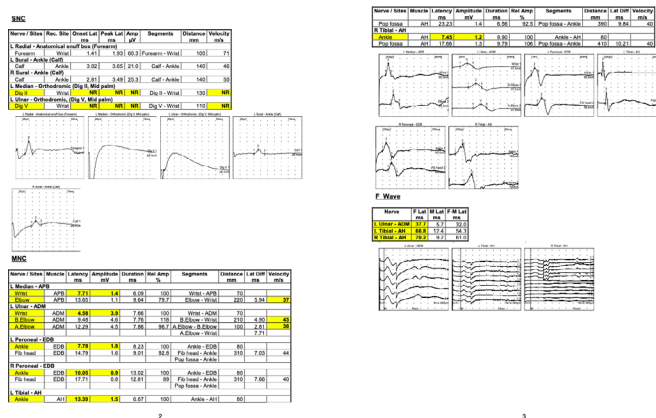


Figure 2 Nerve conduction studies showing a severe, multifocal sensorimotor demyelinating polyneuropathy, with reduced compound motor action potentials throughout, reflecting likely hypoexcitability.

- ▶ Blood investigations: all normal (including vasculitic screen, HIV serology, hepatitis screen and syphilis serology all negative).
- ▶ COVID-19 swab: negative at presentation and throughout patient’s inpatient stay.
- ▶ Lumbar puncture: high protein level and 8 × 10⁶/L lymphocytes—albuminocytological dissociation is expected in GBS.
- ▶ Anti-ganglioside antibodies: negative—sometimes found to be positive in GBS; usually reflect a specific GBS subtype or associated with a specific preceding infection.
- ▶ Nerve conduction studies: severe, multifocal sensorimotor demyelinating polyneuropathy, with reduced compound motor action potentials, reflecting likely hypoexcitability—compatible with a diagnosis of GBS.

DIFFERENTIAL DIAGNOSIS

The patient’s initial presentation with a unilateral lower motor neuron facial weakness pointed to a diagnosis of Bell’s palsy.

As the facial weakness became bilateral, progressive and severe, a diagnosis of GBS was suspected and confirmed on investigations as detailed above.

TREATMENT

- ▶ The patient was initially started on oral prednisolone—this was continued for 10 days total with a tapering dose regime in view of improvement noted in facial paralysis with this treatment.
- ▶ IVIGs were started when the patient presented with increasing ascending lower limb weakness and ascending paraesthesia—this was given for a total of 5 days at a dose of 2 g/kg intravenously over 5 days.
- ▶ The patient also underwent intensive physical rehabilitation, with physiotherapy and occupational therapy.

OUTCOME AND FOLLOW-UP

The patient showed rapid improvement following the treatment. His facial weakness has completely resolved since the onset of symptoms. His respiratory function remained stable throughout the admission. He underwent intensive physiotherapy and can now mobilise independently and was discharged home. He is being followed up as an outpatient at the Neurology Outpatient Clinic and Physiotherapy and Occupational Therapy Clinics.

DISCUSSION

The COVID-19 pandemic hit the world by storm, and Malta was no exception. At the time of writing, 30 675 confirmed cases of COVID-19 were recorded in Malta, with 420 patients succumbing to the disease.¹ The rate of vaccination uptake by the Maltese population is encouraging, with 76.28% of the population being fully vaccinated so far, and with the vaccination programme ongoing.²

Since the start of the production of vaccines, clinical trials and launch of mass vaccination programmes against COVID-19, scrutiny by not only both the scientific and medical community, but also by the general public, was not amiss. This was of course expected, and is essential, in order to monitor for potentially serious consequences from such vaccines. Thus far, there has been no evidence of an increased risk of GBS resulting from either COVID-19 infection nor from COVID-19 vaccines³; however, individual cases and population cohorts should be scrutinised, in order to ensure the constant evaluation of such risks.

This is the first reported case of GBS which was temporally related to the Vaxzevria vaccine in Malta. Other published reports of GBS following COVID-19 vaccination include those reported in relation to the Johnson & Johnson trial,³ and two more recent case reports related to the ChAdOx1-S/nCoV-19 vaccine in England and India.^{4 5} The Johnson & Johnson trial cases were not deemed to be secondary to the vaccine since there was also another case of GBS in the control group.³ In the latter two case reports, however, cases were also temporally associated with COVID-19 vaccination, and there was the notable feature of bilateral facial weakness as the presenting symptom.^{4 5} It is highly interesting that all these cases presented with bifacial paresis which is in contrast to the typical presentation of GBS, which is usually an ascending paralysis.

GBS is a heterogeneous condition, typically characterised by rapidly progressive, ascending, symmetrical paraesthesia and motor weakness associated with hyporeflexia or areflexia. Cranial nerve deficits may also occur. Molecular mimicry, anti-ganglioside antibody production and complement activation have all been implicated in the pathogenesis of GBS. Back pain is also an important symptom that may be present before the onset of weakness, and may sometimes mislead the clinician in the initial stages of diagnosis.⁶

GBS often occurs after infection, whereby the immune response produces antibodies that cross-react with gangliosides at nerve membranes. This in turn causes nerve damage or a functional block of nerve conduction. The type of infection and the specific anti-ganglioside antibody involved in the disease will generally define the subtype of GBS and the ultimate clinical course and prognosis.⁶

The estimated incidence rate of GBS in the USA and Europe is approximately between 0.81 and 1.89 cases per 100 000 person-years. Incidence increases with age, and the condition is also slightly more common in men. The lifetime risk of developing GBS is about 1 in 1000.⁷

Among the various side effects reported for different vaccines, neurological events can be among the most severe and thus of most concern. The potential association of vaccines and GBS was first brought to attention in 1976, following an influenza outbreak among new US Army recruits, which prompted the development of a new vaccine, and a mass vaccination campaign throughout the USA, due to fears of a possible influenza pandemic similar

to that seen in the Spanish Flu in 1918. Several cases of GBS were noted to be reported once the vaccination programme had commenced, and within a few months, the vaccination campaign was abandoned altogether. Surveillance for GBS cases thereafter revealed an almost 10-fold increased risk of development of GBS during the 6 weeks following receipt of the 1976 vaccine.⁸

Following this, increased attention was given to monitor for GBS following vaccine administration, together with other potential adverse effects. To date, no other vaccines were found to have such an increased risk of GBS following administration, as that in 1976. A slightly increased risk of GBS during the 6 weeks after influenza vaccination, equating to approximately one extra case of GBS per million persons vaccinated, was found in a GBS study conducted in 1992–1993 and 1993–1994 by Lasky *et al.*⁹

No clear pathogenesis has thus far been discovered. It has been postulated that contaminating proteins or other vaccine components may elicit anti-ganglioside antibody production, and that the increased filtration and purification steps used in more recent vaccines help to reduce, but not completely eliminate, this risk.⁸

It is as yet not possible to draw conclusions about any significant association between COVID-19 vaccination and GBS. Based on annual predicted incidence, 900–2200 per 1 billion people are expected to develop GBS within 6 weeks of a single-dose vaccine, and 1500–3700 people per 1 billion would be similarly affected in a 10-week period from a two-dose vaccine. Therefore, a temporal correlation does not imply, and should not be deemed to signify, causality.³ However, it is important to remain vigilant, so that any potential increased risk is properly evaluated, to prevent any further suffering amidst this pandemic. Furthermore, the highly specific and characteristic mode of presentation, with bifacial weakness as the initial symptom, may be a symptom to be vigilant of in the context of recent COVID-19 vaccination.

Learning points

- ▶ Though there is currently no evidence of any association between COVID-19 vaccination and Guillain-Barré syndrome (GBS) incidence, it is important to keep a high index of suspicion and to report any potential side effects or relevant cases that may be related to the vaccine.
- ▶ The specific presentation of bifacial weakness may be a characteristic feature of GBS associated with COVID-19 vaccination.
- ▶ Temporal correlation does not imply causality.
- ▶ A multidisciplinary team approach is important in the management of GBS.

Contributors NM—author, literature review, write up and editing, data interpretation and videography. CC—author, literature review, write up and editing, data interpretation and videography.

Funding The authors have not declared a specific grant for this research from any funding agency in the public, commercial or not-for-profit sectors.

Competing interests None declared.

Patient consent for publication Obtained.

Provenance and peer review Not commissioned; externally peer reviewed.

This article is made freely available for use in accordance with BMJ's website terms and conditions for the duration of the covid-19 pandemic or until otherwise determined by BMJ. You may use, download and print the article for any lawful,

non-commercial purpose (including text and data mining) provided that all copyright notices and trade marks are retained.

REFERENCES

- 1 Covid-19 Dashboard. Available: <https://deputyprimeminister.gov.mt/en/health-promotion/covid-19/Pages/covid-19-infographics.aspx> [Accessed 6 Jul 2021].
- 2 Coronavirus (COVID-19) vaccinations. Available: <https://ourworldindata.org/covid-vaccinations?country=MLT> [Accessed 6 Jul 2021].
- 3 Márquez Loza AM, Holroyd KB, Johnson SA, *et al.* Guillain-Barré syndrome in the placebo and active arms of a COVID-19 vaccine clinical trial: temporal associations do not imply causality. *Neurology* 2021. doi:10.1212/WNL.00000000000011881. [Epub ahead of print: 06 Apr 2021].
- 4 Allen CM, Ramsamy S, Tarr AW, *et al.* Guillain-Barré syndrome variant occurring after SARS-CoV-2 vaccination. *Ann Neurol* 2021. doi:10.1002/ana.26144. [Epub ahead of print: 10 Jun 2021].
- 5 Maramattom BV, Krishnan P, Paul R, *et al.* Guillain-Barré syndrome following ChAdOx1-S/nCoV-19 vaccine. *Ann Neurol* 2021. doi:10.1002/ana.26143. [Epub ahead of print: 10 Jun 2021].
- 6 van den Berg B, Walgaard C, Drenthen J, *et al.* Guillain-Barré syndrome: pathogenesis, diagnosis, treatment and prognosis. *Nat Rev Neurol* 2014;10:469–82.
- 7 Sheikh KA. Guillain-Barré syndrome. *Continuum* 2020;26:1184–204.
- 8 Nelson KE. Invited commentary: Influenza vaccine and Guillain-Barre syndrome--is there a risk? *Am J Epidemiol* 2012;175:1129–32.
- 9 Lasky T, Terracciano GJ, Magder L, *et al.* The Guillain-Barré syndrome and the 1992–1993 and 1993–1994 influenza vaccines. *N Engl J Med Overseas Ed* 1998;339:1797–802.

Copyright 2021 BMJ Publishing Group. All rights reserved. For permission to reuse any of this content visit <https://www.bmj.com/company/products-services/rights-and-licensing/permissions/>
BMJ Case Report Fellows may re-use this article for personal use and teaching without any further permission.

Become a Fellow of BMJ Case Reports today and you can:

- ▶ Submit as many cases as you like
- ▶ Enjoy fast sympathetic peer review and rapid publication of accepted articles
- ▶ Access all the published articles
- ▶ Re-use any of the published material for personal use and teaching without further permission

Customer Service

If you have any further queries about your subscription, please contact our customer services team on +44 (0) 207111 1105 or via email at support@bmj.com.

Visit casereports.bmj.com for more articles like this and to become a Fellow