

Familial vitamin D resistant rickets: End-organ resistance to 1,25-dihydroxyvitamin D

Sangita Choudhury, K. Felix Jebasingh, Salam Ranabir, Th Premchand Singh

Department of Medicine, Regional InstitutWe of Medical Sciences, Imphal, Manipur, India

ABSTRACT

Rickets is softening of bones due to defective mineralization of cartilage in the epiphyseal growth plate, leading to widening of ends of long bones, growth retardation, and skeletal deformities in children. The predominant cause is deficiency or impaired metabolism of vitamin D. The observation that some forms of rickets could not be cured by regular doses of vitamin D, led to the discovery of rare inherited abnormalities of vitamin D metabolism or vitamin D receptor. Vitamin D dependent rickets (VDDR) is of two types: Type I is due to defective renal tubular 25-hydroxyvitamin D 1- α hydroxylase and type II is due to end-organ resistance to active metabolite of vitamin D. Typical signs are observed from the first month of life. The patient with rickets described below had markedly increased serum alkaline phosphatase and 1,25-dihydroxyvitamin D. We attribute these abnormalities to impaired end-organ responsiveness to 1,25-dihydroxyvitamin D.

Key words: End-organ resistance, rickets, vitamin D, vitamin D dependent rickets, 1,25-dihydroxyvitamin D

INTRODUCTION

The term 'vitamin D resistant rickets' was first used in 1937 by Albright *et al.*, to describe form of rickets requiring doses of vitamin D far in excess of those required for healing of nutritionally deficient rickets.^[1] Vitamin D dependent rickets (VDDR) II is a very rare autosomal recessive form of rickets, with fewer than 50 known affected kindreds.^[2] The majority of the patients were the children of consanguineous marriages and have suffered early onset of rickets with few exceptions.^[3] There have been considerable differences in the degree of resistance to 1,25-dihydroxyvitamin D and apparently satisfactory responses have been reported in some cases.^[4,5]

CASE HISTORY

We are describing a case of 15-year-old boy who was referred to endocrinology clinic with progressive bowing of legs. The patient was noted by his parents to have abnormal legs which became increasingly evident when the patient began to walk. He had been seen in the orthopedic clinic; but in spite of persistent calcium supplement, the bowing of legs was progressive and he had been found to have other features suggestive of rickets. Then he was referred to endocrinology outpatient department (OPD) at the age of 15 years, where he was seen by one of the author of this case report.

He was born out of a nonconsanguineous marriage and was the eldest among his six siblings. His dietary history was normal and there was history of enough sun exposure. There was no history suggestive of any malabsorption disorder, hypocalcemia or hypercalcemia, and no history of chronic liver disease or renal disease.

The patient's younger sister who was 9-year-old, also had similar history of progressive bowing of legs since she started walking. No significant history was there in other family members.

Access this article online

Quick Response Code:



Website:
www.ijem.in

DOI:
10.4103/2230-8210.119579

Corresponding Author: Dr. Salam Ranabir, Department of Medicine, Regional Institute of Medical Sciences, P.O. Lamphelpat, Imphal - 795 004, Manipur, India. E-mail: salamranabir@yahoo.co.in

Physical examination

Physical examination revealed a well-nourished boy whose height was 140 cm (<3rd percentile). He did not have alopecia. There was moderate bowing of all leg bones and widening of wrist, knee, and ankle joints bilaterally. He walked with a waddling gate. Moderate enlargement of costochondral junction was noticed. His sister also found to have similar features.

Figures 1 and 2 shows deformity in the limbs of both the cases.

Investigations

Radiological studies of long bones of both the patient and his sister showed cupping, fraying, widening of metaphysis, osteopenia, and bowing. No pseudo fractures were observed.

Figures 3-6 shows the radiological changes including cupping, fraying, widening of metaphysis, and osteopenia in both the cases.

On biochemical studies, the serum calcium level and serum phosphorus level were within normal range for both the patient and his sister. The serum alkaline phosphate level were markedly increased for both of them, 25-hydroxyvitamin D was low and 1,25 dihydroxyvitamin D was strikingly raised in both. Twenty-four hour urinary calcium was high for the patient and low for his sister. Twenty-four hour urinary phosphorus was low for both [Table 1].

Their serum electrolytes and arterial blood gas analysis were within normal range. No abnormalities of fat malabsorption, acidosis, and liver or renal function could be demonstrated. His parents or other siblings did not show any clinical, radiological, or biochemical abnormalities suggestive of rickets.

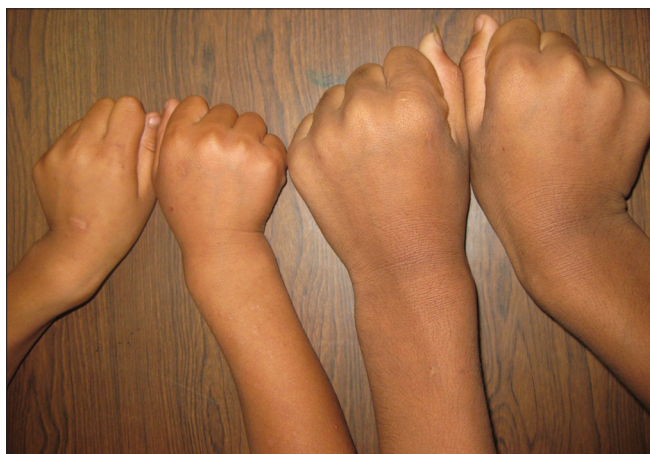

Figure 1: Deformity in the upper limbs in both the cases

With the above clinical, radiological, and biochemical parameter; familial vitamin D resistant rickets was diagnosed.

But, interestingly in both the cases described above in spite of having all the features of rickets, serum calcium level was persistently normal.

DISCUSSION

The patient and his sister both exhibited many of the classic clinical and biochemical features of rickets including progressive bowing of legs; widening of wrist, knee, and ankle joints; moderate enlargement of costochondral junctions with markedly raised serum alkaline phosphatase; low 25-hydroxyvitamin D; and strikingly raised 1,25-dihydroxyvitamin D.

In view of the striking increases in serum 1,25-dihydroxyvitamin D and the absence of evidence of poor nutrition, gastrointestinal malabsorption or noteworthy hepatic or renal disease, we attribute the clinical findings in our patient to impaired responsiveness of target organs to 1,25-dihydroxyvitamin D.

Both were treated with daily dose of oral calcium up to 3 g and 60,000 IU of vitamin D once weekly and asked for follow up after 3 months. On follow-up investigations, patient's 25-hydroxyvitamin D and 1,25-dihydroxyvitamin D level were 26.02 and 254.0, respectively; and for his sister the level were 30.83 and 190.1, respectively.

Unfortunately the patient refused further evaluation, and it is not known whether the skeletal lesions also responded to vitamin D. Finally, the mode of inheritance of the disorder in our patient is unknown. In fact, it has not been determined whether the defect is hereditary or

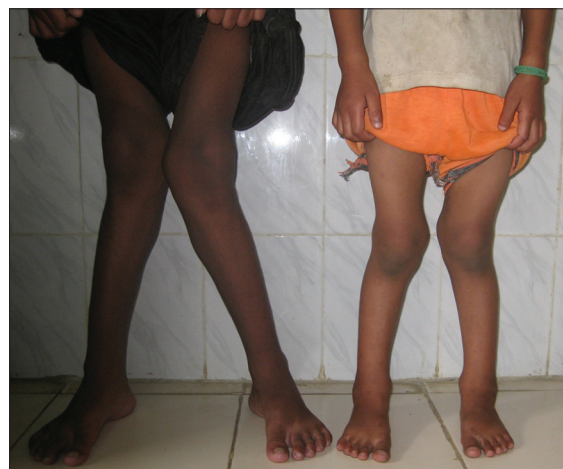

Figure 2: Deformity in the lower limbs in both the cases

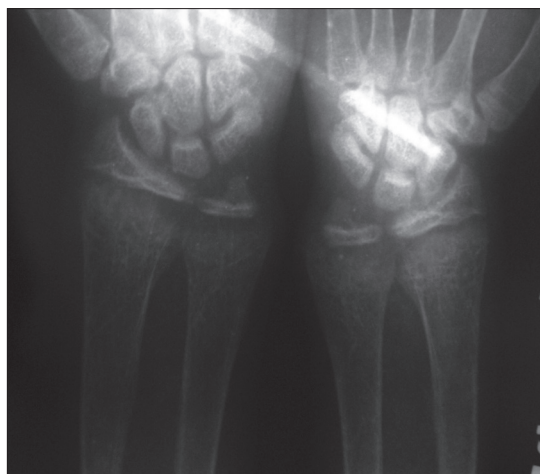


Figure 3: Radiological changes including cupping, fraying, widening of metaphysis, and osteopenia in upper limbs in the patient

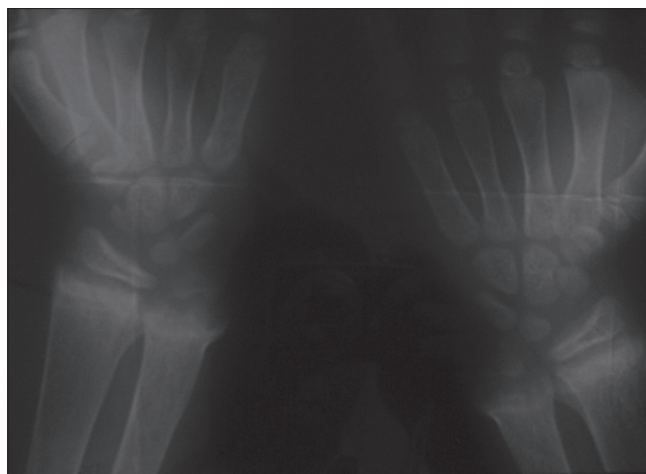

Figure 4: Radiological changes including cupping, fraying, widening of metaphysis, and osteopenia in upper limbs in the patient's sister

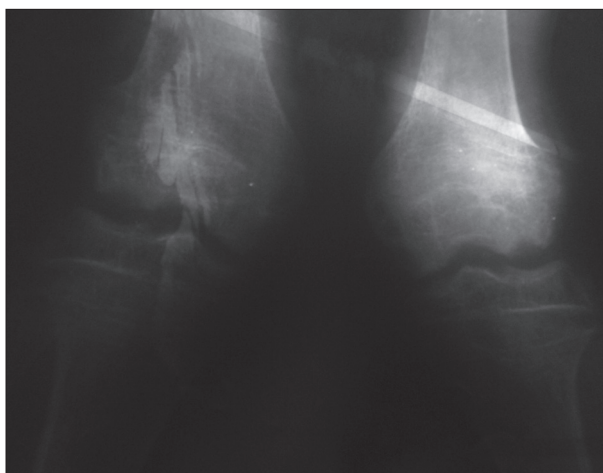

Figure 5: Radiological changes including cupping, fraying, widening of metaphysis, and osteopenia in lower limbs in the patient

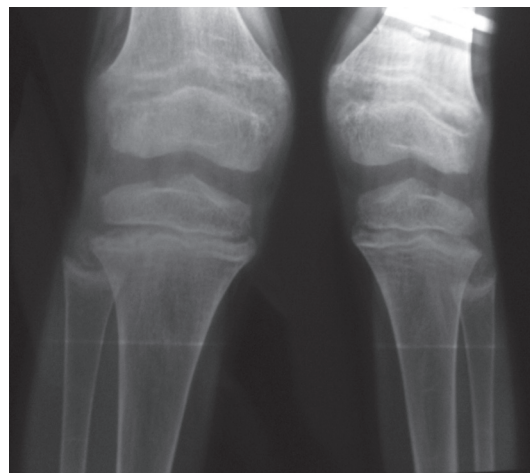


Figure 6: Radiological changes including cupping, fraying, widening of metaphysis, and osteopenia in lower limbs in the patient's sister

Table 1: Biochemical parameters

Investigations	Values for the patient	For patient's sister
S. calcium (8.3-10.3 mg/dl)	9.3	8.3
S. phosphorus (2.5-4.6 mg/dl)	2.6	3.1
S. ALP (175-420)	1,576	1,244
25 (OH) vitamin D (30-100 ng/ml)	4	24.3
1,25 (OH) vitamin D (19.6-54.3 pg/ml)	293.9	204.5
S. PTH (14-72 pg/ml)	30	49.1
24 h urinary calcium (8-11 mg/24 h)	1.5	16.8
24 h urinary phosphorus (400-1,300 g/24 h)	0.299	0.060

S.: Serum, ALP: Alkaline phosphatase, PTH: Parathyroid hormone

acquired. There have been several reports of the sporadic occurrence of vitamin D dependent rickets with onset in late childhood.^[6] It is not known whether the defect in these patients is similar to the one in our patient.

VDDR II is a hereditary disease of target organ resistance to 1,25-dihydroxyvitamin D which is a biologically active

metabolite of vitamin D. The characteristic clinical features of this disease are rickets, hypocalcemia, hypophosphatasia, secondary hyperparathyroidism, and elevated serum levels of alkaline phosphatase activity and 1,25-dihydroxyvitamin D. No appropriate guidelines for treatment of patients with VDDR II are available.^[7]

The success of the treatment is variable and depends on the degree of hormone resistance. When some VDR function is present, a pharmacologic rather than physiologic dose of calcitriol or alphacalcidol can improve calcium absorption and heal rickets. Severely affected individuals can be treated with calcium infusion.^[8,9]

ACKNOWLEDGEMENT

We would like to thank the Doctors from Orthopedic Department who referred the case to us and all the nursing staff for the great care provided.

REFERENCES

1. Albright F, Butler AM, Bloomberg E. Rickets resistant to vitamin D therapy. *AJDC* 1937;54:529-47.
2. Sahay M, Sahay R. Rickets-vitamin D deficiency and dependency. *Indian J Endocrinol Metab* 2012;16:164-76.
3. Fraher LJ, Karmali R, Hinde FR, Hendy GN, Jani H, Nicholson L, *et al.* Vitamin D-dependent rickets type II: Extreme end organ resistant to 1,25 dihydroxyvitamin D₃ in a patient without alopecia. *Eur J Pediatr* 1986;145:389-95.
4. Litman NN, Ulstrom RA, Westin WW. Vitamin D resistant rickets. *Calif Med* 1957;86:248-53.
5. Lips P. Vitamin D related disorders in primer on the metabolic bone disease and disorders of mineral metabolism. In: Rosen CJ, *et al.* editors. 7th ed. Washington: ASBMR. p. 329-35.
7. Fraser D, Scriver CR. Familial forms of vitamin D-resistant rickets revisited. X-linked hypophosphatemia and autosomal recessive vitamin D dependency. *Am J Clin Nutr* 1976;29:1315-29.
8. Ma NS, Malloy PJ, Pitukcheewanont P, Dreimane D, Geffner ME, Feldman D. Hereditary vitamin D resistant rickets: Identification of a novel splice site mutation in the vitamin D receptor gene and successful treatment with oral calcium therapy. *Bone* 2009;45:743-6.
9. Stamp WG, Whitesides TE, Field MH, Scheer GE. Treatment of vitamin-D resistant rickets-A long-term evaluation of its effectiveness. *J Bone Joint Surg Am* 1964;46:965-77.

Cite this article as: Choudhury S, Jebasingh KF, Ranabir S, Singh T. Familial vitamin D resistant rickets: End-organ resistance to 1,25-dihydroxyvitamin D. *Indian J Endocr Metab* 2013;17:S224-7.

Source of Support: Nil, **Conflict of Interest:** None declared.