

[ CASE REPORT ]

## A 29-year-old Woman with Recurrent Pregnancy-induced Hypertension Based on Vascular Compression of the Medulla Oblongata

Tetsuya Akaishi<sup>1</sup>, Hideyasu Kiyomoto<sup>2,3</sup>, Michiaki Abe<sup>1,3</sup>, Hiroshi Okuda<sup>1</sup>, Kota Ishizawa<sup>1</sup>, Toshiki Endo<sup>4</sup>, Masahiro Miyata<sup>5</sup>, Keisuke Nakayama<sup>5</sup>, Sadayoshi Ito<sup>3</sup>, Teiji Tominaga<sup>4</sup> and Tadashi Ishii<sup>1,2</sup>

### Abstract:

We present a report of a 29-year-old woman with non-dipper type refractory hypertension due to the vascular compression of the medulla oblongata. The patient was diagnosed with hypertension at 17 years of age and underwent emergency Caesarean section at 26 weeks of gestation during 2 pregnancies due to severe high blood pressure. We suspected medullary compression by the curved posterior inferior cerebellar artery as the cause of her intractable hypertension, and she underwent Jannetta's decompression surgery. After the surgery, her blood pressure swiftly decreased to almost within the normal range, and her blood pressure pattern normalized to dipper type.

**Key words:** non-dipper type, pregnancy-induced hypertension, intractable hypertension, Jannetta's decompression surgery, medullary compression

(Intern Med 58: 2257-2261, 2019)

(DOI: 10.2169/internalmedicine.2382-18)

### Introduction

Hypertension is typically categorized into two categories: essential hypertension without apparent known causes and secondary hypertension with known causes (1, 2). The causes of secondary hypertension include conditions such as renovascular hypertension, primary aldosteronism, thyroid dysfunction, pheochromocytoma, and drug-induced hypertension (3). Although rare, microvascular compression of the medulla oblongata has been suggested to cause intractable secondary hypertension in several previous reports (2, 4, 5). However, at present, whether or not medullary compression can really cause hypertension is unclear (6).

We herein report a young woman who was successfully treated for intractable hypertension caused by vascular compression of the medulla oblongata by Jannetta's decompression surgery.

### Case Report

The patient was 29 years old when she was referred to our university hospital by a previous doctor because of intractable hypertension during her second pregnancy at 17 weeks of gestation.

She had first been diagnosed with hypertension at 17 years of age and been treated with a calcium channel blocker for several years before stopping the medication prior to her first pregnancy. At 25 years of age, during her first pregnancy, she underwent an emergency Caesarean section because of abruptio placenta at 26 weeks of gestation. After the first delivery, her office blood pressure (OBP) was maintained within the normal range with a minimum dose of amlodipine (2.5 mg/day). At 29 years of age, she experi-

<sup>1</sup>Department of Education and Support for Regional Medicine, Tohoku University Hospital, Japan, <sup>2</sup>Department of Community Medical Supports, Tohoku Medical Megabank Organization, Japan, <sup>3</sup>Division of Nephrology, Endocrinology and Vascular Medicine, Tohoku University Hospital, Japan, <sup>4</sup>Department of Neurosurgery, Tohoku University Graduate School of Medicine, Japan and <sup>5</sup>RIFUNONAIKA CLINIC, Japan

Received: November 14, 2018; Accepted: February 7, 2019; Advance Publication by J-STAGE: April 17, 2019

Correspondence to Dr. Michiaki Abe, michiabe@med.tohoku.ac.jp

**Table. Laboratory and Imaging Studied at the First Visit of Our Hospital.**

WBC	7,800 / $\mu$ L	$\gamma$ -GTP	10 U/L	Ald	49.5 ng/dL
neu.	75 %	T-Bil	0.5 mg/dL	CRP	1.3 mg/dL
lym.	16 %	ChE	167 U/L	Urinalysis	
eos.	2 %	LDH	127 U/L	U-protein	(-)
bas.	0.08 %	Na	134 mEq/L	U-OB	(-)
mono.	6 %	K	3.8 mEq/L	Chest X ray	
RBC	412 $\times$ 10 <sup>4</sup> / $\mu$ L	Cl	101 mEq/L	CTR	43 %
Hb	12.8 g/dL	Ca	8.9 mg/dL	Resting ECG	
Hct	37.2 %	IP	3.3 mg/dL	normal sinus rhythm	
Plt	194 $\times$ 10 <sup>4</sup> / $\mu$ L	T-cho	138 mg/dL	68 bpm	
TP	6.2 g/dL	LDL	74 mg/dL	Cardiac ultrasonography	
Alb	3.4 g/dL	HDL	50 mg/dL	WT	(-)
BUN	10 mg/dL	TSH	0.78 $\mu$ IU/mL	EF	71 %
Cre	0.40 mg/dL	F-T3	1.36 pg/mL		
GOT	11 U/L	F-T4	1.08 ng/mL		
GPT	8 U/L	PRA	4.4 ng/mL/h		

All items in the panel, including thyroid functions, plasma renin activity, and serum aldosterone, were normal. WBC: white blood cell, neu.: neutrophil, lym.: lymphocyte, eos.: eosinophil, bas.: basophil, mono.: monocyte, RBC: red blood cell, Hb: hemoglobin, Hct: hematocrit, Plt: platelet, TP: total protein, Alb: albumin, BUN: blood urea nitrogen, Cre: creatinine, GOT: glutamic oxaloacetic transaminase, GPT: glutamic pyruvic transaminase,  $\gamma$ -GTP: gamma-glutamyl transpeptidase, T-Bil: total bilirubin, ChE: choline esterase, LDH: lactate dehydrogenase, T-cho: total cholesterol, LDL: low density lipoprotein, HDL: high density lipoprotein, TSH: thyroid-stimulating hormone, PRA: plasma renin activity, Ald: aldosterone, CRP: C reactive protein, OB: occult blood, CTR: cardiothoracic ratio, ECG: electrocardiogram, WT: wall thickening, EF: ejection fraction

enced her second pregnancy. Her blood pressure at this time was uncontrollable, and she was referred to our university hospital at 17 weeks of gestation. The results of laboratory tests and diagnostic examinations performed during the initial visit at our hospital are summarized in Table. We suspected essential hypertension and changed the antihypertensive treatment from amlodipine to  $\alpha$ -methyldopa (1,750-3,000 mg/day) and labetalol (150-300 mg/day). However, these agents were not sufficiently effective, and her blood pressure gradually increased to 180/125 mmHg at 25 weeks of gestation. Because of the uncontrollable hypertension, she again underwent a Caesarean section at 26 weeks of gestation. After the delivery, her blood pressure mildly decreased, but her OBP continued to be >150/110 mmHg, despite treatment with multiple hypertension medications. Her therapeutic course from the second pregnancy is shown in Fig. 1, along with the blood pressures measured during visits to the outpatient center. Her blood pressure was also observed by ambulatory blood pressure monitoring (ABPM) during and after the second delivery; results showed a riser blood pressure pattern during pregnancy (Fig. 2A) and non-dipper blood pressure pattern after pregnancy (Fig. 2B).

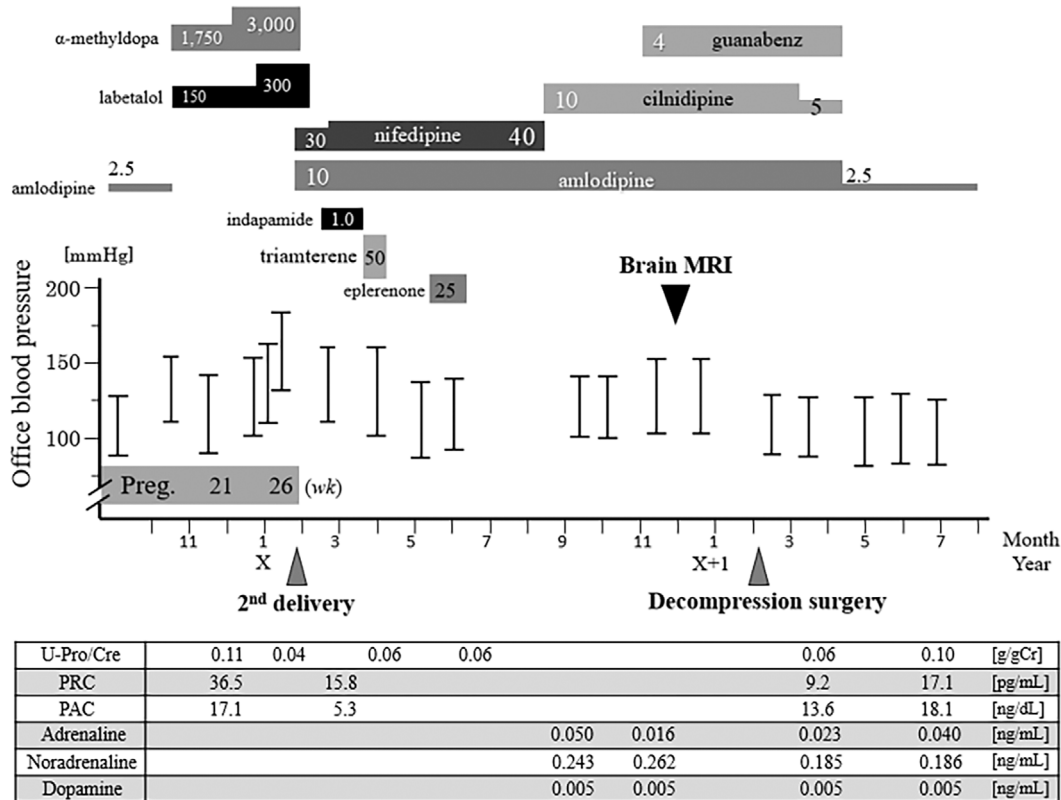
As the patient's intractable hypertension persisted even 10 months after the second delivery, we suspected that microvascular compression of the medulla oblongata might be involved. Magnetic resonance imaging (MRI) of the brain revealed severe compression at the left side of the medulla oblongata by the curved left posterior inferior cerebellar artery (PICA), as shown in Fig. 3A and B. She was referred to the Department of Neurosurgery for decompression sur-

gery to deal with the intractable hypertension that persisted even after the delivery. A preoperative assessment with echocardiography showed no findings suggestive of left ventricular hypertrophy or wall motion abnormalities.

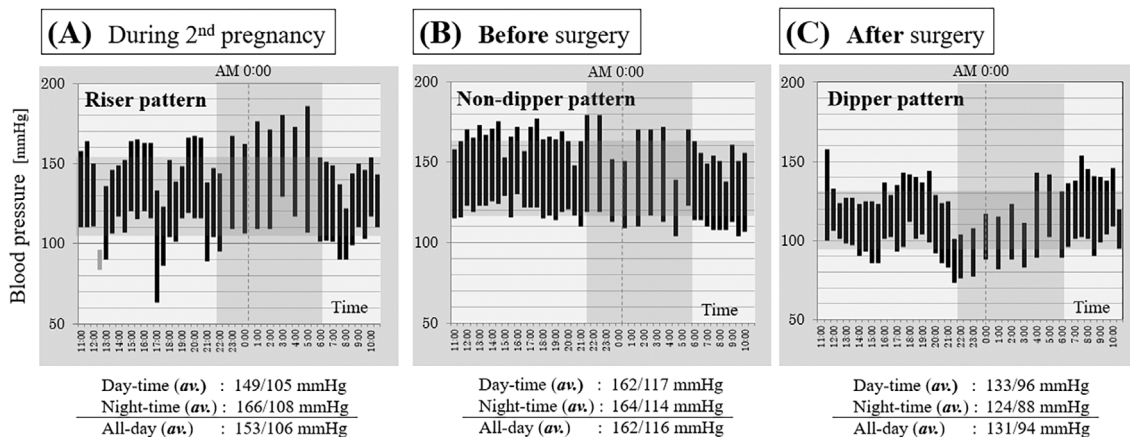
Twelve months after the delivery, the patient underwent Jannetta's decompression surgery with no adverse events (Fig. 4). After the vascular decompression, her blood pressure swiftly decreased to almost within the normal range, as shown on the right side of Fig. 1. An MRI scan of the medulla oblongata after the decompression surgery is shown in Fig. 3C. About one month after the decompression surgery, ABPM showed that her blood pressure had developed the normal dipper type blood pressure pattern (Fig. 2C). Consequently, the patient was able to stop taking antihypertensive medications except for a minimum dose of amlodipine (2.5 mg/day). The monthly measured OBP was also significantly decreased from 147.5 $\pm$ 11.7/100.7 $\pm$ 9.7 mmHg before the operation (n=6) to 127.8 $\pm$ 2.5/87.8 $\pm$ 5.3 mmHg (n=5) after the operation (p<0.01 for systolic; p<0.05 for diastolic). At present, more than three years after the decompression surgery, the patient is being treated with only one low-dose antihypertensive medication, and her blood pressure is well controlled below 130/85 mmHg.

## Discussion

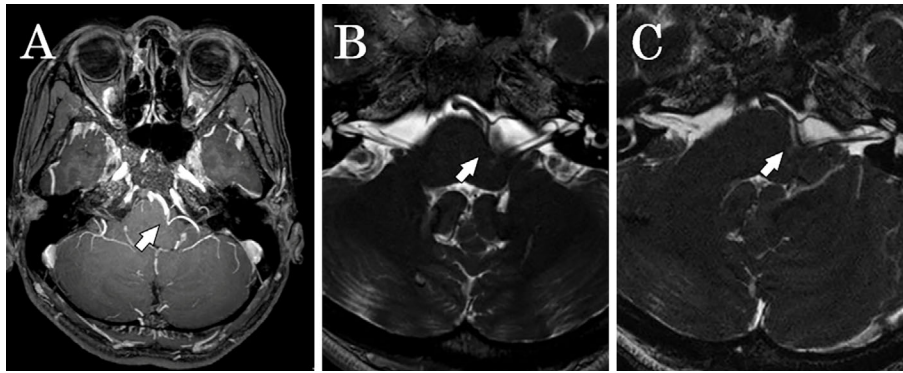
In this report, we described a young woman with intractable hypertension caused by microvascular compression of the medulla oblongata that was swiftly improved by decompression surgery. The patient underwent 2 Caesarean sec-



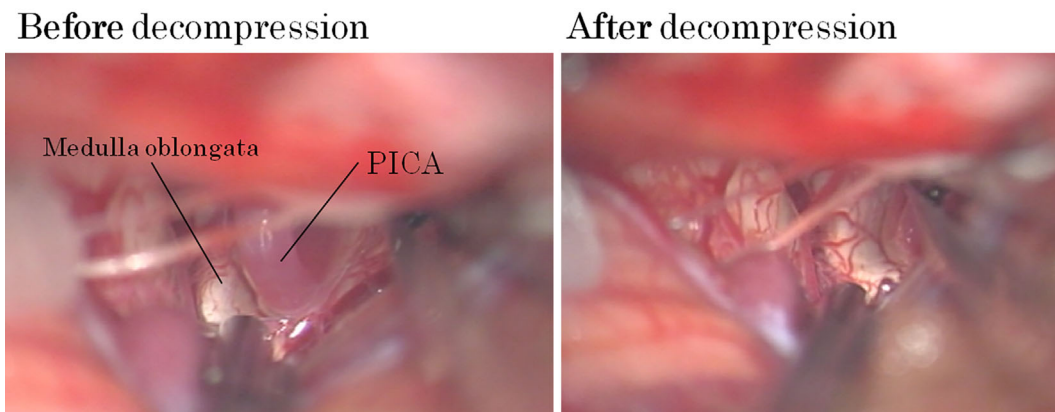
**Figure 1.** Clinical course of the present case with measured office blood pressure. The office blood pressure swiftly and significantly decreased after the decompression surgery. At present, the patient is being treated only with a minimum dose of amlodipine (2.5 mg/day), and her blood pressure is well controlled below 130/85 mmHg. The results of the blood test related to hypertension are listed at the bottom of this figure. Preg: pregnancy, wk: week, U-Pro/Cre: urinary protein/creatinine ratio, PRA: plasma renin activity, PAC: plasma aldosterone concentration



**Figure 2.** Ambulatory blood pressure monitoring before and after the decompression surgery. The pattern of ambulatory blood pressure monitoring (ABPM) before the decompression surgery (A, B) showed a riser/non-dipper-type pattern with an elevated blood pressure at midnight. The ABPM pattern after the decompression surgery (C) showed a normal dipper-type pattern with a decreased blood pressure during sleep. The time zone (vertical, dark gray) depicts nighttime as between 10:00 PM and 06:00 AM. The blood pressure zone (horizontal, dark gray) depicts the calculated average (av.) of the all-day blood pressure. The values of averaged day-time and night-time blood pressure are also written in each of the graphs.



**Figure 3.** Brain MRI findings before and after the decompression surgery. The medulla oblongata was severely compressed by the curved left posterior inferior cerebellar artery (white arrow) before the decompression surgery [A: contrast-enhanced 3D T1-weighted image, B: three-dimensional fast imaging employing steady-state acquisition (3D-FIESTA) sequence with a slice thickness of 2 mm]. After the decompression surgery (C: 3D-FIESTA sequence with a slice thickness of 2 mm), the curved posterior inferior cerebellar artery was successfully separated from the ventrolateral side of the medulla oblongata, and cerebrospinal fluid could be seen between the structures (white arrow).



**Figure 4.** Findings during the decompression surgery. Jannetta's decompression surgery was performed, and the compressing artery was separated from the ventrolateral side of the medulla oblongata. PICA: posterior inferior cerebellar artery

tions at 26 weeks of gestation (in different pregnancies) due to conditions possibly derived from uncontrolled hypertension during the pregnancies. She was diagnosed with essential hypertension when she was 17 years old and had never undergone brain MRI prior to delivering her second child.

A previous study has suggested an association between essential hypertension and activation of the rostral ventrolateral medulla (RVLM) (7). External compression or stimulation of RVLM by any of several causes (e.g., arteriovenous fistula, aneurysm, schwannoma, compression by curved artery) may result in intractable hypertension (8-12). Surgical intervention has been performed in several cases, and decompression surgery has been reported to be effective in most instances (10, 13-16). As in our case, the blood pressure is predicted to swiftly and markedly decrease after decompression surgery. This drastic decrease in blood pressure after surgery therefore requires careful perioperative management in case of hypotension or cerebral infarction (10).

In the present case, the patient underwent two premature deliveries because of untreated RVLM compression by the PICA. If she had been treated with decompression surgery ahead of pregnancy, the pregnancies might have continued to the normal term. It would have been unusual had her physicians dismissed the possibility of RVLM compression, as she had been diagnosed with essential hypertension since the age of 17. RVLM compression-based secondary hypertension is a rare but surgically treatable condition. Based on our experience with this case, we recommend that brain MRI be performed at least once in young patients with intractable essential hypertension.

### Conclusion

Vascular compression of the medulla oblongata, particularly that of the RVLM, can cause secondary hypertension that is often refractory to antihypertensive drugs. If such compression is overlooked before pregnancy, it can result in premature delivery. Young patients with intractable hyperten-

sion without known causes should undergo brain MRI at least once to rule out vascular compression of the medulla oblongata.

**The authors state that they have no Conflict of Interest (COI).**

#### Financial Support

This work was supported by JSPS KAKENHI Grant Number JP 16K08487.

#### Acknowledgement

The authors thank the patient for her supportive cooperation during the treatment. The authors also thank Dr. Shunji Mugikura (Department of Diagnostic Radiology, Tohoku University Hospital) for the radiological assessment and professional comments.

#### References

1. Freel EM, Connell JM. Mechanisms of hypertension: the expanding role of aldosterone. *J Am Soc Nephrol* **15**: 1993-2001, 2004.
2. Vongpatanasin W. Resistant hypertension: a review of diagnosis and management. *JAMA* **311**: 2216-2224, 2014.
3. Faselis C, Doumas M, Papademetriou V. Common secondary causes of resistant hypertension and rational for treatment. *Int J Hypertens* **2011**: 236239, 2011.
4. Boogaarts HD, Menovsky T, de Vries J, et al. Primary hypertension and neurovascular compression: a meta-analysis of magnetic resonance imaging studies. *J Neurosurg* **116**: 147-156, 2012.
5. Akimura T, Furutani Y, Jimi Y, et al. Essential hypertension and neurovascular compression at the ventrolateral medulla oblongata: MR evaluation. *AJNR Am J Neuroradiol* **16**: 401-405, 1995.
6. Ceral J, Zizka J, Elias P, et al. Neurovascular compression in essential hypertension: cause, consequence or unrelated finding? *J Hum Hypertens* **21**: 179-181, 2007.
7. Kumagai H, Oshima N, Matsuura T, et al. Importance of rostral ventrolateral medulla neurons in determining efferent sympathetic nerve activity and blood pressure. *Hypertens Res* **35**: 132-141, 2012.
8. Kan P, Couldwell WT. Posterior fossa brain tumors and arterial hypertension. *Neurosurg Rev* **29**: 265-269; discussion 269, 2006.
9. Lin CH, Lo YK, Lin YT, et al. Central vasomotor failure in a patient with medulla arteriovenous fistula. *Acta Neurol Taiwan* **15**: 192-196, 2006.
10. Kamel MH, Mansour NH, Mascott C, et al. Compression of the rostral ventrolateral medulla by a vagal schwannoma of the cerebellomedullary cistern presenting with refractory neurogenic hypertension: case report. *Neurosurgery* **58**: E1212; discussion E212, 2006.
11. Ozer H, Uzma O, Albayram S, et al. Possible electrical stimulation on rostral ventrolateral medulla that causes significant hypertensive and tachycardic changes during endovascular treatment of a PICA aneurysm abutting the left medullary sulcus. *AJNR Am J Neuroradiol* **26**: 522-524, 2005.
12. Ideguchi M, Kajiwara K, Yoshikawa K, et al. Continuous hypertension and tachycardia after resection of a hemangioblastoma behind the dorsal medulla oblongata: relationship to sympathetic overactivity at the neurogenic vasomotor center. *J Neurosurg* **113**: 369-373, 2010.
13. Ren J, Sun H, Diao Y, et al. Successful treatment with microvascular decompression surgery of a patient with hemiparesis caused by vertebral artery compression of the medulla oblongata: case report and review of the literature. *World Neurosurg* **108**: 994 e11-994 e19, 2017.
14. Ozyurt E, Oguzoglu SA, Kaya AH, et al. [Surgical treatment of essential hypertension resistant to medical treatment: Report of two cases]. *Anadolu Kardiyol Derg* **2**: 40-44, AXVII, 2002.
15. Sasaki S, Tanda S, Hatta T, et al. Neurovascular decompression of the rostral ventrolateral medulla decreases blood pressure and sympathetic nerve activity in patients with refractory hypertension. *J Clin Hypertens (Greenwich)* **13**: 818-820, 2011.
16. Morimoto S, Sasaki S, Takeda K, et al. Decreases in blood pressure and sympathetic nerve activity by microvascular decompression of the rostral ventrolateral medulla in essential hypertension. *Stroke* **30**: 1707-1710, 1999.

The Internal Medicine is an Open Access journal distributed under the Creative Commons Attribution-NonCommercial-NoDerivatives 4.0 International License. To view the details of this license, please visit (<https://creativecommons.org/licenses/by-nc-nd/4.0/>).