



Case Report

Amyand hernia; a case report on serendipitous intra-operative diagnosis

Binit Upadhaya Regmi^a, Pawan Singh Bhat^b, Sujan Bohara^{b,*}, Srijan Malla^b, Jyoti Rayamajhi^b, Samikshya Karki^c, Utsab Adhikari^d, Sushil Bahadur Rawal^b

^a Jibjibe Primary Health Care Center, Rasuwa, Nepal

^b Department of General and Gastrointestinal Surgery, Nepal Medcity Hospital, Lalitpur, Nepal

^c Spinal Injury Rehabilitation Center, Kavre, Nepal

^d Nepalese Army Institute of Health Science, Kathmandu, Nepal

ARTICLE INFO

Keywords:

Amyand hernia

Inguinal hernia

Appendectomy

ABSTRACT

Introduction and Importance: Amyand hernia is an accidental finding that occurs in 0.19–1.7% of patients with inguinal hernia, with children being more commonly affected than adults. However, the management depends on the guidelines given by Losanoff and Basson.

Case Presentation: A 62-year-old male presented with complaints of progressive swelling in the right inguinal region without any clinical spectrum of bowel obstruction or strangulation. Examination revealed a right-sided indirect inguinal hernia with positive Ziemann technique. Open hernioplasty revealed an appendix within a hernia sac and was found to be adhered to the surrounding structure with a fibrotic band. According to the Losanoff and Basson protocol, the patient had an appendectomy and an open mesh repair with polypropylene mesh without any post-operative complications.

Clinical Discussion: Amyand hernia are often predominantly present in children, with a rare presence in the elderly. Pre-operative clinical diagnosis remains a challenge, and the management depends upon the Losanoff and Basson protocol. Appendectomy of the normal appendix within the hernia sac is often recommended to prevent the sequelae (appendicitis, rupture) following manipulation during hernioplasty.

Conclusion: Amyand's hernia is a rare clinical entity and difficult to diagnose due to its uncomplicated presentation. Nevertheless, the progress of appendix inflammation, the possibility of abdominal sepsis, and comorbidities should all be taken into consideration when deciding how to manage individual patients.

1. Introduction

Amyand hernia implies the finding of the incarcerated vermiform appendix (either inflamed or not) within the hernia sac of an inguinal hernia [1,2]. It has been reported in patients aged ranging from 3 weeks (neonates) to 92 years, with varying incidence ranging from 0.19% to 1.7% among reported hernia cases and 0.1% when associated with acute appendicitis [1–3]. Amyand hernia prevails more in children (approximately 3 times) than adults because of the patency of the processus vaginalis in children [1,2]. The management of amyand hernia mostly depends upon the classification and surgical management protocol by Losanoff and Basson [4].

Herein, we report a case of a 62-year-old male with an Amyand hernia, discovered incidentally intraoperatively, and discuss the

management of this rare case. This case is reported in accordance with SCARE guidelines [5].

2. Case Presentation

A 62-year-old male with no known comorbidities and a significant past history presented to our surgical outpatient care with a complaint of progressive swelling in the right inguinal region for 4 months without any signs and symptoms of bowel obstruction or strangulation and a history of fever, weight loss, and lower urinary tract infections. He was an ex-alcoholic but non-smoker. Patient denied any history of similar illness or significant family and allergic history.

On examination, his vital parameters and systemic examination revealed no deviation from normal findings. An examination of the right

* Corresponding author.

E-mail addresses: regmi.binit@gmail.com (B.U. Regmi), pbs1982@hotmail.com (P.S. Bhat), mjsujan777@gmail.com (S. Bohara), srijanmalla@gmail.com (S. Malla), jrayamajhi000@gmail.com (J. Rayamajhi), smilyg938@gmail.com (S. Karki), utsab.me111@gmail.com (U. Adhikari), sushilrawal85@yahoo.com (S.B. Rawal).

<https://doi.org/10.1016/j.amsu.2022.104554>

Received 3 August 2022; Received in revised form 27 August 2022; Accepted 27 August 2022

Available online 2 September 2022

2049-0801/© 2022 The Authors. Published by Elsevier Ltd on behalf of IJS Publishing Group Ltd. This is an open access article under the CC BY-NC-ND license (<http://creativecommons.org/licenses/by-nc-nd/4.0/>).

inguinal region was significant for swelling of 2×2 cm above the right inguinal ligament, pyriform in shape, smooth surface, normal skin (absence of erythema or fistula or sinus), no local rise in temperature, non-tender, soft in consistency, positive impulse on coughing, reducible without scrotal involvement. On the Ziemann technique, an impulse is felt on the index finger (suggestive of indirect inguinal hernia) and there is no bulging on the ring occlusion test. However, no obvious abnormality was present in the left inguinal region. With these clinical findings, the patient was clinically diagnosed with an indirect right-sided inguinal hernia (Nyhus Classification—Type 1).

Routine baseline laboratory investigations were within normal limits. As the patient had no clinical presentation or biochemical variables of compromised bowel, we did not undergo any radiological imaging like ultrasonography (USG) of the abdomen or scrotal region. Following discussion with the patient, he was scheduled for open mesh repair under spinal anesthesia. A general consultant surgeon with prior experience performed the operation. An open mesh repair with polypropylene mesh and appendectomy was done for the right-sided indirect sliding hernia with a defect (approximately 4×3 cm) with the appendix as content within the hernia sac (Fig. 1). An appendix with fibrotic adhesions to surrounding structures was evident, for which adhesiolysis was done. Furthermore, histo-pathological examination of the appendix was suggestive of normal appendix. The postoperative period was uneventful, and follow-up of the patient after 7 days and 30 days remains unremarkable.

3. Discussion

Claudius Amyand, an English surgeon, performed the first appendectomy on an 11-year-old boy with an inguinal incarcerated sac containing a perforated appendix, presenting with right inguinal hernia and a fecal fistula on December 6th, 1735 [2]. An Amyand's hernia is an atypical and rare clinical phenomenon in which an inguinal hernia sac entangles an inflamed, non-inflamed, or perforated vermiform appendix [6,7]. It has been reported predominantly in children, in men compared to women, and on the right side. But in our case, it was an adult male patient. However, in situs inversus, gastro-intestinal malrotation, large

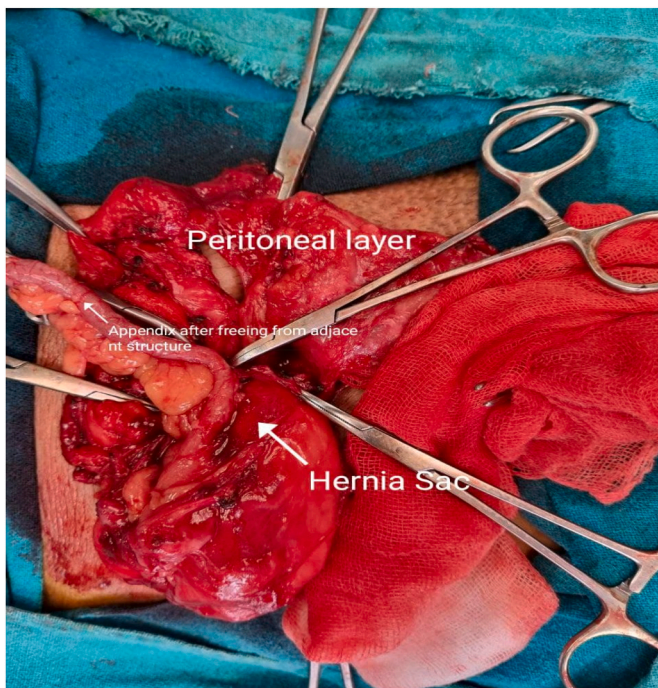


Fig. 1. Photograph showing the appendix (after freeing from adjacent structures) in Amyand type of Hernia.

appendix, or loose cecum remain an exception in which the location of the appendix remains on the left side. Amyand hernia may be chaperoned in some cases by the omentum, cecum, Meckel diverticulum, ovaries, or fallopian tube [2]. In our case, the amyand hernia is on the right side.

Though the pathogenesis of the association of acute appendicitis with Amyand hernia is unknown, studies have proposed two possible mechanisms [8]: (i) inflammation caused by appendix compression due to muscle contraction or an abrupt acute increase in intra-abdominal pressure; and (ii) appendicitis caused by extra-luminal obstruction caused by pressure in the hernia's neck.

Pre-operative clinical diagnosis of Amyand's hernia remains a challenge due to the variable clinical presentation [1,2]. Majorly, it presents with clinical symptoms of pain confined to the right lower quadrant along with an irreducible painful mass in the inguinal or inguinoscrotal region as a provisional clinical diagnosis of incarcerated hernia. Therefore, acute appendicitis within an inguinal hernia sac is taken into consideration [9]. Generally, diagnosis of inguinal hernias is done based on clinical history and examination; imaging (*trans*-abdominal ultrasonography and computed tomography) is not routinely practiced despite being the modality of choice for diagnostic workup of acute abdomen and hernia. And, if done, they are designed to prevent intentional abdominal pathology [1,7]. Some authors have reported preoperative diagnosis of it via imaging modalities [2,7]. Imaging modalities were not in our case as there were no evident features of bowel obstruction and deranged biochemical variables. However, definitive diagnosis is made intra-operatively as an incidental finding and surgical options remain within the hands of surgeons because of the absence of actual management protocol [1]. Losanoff and Basson described the classification (Table 1) system of different subtypes and surgical management protocol of Amyand hernia [4].

Though management protocols for Amyand hernia were developed, performing an appendectomy in the absence of an inflamed appendix remained a point of contention. Ivashchuk et al. suggested an appendectomy only for an inflamed appendix [1], while Kuru et al. supported an appendectomy even in a normal appendix given impending future complications secondary to minor trauma on hernia repair [10]. As our patient had an appendix with fibrotic adhesion to the surrounding hernia sac without any features suggestive of acute appendicitis, he was considered to be a case of normal appendix and thus he was managed as a Type 1 Amyand hernia as per Losanoff and Basson classification and underwent a mesh repair with an appendectomy. Furthermore, the nature of the resected appendix was confirmed by histopathological examination.

4. Conclusions

Due to their unusual and rare character, as well as their diverse clinical presentation, they are frequently diagnosed during surgery.

Table 1

Losanoff and Basson classification and surgical management guideline of Amyand's hernia [4].

Types	Features	Surgical management
I	Normal appendix within an inguinal hernia	Reduction or appendectomy (according to age), mesh repair (hernioplasty)
II	Acute appendicitis localized within a hernia sac (no abdominal sepsis)	Appendectomy through hernia, endogenous repair of hernias (no mesh)
III	Acute appendicitis within an inguinal hernia sac along with peritoneal sepsis	Appendectomy through laparotomy, primary repair of hernia (no mesh)
IV	Acute appendicitis within an inguinal hernia along with other related or unrelated abdominal pathology	Appendectomy, symptomatic workup and procedures as appropriate.

Following that, the choice of a surgical technique is made based on the patient's circumstances, the clinical situation, the type of Amyand's hernia, and recommendations made by Losanoff and Basson.

The takeaway message is that while amyand hernia may appear in an uncomplicated pattern within an inguinal sac, the status of the appendix determines whether to undergo hernia repair with or without mesh repair.

Patient's perspectives

The patient was thankful to the surgical team for curing his condition with an appendectomy in one setting.

Sources of funding

All authors declare that this research did not receive any specific grant or funding from funding agencies in the public, commercial, or not-for-profit sectors.

Ethical approval

This case report did not require ethical approval from ethics committee.

Consent

Written informed consent was obtained from the patient for publication of this case report and accompanying images. A copy of the written consent is available for review by the editor-in-chief of this journal on request.

Declaration of competing interest

All authors declare that they have no conflict of interest.

Provenance and peer review

Not commissioned, externally peer reviewed.

Research registration

N/A.

Guarantor

Dr. Pawan Singh Bhat.

CRediT authorship contribution statement

Binit Upadhaya Regmi: Conceptualization, Writing – review & editing. **Pawan Singh Bhat:** Supervision, Writing – review & editing. **Sujan Bohara:** Data curation, Supervision, Writing – original draft, Writing – review & editing. **Srijan Malla:** Writing – review & editing. **Jyoti Rayamajhi:** Writing – review & editing. **Samikshya Karki:** Conceptualization, Writing – review & editing. **Utsab Adhikari:** Writing – review & editing. **Sushil Bahadur Rawal:** Supervision, Writing – review & editing.

Acknowledgments

The authors wish to acknowledge the patient included in this report.

Appendix A. Supplementary data

Supplementary data to this article can be found online at <https://doi.org/10.1016/j.amsu.2022.104554>.

References

- [1] G. Ivashchuk, et al., Amyand's hernia: a review, *Med. Sci. Mon. Int. Med. J. Exp. Clin. Res.* 20 (2014) 140–146.
- [2] A. Morales-Cárdenas, et al., Amyand hernia: case report and review of the literature, *Ann. Med. Surg.* 4 (2015) 113–115.
- [3] K. Holmes, J.E. Guinn, Amyand hernia repair with mesh and appendectomy, *Surg. Case Reports* 5 (2019) 3–6.
- [4] J.E. Losanoff, M.D. Basson, Amyand hernia: a classification to improve management, *Hernia* 12 (2008) 325–326.
- [5] R.A. Agha, et al., The SCARE 2020 guideline: updating consensus surgical CAsE REport (SCARE) guidelines, *Int. J. Surg.* 84 (2020) 226–230.
- [6] S.I. Bhatti, et al., Amyand's hernia: a rare surgical pathology of the appendix, *Cureus* 10 (2018) 3–7.
- [7] A. Kaymakci, et al., Amyand's hernia: a series of 30 cases in children, *Hernia* 13 (2009) 609–612.
- [8] Y. Gao, et al., Amyand's hernia: a 10-year experience with 6 cases, *BMC Surg.* 21 (2021) 1–6.
- [9] H. Sharma, A. Gupta, N.S. Shekhawat, B. Memon, M.A. Memon, Amyand's hernia: a report of 18 consecutive patients over a 15-year period, *Hernia* 11 (2007) 31–35.
- [10] S. Kuru, A. Bulgurcu, K. Kismet, E. Ertas, Should an appendectomy be performed for the treatment of amyand's hernia with non-inflamed vermiform appendix? A case report and review of the literature, *Viz. Gastrointest. Med. Surg.* 29 (2013) 51–54.