

Transplantation of Achilles Tendon Treated With Bone Morphogenetic Protein 7 Promotes Meniscus Regeneration in a Rat Model of Massive Meniscal Defect

Nobutake Ozeki,¹ Takeshi Muneta,² Hideyuki Koga,² Hiroki Katagiri,² Koji Otabe,² Makiko Okuno,² Kunikazu Tsuji,² Eiji Kobayashi,³ Kenji Matsumoto,⁴ Hirohisa Saito,⁴ Tomoyuki Saito,⁵ and Ichiro Sekiya²

Objective. This study was undertaken to examine whether bone morphogenetic protein 7 (BMP-7) induces ectopic cartilage formation in the rat tendon, and whether transplantation of tendon treated with BMP-7 promotes meniscal regeneration. Additionally, we analyzed the relative contributions of host and donor cells on the healing process after tendon transplantation in a rat model.

Methods. BMP-7 was injected in situ into the Achilles tendon of rats, and the histologic findings and gene profile were evaluated. Achilles tendon injected with 1 μ g of BMP-7 was transplanted into a meniscal defect in rats. The regenerated meniscus and articular cartilage were evaluated at 4, 8, and 12 weeks. Achilles tendon from LacZ-transgenic rats was transplanted into the meniscal defect in wild-type rats, and vice versa.

Results. Injection of BMP-7 into the rat Achilles tendon induced the fibrochondrocyte differentiation of tendon cells and changed the collagen gene profile of tendon tissue to more closely approximate meniscal tissue. Transplantation of the rat Achilles tendon into a meniscal defect increased meniscal size. The rats that received the tendon treated with BMP-7 had a meniscus matrix that exhibited increased Safranin O and type II collagen staining, and showed a delay in articular cartilage degradation. Using LacZ-transgenic rats, we determined that the regeneration of the meniscus resulted from contribution from both donor and host cells.

Conclusion. Our findings indicate that BMP-7 induces ectopic cartilage formation in rat tendons. Transplantation of Achilles tendon treated with BMP-7 promotes meniscus regeneration and prevents cartilage degeneration in a rat model of massive meniscal defect. Native cells in the rat Achilles tendon contribute to meniscal regeneration.

The meniscus is a fibrocartilaginous tissue that contributes to several critical functions within the knee joint, such as load bearing (1), shock absorption (2), and joint stability. A meniscal tear is one of the most common injuries of the knee joint, primarily due to sports injuries or degenerative conditions (3,4). Suture repair of meniscus tears is recommended when feasible to preserve the function of meniscal tissue. However, suture repair is typically only suitable for acute tears that have a longitudinal orientation, although repairs of other more complex acute tears can be selectively performed (5,6). Meniscectomy (partial or total) is the most

Supported by the Ministry of Education, Culture, Sports, Science, and Technology of Japan (Project for Realization of Regenerative Medicine and Global Center of Excellence Program grants).

¹Nobutake Ozeki, MD: Tokyo Medical and Dental University, Tokyo, Japan, and Yokohama City University, Yokohama, Japan; ²Takeshi Muneta, MD, PhD, Hideyuki Koga, MD, PhD, Hiroki Katagiri, MD, Koji Otabe, MD, Makiko Okuno, MD, Kunikazu Tsuji, PhD, Ichiro Sekiya, MD, PhD: Tokyo Medical and Dental University, Tokyo, Japan; ³Eiji Kobayashi, MD, PhD: Jichi Medical University, Shimotsuke, Japan; ⁴Kenji Matsumoto, MD, PhD, Hirohisa Saito, MD, PhD: National Research Institute for Child Health and Development, Tokyo, Japan; ⁵Tomoyuki Saito, MD, PhD: Yokohama City University, Yokohama, Japan.

Dr. Kobayashi is the Chief Scientific Advisor for Otsuka Pharmaceutical Factory, Japan.

Address correspondence to Ichiro Sekiya, MD, PhD, Department of Applied Regenerative Medicine, Graduate School, Tokyo Medical and Dental University, 1-5-45 Yushima, Bunkyo-ku, Tokyo 113-8519, Japan. E-mail: sekiya.arm@tmd.ac.jp.

Submitted for publication April 23, 2012; accepted in revised form July 16, 2013.

common arthroscopic procedure performed on the knee joint (7), but it is correlated with a degenerative change in the articular cartilage and the progression of osteoarthritis (4,8). It has been reported that meniscal allograft transplantation can provide improvements in pain and function in the short and intermediate term. However, the effects of allografts on the prevention of joint degeneration are still unknown (9,10), and the use of allograft menisci have not been approved in several countries, including Japan. The development of synthetic meniscus transplant technology is ongoing and has been met with variable degrees of success to date (11–13).

Autologous tendon grafts are one of the materials used for meniscal reconstruction (14,15). A tendon graft offers the advantages of safety, utility, and biologic properties similar to the peripheral half of the native meniscus (16). In a sheep model, the patellar tendon graft became similar to the original meniscus at 12 months after transplantation. However, in a human clinical study, meniscal reconstruction with semitendinosus tendon or patellar tendon graft has not yet been shown to prevent the progression of cartilage degeneration (15).

The outcome of tendon transplantation for meniscal defect may be improved by additional procedures, one of which is the use of growth factors. Bone morphogenetic protein 7 (BMP-7) is currently used to accelerate bone union for delayed union of fractures in clinical situations (17–19). Recent studies have demonstrated that weekly intraarticular injection of a low dose of BMP-7 prevented the degenerative changes common to cartilage in an experimental osteoarthritis model and in an inflammatory arthritis model, without inducing ectopic ossification (20–22). These results indicate that BMP-7 may promote cartilage formation rather than bone formation in joint conditions. The purposes of this study were 1) to examine whether BMP-7 induces ectopic cartilage formation in tendon, 2) to investigate whether the transplantation of tendon treated with BMP-7 promotes meniscal regeneration, and 3) to analyze the relative contribution of host and donor tissue on the healing process after tendon transplantation in a rat model.

MATERIALS AND METHODS

Animals. Wild-type male Lewis rats (Charles River Japan) and LacZ-expressing-transgenic rats (23) (provided by Jichi Medical University, Tochigi, Japan) ages 10–12 weeks were used for the experiments. Rats were anesthetized by isoflurane inhalation and intraperitoneal injection of tribromoethanol. All animal care and experiments were conducted in

accordance with the institutional guidelines of the Animal Committee of Tokyo Medical and Dental University.

In situ BMP-7 injection into the rat Achilles tendon. A straight skin incision was made to expose the Achilles tendon, followed by an injection of 0.1, 0.5, or 1 μ g of BMP-7 (Stryker Biotech) in 10 μ l of phosphate buffered saline (PBS) with a 31-gauge needle (Figure 1A). After closure of the incision, the rats were allowed to walk freely in their cages and were then killed at 2, 3, or 4 weeks for evaluation of ectopic cartilage formation.

Oligonucleotide microarray. RNA was isolated from normal rat tendon, normal rat meniscus, normal rat articular cartilage with subchondral bone, and rat tendon treated with BMP-7 which had been injected in situ 4 weeks prior ($n = 4$ rats per group), using TRIzol solution (Invitrogen Life Technologies) and cleaned using a High Pure RNA Isolation kit (Roche Applied Sciences). A microarray analysis was performed using 3 μ g of total RNA from each sample, and GeneChip Rat Genome 230 2.0 probe arrays (Affymetrix) according to the manufacturer's instructions (24). Data were analyzed with GeneSpring GX software version 7.3.1 (Agilent Technologies). To normalize the variations in staining intensity among chips, the signal values for all genes on a given chip were divided by the median value for the expression of all genes on the chip. To eliminate genes containing only a background signal, genes were selected only if the raw values of the signal were more than the lower limit of the confidence interval and expression of the gene was judged to be "present" by GeneChip Operating Software version 1.4 (Affymetrix). The microarray data were deposited in the Gene Expression Omnibus (25) (GEO accession no. GSE24612). Genes that met these quality criteria were subjected to further analysis. An unsupervised hierarchical clustering analysis was performed using a minimum distance value of 0.001, a separation ratio of 0.5, and the standard definition of the correlation distance. A dendrogram was obtained from hierarchical clustering analysis using average linkage and a distance metric equal to 1 minus the Pearson correlation coefficient applied to the microarray data.

Real-time quantitative polymerase chain reaction (qPCR). First-strand complementary DNAs (cDNAs) were synthesized using a Transcriptor First-Strand cDNA synthesis kit (Roche), and qPCR analyses were performed using a LightCycler 480 Probe Master system (Roche). β -actin was used as an internal control. Relative messenger RNA expression levels were calculated as described by Niikura et al (26). PCR primers were as follows: for aggrecan, 5'-GCAGGATAACGGACTGAAG-3' (forward) and 5'-GAGTAAAGTGGTCATAGTTCAGCTTG-3' (reverse); for COL1A1, 5'-TCCTGGCAAGAACGGAGAT-3' (forward) and 5'-CAGGAGGTCCACGCTCAC-3' (reverse); for COL2A1, 5'-CCAGGTCTGCTGGAAAA-3' (forward) and 5'-CCTCTTTCTCCGGCCTTT-3' (reverse). Data are expressed as the fold change relative to native tendon.

Transplantation of autologous rat Achilles tendon treated with BMP-7. Achilles tendon was harvested from the right paw and molded into a similar size as the meniscus with both ends ligated by 6-0 nylon sutures. The left knee joint was exposed with a straight skin incision on the anterior side of the knee. After the patellar tendon was dislocated laterally and the anterior insertional ligament of the medial meniscus

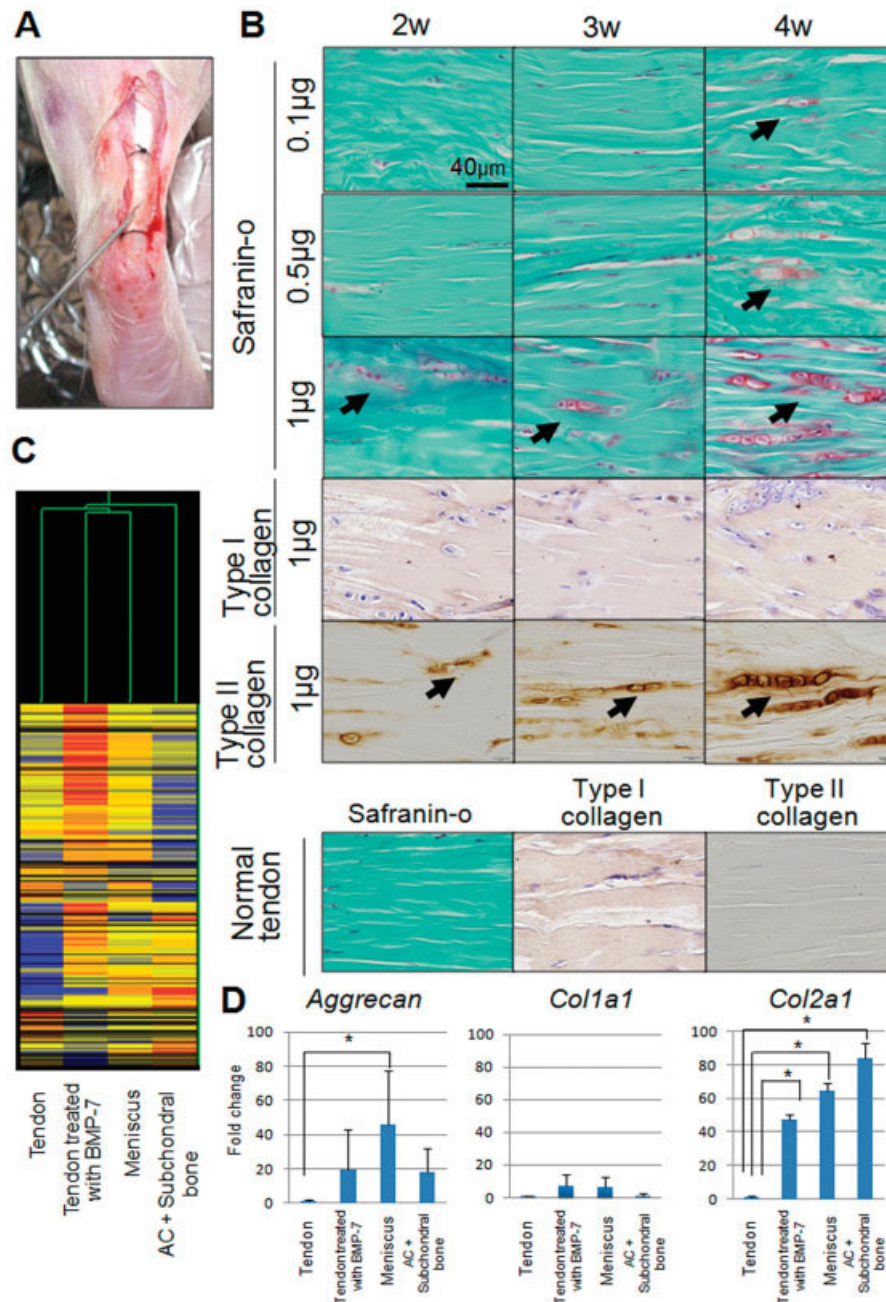


Figure 1. Effect of in situ bone morphogenetic protein 7 (BMP-7) injection into the rat Achilles tendon. **A**, Procedure used to inject BMP-7 into the rat Achilles tendon. **B**, Histologic examination of rat Achilles tendon stained with Safranin O and immunostained with type I and type II collagen. **Arrows** indicate ectopic chondrocyte formation. **C**, Dendrogram generated from microarray analysis of native rat tendon, rat tendon treated with 1 μg of BMP-7 4 weeks before analysis, native rat meniscus, and native rat articular cartilage (AC) with subchondral bone. **D**, Results of polymerase chain reaction analysis of aggrecan, *Col1a1*, and *Col2a1*. Bars show the mean \pm SD expression level relative to the expression level in native tendon (n = 4 rats per group). * = $P < 0.05$ by Kruskal-Wallis test.

was transected, the anterior half of the medial meniscus was dislocated and resected at the level of the medial collateral ligament. Then, 1 μg of BMP-7 in 10 μl of PBS was injected with a 31-gauge needle into the prepared Achilles tendon, and

the tendon was transplanted into the meniscal defect and sutured with the capsule and medial collateral ligament with 6-0 nylon sutures. The rats were allowed to walk freely in their cages and then killed at 4, 8, or 12 weeks (BMP-7-treated

tendon group; n = 6). The same numbers of rats underwent transplantation surgery with Achilles tendon untreated with BMP-7 (tendon group; n = 6) or meniscectomy only (untreated group; n = 6).

Transplantation of Achilles tendon into the meniscal defect using transgenic rats expressing LacZ. The Achilles tendon from LacZ-expressing-transgenic rats was transplanted into the meniscal defect in wild-type rat knees. Conversely, the Achilles tendon from wild-type rats was transplanted into the meniscal defect in LacZ-expressing-transgenic rat knees. At 4 weeks, the transplanted tendon and surrounding area were evaluated (n = 4 rats per group).

Macroscopic observation. The tibial plateau with menisci was carefully separated from the femoral condyle. Macroscopic pictures were taken using an Olympus MVX10 microscope on a dedicated medical photography platform. Quantification of the size of the regenerated meniscus was performed using AxioVision Rel software version 4.8 to measure the ratio of the whole area of the medial meniscus, including both the regenerated region and the normal region, to the whole area of the medial tibial plateau.

Histologic examination. Regenerated rat meniscal tissue and proximal tibia were fixed in 4% paraformaldehyde for 7 days, decalcified in 20% EDTA solution for 10 days or 21 days, respectively, and then embedded in paraffin wax. The specimens were sectioned in the sagittal plane at 5 μm and stained with Safranin O-fast green. Histologic sections were visualized using an Olympus BX53 microscope. Regenerated meniscus was evaluated using the modified Pauli score on a scale of 0–18 points (27) (see Supplementary Table 1, available on the *Arthritis & Rheumatism* web site at <http://online.library.wiley.com/doi/10.1002/art.38099/abstract>). Cartilage degeneration of the medial tibia was evaluated using the Mankin score, on a scale of 0–14 points (28). As a control, a 22-week-old normal rat was evaluated for both meniscus and cartilage injury.

Immunohistochemistry. Paraffin-embedded sections were deparaffinized in xylene, rehydrated in graded alcohol, and washed in PBS. Then the samples were pretreated with 0.4 mg/ml proteinase K (Dako) in Tris HCl buffer for 15 minutes at room temperature for optimal antigen retrieval. All subsequent incubations were performed in a humidified chamber. Endogenous peroxidases were quenched using 0.3% hydrogen peroxidase in methanol for 15 minutes at room temperature. Any residual enzymatic activity was removed by washing with PBS, and nonspecific antigen was blocked by preincubation with PBS containing 10% normal horse serum (Vector) for 20 minutes at 4°C. Primary antibodies (rabbit anti-type I collagen; 1:200 dilution [Abcam] and human anti-type II collagen; 1:200 dilution [Daiichi Fine Chemical]) were applied to sections and kept overnight at 4°C for type I collagen and incubated at room temperature for 1 hour for type II collagen. After extensive washes with PBS, the sections were incubated in the secondary antibody biotinylated goat anti-rabbit IgG for type I collagen (1:200 dilution; Vector) or biotinylated horse anti-mouse IgG for type II collagen (1:200 dilution; Vector) for 30 minutes at room temperature. Immunostaining was detected with Vectastain ABC reagent (Vector) followed by diaminobenzidine staining. The sections were counterstained with hematoxylin.

Detection of LacZ expression. After either LacZ-transgenic rats or wild-type rats were killed, the tibial condyle

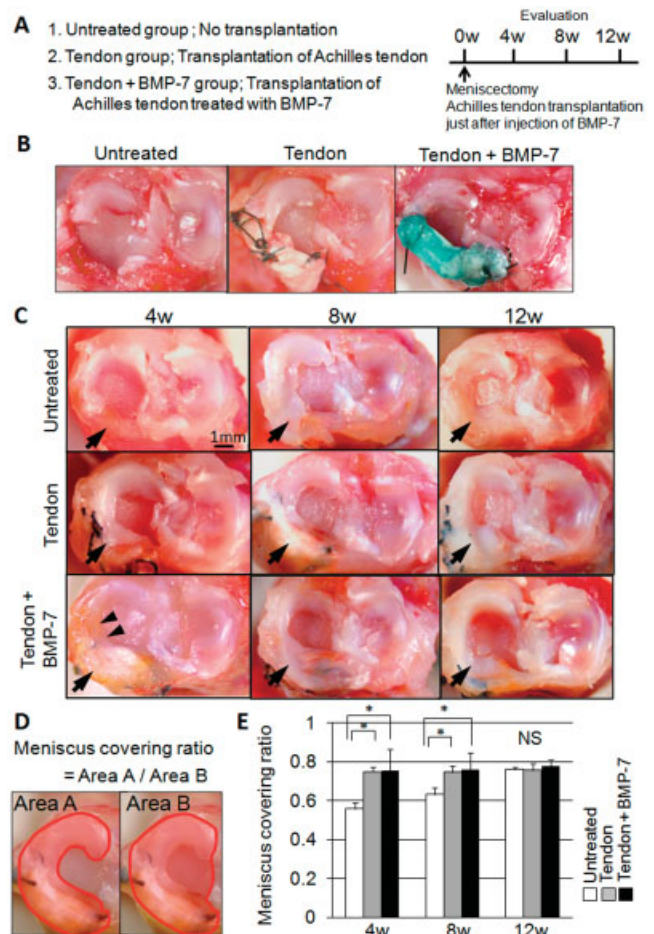


Figure 2. Macroscopic analyses of transplantation of Achilles tendon treated with bone morphogenetic protein 7 (BMP-7) into meniscal defects in rats. **A**, Study scheme. **B**, Procedure used for the surgery. The anterior half of the medial meniscus was resected (untreated group), then transplantation of Achilles tendon was performed (tendon group). In the third group, Achilles tendon was transplanted just after injection of BMP-7 (tendon + BMP-7 group). BMP-7 solution with dying agent is indicated in blue. **C**, Macroscopic features. **Arrows** indicate the resected site; **arrowheads** indicate integration sites of regenerated tissue and native meniscus. **D**, Method of determining the “meniscus covering ratio,” defined as the ratio of medial meniscus area to medial plateau area. **E**, Meniscus covering ratio. Bars show the mean ± SD (n = 6 rats per group). * = P < 0.05 by non-repeated-measures analysis of variance. NS = not significant. Color figure can be viewed in the online issue, which is available at <http://online.library.wiley.com/doi/10.1002/acr.38099/abstract>.

with meniscal tissue was separated from the femoral condyle and fixed with a fixative solution (0.2% glutaraldehyde, 2 mM MgCl₂, and 5 mM EDTA) in PBS for 30 minutes at room temperature and rinsed 3 times in PBS to wash out the fixative solution. The tissue was then treated with an X-Gal staining solution (1 mg/ml X-Gal, 2 mM MgCl₂, 6 mM potassium ferricyanide, and 6 mM potassium ferrocyanide) under incubation at 37°C for 3 hours. Sections were subsequently fixed

again in 4% paraformaldehyde, following separation of meniscal tissue from the tibial condyle. The meniscal tissue was decalcified with 0.5M EDTA (pH 7.5) for 10 days, and embedded in paraffin wax, following sectioning and counterstaining with eosin.

Statistical analysis. StatView 5.0 (SAS Institute) was used for statistical analyses. Non-repeated-measures analysis of variance was performed for analysis of the meniscus covering ratio, and the Kruskal-Wallis test was performed for analysis of PCR results, the modified Pauli score, and the Mankin score. *P* values less than 0.05 were considered significant.

RESULTS

Ectopic fibrocartilage formation in rat Achilles tendons after in situ BMP-7 injections. BMP-7 was injected into the rat Achilles tendon to examine ectopic fibrochondrocyte formation (Figure 1A). When 0.1 or 0.5 μg of BMP-7 was injected, slight cartilage matrix staining with Safranin O was first observed 4 weeks after injection (Figure 1B). When 1 μg of BMP-7 was injected, cartilage matrix staining with Safranin O and immunostaining with type II collagen were first observed 2 weeks after injection, and increased at 3 and 4 weeks. Protein expression of type I collagen did not change with BMP-7 treatment (Figure 1B). These findings indicate that in situ injection of 1 μg of BMP-7 induced ectopic fibrocartilage formation in the rat Achilles tendon, as demonstrated histologically by increased Safranin O staining (Figure 1B).

For microarray analysis, we extracted 374 probes (198 genes) with annotation information containing the key word "collagen" from public databases (Ensembl, Entrez Gene, Swiss Prot, EC, OMIM, Gene Ontology, and InterPro) by using GeneSpring software (see Supplementary Table 2, available on the *Arthritis & Rheumatism* web site at <http://onlinelibrary.wiley.com/doi/10.1002/art.38099/abstract>). Microarray analysis demonstrated that the gene expression related to collagens in the rat tendon treated with BMP-7 was more similar to that in native meniscus than to that in native tendon or articular cartilage with subchondral bone (Figure 1C) (see Supplementary Tables 2 and 3, available on the *Arthritis & Rheumatism* web site at <http://onlinelibrary.wiley.com/doi/10.1002/art.38099/abstract>). PCR analysis revealed that the expression of *Col2a1* was significantly more up-regulated in rat tendon treated with BMP-7 than in native tendon, and *Col2a1* expression levels in BMP-7-treated tendon were similar to those in native meniscus and articular cartilage with subchondral bone (Figure 1D).

Promotion of meniscal regeneration by transplantation of rat Achilles tendon treated with BMP-7. We next investigated the effectiveness of the transplan-

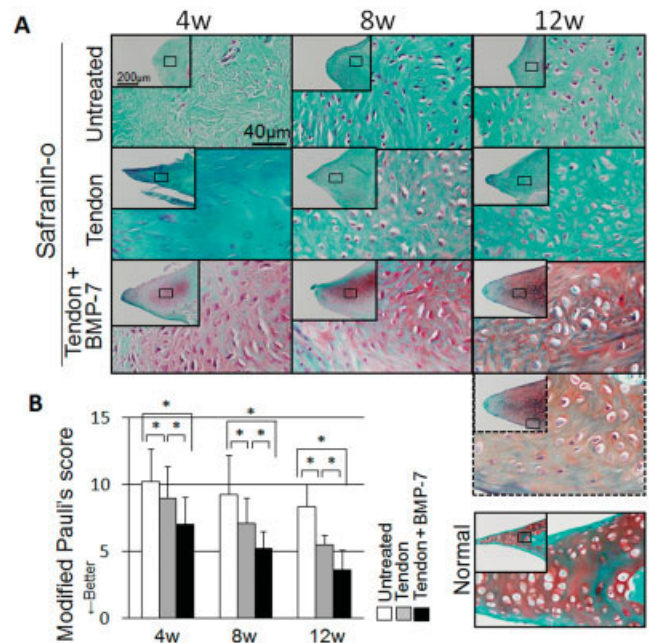


Figure 3. Histologic analysis of regenerated rat meniscus. **A**, Sections from untreated rats, rats that received transplantation of untreated Achilles tendon (tendon), and rats that received transplantation of bone morphogenetic protein 7 (BMP-7)-treated Achilles tendon (tendon + BMP-7), stained with Safranin O 4 weeks, 8 weeks, and 12 weeks after surgery. The boxed areas in the insets are shown at a higher-magnification view in the larger panels. Broken lines indicate the outer zone of the regenerated meniscus in a rat that received BMP-7-treated tendon. **B**, Modified Pauli's scores for histology. Bars show the mean \pm SD ($n = 6$ rats per group). * = $P < 0.05$ by Kruskal-Wallis test. Color figure can be viewed in the online issue, which is available at <http://onlinelibrary.wiley.com/doi/10.1002/acr.38099/abstract>.

tation of autologous rat Achilles tendons treated with 1 μg of BMP-7 in a model of massive meniscal defect (Figures 2A and B). Macroscopically, in the untreated group, the meniscal defect was only filled with synovial tissue 4 and 8 weeks after meniscectomy. Irrespective of BMP-7 treatment, the meniscal defect was repaired as early as 4 weeks after transplantation of Achilles tendon (Figure 2C), and regenerated tissue was integrated with native meniscus (arrowheads in Figure 2C). The meniscus covering ratio (Figure 2D) was smaller in the untreated group than in the other 2 groups 4 and 8 weeks after transplantation (Figure 2E).

Histologically, at 4 weeks, coarse tissue was observed in the untreated rats and tendon tissue was observed in the rats that received transplantation of untreated Achilles tendon. Matrix stained with Safranin O and immunostained with type II collagen was observed in the central portion of the regenerated meniscus at 4 weeks in the rats that received transplantation of

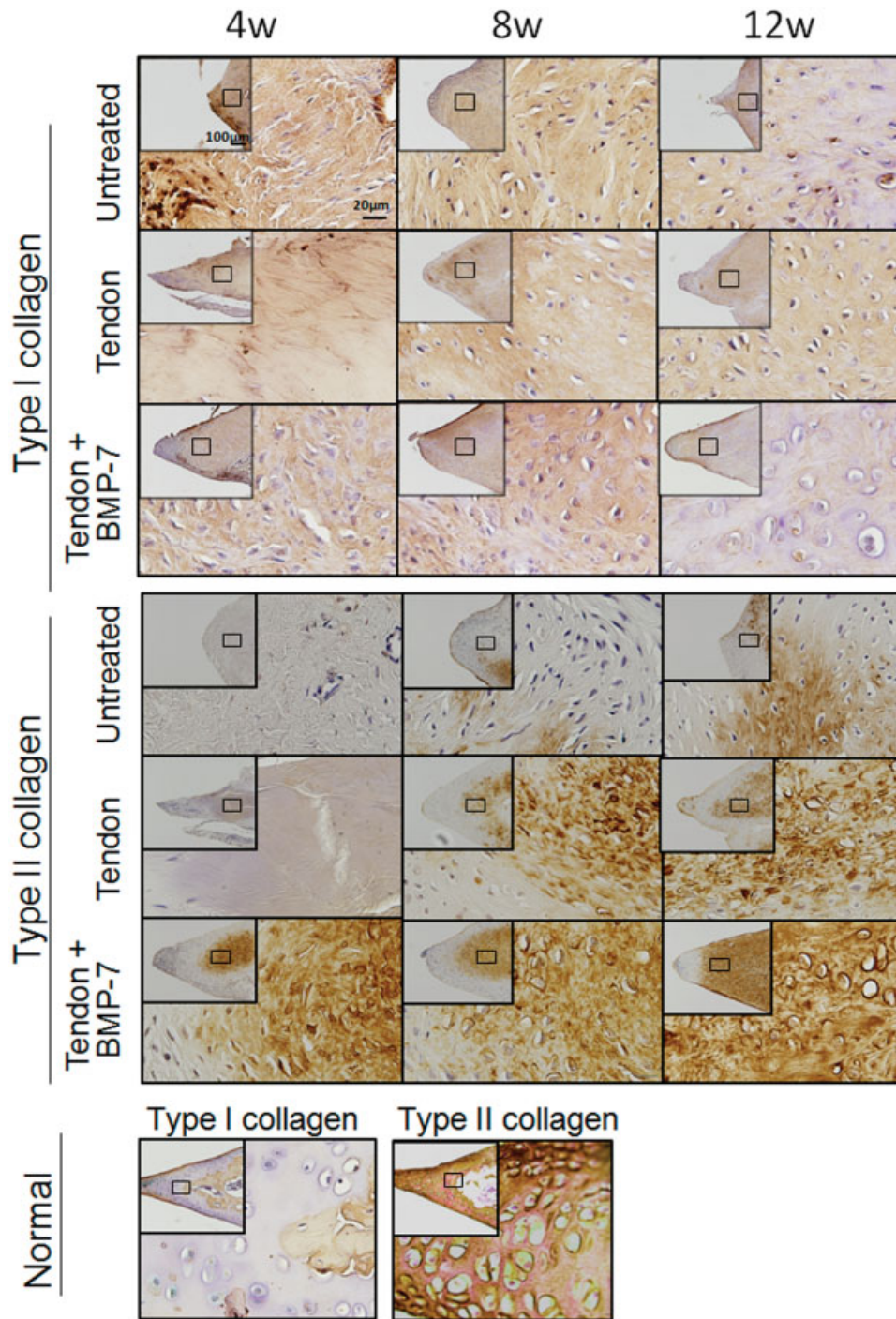


Figure 4. Immunohistochemical analysis for type I collagen and type II collagen in the regenerated meniscus of normal rats, rats that received transplantation of bone morphogenetic protein 7 (BMP-7)-treated tendon (tendon + BMP-7), rats that received transplantation of untreated tendon (tendon), and untreated rats, 4 weeks, 8 weeks, and 12 weeks after surgery. The boxed areas in the insets are shown at a higher-magnification view in the larger panels. Color figure can be viewed in the online issue, which is available at <http://onlinelibrary.wiley.com/doi/10.1002/acr.38099/abstract>.

BMP-7-treated tendon (Figures 3A and 4), whereas matrix immunostained with type II collagen increased at 8 weeks in the rats that received untreated tendon and at

12 weeks in the untreated group. Lacuna formation was observed at 12 weeks in the rats that received BMP-7-treated tendon, and the morphology of the cells became

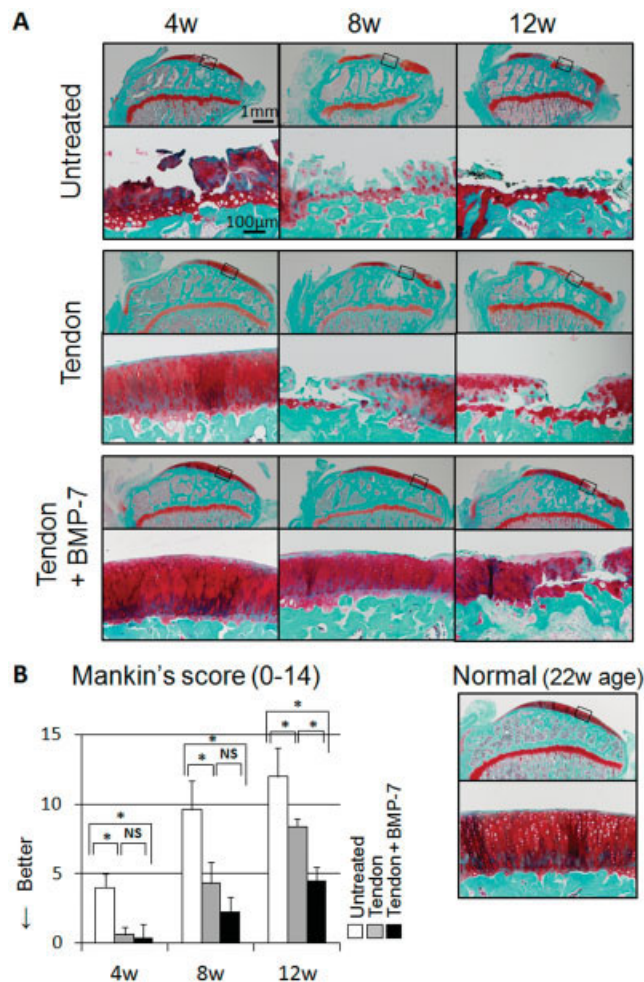


Figure 5. Histologic analysis of rat articular cartilage at the medial tibial plateau. **A**, Sagittal sections from untreated rats, rats that received transplantation of untreated Achilles tendon (tendon), and rats that received transplantation of bone morphogenetic protein 7 (BMP-7)-treated Achilles tendon (tendon + BMP-7), stained with Safranin O 4 weeks, 8 weeks, and 12 weeks after surgery. A section from a 22-week-old normal rat was used as a control. Boxed areas in the top panels are shown at a higher-magnification view in the bottom panels. **B**, Mankin scores. Bars show the mean \pm SD ($n = 6$ rats per group). * = $P < 0.05$ by Kruskal-Wallis test. NS = not significant. Color figure can be viewed in the online issue, which is available at <http://onlinelibrary.wiley.com/doi/10.1002/acr.38099/abstract>.

closer to that of normal meniscal cells. In the regenerated meniscus, increased matrix staining with Safranin O was more apparent in the inner zone than in the outer zone, though the morphology of the cells was similar (Figure 3A, broken line). The pattern of distribution of type I collagen was nearly identical between the rats that received BMP-7-treated tendon and the normal group at 12 weeks (Figure 4). An improved modified Pauli

score was observed in the rats that received BMP-7-treated tendon compared to the untreated group at 4, 8, and 12 weeks (Figure 3B).

While cartilage degeneration was observed as early as 4 weeks after meniscectomy in the untreated group, it was nearly absent in the other 2 groups (Figure 5A). Though cartilage degeneration progressed further thereafter in all of the groups, the Mankin score at 12 weeks was best in the rats that received BMP-7-treated tendon (Figure 5B). These results indicate that transplantation of rat Achilles tendon treated with BMP-7 promoted meniscal regeneration and delayed cartilage degeneration.

Detection of donor rat tendon cells and host rat synovial cells in and around the transplanted tendon. Finally, to analyze the relative contributions of host and donor tendon cells to the healing process after tendon transplantation, we used transgenic rats expressing LacZ. When the Achilles tendon of LacZ-transgenic rats was transplanted into the meniscal defect in wild-type rat knees (Figure 6A), LacZ expression was still detected in transplanted tissue macroscopically (Figure 6B, left panel) and histologically (Figure 6B, right panel) 4 weeks after transplantation, though the LacZ-positive area was decreased.

When the Achilles tendon of wild-type rats was transplanted into meniscal defects in LacZ-transgenic rats (Figure 6C), tissue derived from the LacZ host rats was stained with X-Gal macroscopically 4 weeks after transplantation (Figure 6D, left and middle panels). Histologically, in the LacZ host rat, the LacZ-positive cells were detected within the synovial tissue, which covered the transplanted tendon (Figure 6D, right panel).

DISCUSSION

In this study, the transplantation of Achilles tendon into meniscal defects in rats regenerated tissue that covered the tibial plateau more effectively than tissue in untreated defects. When BMP-7 was injected into the rat tendon before transplantation, the matrix of the regenerated meniscus increased, as indicated by Safranin O and type II collagen staining, and articular cartilage degeneration was delayed.

It is well known that BMPs induce ectopic ossification in adults (29) and induce ectopic cartilage formation during development (30,31). In this study, we demonstrated that the in situ injection of BMP-7 induced ectopic fibrocartilage formation in the rat Achilles tendon and changed the collagen gene profile to more

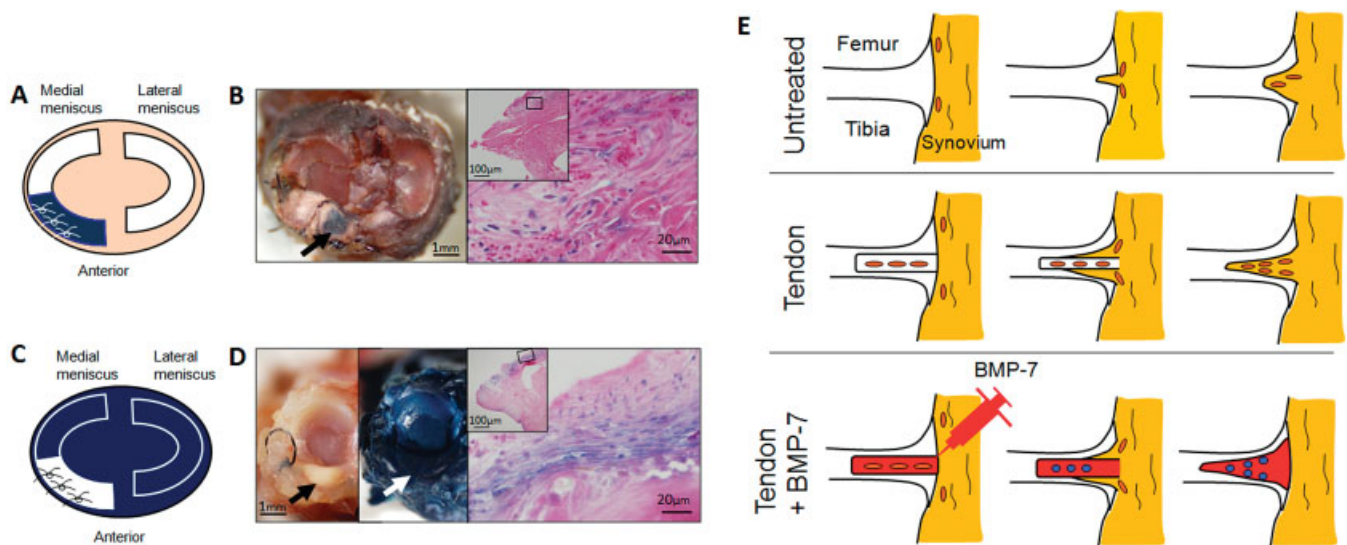


Figure 6. A, Illustration of transplantation of Achilles tendon from a LacZ-transgenic rat into the meniscus of a wild-type rat. B, Macroscopic (left) and histologic (right) analysis of sections from a wild-type rat that received transplantation of Achilles tendon from a LacZ-transgenic rat. Macroscopic features of the tibial plateau with medial and lateral menisci 4 weeks after transplantation are shown. Whole tissue was stained with X-Gal. **Arrow** indicates the LacZ-positive area. Histologic analysis showed LacZ-positive cells (blue) in transplanted tendon at 4 weeks. The boxed area in the **inset** is shown at a higher-magnification view in the larger panel. C, Illustration of transplantation of Achilles tendon from a wild-type rat into the meniscus of a LacZ-transgenic rat. D, Macroscopic (left and middle) and histologic (right) analysis of sections from a LacZ-transgenic rat that received transplantation of Achilles tendon from a wild-type rat. Macroscopic features of the medial tibial plateau left unstained (left) or stained with X-Gal (middle) 4 weeks after transplantation are shown. **Arrows** indicate the transplantation site. Histologic analysis of transplanted tendon stained with X-Gal was performed at 4 weeks. The boxed area in the **inset** is shown at a higher-magnification view in the larger panel. E, Possible mechanism of meniscus regeneration by transplantation of Achilles tendon treated with bone morphogenetic protein 7 (BMP-7) in a rat model of massive meniscal defect. In the untreated group, only a small amount of synovium filled the space of the meniscal defect, and it did not mature into meniscus. In the rats that received transplantation of untreated tendon, the transplanted tendon played the role of scaffold, synovium covered the tendon, and both promoted meniscus regeneration. In the rats that received transplantation of tendon treated with BMP-7, in addition to the effect of tendon transplantation, BMP-7 induced chondrocyte differentiation of tendon cells, and consequently meniscus regeneration was enhanced. Color figure can be viewed in the online issue, which is available at <http://onlinelibrary.wiley.com/doi/10.1002/acr.38099/abstract>.

closely resemble meniscal tissue than tendon tissue. Questions remain as to whether the fibrocartilage formation further progresses toward ossification, whether other BMPs could have similar effects, and whether there are dose-response effects when using doses outside of the range we tested. We do not have the answers to all of these questions at present, but the ectopic fibrocartilage formation observed was promisingly generated in tendon tissue using the experimental conditions described and was the rationale for transplanting the fibrocartilaginous tissue into the meniscal defect in experiments performed thereafter.

For meniscus regeneration or the enhancement of meniscus repair, many approaches using scaffolds, cells, and/or growth factors have been described (11,12,32–35). One method for repair is tendon graft substitution, but it has not previously shown positive results without further modification (14,15). BMP-7 is a critical factor for the development of skeletal growth

(36) and plays important roles in the homeostasis of cartilage and in cartilage repair (37–40). Also, BMP-7 has been shown to be safe for use in humans with its clinical application in the delayed union of bone fractures (17,19). Therefore, we examined the effect of BMP-7 on the enhancement of meniscus regeneration after tendon transplantation.

In this study, we demonstrated that the transplantation of Achilles tendon treated with BMP-7 promoted meniscus regeneration in a rat model of massive meniscal defect and prevented degeneration of articular cartilage. Macroscopically, a greater amount of regenerated meniscus was obtained in the tendon transplantation groups. Histologically, the regenerated meniscus appeared to be most similar to native meniscus in the rats that received transplantation of BMP-7-treated tendon. From these findings, we summarized the possible mechanism of meniscus regeneration in this rat model (Figure 6E).

When meniscal defects are not treated, seemingly only a small amount of synovial tissue including certain kinds of progenitor cells fills the meniscal defect, but the regenerated tissue is too small and too poor to prevent cartilage degeneration. When tendon is transplanted into meniscal defects, it apparently plays a role as a scaffold for meniscal regeneration from very early stages, and is covered by synovium. However, the tendon fails to convert to the fibrocartilage present in the native meniscus. When tendon treated with BMP-7 is transplanted into a meniscal defect, the tendon serves as a scaffold, and the addition of BMP-7 promotes the fibrocartilage differentiation of tendon cells to enhance matrix synthesis.

For the regenerated meniscus, biomechanical testing was not performed. Therefore, we cannot confirm that the regenerated meniscus has the same biomechanical properties as the normal meniscus, though the histologic features were close to those of the native meniscus. However, transplantation of the Achilles tendon treated with BMP-7 delayed cartilage degeneration when compared to the other 2 groups tested. These chondroprotective features suggest that the biomechanical properties of the regenerated tissue in the rats that received transplantation of BMP-7-treated tendon were closer to those of the native rat meniscus than in the tendon alone and empty defect groups.

One of the limitations of this study is the different properties of the small animal and human meniscus. It has been shown that the meniscus in small animals is more cellular than that of the human meniscus (41). Distributions of type I and type II collagen are similar but not identical (42,43). Furthermore, it has been shown that the rat meniscus occasionally ossifies (44), and our experimental tissue-processing conditions used EDTA, which decalcified the tissues, thereby precluding the detection of any significant ossification. Therefore, the results of our study providing evidence of meniscal regeneration though the procedure must be translated to studies in higher mammalian organisms and human trials, given the species differences in the meniscus, to ensure that the clinically relevant regenerated meniscus in tendons treated with BMP-7 are most similar to that of the native meniscus.

To date, there have been no studies describing cell remodeling experiments to determine the fate of transplanted cells and to identify the relative contributions of host and donor tissue to the healing process in the transplantation of tendon for meniscal defect. Our findings suggest that the cell viability of the transplanted tissue is relevant, which is an important finding, since

some of the literature on meniscus transplantation suggests that donor cell viability declines in the weeks after transplantation (45), though Verdonk et al found that cell viability from the donor tissue remains even up to 1 year after surgery (46). Controversy remains regarding whether the residual cells within the tendon graft remain alive or disappear in the process of remodeling during autologous anterior cruciate ligament reconstruction (47).

When the Achilles tendon of LacZ-transgenic rats was transplanted into the meniscal defect in wild-type rat knees in our study, LacZ expression was partially detected in transplanted tissue. This indicates that the original cells within the tendon remained alive and contributed to meniscal regeneration. When the Achilles tendon of wild-type rats was transplanted into meniscal defects in LacZ-transgenic rat knees, transplanted tissue was covered by synovium of LacZ-transgenic rat origin. This indicates that synovial coverage by the host knee joint plays an important role in support of meniscus remodeling and regeneration.

The LacZ-positive area decreased 4 weeks after the Achilles tendon of LacZ-transgenic rats was transplanted into the meniscal defect in wild-type rat knees. The experiment with LacZ-transgenic rats involved a syngeneic transplantation model, and LacZ expression may also have affected immunoreaction. Other studies have used an autologous transplantation model (14,15). Therefore, contributions of host and donor cells in autologous tendon transplantation may differ from those found in the present study.

In conclusion, we have demonstrated that the transplantation of Achilles tendon treated with BMP-7 promoted meniscus regeneration in a rat model of massive meniscal defect and prevented cartilage degeneration. This may be a promising future procedure for the treatment of meniscal defects.

ACKNOWLEDGMENTS

We thank Ms Miyoko Ojima for expert help with the study. We thank Stryker Biotech for providing BMP-7.

AUTHOR CONTRIBUTIONS

All authors were involved in drafting the article or revising it critically for important intellectual content, and all authors approved the final version to be published. Dr. Sekiya had full access to all of the data in the study and takes responsibility for the integrity of the data and the accuracy of the data analysis.

Study conception and design. Ozeki, Muneta, Sekiya.
Acquisition of data. Ozeki, Katagiri, Otabe, Okuno, Matsumoto, Hirohisa Saito.

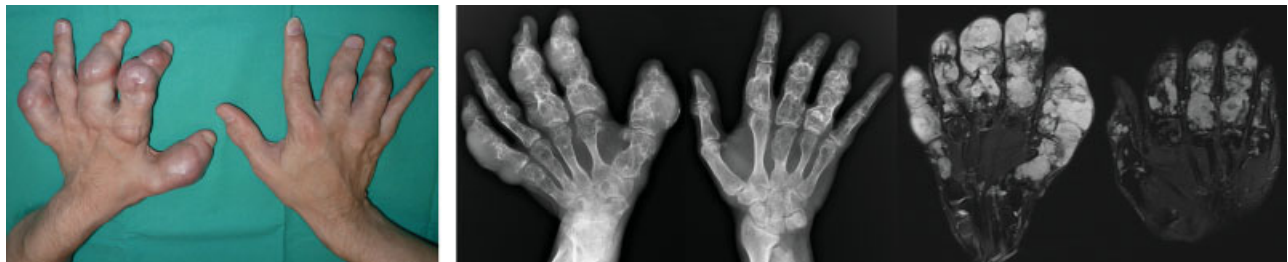Analysis and interpretation of data. Ozeki, Koga, Tsuji, Kobayashi, Matsumoto, H. Saito, T. Saito, Sekiya.

REFERENCES

- Walker PS, Erkman MJ. The role of the menisci in force transmission across the knee. *Clin Orthop Relat Res* 1975;184-92.
- Walsh CJ, Goodman D, Caplan AI, Goldberg VM. Meniscus regeneration in a rabbit partial meniscectomy model. *Tissue Eng* 1999;5:327-37.
- Burks RT, Metcalf MH, Metcalf RW. Fifteen-year follow-up of arthroscopic partial meniscectomy. *Arthroscopy* 1997;13:673-9.
- Englund M, Roos EM, Roos HP, Lohmander LS. Patient-relevant outcomes fourteen years after meniscectomy: influence of type of meniscal tear and size of resection. *Rheumatology (Oxford)* 2001;40:631-9.
- Kraus T, Heidari N, Svehlík M, Schneider F, Sperl M, Linhart W. Outcome of repaired unstable meniscal tears in children and adolescents. *Acta Orthop* 2012;83:261-6.
- Ahn JH, Wang JH, Yoo JC. Arthroscopic all-inside suture repair of medial meniscus lesion in anterior cruciate ligament-deficient knees: results of second-look arthroscopies in 39 cases. *Arthroscopy* 2004;20:936-45.
- Garrett WE Jr, Swionkowski MF, Weinstein JN, Callaghan J, Rosier RN, Berry DJ, et al. American Board of Orthopaedic Surgery Practice of the Orthopaedic Surgeon. Part II. Certification examination case mix. *J Bone Joint Surg Am* 2006;88:660-7.
- Andersson-Molina H, Karlsson H, Rockborn P. Arthroscopic partial and total meniscectomy: a long-term follow-up study with matched controls. *Arthroscopy* 2002;18:183-9.
- McDermott I. Meniscal tears, repairs and replacement: their relevance to osteoarthritis of the knee. *Br J Sports Med* 2011;45:292-7.
- Rodeo SA. Meniscal allografts—where do we stand? *Am J Sports Med* 2001;29:246-61.
- Zur G, Linder-Ganz E, Elsner JJ, Shani J, Brenner O, Agar G, et al. Chondroprotective effects of a polycarbonate-urethane meniscal implant: histopathological results in a sheep model. *Knee Surg Sports Traumatol Arthrosc* 2011;19:255-63.
- Welsing RT, van Tienen TG, Ramrattan N, Heijkants R, Schouten AJ, Veth RP, et al. Effect on tissue differentiation and articular cartilage degradation of a polymer meniscus implant: a 2-year follow-up study in dogs. *Am J Sports Med* 2008;36:1978-89.
- Verdonk P, Beaufils P, Bellemans J, Djian P, Heinrichs EL, Huyse W, et al. Successful treatment of painful irreparable partial meniscal defects with a polyurethane scaffold: two-year safety and clinical outcomes. *Am J Sports Med* 2012;40:844-53.
- Kohn D, Wirth CJ, Reiss G, Plitz W, Maschek H, Erhardt W, et al. Medial meniscus replacement by a tendon autograft. Experiments in sheep. *J Bone Joint Surg Br* 1992;74:910-7.
- Johnson LL, Feagin JA. Autogenous tendon graft substitution for absent knee joint meniscus: a pilot study. *Arthroscopy* 2000;16:191-6.
- Fithian DC, Kelly MA, Mow VC. Material properties and structure-function relationships in the menisci. *Clin Orthop Relat Res* 1990;252:19-31.
- Friedlaender GE, Perry CR, Cole JD, Cook SD, Cierny G, Muschler GF, et al. Osteogenic protein-1 (bone morphogenetic protein-7) in the treatment of tibial nonunions. *J Bone Joint Surg Am* 2001;83-A Suppl 1:S151-8.
- Mizumoto Y, Moseley T, Drews M, Cooper VN, Reddi AH. Acceleration of regenerate ossification during distraction osteogenesis with recombinant human bone morphogenetic protein-7. *J Bone Joint Surg Am* 2003;85-A Suppl 3:124-30.
- Cook SD. Preclinical and clinical evaluation of osteogenic protein-1 (BMP-7) in bony sites. *Orthopedics* 1999;22:669-71.
- Hayashi M, Muneta T, Ju YJ, Mochizuki T, Sekiya I. Weekly intra-articular injections of bone morphogenetic protein-7 inhibits osteoarthritis progression. *Arthritis Res Ther* 2008;10:R118.
- Sekiya I, Tang T, Hayashi M, Morito T, Ju YJ, Mochizuki T, et al. Periodic knee injections of BMP-7 delay cartilage degeneration induced by excessive running in rats. *J Orthop Res* 2009;27:1088-92.
- Takahashi T, Muneta T, Tsuji K, Sekiya I. BMP-7 inhibits cartilage degeneration through suppression of inflammation in rat zymosan-induced arthritis. *Cell Tissue Res* 2011;344:321-32.
- Inoue H, Ohsawa I, Murakami T, Kimura A, Hakamata Y, Sato Y, et al. Development of new inbred transgenic strains of rats with LacZ or GFP. *Biochem Biophys Res Commun* 2005;329:288-95.
- Matsuda A, Morita H, Unno H, Saito H, Matsumoto K, Hirao Y, et al. Anti-inflammatory effects of high-dose IgG on TNF- α -activated human coronary artery endothelial cells. *Eur J Immunol* 2012;42:2121-31.
- National Center for Biotechnology Information, National Institutes of Health. Gene Expression Omnibus. URL: <http://www.ncbi.nlm.nih.gov/projects/geo/>.
- Niikura T, Hak DJ, Reddi AH. Global gene profiling reveals a downregulation of BMP gene expression in experimental atrophic nonunions compared to standard healing fractures. *J Orthop Res* 2006;24:1463-71.
- Pauli C, Grogan SP, Patil S, Otsuki S, Hasegawa A, Koziol J, et al. Macroscopic and histopathologic analysis of human knee menisci in aging and osteoarthritis. *Osteoarthritis Cartilage* 2011;19:1132-41.
- Mankin HJ, Dorfman H, Lippiello L, Zarins A. Biochemical and metabolic abnormalities in articular cartilage from osteo-arthritic human hips. II. Correlation of morphology with biochemical and metabolic data. *J Bone Joint Surg Am* 1971;53:523-37.
- Urist MR. Bone: formation by autoinduction. *Science* 1965;150:893-9.
- Reddi AH, Huggins C. Biochemical sequences in the transformation of normal fibroblasts in adolescent rats. *Proc Natl Acad Sci U S A* 1972;69:1601-5.
- Reddi AH, Anderson WA. Collagenous bone matrix-induced endochondral ossification hemopoiesis. *J Cell Biol* 1976;69:557-72.
- Cook JL, Fox DB, Malaviya P, Tomlinson JL, Kuroki K, Cook CR, et al. Long-term outcome for large meniscal defects treated with small intestinal submucosa in a dog model. *Am J Sports Med* 2006;34:32-42.
- Kobayashi Y, Yasuda K, Kondo E, Katsura T, Tanabe Y, Kimura M, et al. Implantation of autogenous meniscal fragments wrapped with a fascia sheath enhances fibrocartilage regeneration in vivo in a large harvest site defect. *Am J Sports Med* 2010;38:740-8.
- Horie M, Sekiya I, Muneta T, Ichinose S, Matsumoto K, Saito H, et al. Intra-articular injected synovial stem cells differentiate into meniscal cells directly and promote meniscal regeneration without mobilization to distant organs in rat massive meniscal defect. *Stem Cells* 2009;27:878-87.
- Ishida K, Kuroda R, Miwa M, Tabata Y, Hokugo A, Kawamoto T, et al. The regenerative effects of platelet-rich plasma on meniscal cells in vitro and its in vivo application with biodegradable gelatin hydrogel. *Tissue Eng* 2007;13:1103-12.
- Macias D, Ganan Y, Sampath TK, Piedra ME, Ros MA, Hurler JM. Role of BMP-2 and OP-1 (BMP-7) in programmed cell death and skeletogenesis during chick limb development. *Development* 1997;124:1109-17.
- Chubinskaya S, Hurtig M, Rueger DC. OP-1/BMP-7 in cartilage repair. *Int Orthop* 2007;31:773-81.
- Chubinskaya S, Kawakami M, Rappoport L, Matsumoto T, Migita N, Rueger DC. Anti-catabolic effect of OP-1 in chronically compressed intervertebral discs. *J Orthop Res* 2007;25:517-30.
- Flechtenmacher J, Huch K, Thonar EJ, Mollenhauer JA, Davies

- SR, Schmid TM, et al. Recombinant human osteogenic protein 1 is a potent stimulator of the synthesis of cartilage proteoglycans and collagens by human articular chondrocytes. *Arthritis Rheum* 1996;39:1896–904.
40. Cook SD, Patron LP, Salkeld SL, Rueger DC. Repair of articular cartilage defects with osteogenic protein-1 (BMP-7) in dogs. *J Bone Joint Surg Am* 2003;85-A Suppl 3:116–23.
41. Chevrier A, Nelea M, Hurtig MB, Hoemann CD, Buschmann MD. Meniscus structure in human, sheep, and rabbit for animal models of meniscus repair. *J Orthop Res* 2009;27:1197–203.
42. Vanderploeg EJ, Wilson CG, Imler SM, Ling CH, Levenston ME. Regional variations in the distribution and colocalization of extracellular matrix proteins in the juvenile bovine meniscus. *J Anat* 2012;221:174–86.
43. Melrose J, Smith S, Cake M, Read R, Whitelock J. Comparative spatial and temporal localisation of perlecan, aggrecan and type I, II and IV collagen in the ovine meniscus: an ageing study. *Histochem Cell Biol* 2005;124:225–35.
44. Aune AK, Nordsletten L, Ekeland A. Structural capacity of the knee to anterior cruciate ligament failure during quadriceps contraction: an in vivo study in the rat. *J Biomech* 1996;29:891–7.
45. Jackson DW, Halbrecht J, Proctor C, van Sickle D, Simon TM. Assessment of donor cell and matrix survival in fresh articular cartilage allografts in a goat model. *J Orthop Res* 1996;14:255–64.
46. Verdonk R, Almqvist KF, Huisse W, Verdonk PC. Meniscal allografts: indications and outcomes. *Sports Med Arthrosc* 2007;15:121–5.
47. Delay BS, McGrath BE, Mindell ER. Observations on a retrieved patellar tendon autograft used to reconstruct the anterior cruciate ligament: a case report. *J Bone Joint Surg Am* 2002;84-A:1433–8.

DOI 10.1002/art.38115

Clinical Images: Enchondromatosis (Ollier disease)

The patient, a 40-year-old man who had been diagnosed as having Ollier disease when he was child, presented with limb deformities and multiple masses in the hands and feet, which had been painful for several weeks. His medical history included corrective osteotomies for genu varum and leg length discrepancy. On physical examination, the patient was found to be small in stature, with oversized hands and numerous nodules on the fingers (left) and toes that were prominent and tender to palpation on the left thumb, index, middle, and little fingers and resulted in a limited range of motion. Radiographs of the hands revealed bilateral ulnar shortening and expansile intramedullary radiolucent lesions, with lobular contours, endosteal scalloping, and small foci of calcification, consistent with enchondroma (top right). Areas of cortical destruction with extension into the soft tissues were noted on the left hand. Phleboliths and soft tissue calcifications were not found. Fat-suppressed T2-weighted magnetic resonance imaging (MRI) of the hands showed well-circumscribed lobulated lesions of high signal intensity (bottom right), with thin peripheral and septal enhancement after intravenous administration of gadolinium. Results of whole-body MRI ruled out the presence of soft tissue hemangiomas or other associated malignancies, particularly of the brain and abdomen. Originally described in 1899, enchondromatosis is a rare, nonhereditary mesodermal dysplasia characterized by multiple cartilaginous foci distributed asymmetrically throughout the tubular and flat bones (1,2). Although more common in Maffucci syndrome, malignant transformation into chondrosarcoma by 40 years of age has been reported in ~25% of patients with Ollier disease (2,3). Adult patients with Ollier disease generally seek medical attention for pain related to osteoarthritis caused by the deformities or sarcomatous transformation of an enchondroma. In this case, the patient's symptoms persisted despite medical treatment, but he refused surgical intervention. He is currently being followed up closely.

1. Pannier S, Legeai-Mallet L. Hereditary multiple exostoses and enchondromatosis. *Best Pract Res Clin Rheumatol* 2008;22:45–54.
2. Flemming DJ, Murphey MD. Enchondroma and chondrosarcoma. *Semin Musculoskelet Radiol* 2000;4:59–71.
3. Schwartz HS, Zimmerman NB, Simon MA, Wroble RR, Millar EA, Bonfiglio M. The malignant potential of enchondromatosis. *J Bone Joint Surg Am* 1987;69:269–74.

Milena Cerny, MD
 Hannes A. Rudiger, MD
 Berengere Aubry-Rozier, MD
 Eric Dugert, MD
 Fabio Becce, MD
*Centre Hospitalier Universitaire Vaudois
 and University of Lausanne
 Lausanne, Switzerland*