



Received: 2014.02.28
Accepted: 2014.04.14
Published: 2014.11.27

Authors' Contribution:

- A** Study Design
- B** Data Collection
- C** Statistical Analysis
- D** Data Interpretation
- E** Manuscript Preparation
- F** Literature Search
- G** Funds Collection

Magnetic Resonance-Guided High-Intensity Focused Ultrasound (MR-HIFU) in Treatment of Symptomatic Uterine Myomas

Justyna Filipowska^{1A}, Tomasz Łoziński^{2B}

¹ Institute of Nursing and Health Sciences, Faculty of Electroradiology, University of Rzeszów, Rzeszów, Poland

² Department of Gynecology and Obstetrics, Pro-Familia Specialized Hospital, Rzeszów, Poland

Author's address: Justyna Filipowska, Institute of Nursing and Health Sciences, Faculty of Electroradiology, University of Rzeszów, Al. mjr. W. Kopisto 2A, 35-310 Rzeszów, Poland, e-mail: flipowskajustyna@me.com

Summary

Magnetic Resonance-guided High-Intensity Focused Ultrasound (MR-HIFU) is a noninvasive technique for ablation therapy for uterine myomas, where focused ultrasound energy beam generates localized high temperature in the selected area and coagulates chosen tissue, leaving the skin and tissues in between unharmed. Magnetic resonance imaging enables accurate targeting for HIFU as well as temperature monitoring during treatment. MR guidance with 3D anatomical imaging provides reference data for treatment planning, while real-time temperature monitoring aids in controlling ablation process. This review provides basic information regarding methodology, clinical indications for this kind of treatment, expected outcome and patient management during MR-HIFU procedure.

The aim of this work is to introduce a new, noninvasive treatment method for uterine leiomyomas and to present a comparison with other currently used methods.

MeSH Keywords:

High-Intensity Focused Ultrasound Ablation • Leiomyoma • Magnetic Resonance Imaging

PDF file:

<http://www.polradiol.com/abstract/index/idArt/890606>

Background

Uterine myomas are common among women of reproductive age. Gynecological management involves laparoscopic or open myectomy or hysterectomy. These procedures are highly invasive, require patient hospitalization, carry a risk of late complications, are associated with perioperative risk and relatively long recovery time. Thus, there is an ongoing search for alternative methods devoid of disadvantages of classical therapeutic methods. HIFU (High-Intensity Focused Ultrasound) thermal ablation of uterine fibroids appears to be an interesting alternative. It is a non-invasive therapeutic method utilizing focused high-intensity ultrasound beam, which causes local raise in temperature by concentrating ultrasound energy on a small tissue area and, as a consequence, formation of necrotic foci and destruction of selected tissues (so-called ablation). MR-HIFU technology uses magnetic resonance for planning and controlling the process of ablation in a precisely selected therapeutic region. This method is used for noninvasive

treatment of uterine myomas. There are ongoing studies on possible use of MR-HIFU in treatment of other tumors and in so-called targeted drug delivery, i.e. activation of therapeutic agents within targeted lesion using thermosensitive liposomal capsules [1]. FUS (Focused Ultrasound) is a similar method.

The most important difference between both systems is the way of controlling the ultrasound probe. In focused ultrasound ablation (FUS) the probe shifts the focus point by point, ablating tissue in precisely defined, small region, while according to volumetric heating (HIFU) method (HIFU) the probe makes oscillatory movements, forming an ablation focus of predetermined volume. It is a so-called volumetric thermal ablation (volumetric heating) concept. Limitations to point ablation are associated with the danger of acquiring nonhomogeneous area of tissue destruction and prolonged procedure. In volumetric heating method ultrasound beam is controlled electronically and moved by increasing volume of ablated tissue. Diameter

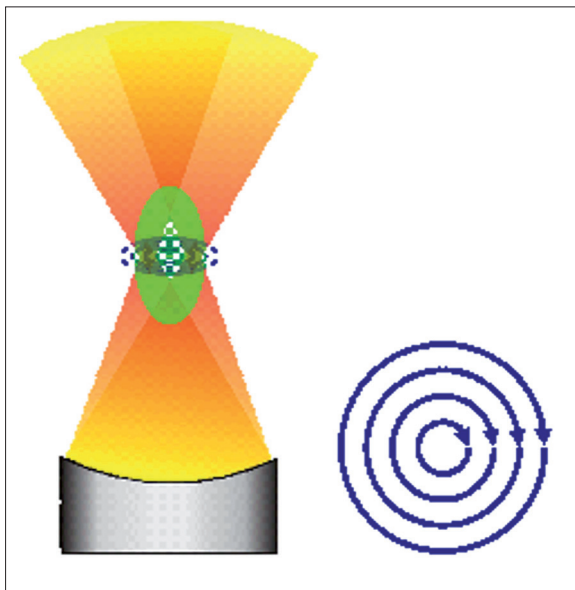


Figure 1. Electronic beam steering: revolving motion forms rings 4–6 mm in diameter, generating so-called therapeutic cells.

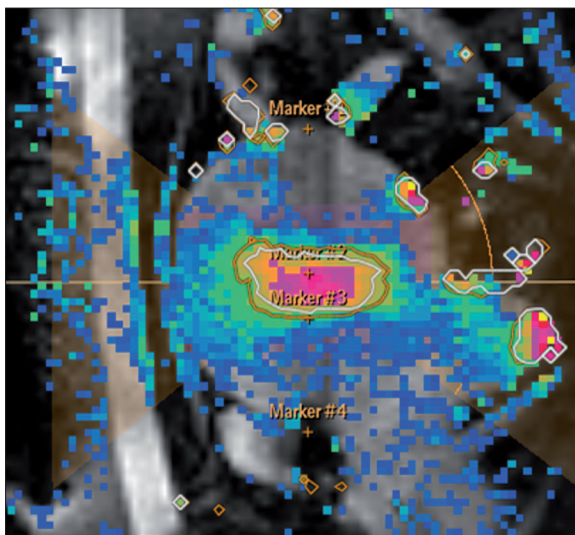


Figure 2. Real time MR temperature monitoring in the ablation zone involves color-coding of, temperature range and creation of thermal maps, where red color corresponds to the highest temperature and blue color to the lowest.

of these ellipsoidal volumes – so-called treatment cells, may be regulated in a range 4–16 mm and length up to 40 mm, covering the pre-programmed ablation zone within a shorter time than in the point method. If ablation of larger areas is necessary (large myomas), it is performed by overlapping several cells on the chosen region (Figure 1).

The goal of this work is to present a new, noninvasive method of treatment of uterine myomas and to compare it to currently used treatment methods.

The Role of Magnetic Resonance in MR-HIFU Therapy

Magnetic resonance imaging enables planning of thermal ablation procedure, as well as steering and controlling of

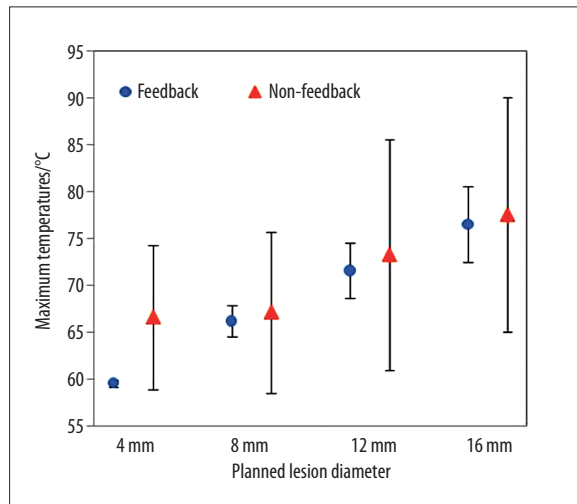


Figure 3. ^ Real time temperature distribution in the ablation zone depending on programmed therapeutic cell size without real time control (predefined, fixed dose and time). * Real time-controlled ablation (same dose, time controlled by MRI feedback). A map of true temperatures in the ablation zone depending on programmed therapeutic cell size.

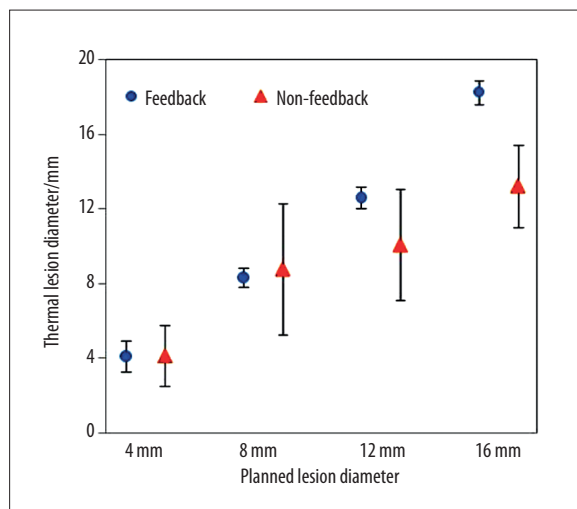


Figure 4. ^ Ablation not controlled in real time (fixed dose and time). Graphic representation of the relationship between planned area of thermal tissue damage and actual ablation zone. * Real time, feedback-controlled ablation (same dose, feedback-controlled time). A graph representing a relationship between planned area of thermal tissue damage and actual ablation zone.

its progress in real time. MR system provides 3D images for treatment planning and shows a temperature map based on water diffusion for monitoring of local heat distribution and observing critical structures that should not be exposed to excessive heat during the procedure (Figure 2).

Control over time of ultrasound beam action based on real time temperature maps acquired in MR allows for maintaining optimal temperature within treatment cell, avoiding tissue overheating and preventing them from boiling, which may take place in a situation of predetermined sonification time and power (Figure 3). It is particularly

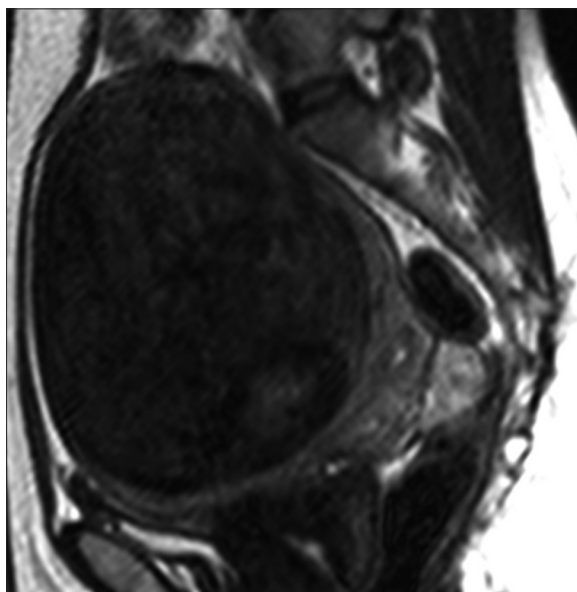


Figure 5. MR, Fast TSE T2w3D DRIVE image, sagittal plane. Very large myoma, $123 \times 103 \times 92 \text{ mm}^3 = 599.5 \text{ ml}$ in volume; pre-treatment size.

important for temperature monitoring within larger therapeutic cells, where the temperature within the cell exceeds that at the periphery [2]. Optimal range of temperatures within therapeutic cells is $60\text{--}65^\circ\text{C}$, which is enough to generate necrotic foci and avoid overheating. Control over ultrasound beam action time based on temperature maps acquired in real time from MR imaging enables induction of necrosis in a precisely defined area, which is difficult to achieve if time and dose of ultrasound has been predetermined (Figure 4).

MR-HIFU System Components

The system consists of ultrasonic transducer, MR scanner and steering board. High power transducer working at frequencies between 1 to 1.5 MHz is located within MR scanner table together with a specialized 3-channel RF receiving coil, with one channel built into the tabletop and a 2-channel segment placed behind the patient in order to ensure optimal coverage and possibility of high resolution imaging. MR system generates a set of 3D imaging data for treatment planning and enables acquisition of temperature-sensitive phase images during the procedure for monitoring of local heat distribution. It allows for determining which structures should undergo further ablation and when heating should be discontinued. Steering board is used for determining geometry of ablation volume, calculating heating patterns and heat doses, as well as positions of all monitoring cross-sections based on acquired MR data. After setting a treatment plan the steering board controls HIFU transducer power supply and mechanical positioning. It also takes control over MR procedure, initializing acquisition of temperature-sensitive phase images, which are then converted into temperature maps. Information regarding temperature is used to automatically adjust and optimize ultrasound beam in real time. Based on real time temperature monitoring a closed feedback loop determines the time of therapy, which is crucial for patient safety.

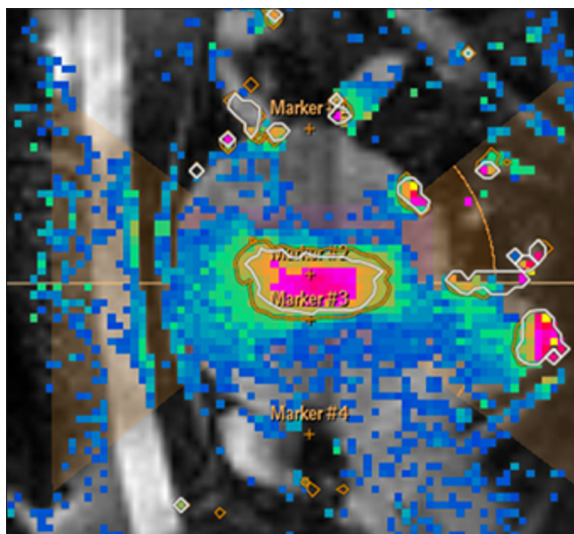


Figure 6. Real-time monitoring of temperature spread within the ablation treated leiomyoma, treatment cell size 16 mm, encoded with color red.

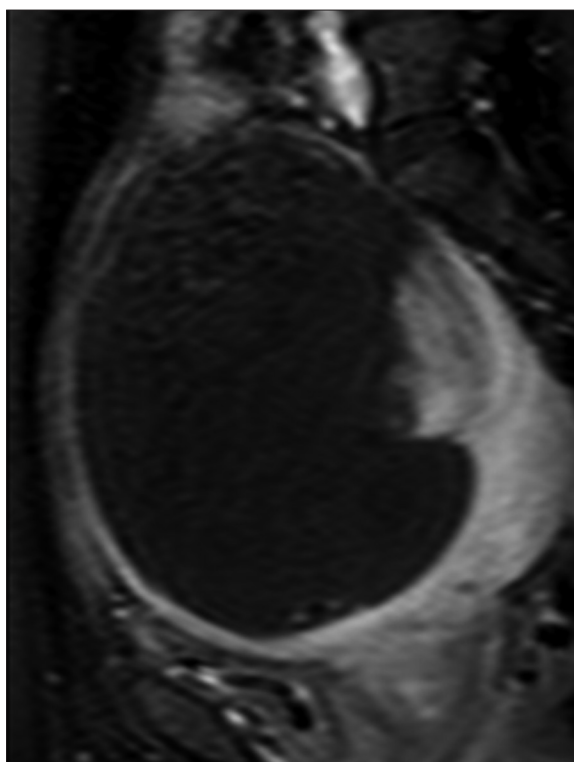


Figure 7. MR imaging, TFE THRIVE 3D SPAIR, T1-weighted image, sagittal plane, examination following administration of contrast medium. Treatment time: 163 min, 89% NPV.

Qualifying for Thermal Ablation of Uterine Myomas. Monitoring of Treatment Results

Almost all types of uterine myomas (intramural, subserous, submucosal) can be treated with MR-HIFU technique. Subserous fibroids should be located no closer than 15mm from serosal surface. Treatment of submucosal myomas is possible all the way to endometrial surface only when the patient is not planning on further pregnancies. This method

should not be used for treatment of pedunculated fibromas. Generally, the minimal accepted diameter of the fibroid qualified for the procedure is 1 cm. There is practically no upper limit. In practice, such procedures are performed on tumors up to 13 cm in diameter. It is possible to ablate several myomas during one therapeutic session. Thanks to the fact that MR imaging is used for planning of the procedure it was demonstrated [3] that low-signal tumors in T2-weighted MR images (so-called dark fibroids) better responded to therapy and necrotic zone was larger than that forming in myomas exhibiting high-signal in T2-weighted images. Fibroids exhibiting strong signal were characterized by high perfusion, which was the cause of rapid cooling of the ablation zone, limiting necrosis [4]. Hence, there were attempts to classify fibroids depending on their susceptibility to MR-HIFU therapy [5]. MR imaging with administration of contrast immediately after treatment and determination of percentage value of so-called non-perfused volume (NPV) corresponding to the ratio of non-perfused fibroid volume (due to induced necrosis) to total volume of treated lesion is a good method for assessment of procedure effectiveness. The greater fragment of the lesion underwent ablation, the better [6,7]. It is accepted that values above 60% correspond to significant reduction of symptoms related to treated fibroid [7,8] (Figures 5–7).

Practical Aspects of Treatment of Uterine Myomas with MR-HIFU Technique

Due to physical properties of ultrasonic wave concentration the target of ablation should be located 12 to 14cm

from the surface of ultrasound transducer. Therefore, the distance between patient skin surface and middle of the lesion should remain between 8 and 10 cm. Very slim patients or, conversely, with overdeveloped adipose tissue, it is possible to perform the procedure with help of advanced techniques of patient positioning [9]. For similar reasons it may be necessary to fill urinary bladder or rectum in order to properly position the uterus for the procedure. Sensitive organs (intestine, urinary bladder) cannot stand in the way of the ultrasound beam. This may mean problems with ablation of particularly large fibromas. The advantages of treating uterine myomas with this method include the possibility of treating tumors of various sizes (1–13 cm in diameter), possibility of treating several lesions at the same time, short duration of the procedure, no need for the patient to stay in the hospital after the procedure. Adverse symptoms include abdominal pain (11–12%), lower limb and back pain (6–8%). Serious adverse effects include skin burns [10]. It seems that the number of adverse events associated with this procedure will decrease with increasing operator's experience [11,12]. The table presents a comparison of various available methods of treatment of uterine myomas (Table 1).

Conclusions

MR-HIFU technique is a new, noninvasive method of treatment of uterine myomas without the need for patient hospital admission, with a limited number of adverse effects, allowing for precise removal of clinically symptomatic

Table 1. Comparison of MR-HIFU and other available therapeutic methods.

Examined features	MR-HIFU	Uterine artery embolization	Open and laparoscopic myomectomy	Open or laparoscopic hysterectomy
Patient population	Possible in most patients with symptomatic medium-size to large myomas and desire to preserve the uterus	Indications limited to intramural myomas, low invasiveness, possibility of preserving the uterus, inability to become pregnant	Symptomatic intramural or subseral myomas; patients who are planning pregnancy without contraindications to surgery	Patients in whom less invasive treatment methods failed, with serious clinical symptoms, not planning other pregnancies, severe bleeding during myomectomy
Time of hospitalization	Ambulatory conditions	1 day	2–5 days laparoscopy; 3–5 days surgery (14)	0–2 days laparoscopy; 3–6 days surgery (15)
Limitations/risk factors	Limitations regarding type and location of myoma, little adverse symptoms (abdominal pain 11%, lower limb 6%, vaginal bleeding 8%, skin burns 1–7% (16)	Possible need for surgical intervention, infection, bleeding	Symptomatic intramural or subseral myomas; patients who are planning pregnancy without contraindications to surgery	Risk associated with surgery, perioperative mortality, irreversible procedure, hot flushes, weight gain, depression, reduced libido, anxiety (18)
Resumption of normal activity	1–3 days (19)	10–14 days (19)	2.9 weeks (laparoscopic) 3.7 weeks (surgery) (19)	2–5 weeks
Fertility/pregnancy	Little available data; observational study of 51 pregnancies; 64% vaginal births, 36% caesarean sections (19)	Not recommended; risk of placental damage, ovarian failure, cessation of menses in 12–15% (19)	Possible pregnancy, requires careful monitoring	No
Recurrence rate	7.4% 12 months; 14% 24 months (19)	10% after 2 years (19)	21.8% after 3 years; 33% after 5 years (19)	Definitive treatment

tumors. It is another important method that can be used for treatment of uterine fibroids and a field for cooperation between radiologists and gynecologists. Reports on possible

use of MR-HIFU for treatment of other tumors and so-called targeted drug delivery give hope for new possibilities in treatment of neoplastic lesions.

References:

1. <http://www.fusfoundation.org/the-technology/overview> (accessed 14.02.2014)
2. Enholm JK: Improved Volumetric MR-Ablation by Robust Binary Feedback Control. *IEEE Trans Biomed Eng*, 2010; 57(1): 103–13
3. Lénárd ZM, McDanold NJ, Fennessy FM et al: Uterine leiomyomas: MR imaging-guided focused ultrasound surgery – imaging predictors of success. *Radiology*, 2008; 249(1): 187–94
4. Funaki K: Clinical outcomes of magnetic resonance-guided focused ultrasound surgery for uterine myomas: 24-month follow-up. *Ultrasound Obstet Gynecol*, 2009; 34(5): 584–89
5. Funaki K, Fukunushi H, Funaki T et al: Magnetic resonance guided focused ultrasound surgery for uterine fibroids: relationship between the therapeutic effects and signal intensity of preexisting T2-weighted MR images. *Am J Obstet Gynecol*, 2007; 196(2): 184–86
6. LeBlang SD, Hoctor KM, Steinberg FL: Leiomyoma shrinkage after MRI-guided Focused Ultrasound Treatment: Report of 80 patients. *Am J Roentgenol*, 2010; 194: 274–80
7. Fennessy FM, Tempny CM, McDanold NJ et al: Uterine leiomyomas: MR imaging guided focused ultrasound surgery-results of different treatment protocols. *Radiology*, 2007; 243(3): 885–93
8. Stewart EA, Gostout B, Rabinovici et al: Sustained relief of leiomyoma symptoms by using focused ultrasound surgery. *Obstet Gynecol*, 2007; 110(2 Pt 1): 279–87
9. Zaher S, Gedroyc WM, Regan L: Patient suitability for magnetic resonance guided focused ultrasound surgery of uterine fibroids. *Eur J Obstet Gynecol Reprod Biol*, 2009; 143: 98–102
10. Hindley J, Gedroyc WM, Regan L et al: MRI guidance of focused ultrasound therapy of uterine fibroids: early results. *Am Roentgenol*, 2004; 183(6): 1713–19
11. Stewart EA, Rabinovici J, Tempny C et al: Clinical outcomes of focused ultrasound surgery for the treatment of uterine fibroids. *Fertil Steril*, 2006; 85: 22–29
12. Okada A, Morita Y, Fukunishi H et al: Non-invasive magnetic resonance-guided focused ultrasound treatment of uterine fibroids in a large Japanese population. *Ultrasound Obstet Gynecol*, 2009; 34(5): 579–83