

Cyclosporin A-related cerebral venous sinus thrombosis

A case report

Fengjuan Gao, MD^{a,b}, Jun Zhang, MD^{a,b}, Fang Wang, MD^{a,b}, Xiaoyan Xin, MD^{b,c}, Dujuan Sha, MD, PhD^{a,b,*}

Abstract

Rationale: Cerebral venous sinus thrombosis (CVST) is a complex life-threatening condition, and its etiology is not well understood. Although oral cyclosporin A is not a common cause of the symptoms related to CVST, there is limited information available.

Patient concerns: In this study, we report a rare case of CVST in a 44-year-old woman with aplastic anemia, who was given cyclosporin A orally for a period of 18 months. She had experienced a headache for 20 days.

Diagnoses: The patient was diagnosed with CVST by computed tomography venography.

Interventions: Low molecular heparin (enoxaparin, 4000 AXaIU, subcutaneous injection, once every 12 hours) was administered for anticoagulation.

Outcomes: The patient developed no recurrence of thrombosis during the 13-month follow-up period.

Lessons: Clinicians should be aware of the possibility of CVST when patients are treated with cyclosporin A and have symptoms such as headaches.

Abbreviations: AA = aplastic anemia, CT = computed tomography, CTV = computed tomography venography, CVST = cerebral venous sinus thrombosis, MRV = magnetic resonance venography.

Keywords: cerebral venous sinus thrombosis, cyclosporin A, headache

1. Introduction

The etiology of cerebral venous sinus thrombosis (CVST) is complex, involving hereditary, and acquired factors, according to a report by Alvis-Miranda et al.^[1] CVST due to hereditary factors is rare, while CVST resulting from acquired factors is commonly observed. Acquired factors mainly include brain tumors, brain trauma, infection of the nervous system, immune system diseases, and drugs. Oral contraceptives are the most common drugs responsible for causing CVST.^[2] Although rare, other drugs, such as cyclosporin A and tacrolimus, have been reported to cause CVST.^[3] Here, we report a rare case of CVST in a 44-year-old

woman, who was administered cyclosporin A orally for 18 continuous months.

2. Case report

A 44-year-old woman presented to our hospital with symptoms of a headache for 20 days and weakness in the right limbs for 1 day. She had a history of aplastic anemia (AA) and had been taking 150 mg oral cyclosporin A (twice a day) continuously for 18 months. Physical examination was performed and the following parameters were noted: height, 170 cm; weight, 68 kg; body temperature, 36.5°C; and blood pressure, 142/83 mm Hg. No abnormality was observed on cardiopulmonary or abdominal examination. Neurological examination revealed conscious mind and motor aphasia; bilateral eye movement was flexible; size of the bilateral pupils were equal at 3 mm in diameter; light reflex was observed; the right nasolabial sulcus was shallow; tongue was in the middle; gag reflex was noted; neck was soft; according to the manual muscle test, the strength level of the right upper and lower limb muscles was 4; the strength level of the left upper and lower limb muscles was 5 (normal); muscle tension in all limbs was normal and physiological reflex was noted; and the Babinski sign on the right side was positive. The patient had no history of diabetes, hypertension, hyperlipidemia, liver cirrhosis, smoking, use of contraceptive pills, pregnancy, puerperium, and infection. Laboratory examination revealed: white blood cells, $6.19 \times 10^9/L$ (normal reference value $4-10 \times 10^9/L$); neutrophils, 86.9% (normal reference value 50–70%); hemoglobin, 89 g/L (normal reference value for adult female 110–150 g/L); platelets $55 \times 10^9/L$ (normal reference value $100-300 \times 10^9/L$); blood concentration of cyclosporin A (valley concentration), 240.7 μ

Editor: N/A.

This report was supported by the National Natural Science Foundation of China (81571122).

The authors have no conflicts of interest to disclose.

^a Department of Emergency, Nanjing Drum Tower Hospital Affiliated to Nanjing University Medical School, ^b The State Key Laboratory of Pharmaceutical Biotechnology, Nanjing University, ^c Department of Radiology, Nanjing Drum Tower Hospital Affiliated to Nanjing University Medical School, Nanjing, Jiangsu, China.

* Correspondence: Dujuan Sha, Department of Emergency, Nanjing Drum Tower Hospital Affiliated With Nanjing University Medical School, 321 Zhongshan Road, Nanjing 210008, Jiangsu, China (e-mail: tbwen0912@126.com).

Copyright © 2018 the Author(s). Published by Wolters Kluwer Health, Inc. This is an open access article distributed under the Creative Commons Attribution License 4.0 (CCBY), which permits unrestricted use, distribution, and reproduction in any medium, provided the original work is properly cited.

Medicine (2018) 97:31(e11642)

Received: 9 January 2018 / Accepted: 28 June 2018

<http://dx.doi.org/10.1097/MD.00000000000011642>

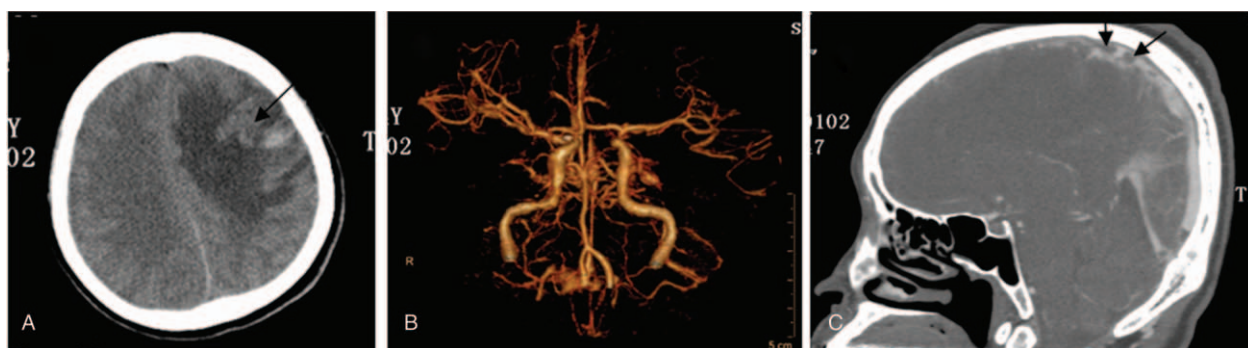


Figure 1. The high-signal image of the computed tomography scan shows ischemia and hemorrhage in the left frontal lobe (black arrow, A); no abnormality in cerebral arteries (B); and sinus thrombosis observed in the superior sagittal sinus by computed tomography venography (black arrow, C).

g/L (normal reference value 150–250 $\mu\text{g/L}$); plasma D dimer, 31.38 mg/L (normal reference value $< 0.5 \text{ mg/L}$); and normal levels of blood protein S, protein C, anticardiolipin antibody, immune indexes, indexes of tumor, antithrombin III blood homocysteine, and blood fibrin. Ischemia and hemorrhage were observed in left frontal lobe by computed tomography (CT) scan (Fig. 1A). There was no abnormality in the cerebral arteries (Fig. 1B) and sinus thrombosis was observed in the superior sagittal sinus region with computed tomography venography (CTV) (Fig. 1C). The patient was administered low molecular heparin (enoxaparin, 4000 AXaIU, subcutaneous injection, once every 12 hours) for anticoagulation. After 2 weeks, it was replaced by warfarin, and the dosage of warfarin was adjusted by the international normalized ratio (2.0–2.5). Cyclosporin A was stopped immediately and replaced by Testosterone Undecanoate. After 30 days, the patient had no more thrombosis. But her hemoglobin concentration was declined to 55 g/L. According to the hematology specialists and neurologists' comments, cyclosporine A was resumed again and warfarin was taken together. The dosage of cyclosporine A was adjusted between 100 to 150 mg (twice a day) according to the blood concentration. The patient developed no recurrence of thrombosis during the 13-month follow-up.

3. Discussion

CVST is a type of cerebrovascular disease, the incidence of which is $< 1\%$ among all stroke cases.^[4] It has been reported that the main risk factors for CVST include oral contraceptives, pregnancy, postpartum complications, trauma, and a hypercoagulable state.^[5] In addition to oral contraceptives, CVST can be caused by other drugs, such as immunosuppressants and cortical hormones^[3,6–27] (Table 1).

Headache is the most common clinical manifestation of CVST. Furthermore, seizures, subarachnoid hemorrhage, intracranial hypertension, and coma have been noted as symptoms in a few patients.^[28–30] Since the clinical manifestations of CVST lack specificity, misdiagnosis or underdiagnosis commonly occurs in clinical practice. Currently, cerebral magnetic resonance venography (MRV) is the best diagnostic method for CVST.^[31,32] In addition, the use of cerebral CTV is feasible, if the patient is unfit to undergo MRV. In the initial stage in our case, headache and vomiting occurred; however, no abnormal symptoms were noted on physical examination. In addition, cerebral CT or cerebral magnetic resonance imaging findings were normal. Cerebral CTV

aided in the final diagnosis. Thus, for patients who are suspected to have CVST, it is suggested that cerebral MRV or CTV is performed at the earliest opportunity.

CVST can also occur as a secondary disease after intracerebral hemorrhage; this is one of the reasons for the misdiagnosis of CVST. The cerebral CT scan of our patient revealed intracerebral hemorrhage; however, on CTV, it was soon discovered to be a result of CVST. Therefore, anticoagulant therapy was promptly administered. According to the 2010 European Federation of Neurological Societies guidelines,^[4] intracerebral hemorrhage is not a contraindication of anticoagulant therapy in CVST. Although CVST itself can be serious, the use of anticoagulant drugs can also aggravate intracerebral hemorrhage. Furthermore, to safely perform anticoagulant therapy in patients with early intracerebral hemorrhage associated with CVST, the therapeutic decision should be individualized to the patient and caution should be taken.^[33]

Cyclosporin A, a specific immune inhibitor, is now recognized as the first-line drug in the treatment of AA in adults. There are few reports on CVST induced by cyclosporin A,^[3,11,12] its mechanism is remains unclear. According to the medical history and examination results, the patient had no cerebral trauma, intracranial surgery, central nervous system infection, facial abscess, tumor, autoimmune disease, other oral drugs, puerperium, pregnancy, hypercoagulable state, or hereditary diseases; therefore, other possible causes of CVST had been ruled out. Anemia is the main symptom of AA. Anemia can also predispose to CVST. But it was reported^[34,35] only a weak association with severe anemia (hemoglobin $< 5.0 \text{ mmol/L}$ for nonpregnant women) and no association with mild anemia. In this patient, the hemoglobin concentration is 89 g/L (5.52 mmol/L). Thus, we consider the patient to have had CVST induced by Cyclosporin A. Cyclosporin A inhibits the release of prostacyclin from vascular endothelial cells, activates the renin-angiotensin system, increases the synthesis of systolic vascular endothelia and thromboxane A₂, and increases production of free radicals; thus, this directly leads to endothelial injury and vasomotor function damage.^[36] In addition, cyclosporin A can activate the endogenous coagulation pathway^[37] and induce the expression of inducible nitric oxide synthase.^[38] These factors are considered to be the main mechanisms through which thrombosis is induced by cyclosporin A. According to the literature report, the time ranges of cyclosporine A induced CVST is from 9 days to 11 months,^[3,11,12] and our patient had taken cyclosporine A for 18 months. Therefore, the specific time for cyclosporine A induced

Table 1**Drug factors associated with cerebral venous sinus thrombosis.**

Drug	Age/sex	CVST modality	Location of CVST	First author (Ref. No.)	Published year
Ecstasy	22/F	Cerebral angiography	Both transverse sinuses	Rothweil ^[6]	1993
Medroxyprogesterone acetate	49/F	Autopsy	Superior sagittal sinus	Hitosugi ^[7]	1997
Lithium	30/F	CT/MRI	Superior sagittal sinus, straight sinus, left transverse sinus, left sigmoid sinus	Wasay ^[8]	2000
Oxymetholone	40/F	MRV	Superior sagittal sinus, left transverse sinus	Chu ^[9]	2001
Androgen	22/M	MRV	Superior sagittal and transverse sinus	Sahraian ^[10]	2004
Cyclosporin	19/M	CT/MRA	Superior sagittal sinus and right transverse sinus	Murata ^[11]	2004
	48/F	MRV	Left transverse sinus, sigmoid sinus	Al-Shekhlee ^[12]	2005
	25/M	CT/MRI	Superior sagittal sinus	Rajapakse ^[3]	2009
Thalidomide	74/F	MRV	Straight sinus, transverse sinus	Lenz ^[13]	2004
Phytoestrogens	52/F	MRV	Left lateral and sigmoid sinus	Guimaraes ^[14]	2005
Contraceptive ring	33/F	CT	Left transverse sinus, sigmoid sinus	Dunne ^[15]	2010
Nuvaring	28/F	CT	Left sigmoid and transverse sinuses	Kolacki ^[16]	2012
Finasteride	35/M	CT	Sagittal sinus and left transverse sinus	Tsuji ^[17]	2014
Sildenafil	57/M	MRV	Right transverse and sigmoid sinuses, superior sagittal sinus	Rufa ^[18]	2007
Methotrexate	12/M	MRI	Left transverse and sigmoid sinuses	Mahadeo ^[19]	2010
L-asparaginase	10/M, 13/F	CT (case 1), MRV (case 2)	Superior sagittal sinus (2 cases)	Wani ^[20]	2010
Asparaginase	9/M	MRI	Superior sagittal sinus	Alsaïd ^[21]	2013
Tamoxifen	40/F	MRI	Superior sagittal sinus, right lateral sinus	Akdal ^[22]	2001
	46/F	CT/MRI	Superior sagittal sinus and straight sinus	Kim ^[23]	2015
	30/F	Cerebral angiography	Superior sagittal sinus	Hwang ^[24]	2015
Steroid	32/F	MRV	Left transverse and sigmoid sinus	Gazıoglu ^[25]	2013
IgG	16/F	MRI	Superior sagittal sinus	Benadiba ^[26]	2015
Heparin	69/F	CT, MRI, cerebral angiography, autopsy	Superior sagittal sinus	Fesler ^[27]	2011

CT = computed tomography, CVST = cerebral venous sinus thrombosis, MRA = magnetic resonance angiography, MRI = magnetic resonance imaging, MRV = magnetic resonance venography.

CVST is unclear. We also noticed that the time of intravenous cyclosporin A induced CVST is shorter than that of oral cyclosporine A.^[3,11,12] The fastest time of the former is 9 days.^[12] Whether it is related to the rapid increase of blood concentration of intravenous cyclosporin A, it is not reported up to present. Patients should be informed about the possibility of CVST and caution should be taken for patients who experience headaches when being treated with oral cyclosporin A. Early diagnosis is important, such that prompt therapy can be administered to improve the prognosis of patients and reduce mortality and morbidity.

Acknowledgments

The authors thank the assistance from our colleagues at the Department of Hematology of Nanjing Drum Tower Hospital. The authors thank Editage (www.editage.com) for English language editing.

Author contributions

Data curation: Jun Zhang, Fang Wang.

Methodology: Xiaoyan Xin.

Writing – original draft: Fengjuan Gao.

Writing – review and editing: Dujuan Sha.

References

- [1] Alvis-Miranda HR, Castellar-Leones SM, Alcalá-Cerra G, et al. Cerebral sinus venous thrombosis. *J Neurosci Rural Pract* 2013;4:427–38.
- [2] Özdemir HH, Varol S, Akil E, et al. Evaluation of cerebral venous thrombosis secondary to oral contraceptive use in adolescents. *Neuro Sci* 2015;36:149–53.
- [3] Rajapakse S, Gnanajothy R, Lokunarangoda N, et al. A kidney transplant patient on cyclosporine therapy presenting with dural venous sinus thrombosis: a case report. *Cases J* 2009;2:9139.
- [4] Einhäupl K, Stam J, Boussier MG, et al. European Federation of Neurological Societies. EFNS guideline on the treatment of cerebral venous and sinus thrombosis in adult patients. *Eur J Neurol* 2010; 17:1229–35.

- [5] Meng R, Ji X, Wang X, et al. The etiologies of new cases of cerebral venous sinus thrombosis reported in the past year. *Intractable Rare Dis Res* 2012;1:23–6.
- [6] Rothwell PM, Grant R. Cerebral venous sinus thrombosis induced by “ecstasy”. *J Neurol Neurosurg Psychiatry* 1993;56:1035.
- [7] Hitosugi M, Kitamura O, Takatsu A, et al. A case of dural sinus thrombosis during the medication of medroxyprogesterone acetate. *Nihon Hoigaku Zasshi* 1997;51:452–6.
- [8] Wasay M, Bakshi R, Kojan S, et al. Superior sagittal sinus thrombosis due to lithium: local urokinase thrombolysis treatment. *Neurology* 2000;54:532–3.
- [9] Chu K, Kang DW, Kim DE, et al. Cerebral venous thrombosis associated with tentorial subdural hematoma during oxymetholone therapy. *J Neurol Sci* 2001;185:27–30.
- [10] Sahraian MA, Mottamedi M, Azimi AR, et al. Androgen-induced cerebral venous sinus thrombosis in a young body builder: case report. *BMC Neurol* 2004;4:22.
- [11] Murata S, Ishikawa N, Oshikawa S, et al. Cerebral sinus thrombosis associated with severe active ulcerative colitis. *Intern Med* 2004;43:400–3.
- [12] Al-Shekhlee A, Oghlakian G, Katirji B. A case of cyclosporin-induced dural sinus thrombosis. *J Thromb Haemost* 2005;3:1327–8.
- [13] Lenz RA, Saver J. Venous sinus thrombosis in a patient taking thalidomide. *Cerebrovasc Dis* 2004;18:175–7.
- [14] Guimaraes J, Azevedo E. Phytoestrogens as a risk factor for cerebral sinus thrombosis. *Cerebrovasc Dis* 2005;20:137–8.
- [15] Dunne C, Malyuk D, Firoz T. Cerebral venous sinus thrombosis in a woman using the etonogestrel-ethinyl estradiol vaginal contraceptive ring: a case report. *J Obstet Gynaecol Can* 2010;32:270–3.
- [16] Kolacki C, Rocco V. The combined vaginal contraceptive ring, nuvaring, and cerebral venous sinus thrombosis: a case report and review of the literature. *J Emerg Med* 2012;42:413–6.
- [17] Tsuji Y, Nakayama T, Bono K, et al. Two cases of stroke associated with the use of finasteride, an approved drug for male-pattern hair loss in Japan. *Rinsho Shinkeigaku* 2014;54:423–8.
- [18] Rufa A, Cerase A, Monti L, et al. Recurrent venous thrombosis including cerebral venous sinus thrombosis in a patient taking sildenafil for erectile dysfunction. *J Neurol Sci* 2007;260:293–5.
- [19] Mahadeo KM, Dhall G, Panigrahy A, et al. Subacute methotrexate neurotoxicity and cerebral venous sinus thrombosis in a 12-year-old with acute lymphoblastic leukemia and methylenetetrahydrofolate reductase (MTHFR) C677T polymorphism: homocysteine-mediated methotrexate neurotoxicity via direct endothelial injury. *Pediatr Hematol Oncol* 2010;27:46–52.
- [20] Wani NA, Kosar T, Pala NA, et al. Sagittal sinus thrombosis due to L-asparaginase. *J Pediatr Neurosci* 2010;5:32–5.
- [21] Alsaid Y, Gulab S, Bayoumi M, et al. Cerebral sinus venous thrombosis due to asparaginase therapy. *Case Rep Hematol* 2013;2013:841057.
- [22] Akdal G, Donmez B, Cakmakci H, et al. A case with cerebral thrombosis receiving tamoxifen treatment. *Eur J Neurol* 2001;8:723–4.
- [23] Kim Y, Kim OJ, Kim J. Cerebral venous thrombosis in a breast cancer patient taking tamoxifen: report of a case. *Int J Surg Case Rep* 2015;6:77–80.
- [24] Hwang SK. A case of dural arteriovenous fistula of superior sagittal sinus after tamoxifen treatment for breast cancer. *J Korean Neurosurg Soc* 2015;57:204–7.
- [25] Gazioglu S, Solmaz D, Boz C. Cerebral venous thrombosis after high dose steroid in multiple sclerosis: a case report. *Hippokratia* 2013;17:88–90.
- [26] Benadiba J, Robitaille N, Lambert G, et al. Intravenous immunoglobulin-associated thrombosis: is it such a rare event? Report of a pediatric case and of the Quebec Hemovigilance System. *Transfusion* 2015;55:571–5.
- [27] Fesler MJ, Creer MH, Richart JM, et al. Heparin-induced thrombocytopenia and cerebral venous sinus thrombosis: case report and literature review. *Neurocrit Care* 2011;15:161–5.
- [28] Ferro JM, Canhao P, Stam J, et al. Prognosis of cerebral vein and dural sinus thrombosis: results of the International Study on Cerebral Vein and Dural Sinus Thrombosis (ISCVT). *Stroke* 2004;35:664–70.
- [29] De Bruijn SF, Stam J, Kappelle LJ. Thunderclap headache as first symptom of cerebral venous sinus thrombosis. *CVST Study Group. Lancet* 1996;348:1623–5.
- [30] Cantu C, Barinagarrementeria F. Cerebral venous thrombosis associated with pregnancy and puerperium. Review of 67 cases. *Stroke* 1993;24:1880–4.
- [31] Ferro JM, Canhao P. Cerebral venous sinus thrombosis: update on diagnosis and management. *Curr Cardiol Rep* 2014;16:523.
- [32] Masuhr F, Mehraein S, Einhaupl K. Cerebral venous and sinus thrombosis. *J Neurol* 2004;251:11–23.
- [33] Fuentes B, Martinez-Sanchez P, Raya PG, et al. Cerebral venous sinus thrombosis associated with cerebral hemorrhage: is anticoagulant treatment safe? *Neurologist* 2011;17:208–10.
- [34] Stolz E, Valdueza JM, Grebe M, et al. Anemia as a risk factor for cerebral venous thrombosis? An old hypothesis revisited. Results of a prospective study. *J Neurol* 2007;254:729–34.
- [35] Coutinho JM, Zuurbier SM, Gaartman AE, et al. Association between anemia and cerebral venous thrombosis: case-control study. *Stroke* 2015;46:2735–40.
- [36] Püschel A, Lindenblatt N, Katzfuss J, et al. Immunosuppressants accelerate microvascular thrombus formation in vivo: role of endothelial cell activation. *Surgery* 2012;151:26–36.
- [37] Tomasiak M, Rusak T, Gacko M, et al. Cyclosporin enhances platelet procoagulant activity. *Nephrol Dial Transplant* 2007;22:1750–6.
- [38] Papachristou E, Papadimitropoulos A, Kotsantis P, et al. Interaction of endothelin-1 and nitric oxide pathways in human tubular epithelial cells under the influence of cyclosporin-A. *Ren Fail* 2010;32:727–32.