

Fatal Course of a Suicidal Intoxication with Hydrochloric Acid

Ronald Koschny^a Maria Herceg^b Wolfgang Stremmel^a
Christoph Eisenbach^a

Departments of ^aGastroenterology and ^bAnesthesiology, University Hospital Heidelberg, Heidelberg, Germany

Key Words

Intoxication · Ingestion · Suicide · Hydrochloric acid

Abstract

Suicidal ingestion of undiluted hydrochloric acid is a rare but life-threatening event. We report on the dramatic and fulminant course of a 61-year-old woman who drank 200 ml of 30–33% hydrochloric acid. On admission to our intensive care unit she was alert and oriented with stable vital signs. Gastroscopy demonstrated complete necrosis from the hypopharynx to the pylorus, which was flushed continuously via drainage catheters. At that time point perforation was not evident. Shortly thereafter she developed an acute abdomen and a tension pneumothorax which was decompressed. CT scan demonstrated esophageal and intestinal perforation with massive mediastinal necrosis. On emergency laparotomy she showed complete necrosis of the intestine and stomach. The patient died 10 h after admission from multiorgan failure. The therapeutic options are critically discussed in comparison to previously reported cases in the literature.

Introduction

In contrast to frequent intoxications with benzodiazepines or alcohol [1], ingestion of alkaline or acid in adults is rare [2]. Diluted acid/alkali usually induces limited mucosal damage. In contrast, concentrated alkali results in severe esophageal damage with liquefaction necrosis, whereas acids tend to spare the esophagus and produce necrosis of the stomach with coagulation necrosis [3]. However, there seems to be no difference between alkali and acid ingestion regarding hospital stay and complication rate [4], although less favorable outcome for acid ingestion has also been reported [5]. Hydrochloric acid (HCl; pH 1) is a widespread industrial product used in several countries as a toilet cleaner. Treatment of

Dr. Ronald Koschny
Department of Gastroenterology, University Hospital Heidelberg
Im Neuenheimer Feld 410
DE-69120 Heidelberg (Germany)
E-Mail ronald.koschny@med.uni-heidelberg.de

accidental or suicidal ingestion of undiluted hydrochloric acid mainly consists of close clinical monitoring and symptomatic therapy with gastric lavage, treatment of acidosis, pain and hemolysis. Emergency operation is indicated upon detected or suspected perforation, resulting in high mortality rates [4, 6]. We report on a fulminant course after suicidal ingestion of undiluted hydrochloric acid with a lethal outcome.

Case Report

We report on an otherwise healthy 61-year-old woman who orally ingested 200 ml of concentrated hydrochloric acid (30–33%) from a storage container in a suicide attempt. Upon arrival of the emergency physician, the patient was fully oriented (Glasgow Coma Scale 14) and complained about intensive pain in her mouth and throat, hoarseness and difficult swallowing. Aspiration of acid was denied. Her vital signs were stable (pulse 81/min, systolic blood pressure 110 mm Hg, oxygen saturation 97% under room air). On examination she did not show any abnormalities except for significant signs of chemical burn in her mouth and a slightly swollen tongue. She was given oxygen (6 l/min via oxygen mask) and treated with piritramide, metoclopramide and 200 mg methylprednisolone and immediately admitted to our intensive care unit.

Upon arrival she was intubated for airway protection for the following examination. An emergency gastroscopy was performed, which showed complete necrosis of the hypopharynx, esophagus and stomach (grade 3b according to Zargar et al. [7]) (fig. 1). Depth of necrosis could not be evaluated, but perforation was not evident. Continuous irrigation (250 ml water/h) was performed after endoscopically guided insertion of naso-esophageal and nasogastric tubes. Antibiotic therapy was initiated with ceftriaxone. Pantoprazole was started with 80 mg bolus followed by continuous perfusion with 8 mg/h. Chest X-ray did not show pneumothorax or signs of mediastinal widening. Due to metabolic acidosis (pH 6.93, base excess -24 mmol/l) and hyperkalemia (7.3 mmol/l), glucose/insulin infusion, furosemide and Tris buffer were applied and hemodialysis was initiated. Initial laboratory analysis and follow-up parameters are given in table 1.

On repeated physical examination she developed a tense abdomen after 4 h. X-ray in the left lateral position showed massive amounts of free air in the abdominal cavity. Therefore, a CT scan was performed, demonstrating gastric perforation with free abdominal air, retroperitoneal air, multiple hypodense lesions of the liver and left-sided tension pneumothorax with pleural effusion and mediastinal necrosis (fig. 2). After immediate decompression of the tension pneumothorax (Monaldi) a thoracic drainage (Bülau) was inserted. Under constant naso-oral/naso-gastric irrigation the thoracic drainage purged acidic (pH <3 on flash test) coarse flocculent necrotic material, indicating esophageal and mediastinal perforation.

The patient was transferred to the operation theatre for exploration. Here she showed a completely necrotic stomach, small and large intestine without any therapeutic options (fig. 3). She died 10 h after admission from multiorgan failure.

Discussion

In adults acid ingestion is mainly suicidal rather than accidental, which is associated with higher concentration and ingested volume of acids [5, 8]. Pre-hospital therapy is mainly symptomatic and aims for dilution of the ingested corrosive. Inducing vomiting for acid removal is obsolete because a second contact with the esophageal mucosa might aggravate

tissue damage. Our patient was found by her husband early after acid ingestion and was given a cup of tea for acid dilution. Upon arrival of the emergency physician she complained of difficult swallowing. To avoid aspiration no further oral dilution attempts were undertaken. Blind insertion of a gastric tube for oral drainage might be discussed but was omitted due to the risk of perforation and induction of regurgitation or vomiting.

Although clinical benefit from early corticosteroids in corrosive injury has been anecdotically reported, a randomized trial did not show reduction of esophageal strictures by prednisolone [9]. Therefore, the routine use of steroids as a prophylaxis for stricture formation, especially in grade 2 caustic burn, is not recommended [10]. In our case administration of methylprednisolone might have been dispensable.

Since clinical symptoms and degree of oropharyngeal burn do not predict the severity of gastroesophageal injury [11], early diagnostic endoscopy (within 12 h) is recommended, especially after ingestion of undiluted acid, a large amount of agent and third-degree burn of the oropharynx [4]. The 6-point classification system by Zargar et al. [7] is predictive for the clinical course and thus commonly used for quantitatively describing mucosal injury. Mucosal grade 3a (multiple ulcerations/necrotic areas) and grade 3b injury (extensive necrosis) have been reported in up to 28 and 43%, respectively, after hydrochloric acid ingestion [4]. In our case immediate gastroscopy was performed for removal of remaining acid, insertion of drainages and risk evaluation demonstrating grade 3b injury in the complete esophagus and stomach.

Mucosal injury grade 3 (Zargar) is associated with a high rate of systemic complications including bleeding and perforation [4]. Using a 3-point classification system, Poley et al. [5] reported on a high risk of systemic complications (RR 3.0), such as renal insufficiency, hepatic dysfunction, disseminated intravascular coagulation and hemolysis in grade 3 mucosal burn (hemorrhage, deep ulceration). Mortality of patients with one or more systemic complications was considerably high (45%). Dalus et al. [6] reported a 100% mortality in patients with perforation or orotracheal fistula. Hypotension, respiratory symptoms, high volume or concentration of ingested acid, hematemesis, metabolic acidosis and development of acute respiratory distress syndrome were identified as further risk factors for death.

There are no therapeutic standards for caustic injuries, although clinical data suggest that grade I and IIa burns (according to Zargar) can be managed conservatively even without antibiotic therapy. Grade IIb–IIIb injuries have a high risk to develop post-acute strictures and should be treated by early endoscopic dilatation. Prophylactic antibiotic therapy and parenteral nutrition is generally recommended. In contrast, the role of surgical intervention without overt perforation is less well defined. In a case series including ingestion of concentrated acid, operation was performed only when perforation was evident. Despite surgical intervention 50% of these patients died [5].

Robustelli et al. [12] suggested to perform CT scan in every patient with endoscopic grade 3 burn to detect early signs of perforation. Zerbib et al. [13] discussed a more aggressive management for patients with endoscopic grade 3 mucosal injury: despite lack of perforation, emergency operation was performed when at least 1 of 6 risk factors was present (abdominal tenderness, neurological impairment, cardiovascular shock, metabolic acidosis, disseminated intravascular coagulation, kidney failure). According to this algorithm 20 of 66 eligible patients with endoscopic grade 3 injury underwent laparotomy within 48 h after admission. Four of these patients had clinical signs of peritonitis and were operated within 2 h after admission with a postoperative mortality rate of 50% (n = 2). Another patient in the ‘delayed’ operation group (up to 48 h) also died postoperatively. Eight of 46 patients with initial conservative management (conservative arm) eventually required surgery at a median of 78 days.

Due to the rapid clinical deterioration in our case with development of acute abdomen 5 h after admission, early CT scan was performed, demonstrating massive necrosis of the esophagus and stomach with abdominal and mediastinal perforation. Therefore, our patient underwent emergency operation 7 h after admission, demonstrating already complete intestinal and mediastinal necrosis. According to the algorithm by Zerbib et al. [13], metabolic acidosis was present as a risk factor in our patient. Therefore, emergency operation could have been discussed directly after endoscopy. Accordingly, in the report of a case similar to ours but with ingestion of only 20 ml of concentrated hydrochloric acid, endoscopy demonstrated grade 3 mucosal injury without signs of perforation [14]. Emergency operation with partial esophagectomy and complete gastrectomy was performed with favorable outcome. However, in our patient efflux of acidic necrotic material with pH <3 via pleural drainage only a few hours after admission despite constant esophageal irrigation indicates rapid and massive tissue destruction. Thus, the benefit of any earlier surgical intervention remains questionable. Additionally, elevated and steeply increasing troponin retrospectively indicated early myocardial damage. This might result from direct cardiac corrosion after early esophageal perforation. Another published case with ingestion of 150 ml concentrated hydrochloric acid demonstrated metabolic acidosis (pH 7.14) at admission without signs of perforation [15]. However, after 6 h peritonitis became clinically evident and necrosectomy, total gastrectomy and partial esophagectomy were performed after radiological detection of free abdominal air due to an intraoperatively detected 10 cm gastric perforation. This report is quite similar to our patient, but demonstrated a more favorable outcome after the comparably late 'on demand' surgical intervention than in our case.

Taken together, we reported on a dramatic and fulminant course of hydrochloric acid ingestion. Early oral dilution of the ingested agent, immediate admission to an intensive care unit with endoscopic evaluation and permanent clinical re-evaluation is crucial in the management of this kind of intoxication. Due to lacking data, the time point of extended radiological diagnostics and surgical intervention in cases without evident perforation needs to be defined on an individual basis and in close cooperation between the intensive care unit team, endoscopist, radiologist and surgeon.

Acknowledgements

The authors would like to thank the following colleagues of the University Hospital Heidelberg for their cooperation in the clinical management of this patient: Dr. Andreas Winzer, Dr. Philipp Zwickel, Dr. Anja Schaible, Prof. Dr. Peter Hallscheidt, Prof. Dr. Alexis Ulrich and Dr. Friedrich Hubertus Schmitz-Winnenthal.

Disclosure Statement

None of the authors has any conflict of interest to disclose.

References

- Eisenbach C, Ungur AL, Unger J, Stremmel W, Encke J: Admission to intensive care for parasuicide by self-poisoning: variation by time cycles, climate and the lunar cycle. *Psychiatry Res* 2008;161:177–184.
- Christesen HB: Caustic ingestion in adults – epidemiology and prevention. *J Toxicol Clin Toxicol* 1994;32:557–568.
- Bosher LW Jr, Burford TH, Ackerman L: The pathology of experimentally produced lye burns and strictures of the esophagus. *J Thorac Surg* 1951;21:483–489.
- Cheng HT, Cheng CL, Lin CH, Tang JH, Chu YY, Liu NJ, Chen PC: Caustic ingestion in adults: the role of endoscopic classification in predicting outcome. *BMC Gastroenterol* 2008;8:31.
- Poley JW, Steyerberg EW, Kuipers EJ, Dees J, Hartmans R, Tilanus HW, Siersema PD: Ingestion of acid and alkaline agents: outcome and prognostic value of early upper endoscopy. *Gastrointest Endosc* 2004;60:372–377.
- Dalus D, Mathew AJ, Somarajan Pillai S: Formic acid poisoning in a tertiary care center in South India: a 2-year retrospective analysis of clinical profile and predictors of mortality. *J Emerg Med* 2013;44:373–380.
- Zargar SA, Kochhar R, Mehta S, Mehta SK: The role of fiberoptic endoscopy in the management of corrosive ingestion and modified endoscopic classification of burns. *Gastrointest Endosc* 1991;37:165–169.
- Arevalo-Silva C, Eliashar R, Wohlgelemlerter J, Elidan J, Gross M: Ingestion of caustic substances: a 15-year experience. *Laryngoscope* 2006;116:1422–1426.
- Anderson KD, Rouse TM, Randolph JG: A controlled trial of corticosteroids in children with corrosive injury of the esophagus. *N Engl J Med* 1990;323:637–640.
- Fulton JA, Hoffman RS: Steroids in second degree caustic burns of the esophagus: a systematic pooled analysis of fifty years of human data: 1956–2006. *Clin Toxicol (Phila)* 2007;45:402–408.
- Gaudreault P, Parent M, McGuigan MA, Chicoine L, Lovejoy FH Jr: Predictability of esophageal injury from signs and symptoms: a study of caustic ingestion in 378 children. *Pediatrics* 1983;71:767–770.
- Robustelli U, Bellotti R, Scardi F, Fortunato Armellino M, De Masi A, Forner AL, Riccio E, Manguso F: Management of corrosive injuries of the upper gastrointestinal tract. Our experience in 58 patients. *G Chir* 2011;32:188–193.
- Zerbib P, Voisin B, Truant S, Saulnier F, Vinet A, Chambon JP, Onimus T, Pruvot FR: The conservative management of severe caustic gastric injuries. *Ann Surg* 2011;253:684–688.
- Diaz-Sanchez A, Carrion G, Barreiro A, Ortiz C, De Fuenmayor ML, Gimeno M, Ponferrada A, Martin S, Aldeguer M: Massive gastric necrosis from hydrochloric acid ingestion. *Rev Esp Enferm Dig* 2009;101:568–570.
- Juriscic D, Samardzic J, Hreckovski B, Bano V, Jakovina T, Held R: Massive necrosis of the upper gastrointestinal tract with acute gastric perforation and metabolic acidosis after hydrochloric acid (HCl) ingestion. *Zentralbl Chir* 2011;136:289–290.

Table 1. Laboratory analysis

Parameter	Normal range	9:49	13:32	15:55
pH (arterial)	7.36–7.44	7.09	7.16	7.26
Base excess, mmol/l	–5 to +5	–13	–14	–12.5
GFR, ml/min	>80	77.5	46.5	48.9
Creatine kinase, U/l	<170	183	178	324
Highly sensitive troponin T, pg/ml	<50	177	417	615
LDH, U/l	<248	479	833	1,192
ASAT, U/l	<35	65	162	317
CRP, mg/l	<5	<2.0	<2.0	3.0
PCT, ng/ml	<0.05	0.07	3.4	7.6
Lactate, mmol/l	0.6–1.6	1.6	3.8	4.6
Leukocytes, /nl	4–10	18.5	19.3	20.3
Hemoglobin, g/dl	12–15	15.4	12.0	11.3
INR	<1.2	1.07	1.74	2.12

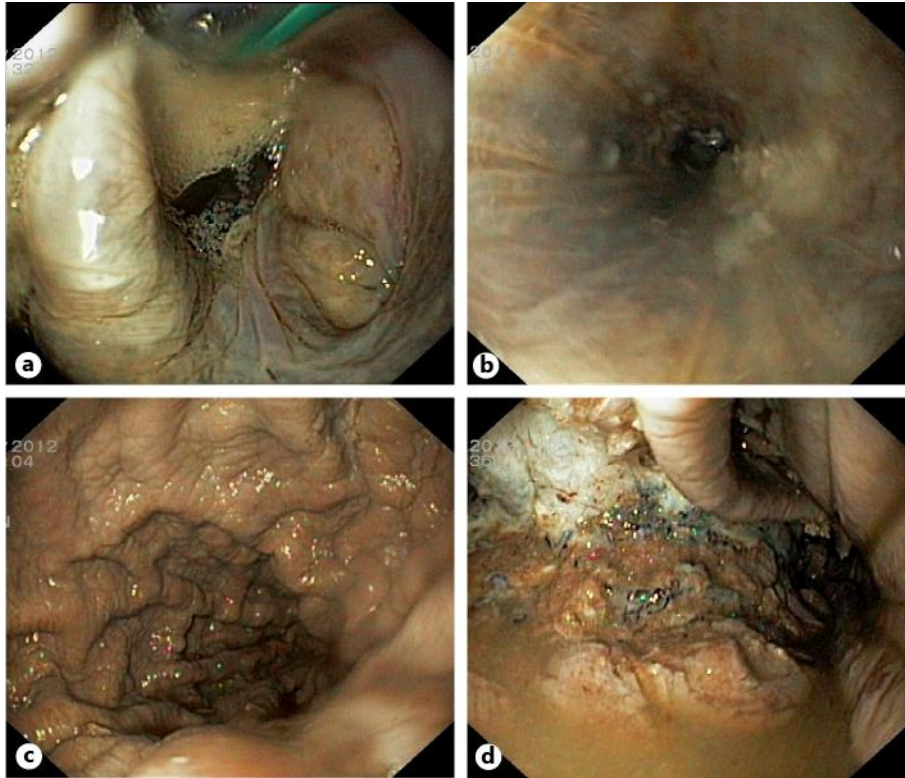


Fig. 1. Endoscopy demonstrated complete necrosis from the hypopharynx to the pylorus. **a** Hypopharynx (upper part: tracheal tube). **b** Esophagus. **c** Gastric corpus. **d** Gastric antrum.

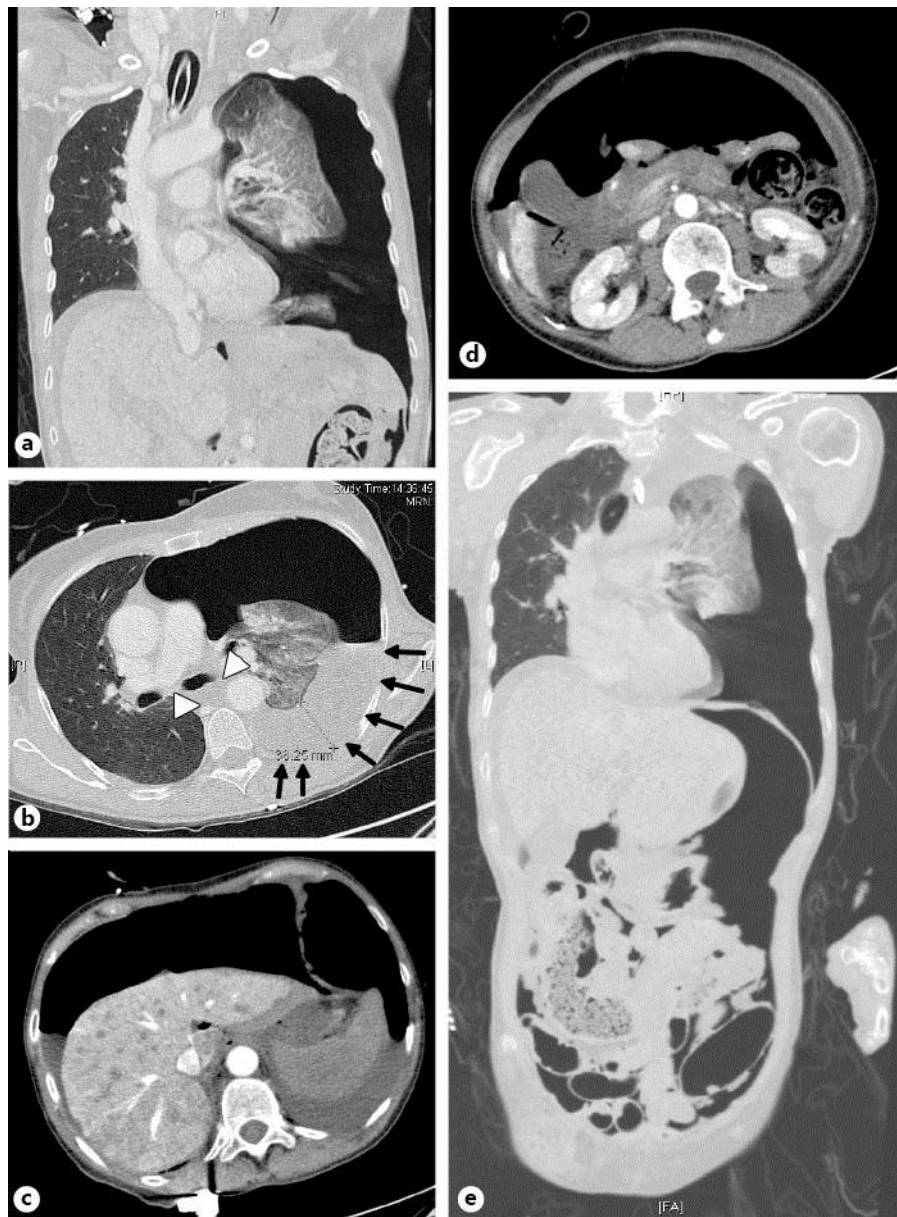

Fig. 2. CT scan of the chest and abdomen demonstrated tension pneumothorax (**a, b**), necrotic esophagus (**b**, white arrowheads), necrotic pleural effusion (**b**, black arrows) and gastrointestinal perforation with free air in the abdominal cavity (**c, d**). **e** Frontal reconstruction of the CT scan.

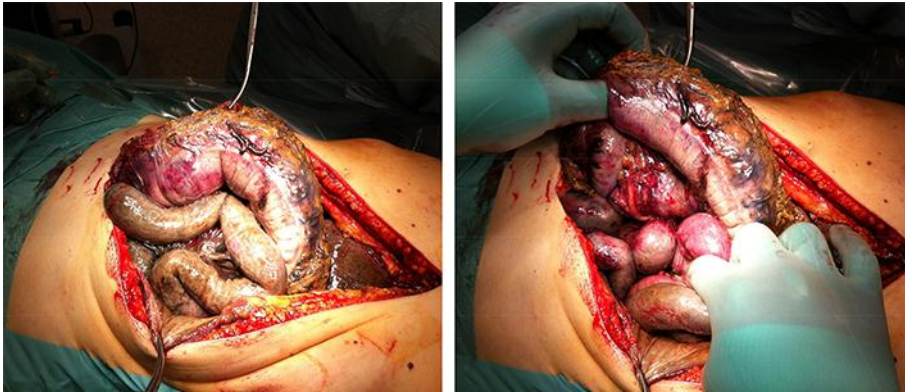


Fig. 3. Intraoperative view of exploratory laparoscopy showing the complete necrotic intestine.