

Arthroscopic-Assisted Lower Trapezius Tendon Transfer for Massive Irreparable Posterosuperior Rotator Cuff Tears Using an Achilles Tendon-Bone Allograft



Eugene T. Ek, M.B.B.S., Ph.D., F.R.A.C.S., Timothy Lording, M.B.B.S., F.R.A.C.S., and Andrew P. McBride, M.B.B.S., F.R.A.C.S.

Abstract: The lower trapezius tendon (LTT) transfer has been described for the management of irreparable posterosuperior rotator cuff tears. Here we describe our technique of an arthroscopic-assisted LTT transfer using an Achilles tendon-bone allograft. This technique allows for augmentation of the tendon transfer using an Achilles tendon allograft while also keeping the calcaneal bone insertion, which allows for added bony fixation into the humerus and also minimizing the risk of the "killer turn" phenomenon at the aperture of fixation.

The management of massive irreparable tears of the rotator cuff is a challenging problem, especially in the young and active individual. Tendon transfers around the shoulder to treat irreparable posterosuperior rotator cuff tears was first described by Gerber in 1988, who showed that transfer of the latissimus dorsi tendon (LDT) can successfully improve shoulder function and range of motion in such patients.¹ However, the literature has shown that success of this procedure depends on careful patient selection, which includes an intact or repairable subscapularis tendon, absent or minimal glenohumeral arthropathy,

nonpseudoparalytic shoulder, and absent or minimal superior humeral head migration.²

Although several authors have shown reliable improvement in overall shoulder function and decrease in pain levels following the LDT transfer, some studies have reported variable functional outcomes.^{3,4} Costouros et al.⁵ showed that the status of the teres minor plays an important role because patients with teres minor fatty infiltration demonstrated poorer results following LDT transfer. Furthermore, some authors suggest that LDT transfer does not always satisfactorily restore external rotation with the arm at the side, especially in the setting of teres minor pathology.^{5,6} This may be explained by a biomechanical study conducted by Herzberg et al.⁷ who showed the transferred LDT had less strength than the teres minor and infraspinatus muscles and a differing vector across the glenohumeral joint.

In 2016, Elhassan et al.^{8,9} described the lower trapezius tendon (LTT) transfer as an alternative to LDT transfer for management of irreparable posterosuperior rotator cuff tears. Although the LTT was shown biomechanically to provide less strength than the infraspinatus, it provided both greater excursion and a vector more similar to infraspinatus and teres minor compared to the LDT transfer.^{9,10} As such, this results in an improved anteroposterior balancing force across the glenohumeral joint. Although the long-term outcomes of LTT transfer are still lacking, when

From the Melbourne Orthopaedic Group (E.T.E., T.L., A.P.M.), Windsor, Melbourne, Victoria, Australia; and Department of Surgery, Monash Medical Centre (E.T.E.), Monash University, Melbourne, Australia

The authors report the following potential conflicts of interest or sources of funding: E.T.E. and T.L. have been paid consultants for Device Technologies, Australia, which is a distributor for Arthrex. E.T.E. and the Melbourne Orthopaedic Group receive fellowship funding support from Device Technologies, Australia. Full ICMJE author disclosure forms are available for this article online, as [supplementary material](#).

Received May 20, 2020; accepted July 28, 2020.

Address correspondence to Eugene Ek, M.B.B.S., Ph.D., Melbourne Orthopaedic Group, 33 The Avenue, Windsor, Melbourne, 3181, VIC, Australia. E-mail: eugene.ek@mog.com.au

© 2020 by the Arthroscopy Association of North America. Published by Elsevier. This is an open access article under the CC BY-NC-ND license (<http://creativecommons.org/licenses/by-nc-nd/4.0/>).

2212-6287/20901

<https://doi.org/10.1016/j.eats.2020.07.018>

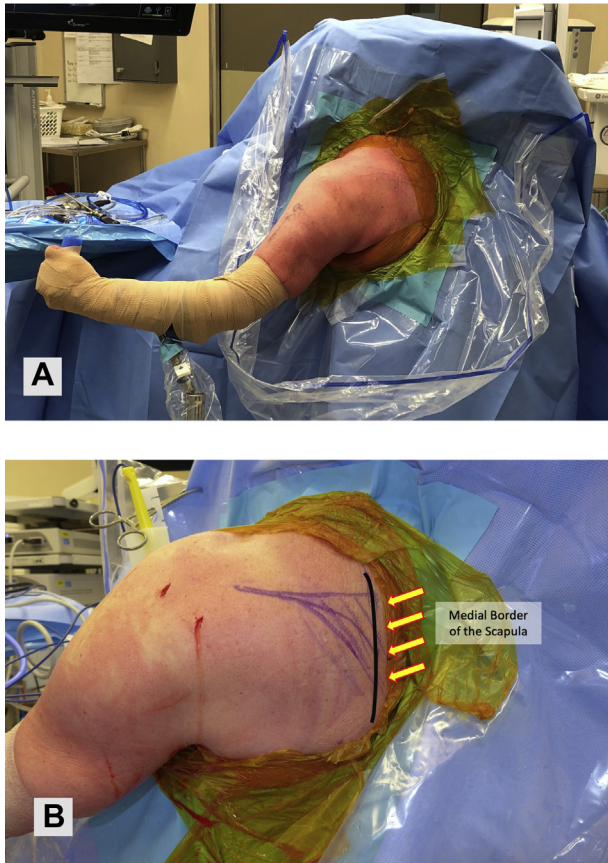


Fig 1. Patient positioning (left shoulder). (A) Patient is placed in a beach chair position with the operated arm in a pneumatic articulating arm holder. (B) Exposure of the whole posterior scapula beyond the medial border, is important for lower trapezius tendon harvest.

compared with the LDT transfer, early to mid-term results are indeed promising.^{8,11}

Because of the relatively short tendon of the lower trapezius, this invariably requires an intercalary tendon graft as an augment between the LTT and the greater tuberosity. Both autologous and allograft hamstring tendon and Achilles tendon allograft have been described in the literature for this purpose.¹¹ Furthermore, various open and arthroscopic-assisted techniques have been reported to fix the LTT graft to the greater tuberosity, including onlay techniques with suture anchor fixation or tubularization of the tendon into a bone tunnel.¹¹ Results of these transfer techniques for the LTT have not yet been well established; however, they have been extensively used for LDT transfer, and recent reports suggest that the rupture rate is up 40% to 50%.¹² Therefore, reliable fixation of the tendon transfer is paramount.

A concern with an inlay technique, where the tendon is tubularized and inserts at a right angle into the bone, is the so called "killer turn" in the graft around the bony edge, which has been shown to

increase tensile forces on the graft, leading to elongation and eventual failure, or tunnel widening.¹³ As such, onlay techniques have become increasingly popular to avoid this potential complication. Such has been the case with posterior cruciate ligament surgery in the knee. However, in the knee, calcaneal bone blocks attached to Achilles tendon allografts have been increasingly used for posterior cruciate ligament reconstruction as the bone block allows for bony fixation and gives versatility in addressing possible bone voids from prior surgery, whereas avoiding the "killer turn" at the aperture of fixation. All these factors are relevant when considering its similar use in the shoulder. Hence, here we describe our technique using an Achilles tendon-bone allograft for arthroscopic-assisted lower trapezius tendon transfer.

Surgical Technique

Patient Positioning and Diagnostic Arthroscopy

The patient is placed in a beach chair position, with the operated arm placed into a hydraulic arm holder (Spider2, Smith & Nephew, UK) (Fig 1A). Preoperatively, range of motion of both shoulders is examined. Anatomic landmarks are marked, the operative site is draped after sterile preparation, and the arm is fixed in the arm holder. It is important that the whole posterior scapular is exposed up to the medial border to allow for LTT harvest (Fig 1B).

A diagnostic glenohumeral arthroscopy is performed using a 30° arthroscope viewing from a standard

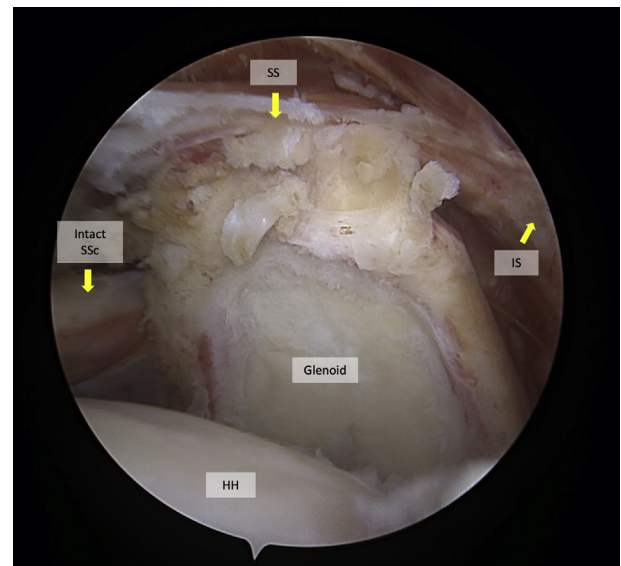


Fig 2. Arthroscopic view of the left shoulder from the posterolateral portal showing a massive irreparable tear of the supraspinatus (SS) and infraspinatus (IS) tendons. The subscapularis tendon is noted to be intact (SSc). (HH, humeral head.)

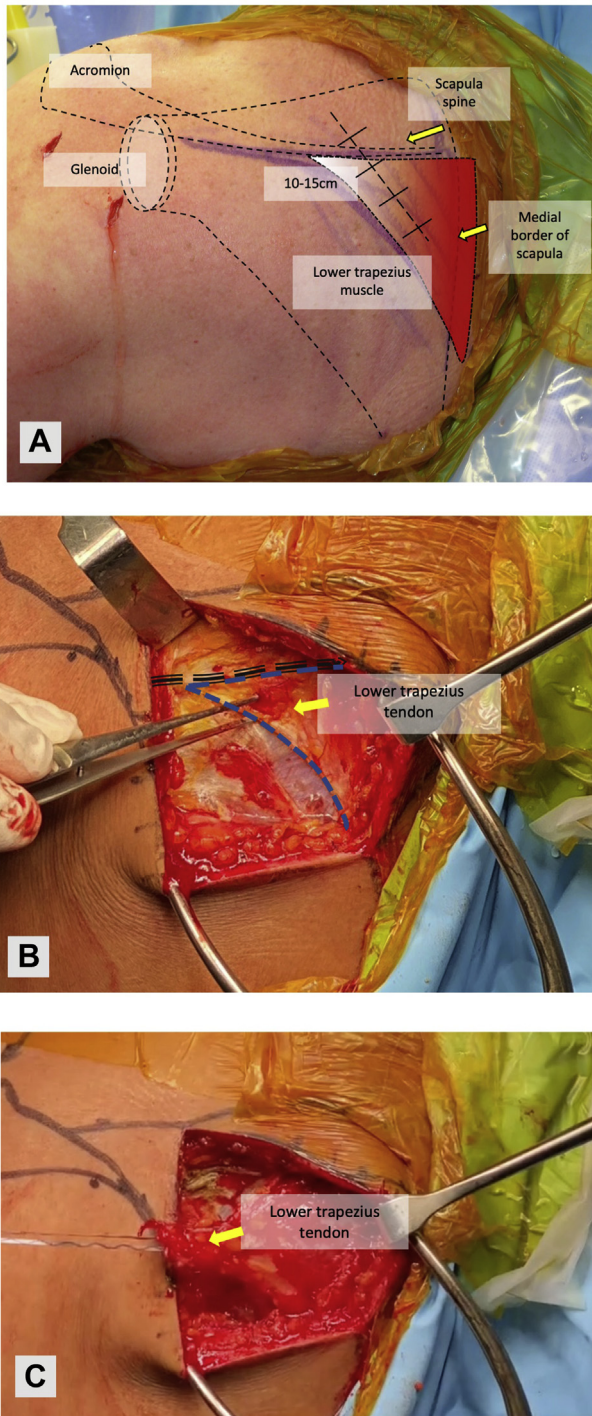


Fig 3. (A) The bony landmarks of the posterior scapular of the left shoulder. The lower trapezius tendon (red) inserts to the medial one-third of the scapula spine. The oblique incision is approximately 10 to 15 cm long and centered just medial to the lower trapezius tendon insertion (dashed line). (B) The lower trapezius tendon can be identified as it inserts into the scapula spine. (C) The lower trapezius tendon muscle is then released superficially and deep mobilized to obtain maximal excursion.

posterior portal. Absence of significant glenohumeral arthritis is confirmed. Inspection of the subscapularis tendon is imperative to ensure its integrity. If torn, an arthroscopic subscapularis tendon repair is performed. However, if irreparable, this precluded the continuation of an LTT transfer and the planned surgery is abandoned ([Video 1](#)).

Soft-Tissue Releases and Greater Tuberosity Preparation

An extensive release and clearance of the rotator interval is undertaken, and the anterior capsular release also release inferiorly to allow for the humeral head to recenter in the event of development of superior humeral head migration. The subacromial bursa is removed from the subdeltoid space and the rotator cuff is assessed. The retracted posterosuperior rotator cuff is grasped to confirm that the tendon is in fact irreparable ([Fig 2](#)). The remaining tendon remnants on the greater tuberosity are cleared and the site for the graft insertion is determined. We aim to insert the Achilles tendon-bone block at the upper aspect of the infraspinatus tendon insertion. The interval between the deltoid and the infraspinatus and teres minor is identified and developed to allow for later passage of the tendon allograft.

Lower Trapezius Tendon Harvest

The medial border of the scapula, the scapula spine, and the tendon insertion of the LTT are marked on the skin before the procedure ([Fig 3A](#)). The lower trapezius inserts into the medial third of the scapula spine. A 10- to 15-cm oblique incision is made over the lower trapezius tendon insertion and the subcutaneous tissue is dissected and removed until the tendon is identified. The LTT is identified as an oblique tendon, which can be elevated off from the underlying infraspinatus muscle and can be seen with its horizontal oriented fibers ([Fig 3B](#)). The tendon is then detached from the scapula spine and extensive mobilization is performed superiorly and medially along the upper border of the tendon to separate it from the middle trapezius ([Fig 3C](#)). Care is taken to avoid injury to spinal accessory nerve that runs inferior to the muscle, approximately 3 to 4 cm medial to the scapula.

Achilles Tendon-Bone Allograft Preparation

We prefer the use of a nonirradiated Achilles tendon allograft with the calcaneal bone block still attached. We are fortunate that the institution that provides our allograft preprepares the graft, leaving a bone block attached measuring approximately 1 cm × 25 cm in dimensions ([Fig 4A](#)). The graft is prepared on the back

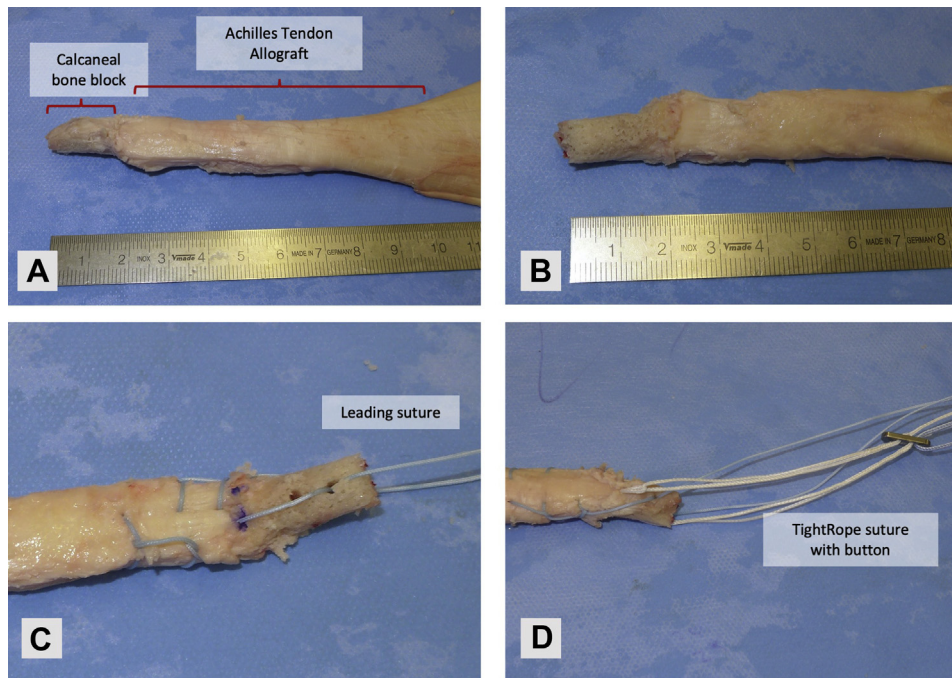


Fig 4. Achilles tendon-bone allograft. (A) Calcaneal bone block precut and left attached to the tendon allograft. (B) The bone block is compressed in a cylinder down to approximately 8 mm in diameter. (C) A high-strength suture is passed through the bone block and the tendon is whip stitched. This provides good grasping fixation to the graft and bone as it is pulled into the shoulder joint. (D) The Arthrex TightRope device with the attached EndoButton is applied to the bone block.

table. The bone block is tubularized using a cylinder clamp to shape the graft to fit an 8-mm bone tunnel (Fig 4B). The bone is also shorted to approximately 20 mm in length. A 2.0-mm drill hole is made through the bone block and a No. 2 FiberWire suture (Arthrex, Naples, FL) is passed through the bone and the tendon is then whip stitched up and down for approximately 5 cm to obtain a stable grasp on the tendon. The suture again passes through the drill hole in the opposite direction as the previous suture. This suture acts as the leading suture that will aid in docking the bone block into the humeral tunnel (Fig 4C). The Arthrex BTB (bone-tendon-bone) TightRope Graft fixation system (Arthrex) is then applied to the Achilles bone block according to the technique guide (Fig 4D, Video 1).

Arthroscopic Insertion of the Achilles Tendon-Bone Allograft into the Humerus

The arthroscope is reentered into the shoulder joint through the posterior portal and the bicipital groove is identified because this is the hardest bone on the anterior aspect of the humeral head. A drill sleeve is then applied and a guide wire is passed from anterior to posterior, with the goal being that the pin exits at the upper part of native infraspinatus tendon insertion point (Fig 5A). The guidewire is exchanged for

an 8.5-mm flip cutter drill that is passed through the anterior drill sleeve through the humerus from anterior to posterior (Fig 5B). The flip cutter is then flipped and a retrograde 8.5 mm × 20 mm tunnel is made (Fig 5C). A suture shuttle is passed from anterior to posterior and is retrieved out of the posterior portal.

At the posterior incision site, a plane to pass the graft is created by incising the infraspinatus fascia through the posterior incision. One can expect a gush of fluid as this communicates with the shoulder joint. A long grasper is then inserted along the length of the infraspinatus muscle and the shuttling suture is pulled out of the posterior wound. The sutures attached to the allograft are loaded through suture loop and then pulled into the shoulder and out anteriorly through the humerus. With tension on the No. 2 FiberWire suture, the bone block with its trailing tendon is pulled into the shoulder joint. As the bone enters the humeral tunnel, a grasper is inserted arthroscopically and used to guide the bone into the tunnel (Fig 6A). Once completely docked, the TightRope sutures are then tensioned, which securely pulls the button to the humerus providing very stable fixation of the graft (Fig 6B). When tension is placed on the tendon graft, one should see the humeral head externally rotate.

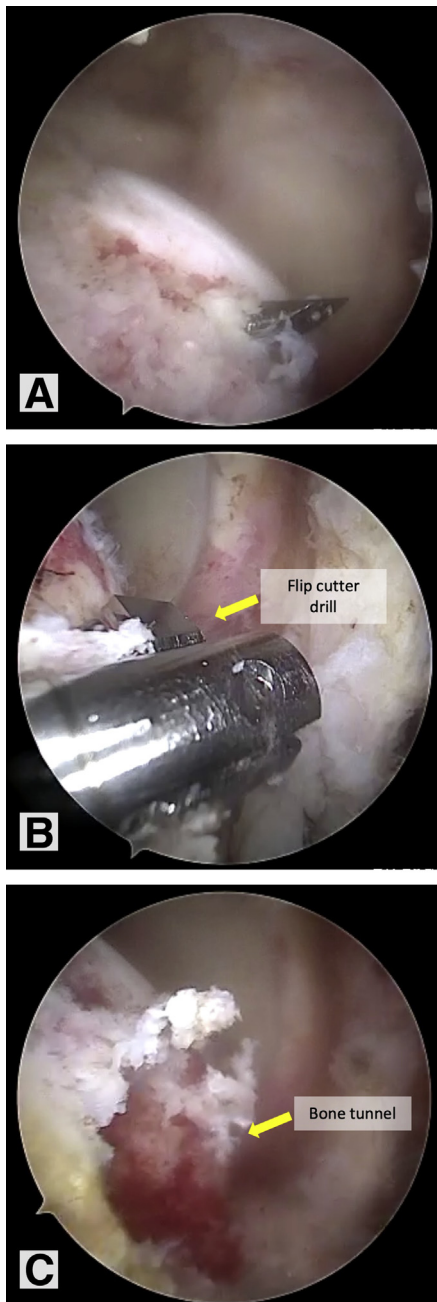


Fig 5. (A) A guide wire is advanced from the bicipital groove anteriorly and exits at the upper portion of the infraspinatus insertion on the greater tuberosity. (B) A flip cutting drill is then advanced along that path and the flip cutter is flipped. (C) A retrograde 8.5 mm × 20 mm tunnel is made. (Left shoulder, posterolateral viewing portal).

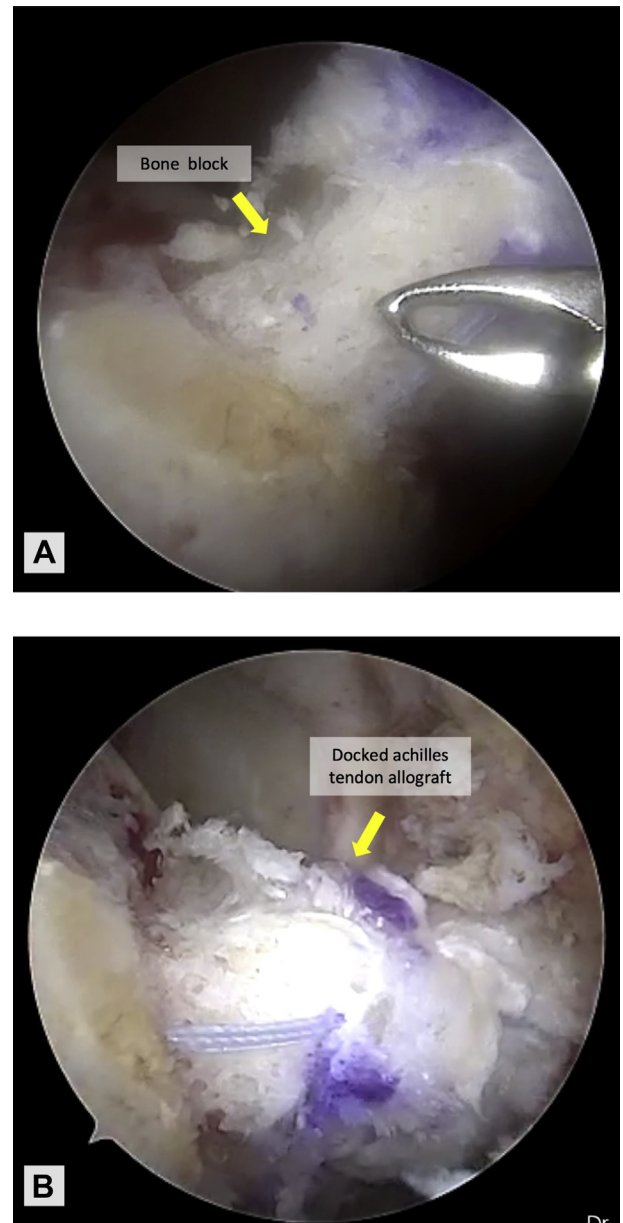


Fig 6. (A) The bone block is advanced into the tunnel with counterpressure from pulling on the sutures coming out of the anterior cortex. Docking of the graft is assisted by a grasper. (B) The Achilles tendon-bone allograft is securely docked into the humeral head at the desired insertion point. (Left shoulder, posterolateral viewing portal).

Graft Attachment to the Lower Trapezius and Tensioning

To inset the Achilles tendon to the lower trapezius tendon, the shoulder is placed in 45° of abduction and 30° of external rotation. The tendon allograft is split into 3 tails (Fig 7A) that are then weaved, in a Pulvertaft fashion, through the lower trapezius tendon under maximal tension (Fig 7B). Once complete, the shoulder is rotated and the LTT transfer should move

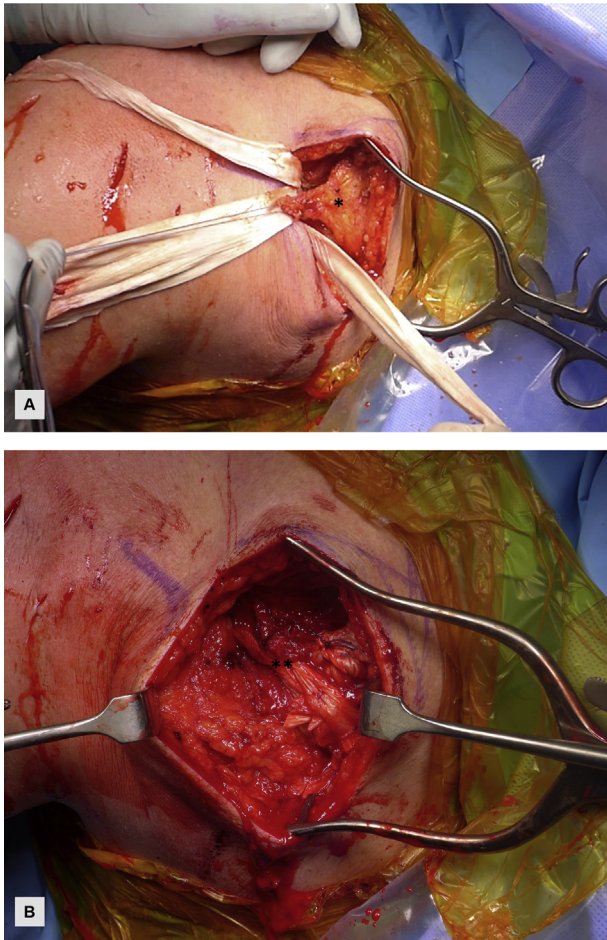


Fig 7. (A) The Achilles tendon allograft is split into 3 tails that are weaved through the lower trapezius tendon and muscle (*) in a Pulvertaft fashion. (B) After completion of the weave, the anastomoses (**) between the Achilles allograft and the lower trapezius tendon can be seen. (Left shoulder).

as one with the shoulder. The arthroscopy portals are closed in a standard fashion and the posterior incision is closed with 2-0 Vicryl subdermal sutures and 3-0 Monocryl to the skin. Standard dressings are applied. The patient is placed in an abduction/external rotation brace which is set at 45° abduction and 30° external rotation to relieve tension on the reconstruction (Fig 8).

Postoperative Protocol

The shoulder remains in the brace for 6 weeks but allowed to perform passive range of motion of the shoulder above the brace. From 6 to 12 weeks, active range of motion is permitted, with avoidance of any activation of the LTT transfer. After 3 months, a computed tomography scan is performed to confirm union of the allograft bone in the humerus and focused activation of the LTT transfer is then begun with physical therapy by coupling shoulder abduction and

external rotation with scapula retraction. Patients generally are allowed to return to sporting activities at 6 months.

Discussion

This arthroscopic-assisted technique describes the use of an Achilles tendon-bone allograft with transosseous inlay fixation for augmentation of a lower trapezius tendon transfer (Table 1). It is a modification of a previously described technique which aims to provide more reliable bone-bone healing and address the issue of guillotine-type failure that can occur at the tendon graft-humeral interface, when a tendon is tubularized and inserted into a transosseous tunnel (Table 2).¹³⁻¹⁵

Elhassan et al.⁸ published results of 33 patients who underwent LTT transfer using Achilles tendon allograft through an open technique with onlay suture anchor fixation of the graft to the humerus. The results of this series were reported at an average follow up of 47 months with patients achieving significant improvements in pain levels and range of motion. Valenti et al.¹⁶ showed similar results in 14 patients who underwent an LTT transfer using semitendinous autograft passed through a transosseous tunnel and fixed with a cortical button. Our technique combines the above approaches by using an Achilles tendon allograft with a bone block passed through a transosseous tunnel at the insertion site of the infraspinatus. This site of reinsertion to a more posterior location probably decreases the tension applied to the transferred tendon and therefore facilitates healing.¹⁵

Onlay versus inlay transosseous fixation has not been biomechanically or clinically compared for LTT transfer, and our understanding of failure

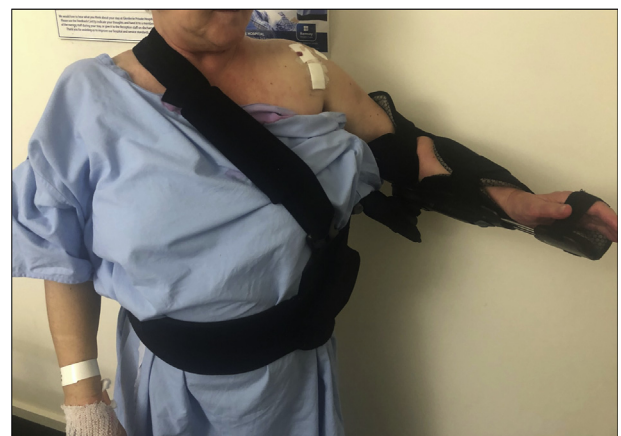

Fig 8. Patient is placed in an abduction (45°) and external rotation (30°) brace for 6 weeks. The elbow is free for active range of motion within the brace.

Table 1. Pearls and Pitfalls

Step	Procedure	Pitfalls	Pearls
1.	Subacromial and subdeltoid preparation	Superior migration of the humeral head Tight working space between humerus and deltoid superior to teres minor Degenerate atrophied infraspinatus	Clear the rotator interval and release anterior capsule to recenter the head. Maintain shoulder in slight abduction and external rotation to clear space above teres minor Dissect and clear to level of scapular below the level of the spine
2.	Lower trapezius harvest	Identification of the lower trapezius Mobilization of lower trapezius from the spine of the scapular, infraspinatus, and middle trapezius	Removal of subcutaneous fat to identify the tendon (oblique oriented fibers) Remain superficial when dissecting along the superior edge of the tendon to avoid damage to the spinal accessory nerve that lies deep
3.	Allograft preparation	Fracture of allograft bone block	Tubularize with a cylinder clamp and drill with maximum drill aperture of 2 mm to avoid fracture
4.	Bone tunnel preparation	Humerus fracture	Use of a flip cutter allows retrograde drilling of 8.5 mm hole that is kept to 20 mm only in depth
5.	Passing of the graft	Bone block fails to dock or remains proud	Maintain firm pressure on the blue FiberWire suture while using a grasper passed through the posterior portal to dock the graft
6.	Attachment of the graft to the lower trapezius	Under tensioning of the graft.	Place shoulder in abduction 45° and external rotation 30°. Attach graft via Pulvertaft weave under maximum tension

mechanisms and the rate arises from studies examining the latissimus dorsi tendon transfer.¹⁷ In the LDT transfer, tubularization of the tendon with transosseous fixation (suture button) was reported to have the strongest fixation in vitro; however, it was shown to have a high failure rate in vivo approaching 46%.^{17,18} With our technique, we believe that this may reduce failures by removing the “killer turn” that a tubularized tendon needs to make as it docks into the transosseous tunnel in the humeral head, and also allowing more reliable bone to bone healing (Table 2).

Table 2. Strengths and Limitations

Strengths	Potentially more reliable bone to bone healing within the greater tuberosity bone tunnel Inherent stability at the bone block to Achilles allograft tendon interface Avoids the "killer turn" phenomenon as the graft enters the greater tuberosity
Limitations	Can be technically challenging to dock the bone block within the bone tunnel Potential for bone block to fragment when pulling the block into the tunnel If incomplete docking of the bone block, there may be prominent that may impede motion

References

- Gerber C, Vinh TS, Hertel R, Hess CW. Latissimus dorsi transfer for the treatment of massive tears of the rotator cuff. A preliminary report. *Clin Orthop Relat Res* 1988;232: 51-61.
- Gerber C, Rahm SA, Catanzaro S, Farshad M, Moor BK. Latissimus dorsi tendon transfer for treatment of irreparable posterosuperior rotator cuff tears: Long-term results at a minimum follow-up of ten years. *J Bone Jt Surg Ser A* 2013;95:1920-1926.
- Valenti P, Kalouche I, Diaz LC, Kaouar A, Kilinc A. Results of latissimus dorsi tendon transfer in primary or salvage reconstruction of irreparable rotator cuff tears. *Orthop Traumatol Surg Res* 2010;96:133-138.
- Nové-Josserand L, Costa P, Liotard JP, Safar JF, Walch G, Zilber S. Results of latissimus dorsi tendon transfer for irreparable cuff tears. *Orthop Traumatol Surg Res* 2009;95: 108-113.
- Costouros JG, Espinosa N, Schmid MR, Gerber C. Teres minor integrity predicts outcome of latissimus dorsi tendon transfer for irreparable rotator cuff tears. *J Shoulder Elb Surg* 2007;16:727-734.
- Gerber C, Maquieira G, Espinosa N. Latissimus dorsi transfer for the treatment of irreparable rotator cuff tears. *J Bone Jt Surg Ser A* 2006;88:113-120.
- Herzberg G, Urien JP, Dimnet J. Potential excursion and relative tension of muscles in the shoulder girdle: Relevance to tendon transfers. *J Shoulder Elb Surg* 1999;8:430-437.
- Elhassan BT, Wagner ER, Werthel JD. Outcome of lower trapezius transfer to reconstruct massive irreparable

- posterior-superior rotator cuff tear. *J Shoulder Elb Surg* 2016;25:1346-1353.
9. Hartzler RU, Barlow JD, An KN, Elhassan BT. Biomechanical effectiveness of different types of tendon transfers to the shoulder for external rotation. *J Shoulder Elb Surg* 2012;21:1370-1376.
 10. Omid R, Heckmann N, Wang L, McGarry MH, Vangsness CT, Lee TQ. Biomechanical comparison between the trapezius transfer and latissimus transfer for irreparable posterosuperior rotator cuff tears. *J Shoulder Elb Surg* 2015;24:1635-1643.
 11. Clouette J, Leroux T, Shanmugaraj A, et al. The lower trapezius transfer: A systematic review of biomechanical data, techniques, and clinical outcomes. *J Shoulder Elb Surg* 2020;29:1505-1512.
 12. Grimberg J, Kany J, Valenti P, Amaravathi R, Ramalingam AT. Arthroscopic-assisted latissimus dorsi tendon transfer for irreparable posterosuperior cuff tears. *Arthrosc J Arthrosc Relat Surg* 2015;31:599-607.e1.
 13. Bergfeld JA, McAllister DR, Parker RD, Valdevit ADC, Kambic HE. A biomechanical comparison of posterior cruciate ligament reconstruction techniques. *Am J Sports Med* 2001;29:129-136.
 14. Elhassan BT, Alentorn-Geli E, Assenmacher AT, Wagner ER. Arthroscopic-assisted lower trapezius tendon transfer for massive irreparable posterior-superior rotator cuff tears: Surgical technique. *Arthrosc Tech* 2016;5:e981-e988.
 15. Kany J, Sekaran P, Grimberg J, et al. Risk of latissimus dorsi tendon rupture after arthroscopic transfer for posterior superior rotator cuff tear: A comparative analysis of 3 humeral head fixation techniques. *J Shoulder Elb Surg* 2020;29:282-290.
 16. Valenti P, Werthel JD. Lower trapezius transfer with semitendinosus tendon augmentation: Indication, technique, results. *Obere Extrem* 2018;13:261-268.
 17. Diop A, Maurel N, Chang VK, Kany J, Duranthon LD, Grimberg J. Tendon fixation in arthroscopic latissimus dorsi transfer for irreparable posterosuperior cuff tears: An in vitro biomechanical comparison of interference screw and suture anchors. *Clin Biomech* 2011;26:904-909.
 18. Kany J, Guinand R, Croutzet P, Valenti P, Werthel JD, Grimberg J. Arthroscopic-assisted latissimus dorsi transfer for subscapularis deficiency. *Eur J Orthop Surg Traumatol* 2016;26:329-334.