

Cartilage Allografts for Aesthetic Nose Surgery: A Viable Option

German Vargas, MD
Rafael Biguria, MD

Background: Illusions in rhinoplasty are a powerful tool yet often overlooked. There are numerous examples of how a specific change in 1 part of the nose will influence the balance of the nose on the entire face. Although cartilage autograft remains the gold standard in structural reconstruction of the nose, for selected cases, allografts can be favored.

Methods: A retrospective cohort study was performed on all patients who underwent cartilage allograft for aesthetic nose surgery from January 2012 to June 2017. All patients were informed of the therapeutic and experimental nature of the localized cartilage allograft use and then consented to the procedure orally and in writing. From January 2012 to June 2017, a total of 105 patients were operated on using cartilage allografts.

Results: Of these 105 patients, follow-up to a year was achieved in 97.

Conclusion: The use of cartilage allograft in our practice has been a useful proven tool that can help manage a patient aesthetic outcome. This gives us the opportunity for cartilage banking and thus, using it, fewer incisions and scars on our patients. (*Plast Reconstr Surg Glob Open* 2018;6:e1859; doi: 10.1097/GOX.0000000000001859; Published online 6 September 2018.)

INTRODUCTION

Rhinoplasty is the surgery to reshape the nose. It enhances facial harmony and the proportions of the nose. It can also correct impaired breathing caused by structural defects in the nose. Rhinoplasty surgery can change nose size in relation to facial balance, nose width at the bridge or in the size and position of the nostrils, nose profile with visible humps or depressions on the bridge, nasal tip that is enlarged or bulbous, drooping, upturned or hooked, nostrils that are large, wide, or upturned, and nasal asymmetry.

Illusions in rhinoplasty are a powerful tool yet often overlooked. There are numerous examples of how a specific change in 1 part of the nose will influence the balance of the nose on the entire face. A plumping graft at

the nasolabial angle will not only blunt the angle, but, create the illusion of cephalic tip rotation.¹

Although cartilage autograft remains the gold standard in structural reconstruction of the nose, for selected cases, allografts can be favored due to their large availability of resolving the continuous growing reconstructive demand and the necessity for a more simple surgical procedure in some patients.² Cartilage preservation was first described and possibly achieved by Prudden³ in 1881.

PATIENTS AND METHODS

Study Design and Patient Population

A retrospective cohort study was performed on all patients who underwent cartilage allograft for aesthetic nose surgery from January 2012 to June 2017. The criterion for inclusion was patients who had an aesthetic rhinoplasty. All patients were informed of the therapeutic and experimental nature of the localized cartilage allograft use and then consented to the procedure orally and in writing. Risk of contracting a viral disease was obtained. Any patient who had previous surgery or any type of treatment to the nose, anyone who did not receive follow-up for up to a year or declined this treatment was excluded from the study.

Cartilage Preparation

All patients from whom cartilage is grafted are tested for viral infections that included hepatitis B, hepatitis C,

Received for publication March 19, 2018; accepted May 14, 2018.

The use of cartilage for aesthetic nose surgery has been long recognized. However, there are times when nose cartilage is insufficient and we are left with the option of grafting cartilage from other places such as conchal and costochondral cartilage. This can leave the patient with other morbidities and scars. We present this new method for using cartilage allograft to avoid these other cartilage grafting methods and still obtain an adequate and lasting aesthetic nose outcome.

Copyright © 2018 The Authors. Published by Wolters Kluwer Health, Inc. on behalf of The American Society of Plastic Surgeons. This is an open-access article distributed under the terms of the Creative Commons Attribution-Non Commercial-No Derivatives License 4.0 (CCBY-NC-ND), where it is permissible to download and share the work provided it is properly cited. The work cannot be changed in any way or used commercially without permission from the journal.

DOI: 10.1097/GOX.0000000000001859

Disclosure: The authors have no financial interest to declare in relation to the content of this article. The Article Processing Charge was paid for by the authors.

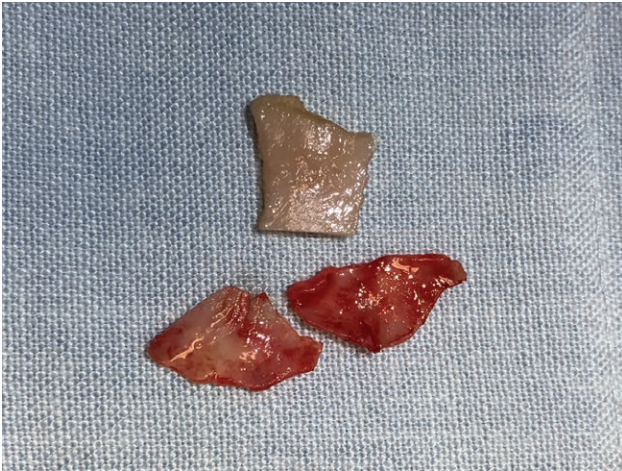

Fig. 1. Allograft cartilage from septal cartilage has a whiter appearance compared with the alar cartilage autograft during surgery.

and HIV before surgery. Cartilage graft is collected in cooperation with the otorhinolaryngology department. After a septal cartilage extraction is done, cartilage is added to a solution containing thiomersal (white merthiolate) in a ratio of 10 to 1. This is later stored in a refrigerated environment at 4 degree Celsius. Cartilages are separated in different bottles depending on the month they were extracted to tell the “age” of it. No cartilage is used after 12 months or before 1 month of preservation to minimize the risk of resorption.

Procedure

At surgery, a closed rhinoplasty is done for aesthetic purposes. To enhance the nose tip, after cephalic alar cartilage resection is done, a sandwich type cartilage graft using allo and autografts is used (Figs. 1, 2). A third-generation cephalosporin is used as antibiotic prophylaxis. Follow-up was done at seventh day postoperative, then every fourth day for 4 times, then at 2, 6, and 12 months postoperatively. Pictures are always taken before surgery and at 12 months postoperatively. No other type of treatment is used for immunosuppression.

RESULTS

From January 2012 to June 2017, a total of 105 patients were operated on using cartilage allografts. Of these 105 patients, follow-up to a year was achieved in 97. Of these 97 patients included in the study, 17.5% or 17 were male and 82.5% or 80 were female. The ages of patients operated on went from 18 to 48, with an average of 27.

Of the 97 patients included in the study, we observed an overall of 4 minor complications (resorption). We did not notice any systemic effects, erythema, or infections due to the allograft. None of the associated complications had a correlation with tobacco use.

In the 4 cases that experienced resorption on the nose tip allograft, we reoperated. No unusual changes other than regular fibrosis from the first surgery were seen.

At 1-year postoperatively, patients could be seen with adequate nose projection using this allograft (Figs. 3–6).

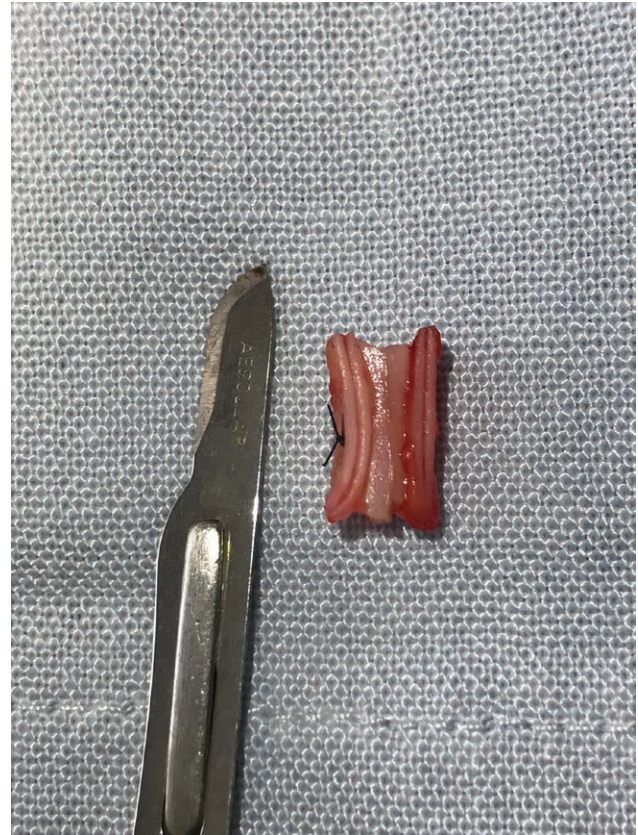

Fig. 2. Cartilage sandwich is prepared using alar cartilage as the outer shell and in the middle the cartilage allograft is located.

DISCUSSION

Previous studies conducted in Ireland by MacConaill⁴ demonstrated that cartilage was preserved in a white merthiolate solution for 2 years for autotransplantation.

Current findings suggest that composite tissue allotransplantation may be the elective option for reconstruction of the extensive defects with associated architectural and functional deficits in the midface region, impossible to approach by conventional surgical techniques.²

Cartilage is different from other tissues due to its lack of vascularization and innervation, having minimal ability for lesion repair.⁵ Histologically, cartilages are composed of cells included in the cartilage matrix consisting of ground substance and collagen and elastin fiber (consistence in those fibers varies in different types of cartilaginous tissues) and enclosed in the perichondrium. Chondrocytes are situated in lacunae of the extracellular matrix.⁶ Avascularity was thought to determine the “immune privilege” of the cartilage, based on the observations that the immune system is limited in recognizing and rejecting cartilage allografts.⁷

The antigenicity of the cartilage is determined by the expression of major histocompatibility complex (MHC) antigens on structural components of cartilaginous tissues. The perichondrium has relatively less immunogenicity, determined by its cellular components. The perichondrium is involved in the initiation of the allorecognition in nonvascularized cartilage allografts.⁶

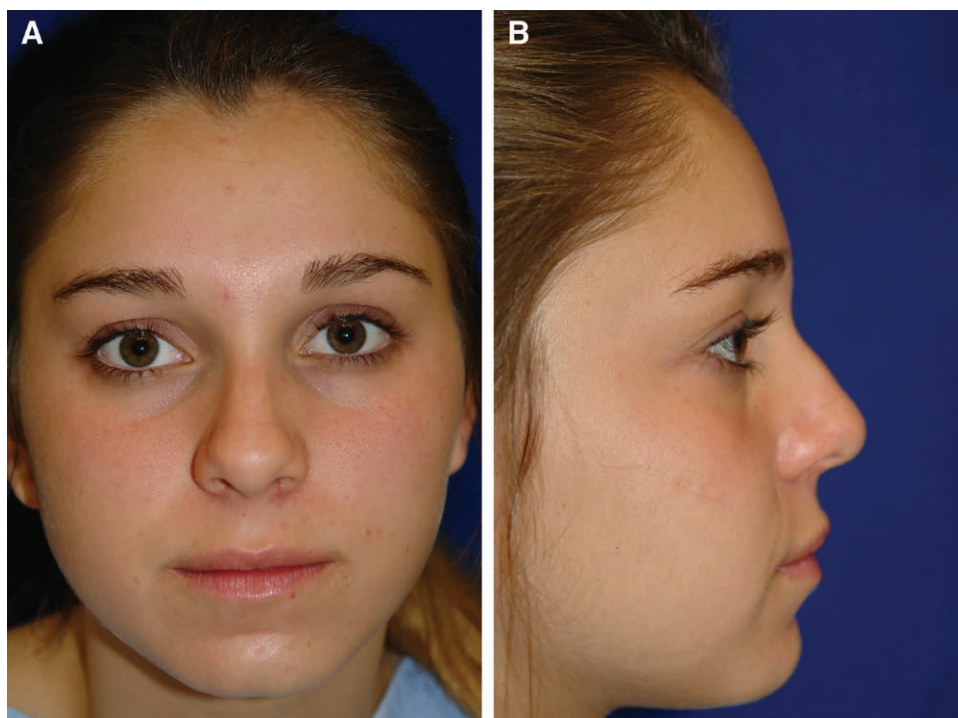


Fig. 3. Preoperative frontal (A) and lateral view (B) of patient 1.

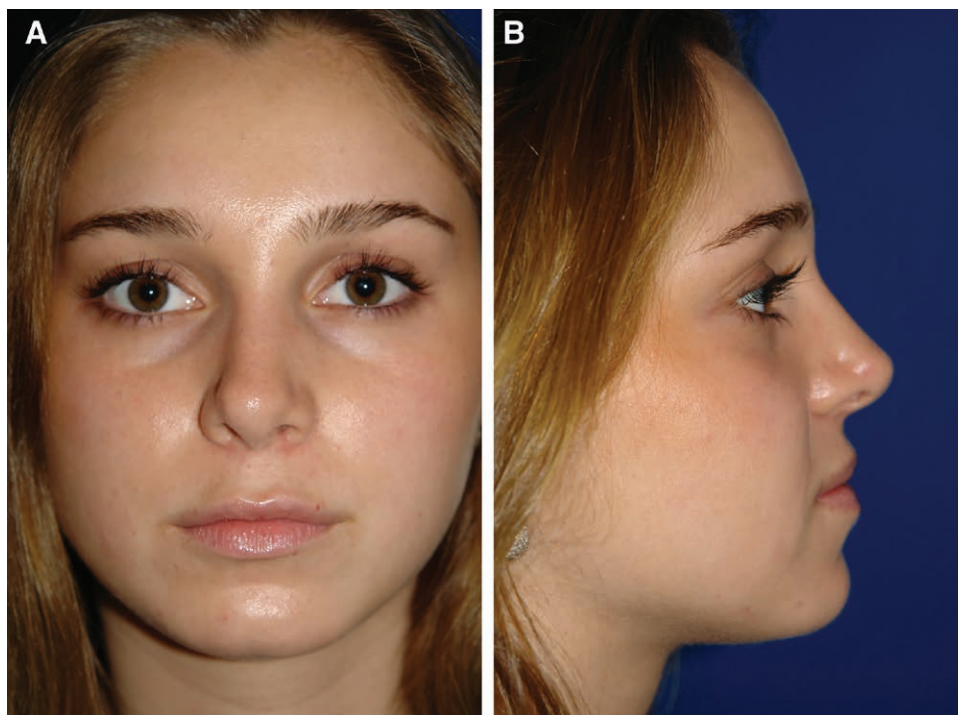

Fig. 4. Postoperative frontal (A) and lateral view (B) of patient 1.

The cartilage matrix does not express antigen MHC, and it does not provoke an immunologic reaction, due to its immunologic inaction. The chondrocytes, on the other hand, express antigens, MHC I and to some extent MHC II, which makes them susceptible to being recognized

and provoking an important immune response. The particularity is their location in the lacunae surrounded by a nonantigenic matrix, which means that if the transplanted cartilage is intact, it is protected from immunologic recognition and graft destruction.⁶ This may be the

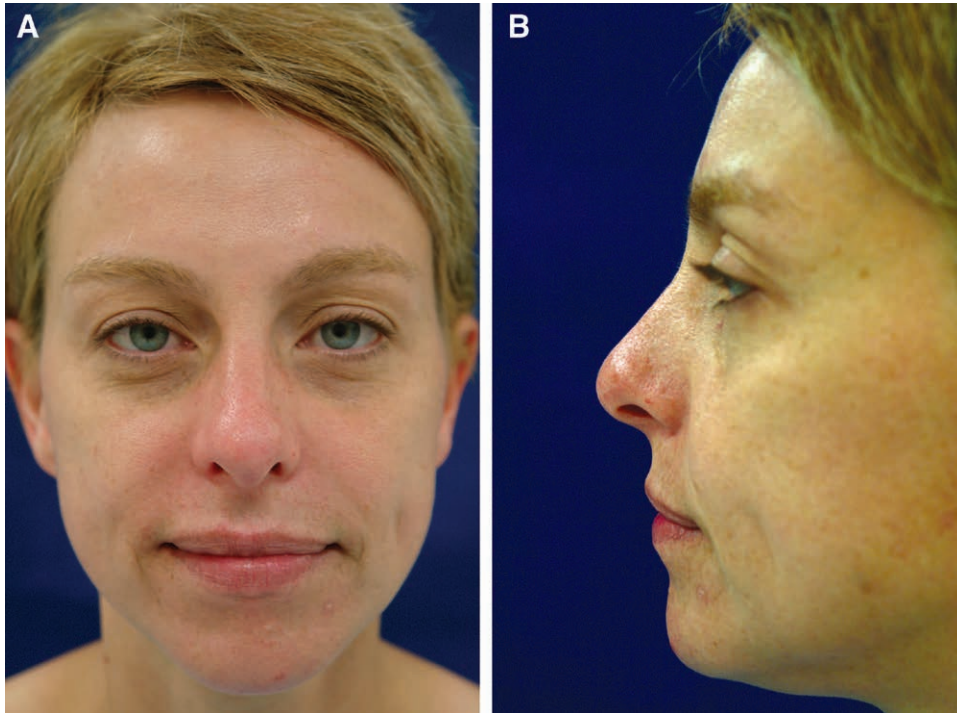

Fig. 5. Preoperative frontal (A) and lateral view (B) of patient 2.

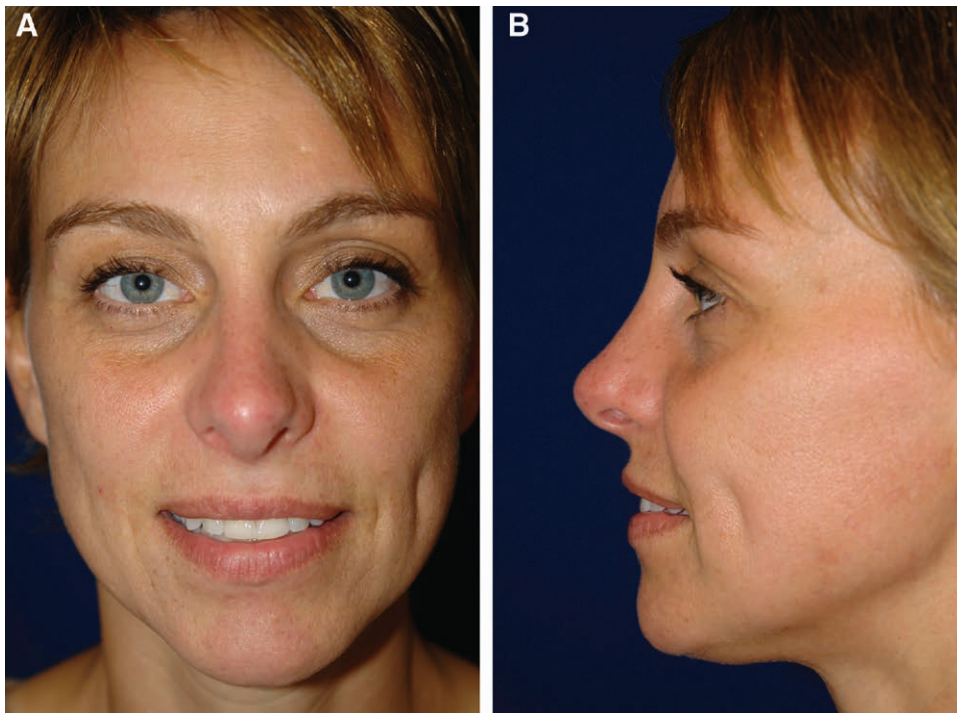

Fig. 6. Postoperative frontal (A) and lateral view (B) of patient 2.

most important factor associated with resorption. It may be possible that the cartilages that suffered resorption may have had less matrix and thus chondrocytes were exposed to the allograft recipient. We did not have any

pathologist analyze the cartilages before surgery, but histopathological findings in both experimental and clinical experience confirmed the low antigenicity of the cartilaginous tissue.⁶

CONCLUSIONS

Autografts will always represent the gold standard for human implantation. Advantages include the lowest rates of extrusion and resorption and perfect immunogenicity. Unfortunately, the use of autografts frequently requires multiple operative fields, prolonged anesthesia time, and additional scars and complications from the donor sites. Nasal reconstruction frequently uses autologous bone and/or cartilage. There are multiple potential donor sites, each with its own characteristics.¹

The use of cartilage allograft in our practice has been a useful proven tool that can help manage a patient aesthetic outcome. This gives us the opportunity for cartilage banking and thus, using it, fewer incisions and scars on our patients.

German Vargas, MD

3a calle A 8–38 zona 10

Edificio Renova

Guatemala, Guatemala

E-mail: gvargas@renova.com.gt

REFERENCES

1. Park SS. Fundamental principles in aesthetic rhinoplasty. *Clin Exp Otorhinolaryngol.* 2011;4:55–66.
2. Grosu-Bularda A, Manea C, Lazarescu L, Lascar Ioan. The role of cartilage and bone allografts in nasal reconstruction. *Romanian J Rhinol.* 2016;6.
3. Prudden TM. Experimental studies on the transplantation of cartilage. *Am J Med Sci.* 1881;82:360.
4. MacConaill MA. Calcospheritic calcification of cartilage. *J Anat.* 1973;115:23–27.
5. Arzi B, DuRaine GD, Lee CA, et al. Cartilage immunoprivilege depends on donor source and lesion location. *Acta Biomater.* 2015;23:72–81.
6. Unadkat J, Sacks JM, Schneeberger S, et al. Relative antigenicity of allograft components and differential rejection. In: Hewitt CW, Lee WPA, Gordon CR, eds. *Transplantation of Composite Tissue Allografts.* Springer; 2008:55–69.
7. Revell CM, Athanasiou KA. Success rates and immunologic responses of autogenic, allogenic, and xenogenic treatments to repair articular cartilage defects. *Tissue Eng Part B Rev.* 2009;15:1–15.