



Contents lists available at ScienceDirect

## Respiratory Medicine Case Reports

journal homepage: <http://www.elsevier.com/locate/rmcr>

## Case report

## Repeated treatment with gefitinib and alectinib in a patient with multiple EGFR-mutant and ALK-mutant lung adenocarcinomas: A case report

Takafumi Yorozuya<sup>a,\*</sup>, Yutaro Nagano<sup>b</sup>, Hirofumi Chiba<sup>c</sup>, Yui Imai<sup>b</sup>, Kento Yasuda<sup>b</sup>, Yuta Sudo<sup>c</sup>, Tetsuya Taya<sup>b</sup>, Makoto Shioya<sup>b</sup>

<sup>a</sup> Department of Respiratory Medicine, Sapporo Kosei General Hospital, Kita3 Higashi8-5, Chuo-ku, Sapporo, 060-0033, Japan

<sup>b</sup> Department of Respiratory Medicine, Otaru General Hospital, 1-1-1, Wakamatsu, Otaru, 047-8550, Japan

<sup>c</sup> Department of Respiratory Medicine and Allergology, Sapporo Medical University School of Medicine, minami1-nishi16, Chuo-ku, Sapporo, 060-8543, Japan

## ARTICLE INFO

## Keywords:

Epidermal growth factor receptor  
Anaplastic lymphoma kinase  
Multiple lung cancers  
Co-alternations  
Repeated treatment

## ABSTRACT

Multiple EGFR-mutant and ALK-mutant lung cancers are rare, and standard treatment has not been established because of the small number of cases. A 79-year-old man was found to harbor nodular shadows in right S1, right S5, and left S3. He was surgically diagnosed with stage IIB (pT3N0M0) EGFR G719X-mutant lung adenocarcinoma in left S3 and stage IA1 (pT1aN0M0) ALK-mutant lung adenocarcinoma in right S5. Owing to the relapse of the EGFR-mutant adenocarcinoma, gefitinib treatment was commenced 3 months postoperatively. The tumor shrank temporarily; however, the nodular shadow in the right S1 and #3a lymph nodes were found to increase in size. He was diagnosed with adenosquamous carcinoma in right S1 and relapsing ALK-mutant adenocarcinoma in #3a lymph node. Gefitinib treatment was continued, but due to a renewed increase in the size of the #3a lymph node, the drug was changed to alectinib 16 months postoperatively. Subsequently, the EGFR-mutant adenocarcinomas were found to increase in left S1 despite the decrease in the #3a lymph node size. Nineteen months after the first surgery, the treatment was changed to gefitinib, and repeated treatment with this drug and alectinib administered every 2 months was continued. This approach enabled 39 months of progression-free survival, and no serious adverse events were observed.

## 1. Introduction

Epidermal growth factor receptor (EGFR) mutation occurs in 40%–55% of Asian patients with lung adenocarcinoma [1], whereas anaplastic lymphoma kinase (ALK) rearrangements occur in 3%–5% of Asian patients with lung adenocarcinomas; G719X is a rare mutation comprising only 2%–3% of all EGFR mutations. Standard treatment for the cases with multiple EGFR-mutant and ALK-mutant lung cancers has not been established because of the small number of cases. We herein report the rare case of a patient with multiple EGFR-mutant and ALK-mutant lung adenocarcinomas who achieved long-term progression-free survival (PFS) following repeated treatment with gefitinib and alectinib.

## 2. Case report

A 79-year-old man who was a smoker with a Brinkman index of 900 was found to harbor nodular shadows in right S1, right S5, and left S3 (Fig. 1). The diagnosis of all three lesions could not be confirmed by transbronchial biopsy. Therefore, we decided to continue patient follow-up because it was a pure ground glass nodule for right S1, and confirmed the diagnosis of the other two lesions by surgical biopsy. Although the possibility of contralateral lung metastasis was also considered, we decided to perform surgical biopsy of both lungs after consulting with the patient, considering that the two lesions may have different tumors. Two months later, he underwent partial upper left lobe resection and was diagnosed with stage IIB (pT3N0M0) EGFR G719X-mutant lung adenocarcinoma. The next month, he underwent right middle-lobe resection and was diagnosed with stage IA1 (pT1aN0M0) ALK-mutant lung adenocarcinoma.

**Abbreviations:** ALK, Anaplastic lymphoma kinase; EGFR, Epidermal growth factor receptor; HRCT, High resolution computed tomography; LN, Lymph node; PFS, Progression-free survival.

\* Corresponding author.

E-mail address: [taka0703@sapmed.ac.jp](mailto:taka0703@sapmed.ac.jp) (T. Yorozuya).

<https://doi.org/10.1016/j.rmcr.2021.101378>

Received 20 November 2020; Received in revised form 4 February 2021; Accepted 1 March 2021

Available online 4 March 2021

2213-0071/© 2021 The Author(s).

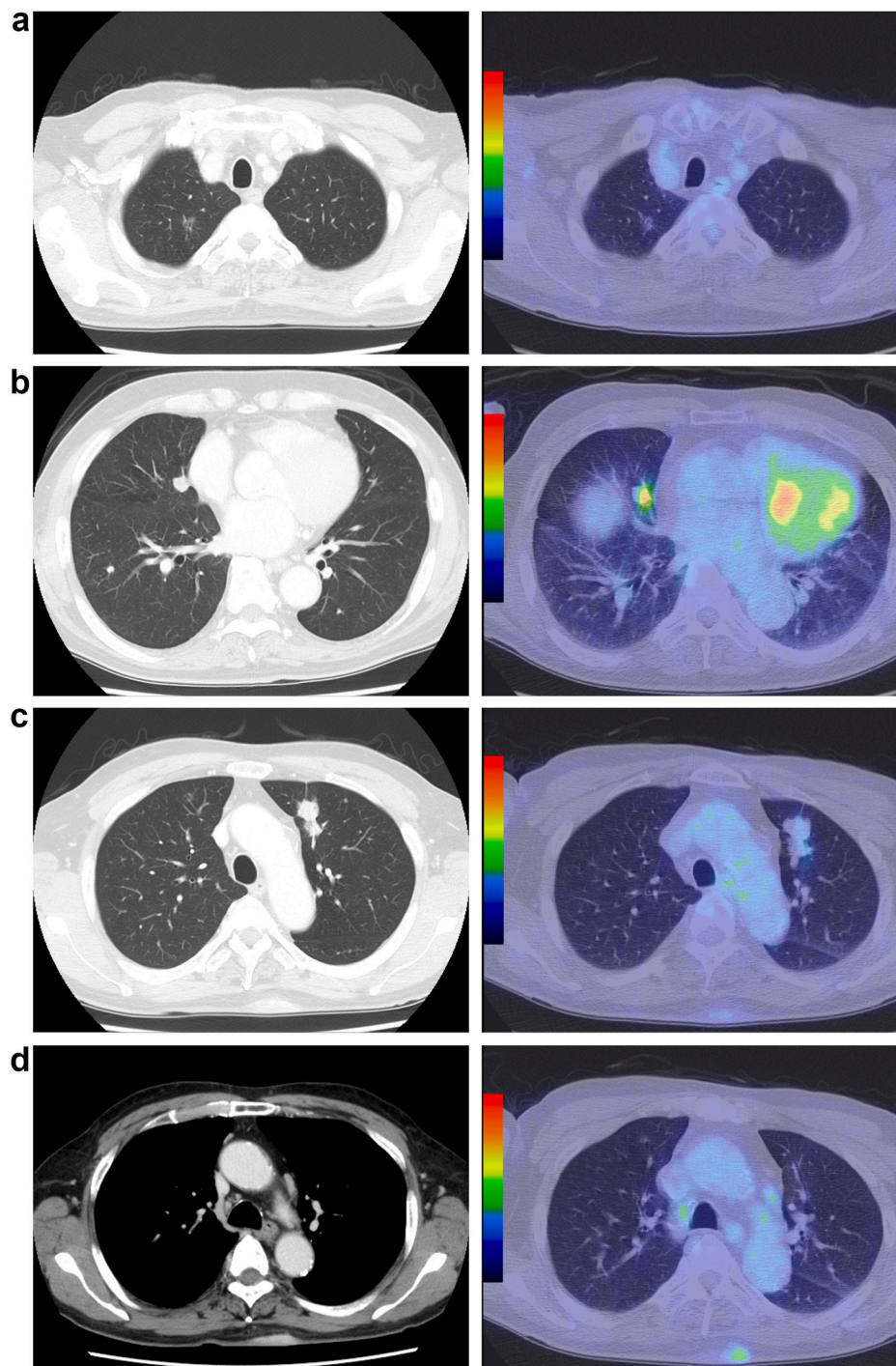
Published by Elsevier Ltd.

This is an open access article under the CC BY-NC-ND license

(<http://creativecommons.org/licenses/by-nc-nd/4.0/>).

Initially, postoperative adjuvant chemotherapy with cytotoxic anti-cancer drugs was planned; however, multiple nodular shadows appeared in left S1, and transbronchial biopsy was not possible. Clinically, EGFR-mutant adenocarcinoma was suspected because the patient had a 3 mm accessory nodule near the main tumor in the resected left S3 and the lesion was in the same left upper lobe. Gefitinib was started 3 months after the first surgery, and the tumors were found to be decreasing. Eleven months after the first surgery, the nodular shadow in right S1 and #3a lymph node (LN) were found to be increasing in size (Fig. 2). For #3a LN, we decided to perform a surgical biopsy because we were unable to determine the tumor from which it had metastasized. The surgical lung biopsy led to the diagnosis of adenosquamous carcinoma in right S1 and relapsing ALK-mutant adenocarcinoma in #3a LN.

Gefitinib treatment was continued as it was, but due to an increase in the #3a LN size again (Fig. 3), it was changed to alectinib from 16 months after the first surgery. Nineteen months after the first surgery, the multiple nodular shadows in left S1 were increased despite a decrease in the #3a LN size. The treatment was changed to gefitinib, and the multiple nodular shadows in left S1 were reduced. Then, repeated treatment with gefitinib and alectinib administered every 2 months was continued. At the last follow-up, the PFS duration after the initiation of gefitinib was 39 months, and no lesions suggestive of a new appearance of other lesions, including adenosquamous carcinoma, were observed.



**Fig. 1.** Image findings before the first surgery.

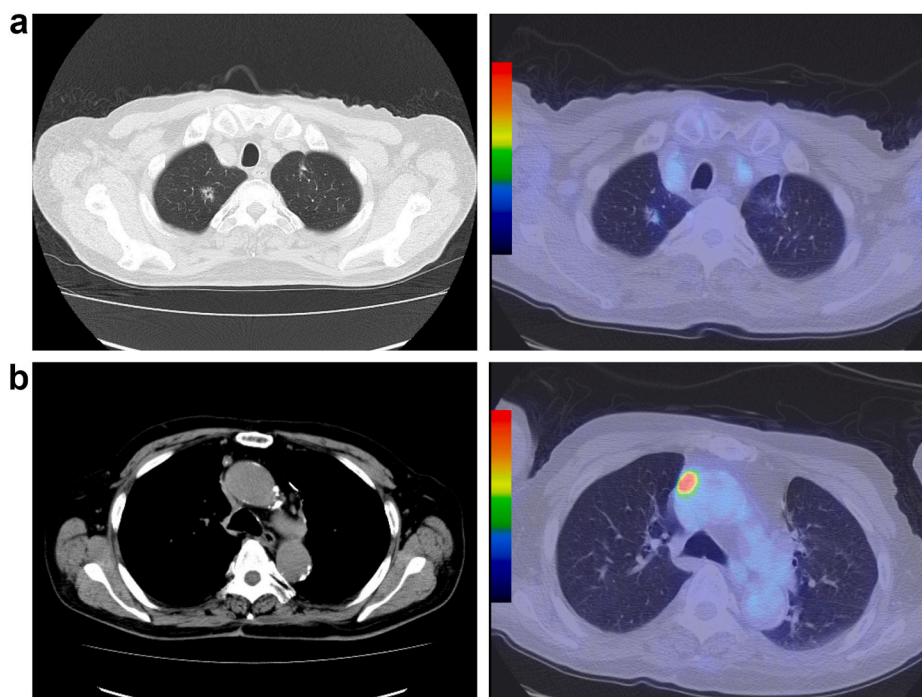
(a) The chest high resolution computed tomography (HRCT) scan showed a ground glass nodule in right S1. F18 fluorodeoxyglucose positron emission tomography (FDG-PET) scan showed a low uptake.

(b) HRCT scan showed a  $10 \times 10 \text{ mm}^2$  nodular shadow in right S5. FDG-PET scan showed a high uptake with a maximal standardized uptake value of 4.2.

(c) HRCT scan showed a  $30 \times 15 \text{ mm}^2$  nodular shadow in left S3. FDG-PET scan showed a low uptake.

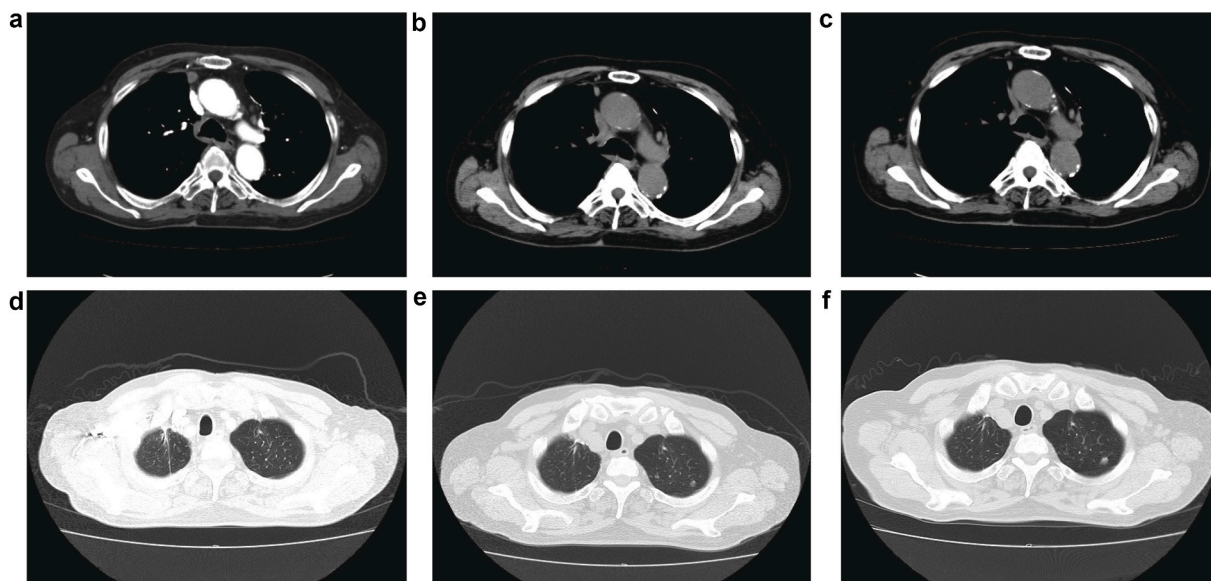
(d) The #3a lymph node (LN) was small and flat, with no apparent swelling. FDG-PET scan showed a low uptake.





**Fig. 2.** Image findings before the third surgery

- (a) 11 months after the first surgery, the nodular shadow in right S1 was found to be increased. FDG-PET scan showed a low uptake.
- (b) The #3a LN size was found to be increased. FDG-PET scan showed a high uptake with a maximal standardized uptake value of 15.1.



**Fig. 3.** The course of EGFR-mutant and ALK-mutant adenocarcinomas from before starting alectinib to the first year of repeated therapy

- (a) 16 months after the first surgery, the #3a LN size was found to be increased again.
- (b) 18 months after the first surgery, treatment with alectinib decreased the #3 LN size.
- (c) 30 months after the first surgery, the #3a LN size indicated "stable disease."
- (d) 16 months after the first surgery, the nodular shadows in left S1 were not apparent.
- (e) 18 months after the first surgery, the nodular shadows in left S1 were found to be increased.
- (f) 30 months after the first surgery, the nodular shadows in left S1 indicated "stable disease."

### 3. Discussion

Chemotherapy for patients with multiple EGFR-mutant and ALK-mutant lung cancers has not been established because of the small number of cases. Fan et al. reported that 4.71% of multifocal lung adenocarcinomas have EGFR/ALK co-alterations [2]. However, these

were surgical cases and few treatment cases have been reported. To date, two treatment cases similar to the current case have been reported [3,4]. Tsunezuka et al. reported a case in which EGFR-mutant and ALK-mutant double cancer was diagnosed by surgical resection [3]. Ten months after administering adjuvant chemotherapy, alectinib was administered owing to the relapse of ALK-mutant adenocarcinoma. He mentioned that

in previous reported cases, it was unclear whether two tumors each with one genetic alteration developed simultaneously or a single tumor acquired both oncogenic drivers during its development [5–7]. In the present case, EGFR mutations and ALK rearrangements were detected in different surgically resected tumors rather than in the same tumor. Because each of these tumors has a different oncogenic driver, it is believed that the development process is different, and it might be impossible to control tumors with EGFR-TKI or ALK-TKI alone. Zhao et al. mentioned that the response rate of TKIs in double-positive patients was 63.6% for EGFR-TKIs and 55.6% for ALK-TKIs. They have a lower response rate than that of a single-mutant patient [8]. Yokoyama et al. mentioned two possible mechanisms for low response rates [9]. The ALK rearrangement may be associated with resistance to EGFR-TKI, and the EGFR mutation and ALK rearrangement within the same cell may be heterogeneous and affect therapeutic effect. However, these discussions are about the concomitant mutation in the same cell. In the present case, ALK-mutant adenocarcinoma progresses when EGFR-TKI is used, and EGFR-mutant adenocarcinoma progresses when ALK-TKI is used. Because there is a concern that the concomitant use of TKI may increase the risk of adverse events, such as drug-induced lung injury, repeated therapy was selected. To the best of our knowledge, no similar cases have been reported. Therefore, it was necessary to discuss the treatment cycle interval. Alectinib treatment was started 16 months after the first surgery, and multiple nodular shadows of left S1 had increased 19 months after the first surgery. Hence, we judged that tumors that were not treatment-targeted increased in 3 months, and the cycle interval was set to 2 months. This is the first case showing the benefit of repeated therapy with two TKIs every 2 months.

In conclusion, in a patient with multiple EGFR-mutant and ALK-mutant lung cancers, repeated treatment with gefitinib and alectinib achieved a long-term PFS of 39 months without serious adverse events.

### Funding

This research did not receive any specific grant from funding agencies in the public, commercial, or not-for-profit sectors.

### Ethical considerations

All procedures done were in accordance with The Code of Ethics of the World Medical Association (Declaration of Helsinki). Written informed consent was obtained for participation in the study. The privacy rights of human subjects were observed. Since, this is a case report, ethics approval is not applicable in this case.

### Data availability statement

The datasets generated during and/or analyzed during the current study are available from the corresponding author on reasonable request.

### Author contributions

Conceptualization - T.Yorozyua, Y.Nagano, H.Chiba.  
Data curation - T.Yorozyua, Y.Nagano, Y.Imai, K.Yasuda, Y.Sudo, T.

Taya.

Formal analysis - T.Yorozyua, Y.Nagano, H.Chiba, Y.Sudo, T.Taya, M.Shioya.

Funding acquisition - None.

Investigation - T.Yorozyua, Y.Nagano, Y.Imai, K.Yasuda, Y.Sudo, T.Taya.

Methodology - T.Yorozyua, Y.Nagano, H.Chiba.

Project administration - H.Chiba, M.Shioya.

Resources - T.Yorozyua, Y.Nagano, H.Chiba, Y.Imai, K.Yasuda, Y.Sudo, T.Taya, M.Shioya.

Software - None.

Supervision - H.Chiba, M.Shioya.

Validation - T.Yorozyua, Y.Nagano, H.Chiba, Y.Sudo, T.Taya, M.Shioya.

Visualization - T.Yorozyua, Y.Nagano, H.Chiba, Y.Sudo, T.Taya, M.Shioya.

Roles/Writing - original draft - T.Yorozyua, Y.Nagano, Y.Sudo.

Writing - review & editing – T.Yorozyua, Y.Nagano, H.Chiba, Y.Imai, K.Yasuda, Y.Sudo, T.Taya, M.Shioya.

### Declaration of competing interest

The authors declare that they have no known competing financial interests or personal relationships that could have appeared to influence the work reported in this paper.

### Acknowledgments

The authors would like to thank Enago ([www.enago.jp](http://www.enago.jp)) for the English language review.

### References

- [1] K. Li, M. Yang, N. Liang, S. Li, Determining EGFR-TKI sensitivity of G719X and other uncommon EGFR mutations in non-small cell lung cancer: perplexity and solution (Review), *Oncol. Rep.* 37 (2017) 1347–1358.
- [2] J. Fan, X. Dai, Z. Wang, et al., Concomitant EGFR mutation and EML4-ALK rearrangement in lung adenocarcinoma is more frequent in multifocal lesions, *Clin. Lung Canc.* 20 (2019) e517–e30.
- [3] Y. Tsunozuka, N. Tanaka, H. Fujimori, et al., The case of double primary lung adenocarcinomas with an EGFR mutation and ALK translocation successfully treated with alectinib at the post-surgical recurrence, *J. Med. Invest.* 64 (2017) 305–307.
- [4] J. Fan, J. Wu, B. Huang, et al., Concomitant EGFR mutation and ALK rearrangement in multifocal lung adenocarcinoma: a case report, *Diagn. Pathol.* 15 (2020) 42.
- [5] G. Toyokawa, K. Taguchi, T. Ohba, et al., First case of combined small-cell lung cancer with adenocarcinoma harboring EML4-ALK fusion and an exon 19 EGFR mutation in each histological component, *J. Thorac. Oncol.* 7 (2012) e39–41.
- [6] A. Miyanaga, K. Shimizu, R. Noro, et al., Activity of EGFR-tyrosine kinase and ALK inhibitors for EML4-ALK-rearranged non-small-cell lung cancer harbored coexisting EGFR mutation, *BMC Canc.* 13 (2013) 262.
- [7] R. Chiari, S. Duranti, V. Ludovini, et al., Long-term response to gefitinib and crizotinib in lung adenocarcinoma harboring both epidermal growth factor receptor mutation and EML4-ALK fusion gene, *J. Clin. Oncol.* 32 (2014) e30–e32.
- [8] N. Zhao, S.Y. Zheng, J.J. Yang, et al., Lung adenocarcinoma harboring concomitant EGFR mutation and EML4-ALK fusion that benefits from three kinds of tyrosine kinase inhibitors: a case report and literature review, *Clin. Lung Canc.* 16 (2015) e5–e9.
- [9] A. Yokoyama, A. Tamura, K. Miyakawa, et al., Pulmonary adenocarcinoma, harboring both an EGFR mutation and ALK rearrangement, presenting a stable disease to erlotinib and a partial response to alectinib, *Intern. Med.* 57 (2018) 2377–2382.