



# White matter network disruption and cognitive correlates underlying impaired memory awareness in mild cognitive impairment

Yu-Ling Chang<sup>a,b,c,d,1,\*</sup>, Ruei-Yi Chao<sup>a</sup>, Yung-Chin Hsu<sup>e</sup>, Ta-Fu Chen<sup>c</sup>,  
Wen-Yih Isaac Tseng<sup>b,e,f,g</sup>

<sup>a</sup> Department of Psychology, College of Science, National Taiwan University, Taipei 10617, Taiwan

<sup>b</sup> Neurobiology and Cognitive Science Center, National Taiwan University, Taipei 10617, Taiwan

<sup>c</sup> Department of Neurology, National Taiwan University Hospital, College of Medicine, National Taiwan University, Taipei 10048, Taiwan

<sup>d</sup> Center for Artificial Intelligence and Advanced Robotics, National Taiwan University, Taipei 10617, Taiwan

<sup>e</sup> Graduate Institute of Medical Device and Imaging, College of Medicine, National Taiwan University, Taipei 10051, Taiwan

<sup>f</sup> Graduate Institute of Brain and Mind Sciences, College of Medicine, National Taiwan University, Taipei 10051, Taiwan

<sup>g</sup> Department of Medical Imaging, National Taiwan University Hospital, College of Medicine, National Taiwan University, Taipei 10048, Taiwan

## ARTICLE INFO

### Keywords:

Anosognosia  
Diffusion MRI  
Disconnection syndrome  
Executive function  
Memory awareness  
Mild cognitive impairment

## ABSTRACT

Decreased awareness of memory declines in mild cognitive impairment (MCI) has been linked to structural or functional changes in a wide gray matter network; however, the underlying white matter pathway correlations for the memory awareness deficits remain unknown. Moreover, consistent findings have not been obtained regarding the cognitive basis of disturbed awareness of memory declines in MCI. Due to the methodological drawbacks (e.g., correlational analysis without controlling confounders related to clinical status, a problem related to the representativeness of the control group) of previous studies on the aforementioned topic, further investigation is required. To address the research gaps, this study investigated white matter microstructural integrity and the cognitive correlates of memory awareness in 87 older adults with or without mild cognitive impairment (MCI). The patients with MCI and healthy controls (HCs) were divided into two subgroups, namely those with normal awareness (NA) and poor awareness (PA) for memory deficit, according to the discrepancy scores calculated from the differences between subjective and objective memory evaluations. Only the results for HCs with NA (HC-NA) were compared with those for the two MCI groups (i.e., MCI-NA and MCI-PA). The three groups were matched on demographic and clinical variables. An advanced diffusion imaging technique—diffusion spectrum imaging—was used to investigate the integrity of the white matter tract. The results revealed that although the HC-NA group outperformed the two MCI groups on several cognitive tests, the two MCI groups exhibited comparable performance across different neuropsychological tests, except for the test on reasoning ability. Compared with the other two groups, the MCI-PA group exhibited lower integrity in bilateral frontal-striatal fibers, left anterior thalamocortical radiations, and callosal fibers connecting bilateral inferior parietal regions. These results could not be explained by gray matter morphometric differences. Overall, the results indicated that mnemonic anosognosia was not sufficient to explain the memory awareness deficits observed in the patients with MCI. Our brain imaging findings also support the concept of anosognosia for memory deficit as a disconnection syndrome in MCI.

## 1. Introduction

A diminished ability to recognize the presence or perceive the severity of cognitive deficits, which is referred to as anosognosia, is a common feature in Alzheimer's disease (AD) (Lenzoni et al., 2020;

Morris and Mograbi, 2013); however, large variability exists in the incidence and prevalence of anosognosia of memory deficits (Mondragon et al., 2019). Disturbed awareness of cognitive changes in the context of pathological aging negatively influences patients' safety and health outcomes, their decision-making capacity, and caregiver quality

\* Corresponding author at: Department of Psychology, College of Science, National Taiwan University, No. 1, Sec. 4, Roosevelt Rd, Taipei 10617, Taiwan.

E-mail address: [ychang@ntu.edu.tw](mailto:ychang@ntu.edu.tw) (Y.-L. Chang).

<sup>1</sup> ORCID: 0000-0003-2851-3652.

<https://doi.org/10.1016/j.nicl.2021.102626>

Received 10 November 2020; Received in revised form 3 February 2021; Accepted 5 March 2021

Available online 13 March 2021

2213-1582/© 2021 The Author(s).

Published by Elsevier Inc.

This is an open access article under the CC BY-NC-ND license

(<http://creativecommons.org/licenses/by-nc-nd/4.0/>).

of life (Al-Aloucy et al., 2011; Cosentino et al., 2011; DeFeis et al., 2019). Given that mild cognitive impairment (MCI) may represent the prodromal stage of dementia, investigating the similarities in the characteristics of MCI and dementia may be crucial to understand the evolution of cognitive deficits during the dementing process and to evaluate dementia risks. However, mixed results have been obtained regarding whether disturbed awareness of cognitive changes can be identified in MCI. Some studies have provided evidence that aspects of decreased awareness of memory difficulty can be observed in patients with amnesic MCI, and anosognosia has been identified as an independent predictor of conversion from MCI into AD (Gerretsen et al., 2017; Spalletta et al., 2014). However, a meta-analysis indicated that patients with MCI are as reliable as healthy older adults for self-reporting cognitive dysfunction (Piras et al., 2016). These conflicting findings warrant further investigation. An important point is that many studies that have investigated anosognosia of memory deficits in MCI have tended to examine patients with MCI as a homogenous group without considering the marked variations in clinically observed awareness of memory loss across individuals (Chao et al., 2021; Mondragón et al., 2019; Piras et al., 2016). Therefore, examining the underpinnings of the differences between the neuropsychological presentations and neural mechanisms of MCI with and without anosognosia is crucial.

The neuropsychological correlates of memory awareness have been widely investigated, and the complexity of the concept of self-awareness has been highlighted in different models. For example, the Cognitive Awareness Model (CAM) provides a neurocognitive mechanism to account for heterogeneous bases of awareness deficits (Morris and Mograbi, 2013). The CAM posits that an executive anosognosia can occur when the comparator mechanism fails to detect memory errors or does not perceive errors as affectively salient. By contrast, a mnemonic anosognosia can arise because individuals fail to update or consolidate their representation of the self's ability over time (Mograbi et al., 2009). Similar to AD literature (Gallo et al., 2012; Lenzone et al., 2020), several studies conducted among patients with MCI have identified the major role of memory deficits in decreased metamemory (Perrotin et al., 2007; Piras et al., 2016; Ryals et al., 2019). These studies have postulated that the awareness deficits in MCI patients are a product of "forgetting that one forgets." In contrast to the notion of mnemonic anosognosia, some studies have failed to find an association between memory and metamemory in patients with AD (Bertrand et al., 2019; Cosentino et al., 2007). Other studies have highlighted the effect of executive function, which serves as a comparator mechanism, on memory awareness in MCI (Chao et al., 2021; Senturk et al., 2017); however, some studies have failed to identify an association between executive function and memory awareness in patients with MCI (Perrotin et al., 2007; Piras et al., 2016). Overall, although considerable variability has been observed across studies, most current evidence supports a relationship between cognitive impairment and decreased memory awareness in MCI. Similar to AD, the anosognosia in MCI may reflect, at least in part, a failure to update one's autobiographical knowledge (Clare et al., 2011) regarding impaired cognitive abilities due to impaired memory ability, executive function, or a combination of both.

Although the cognitive mechanisms of anosognosia have been widely studied, the neural basis of metacognitive deficits has not been investigated in detail. The available evidence links impaired self-awareness of memory deficits in MCI with structural, metabolism, or perfusion abnormalities in a range of brain networks, including the hippocampus, prefrontal, temporopolar, and parietal regions (Mondragon et al., 2019; Theriault et al., 2018; Vannini et al., 2017; Zamboni et al., 2013). Functional connectivity studies have also revealed that anosognosia is associated with attenuated functional connectivity between the posterior cingulate cortex and prefrontal as well as bilateral inferior parietal lobes in amnesic MCI compared with healthy controls (HCs) (Berlingeri et al., 2015; Vannini et al., 2017). Overall, the widespread involvement of brain regions suggests the existence of a complex cortico-subcortical circuit underlying awareness of memory function.

The aforementioned results obtained through functional imaging provide further evidence supporting the hypothesis that anosognosia may be associated with functional metabolic changes and may represent functional disconnection between brain regions supporting self-referential processing and memory processing (Vannini et al., 2017). An interesting question is whether this wide network disconnection can be observed not only functionally but also anatomically. Diffusion imaging can be used to examine the strength of white matter microstructure connectivity in the brain. However, although several studies have focused on the anosognosia of physical body function (e.g., awareness of hemiplegia) and white matter connectivity in stroke patients (Monai et al., 2020), to the best of our knowledge, only one study (Baird et al., 2015) has investigated the white matter correlates of memory awareness for an in-session memory task. That study focused on young adults (mean age = 21.5 years) and found that the ability to make accurate metamemory judgments is associated with increased diffusion anisotropy in tracts extending into the right inferior parietal lobule in the region near the angular gyrus (Baird et al., 2015). No study has yet examined the memory awareness ability and white matter connectivity in populations with MCI.

Previous studies that have examined the neural correlates of memory anosognosia in populations with MCI or AD have essentially treated the diagnostic group as a single entity and have reported correlations between variables representing brain function or morphology. However, inferring causation from correlational studies is difficult because the brain-behavior relationship may result from a third variable. For example, increases in anosognosia are often accompanied by increased severity in the cognitive impairments of patients with MCI or AD, which could be a confounder in the correlation observed between the anosognosia and neural substrates or cognitive variables. Consequently, the associations observed in the aforementioned studies may reflect a diagnosis or disease effect rather than a true association related to memory awareness functioning. Thus, characterizing the intergroup variability in memory awareness and other clinical characteristics is crucial before examining the behavior-brain relationship. Furthermore, studies have often assumed that HCs represent a group of participants with good memory awareness, and the cognitive performance or brain measurements of the HC group has often been compared with that of diagnostic groups. However, some studies have observed a degree of metacognitive ability among cognitively unimpaired healthy adults, even young adults (Baird et al., 2015; Chao et al., 2021; Selmeczy and Dobbins, 2017). Accordingly, a rigorous definition of the control group is crucial when investigating the intergroup variability of patient groups.

The present study addressed the aforementioned research gaps and comprised two parts. First, we examined the similarities and differences in the neuropsychological profiles of two MCI subgroups (i.e., those with normal and poor memory awareness) and an HC group with normal awareness (NA). With regard to the neuropsychological profiles, we focused on memory and executive functions. Second, the white matter network associated with anosognosia for memory function in MCI was mapped. The present study investigated four tract groups of interest: (1) hippocampus-related limbic circuit fibers, (2) association fibers connecting the frontal region to the inferior parietal and temporal regions, (3) frontal-subcortical projection fibers, and (4) callosal fibers connecting anterior and posterior brain regions. Notably, these fiber tracts were selected on the basis of the wide gray matter network identified in the aforementioned structural and functional imaging studies of memory anosognosia. The identified gray matter network includes the hippocampus, prefrontal, temporopolar, and parietal regions. The callosal fibers connecting to anterior and posterior brain regions were also included in the present study because of their roles in transferring relevant information between bilateral target end zones (i.e., prefrontal and parietal regions) (van der Knaap and van der Ham, 2011). Variations in white matter microstructure are hypothesized to underlie group differences in anosognosia for memory impairment in patients with MCI.

A compromised connection related to the medial and lateral temporal systems (e.g., hippocampus-related fibers and uncinate fasciculus) is expected to be observed if processes of personal memories (Andrews-Hanna et al., 2010) play an essential role in accounting for anosognosia in MCI. By contrast, if the involvement of the executive control system is crucial, white matter fibers in the frontal regions, including frontal-subcortical projection fibers, are expected to account for anosognosia for the memory impairment observed in MCI. MCI with impaired memory awareness has been hypothesized to be associated with compromised white matter integrity in tracts involving parietal regions, particularly the inferior parietal lobule, because these regions are vital regions associated with metamemory (Chua et al., 2009; Elman et al., 2012) and play important roles in coding information pertaining to memory or directing attention to memory representations (Cabeza et al., 2012, 2008).

## 2. Materials and methods

### 2.1. Participants

This study involved 87 older adults without dementia, of whom 46 were diagnosed with MCI and 41 were age- and education-matched cognitively unimpaired HCs. All participants were right-handed. The HC participants were recruited from local communities, and the participants with MCI were recruited from the memory clinics of local hospitals. Potential participants were thoroughly screened through interviews to exclude individuals with a current or past diagnosis of a neurological or psychiatric disorder, a known head injury with loss of consciousness, contra-indications for MRI scanning, alcohol or substance abuse, or extensive white matter hyperintensities on structural MRI. The present study was approved by the Ethics Committee and Institutional Review Board of National Taiwan University Hospital. Before conducting the experimental procedures, written informed consent was obtained from all the participants.

The participants were classified as having MCI according to criteria adapted from Petersen and Morris (Petersen and Morris, 2005). The criteria were the following: (1) normal activities of daily living, (2) absence of dementia, and (3) mild quantifiable cognitive impairment in one or more domains. The criterion of appearance of subjective or informant-reported memory decline was not required for enrollment into the present study. The criterion of objective cognitive impairment was operationally defined as performance  $\geq 1$  standard deviation lower than the age-appropriate norm on at least two measures in at least one cognitive domain. This definition was adopted to balance the reliability and rigor of MCI diagnoses with the sensitive detection of mild impairments in cognition (Chang et al., 2015; Jak et al., 2009a, 2009b; Loewenstein et al., 2009). According to the aforementioned criteria, the MCI sample in the present study comprised 21 participants with impairment in only episodic memory [i.e., single-domain amnesic MCI (S-aMCI)], 23 participants with impairments in their memory and other cognitive function domains [i.e., multidomain amnesic MCI (M-aMCI)], and 2 participants with impairments in one of the non-episodic memory function domains [i.e., single-domain nonamnesic MCI (S-naMCI)].

#### 2.1.1. Estimation of awareness of memory deficits

Studies have obtained inconsistent results on the neuropsychological correlates of memory awareness possibly due to the poor characterization of the intragroup variability in the memory awareness ability of MCI or HC groups. Accordingly, in the present study, the MCI and HC groups were further divided into two subgroups, namely those with poor awareness (PA) and NA for the low objective memory function based on a discrepancy measure adapted from the study of Miskowiak et al. (Miskowiak et al., 2016). Specifically, the z-transforming difference score between the subjective and objective memory evaluations was calculated for each participant by using the following formula: inverted

z-transforming subjective scores – objective memory composite z-scores. The details of the measures used to indicate subjective and objective memory function are described in the following sections. Notably, the z-scores of subjective memory evaluation based on the self-report questionnaire were inverted before deriving the discrepancy scores to maintain consistency with the direction of the objective memory results (i.e., higher scores indicate better memory function). A positive discrepancy score indicated that the participants' rank ordering for their subjective evaluation was higher than that for their objective performance, which suggested an overestimation of their objective memory function. By contrast, a negative discrepancy score indicated an underestimation of the objective memory function. Scores near 0 were considered to indicate relatively high concordance between self-evaluated memory function and objective memory performance. In the present study, we investigated poor self-awareness of memory deficits. All the participants were divided into two subgroups: (1) the PA subgroup (MCI-PA,  $n = 22$ ; HC-PA,  $n = 5$ ) and (2) the NA subgroup (MCI-NA,  $n = 24$ ; HC-NA,  $n = 36$ ). The PA subgroup comprised individuals whose objective memory performance was overestimated (defined as having a discrepancy score  $\geq 0.5$ ). The NA subgroup comprised individuals whose objective memory performance was accurately estimated or underestimated (defined as having a discrepancy score  $< 0.5$ ). Due to the small sample size of the HC-PA subgroup and the primary focus on the MCI groups in this study, the following analyses mainly focused on comparing the behavior and brain characteristics among the two MCI subgroups and the HC-NA subgroup.

### 2.2. Neuropsychological data acquisition

A neuropsychological test battery was conducted to assess the performance in four cognitive domains. The battery included the following tests: (1) *Learning and Memory*: (1a) logical memory (LM) immediate and delayed recall of the Wechsler Memory Scale-III (WMS-3) (Hua et al., 2005) and (1b) the California Verbal Learning Test, Second Edition (CVLT-II) (Delis, 2000), total learning and long delayed free recall; (2) *Executive Function*: (2a) matrix reasoning subtest of the Wechsler Adult Intelligence Scale, Third Edition (WAIS-3) (Chen and Chen, 2002), (2b) the switching condition of the design fluency test of the Delis-Kaplan Executive Function System (Delis et al., 2001), (2c) digit span backward length of the WAIS-3, and (2d) the color-word interference condition of the Stroop task (Stroop-cw) (Golden, 1978); (3) *Attention*: (3a) digit span forward length of the WAIS-3 and (3b) digit symbol substitution subtest of the WAIS-3; and (4) *Language*: (4a) vocabulary subtest of the WAIS-3 and (4b) the animal fluency test (Benton et al., 1994; Hua et al., 1997). In addition to cognitive measures, we evaluated the Framingham Stroke Risk Profile (FSRP) (D'Agostino et al., 1994) to examine the cerebrovascular risk burden. The Clinical Dementia Rating (CDR) scale (Morris, 1993) and Geriatric Depression Scale (GDS): Short Form (Mui, 1996) were also used for assessing the functional status and depression status, respectively.

#### 2.2.1. Objective memory index

The four memory variables (i.e., LM immediate and delayed recall as well as CVLT-II List A 1–5 total recall and long delayed free recall) obtained from the LM and CVLT-II were used to compute the composite z-scores of episodic memory. Specifically, the raw scores of the participants' performance on each memory variable were first transformed into four z-scores according to the norms of each memory variable obtained from the entire participant pool in the present study. The four z-scores were then averaged, and the resulting composite z-scores represented the participants' relative performance on memory function, with positive values representing better objective memory performance.

#### 2.2.2. Subjective memory index

Green's Memory Complaints Inventory (Green and Allen, 2004) was used to evaluate the participants' self-perception of their memory

function. This questionnaire contains nine subscales that represent different aspects of self-reported memory problems (i.e., general memory problems, verbal memory problems, visuospatial memory problems, numerical information problems, pain interferes with memory, memory interferes with work, impairment of remote memory, amnesia for complex behavior, and amnesia for antisocial behavior). Because verbal memory is the most commonly reported problem encountered by older adults (Amariglio et al., 2011), we used two subscales—the General Memory Problems and Verbal Memory Problems subscales—to indicate subjective memory evaluations. Lower scores on the self-evaluated questionnaire reflected a lower endorsement of memory problems for an individual. To ensure consistency with the direction of the objective memory results, the z-scores of the subjective memory evaluations based on the questionnaire were inverted before determining the discrepancy scores.

### 2.3. MRI data acquisition

The participants were scanned using a 3-Tesla MRI system (Magnetom Trio, Siemens, Erlangen, Germany) equipped with a 32-channel phased-array head coil. An axial plane parallel to the anterior and posterior commissure lines was determined for the section orientation of the T1- and T2-weighted structural MRI and diffusion spectrum imaging (DSI) scans. High-resolution T1-weighted images were acquired using a three-dimensional magnetization-prepared rapid gradient echo sequence [repetition time (TR)/echo time (TE) = 2000 ms/2.98 ms, flip angle = 9°, field of view (FOV) = 256 × 256 × 192 mm<sup>3</sup>, acquisition matrix = 256 × 256 × 192 mm<sup>3</sup>, and voxel size = 1 mm<sup>3</sup>]. To provide an anatomical reference, T2-weighted structural images were also acquired with a turbo spin-echo sequence (TR/TE = 9430/101 ms, flip angle = 150°, FOV = 248 × 248 mm<sup>2</sup>, matrix size = 256 × 256, and section thickness = 3 mm) to cover the entire brain.

An advanced diffusion imaging method, namely DSI, was employed to examine the white matter network disconnection in relation to individual differences in memory awareness accuracy. The DSI technique enables highly accurate mapping of axonal trajectories because it can address problems associated with other diffusion imaging approaches, such as diffusion tensor imaging (DTI), by reducing the cross-fiber problem, which can result in the significant underestimation of the distribution of fiber pathways and in inaccuracies in identifying regions with partial volumes of cerebrospinal fluid or gray matter (Wedeen et al., 2005, 2008, 2012). DSI was performed using a single-shot spin-echo echo-planar imaging sequence (TR/TE = 9600/130 ms, flip angle = 90°, FOV = 200 × 200 mm<sup>2</sup>, acquisition matrix = 80 × 80, slice thickness = 2.5 mm, slice number = 56, and no gap) embedded with twice-refocused diffusion-sensitive gradients to minimize eddy-current-induced geometric distortions (Reese et al., 2003). Half-sphere sampling was employed in this study to reduce the total scan time. A total of 102 diffusion gradient vectors were applied, and each vector corresponded to the grid point filled in the half sphere of a 3D diffusion-encoding space (*q*-space) with a radius of 3 units ( $|q| \leq 3$ ) and maximum diffusion sensitivity ( $b_{max}$ ) of 4000 s/mm<sup>2</sup> (Kuo et al., 2008). Neuroimaging data were collected within 6 weeks of the neuropsychological evaluation.

## 2.4. Data analysis

### 2.4.1. Cortical parcellation and volumetric segmentation

The T1-weighted structural images were reviewed for quality and were registered to the study template. Volumetric segmentation (Fischl et al., 2002, 2004) and cortical surface reconstruction (Dale et al., 1999; Dale and Sereno, 1993; Fischl et al., 1999, 2004) were performed using FreeSurfer software (<http://surfer.nmr.mgh.harvard.edu/>). To limit the number of comparisons, only brain regions relevant to memory awareness, as indicated by previous studies, were included in the analysis. These included regions were the bilateral hippocampus (volumetric measures) and regions (thickness measures) of the inferior parietal

lobule and prefrontal lobes (i.e., medial orbital, caudal middle, rostral middle, pars opercularis, and pars triangularis). To further reduce the number of comparisons, the five prefrontal variables were combined and averaged as a composite frontal variable. In addition to the regional gray matter volumetric and thickness measures, global measures of brain morphometry, including the total cerebral gray matter volume (excluding the volume of the brainstem and cerebellum), total cerebral white matter [excluding the cerebellar white matter volume but including the white matter hypointensity (WMH) volume], and estimated total cranial vault (eTIV) volume, were included in this study.

### 2.4.2. Processing and analysis of the diffusion imaging data

All the collected images were subjected to quality assurance to ensure that no significant signal dropout occurred due to head motions before the reconstruction of the DSI data. Specifically, the criterion for poor dataset quality was set at >90 images of signal loss, which corresponded to a 6% error in the generalized fractional anisotropy (GFA) estimation. The images of all the participants in this study passed the quality assurance. The 102 acquired diffusion-attenuated signals from the half sphere were projected to fill the sphere's other half for each voxel. The diffusion probability density function (PDF) was reconstructed using the three-dimensional Fourier transform of signal intensity in the *q*-space. The second moment of the PDF along each of the 362 radial directions in a six-fold tessellated icosahedron was computed to obtain an orientation distribution function (ODF). The intravoxel fiber orientations were determined from the decomposed ODFs to identify the fiber direction field for tractography (Yeh and Tseng, 2013). A scalar measure of the degree of diffusion directionality, namely the GFA, was defined for each voxel according to the following formula: standard deviation of the ODF/root mean square of the ODF (Tuch, 2004). The mean GFA (mGFA) of each tract bundle is a DSI metric that is analogous to fractional anisotropy in DTI. The mGFA reflects the microstructural integrity of the white matter tract.

Tract-based automatic analysis (TBAA) was performed to reconstruct the white matter tracts of interest by using the method developed by Chen et al. (2015). Specifically, a study-specific template (SST) was first created from the DSI data of all the participants in the present study. The SST was then registered to a standard DSI template, namely NTU-DSI-122 (Hsu et al., 2015), to obtain the sampling coordinates. During the registration, the diffeomorphic anatomical registration through exponentiated lie algebra (DARTEL) algorithm of SPM12 was used to register the mean tissue probability map of the SST to the Montreal Neurological Institute (MNI) space, which resulted in the generation of a transformation map. The diffusion-weighted images of the SST were then transformed into the MNI space according to the transformation map obtained in the previous step. Subsequently, the transformed SST was registered to the NTU-DSI-122 template by using the large deformation diffeomorphic metric mapping (LDDMM)-DSI algorithm (Hsu et al., 2012), and a transformation map was produced. After the registration process was completed, the fiber tract coordinates in NTU-DSI-122, which are in the MNI space, were transformed into the DSI data of each participant to determine the mGFA of each tract bundle. The quality of registration was validated and showed robustness regardless of sample age and sex in our previous study (Tseng et al., 2021).

The tracts of interest included four groups of fibers: (1) hippocampus-related limbic circuit fibers, namely the bilateral fornix and inferior cingulum (IC, connection from the posterior cingulum to the hippocampus); (2) association fibers connecting the lateral frontal region to the inferior parietal and temporal regions, namely bilateral superior longitudinal fasciculus-III (SLF-III), inferior fronto-occipital fasciculus (IFOF), and uncinate fasciculus; (3) frontal-subcortical projection fibers, namely bilateral dorsal frontal-striatal tracts (striatal connections to the medial frontal and superior frontal regions), ventral frontal-striatal tracts (striatal connections to the inferior and middle frontal gyrus), and anterior thalamocortical radiations-ventral frontal part (to the orbitofrontal, middle, and inferior frontal regions); and (4)

callosal fibers, namely the corpus callosum of the dorsal (mainly the medial frontal and superior frontal regions) and ventral (mainly the inferior and middle frontal gyrus) prefrontal, inferior parietal lobule, and splenium regions.

#### 2.4.3. Statistical analyses

Analyses of variance (ANOVAs) and chi-square tests were used to compare group demographics (age, education attainment, and sex distribution) and clinical data (e.g., CDR sum-of-boxes, GDS, and FSRP scores) at an  $\alpha$  level of 0.05. For group comparisons of other neuropsychological variables, we conducted a multivariate analysis of covariance (MANCOVA) by controlling for the educational level and then performed a post hoc univariate comparison at an  $\alpha$  level of 0.0042.

Brain morphometric variables, including global measures of the brain (i.e., total cerebral gray matter volume, total cerebral white matter, eTIV volume, and WMH estimates) and regional gray matter volumetric and thickness measures, were compared among groups by using ANOVAs. The effects of sex were regressed from all gray matter thickness and volumetric measures, and standardized residual values were used for the analyses. In addition, we corrected the bilateral hippocampal volumes according to differences in head size by regressing the eTIV volume (derived from an atlas scaling factor described by Buckner et al. (Buckner et al., 2004)).

To evaluate white matter diffusion variables, analyses of covariance (ANCOVAs) that were controlled for sex were used for assessing group differences in the mGFA values of the four fiber tract groups. The effect sizes were calculated for pairwise comparisons of cognitive and brain variables that were significant according to Cohen's  $d$  (Cohen, 1977). Spearman correlation analyses were conducted for all the participants and only the patients with MCI to examine the association of white matter variables with the discrepancy scores between subjective and objective evaluations of memory function. Given the relatively small

sample size and to achieve a balance between the rigorous control of the potential confounding covariate and the ability to detect meaningful findings, the  $\alpha$  level was set as the conventional significance threshold ( $p < 0.05$ ) for all the statistical analyses involving brain variables (i.e., group comparisons for gray and white matter variables as well as correlational analyses between white matter tract microstructural integrity and subjective-objective memory evaluation discrepancy scores). All analyses were conducted using SPSS (Version 26.0, IBM Corp., Armonk, NY, USA).

### 3. Results

#### 3.1. Demographic, clinical, and cognitive characteristics by group

Table 1 presents a summary of the basic demographic and clinical characteristics of the participants. The three groups did not differ in their age, education, sex distribution, FSRP scores, and GDS scores (all  $p$  values  $> 0.05$ ). The two MCI groups did not differ in the MCI subtype composition ( $p > .05$ ). As expected, the two MCI groups exhibited higher CDR sum-of-boxes scores than the HC group did ( $F_{(2, 74)} = 4.42, p = .015, \eta_p^2 = 0.43$ ); however, the two MCI groups had comparable CDR sum-of-boxes scores ( $p > .05$ ).

The MANCOVA results obtained after controlling for the education level were significant (Wilks' Lambda = 0.34,  $F_{(24,120)} = 3.57, p < .001$ , partial  $\eta^2 = 0.42$ ) among neuropsychological measures (Table 1). Follow-up univariate analyses revealed that the HC-NA group outperformed the MCI-NA and MCI-PA groups on the WMS-3 LM immediate recall ( $p < .001$ , Cohen's  $d = 1.10$  vs.  $p < .001$ , Cohen's  $d = 1.94$ ) and delayed recall ( $p < .001$ , Cohen's  $d = 1.20$  vs.  $p < .001$ , Cohen's  $d = 2.17$ ), the CVLT-II total learning ( $p < .001$ , Cohen's  $d = 1.59$  vs.  $p < .001$ , Cohen's  $d = 2.35$ ) and long delayed free recall ( $p < .001$ , Cohen's  $d = 1.81$  vs.  $p < .001$ , Cohen's  $d = 2.58$ ), WAIS-3 matrix reasoning

**Table 1**

Demographic, clinical, and cognitive characteristics of healthy controls (HCs) with normal awareness (NA) for memory deficit and individuals diagnosed with mild cognitive impairment (MCI) having NA or poor awareness (PA) for memory deficit.

	HC-NA n = 36 (mean S.D.)	MCI-NA n = 24 (mean S.D)	MCI-PA n = 22 (mean S.D)	p value
<i>Demographics &amp; Clinical variables</i>				
Age	69.33 (4.09)	71.54 (8.85)	72.82 (7.83)	0.15
Education	13.78 (2.90)	12.21 (3.49)	12.14 (3.55)	0.09
Sex (women/ men)	21/15	14/10	11/11	0.80
aMCI single/ aMCI multi/naMCI single	–	14/9/1	7/14/1	0.19
FSRP % stroke risk	9.94 (6.87)	11.42 (9.12)	13.73 (7.41)	0.20
CDR-SB	0.48 (0.51)	1.07 (1.23)	1.19 (1.11)	.015 <sup>a</sup>
Geriatric Depression Scale	2.56 (2.18)	3.25 (2.59)	2.32 (2.55)	0.39
<i>Learning and memory</i>				
LM immediate recall	38.67(10.38)	26.14(12.32)	19.78 (9.02)	<0.001 <sup>a</sup>
LM delayed recall	24.06(8.76)	13.19(9.30)	8.28(5.38)	<0.001 <sup>a</sup>
CVLT-II total learning	49.61(8.70)	34.24(10.52)	30.17(7.85)	<0.001 <sup>a</sup>
CVLT-II long delayed free recall	11.42(2.44)	5.33(4.07)	3.39(3.66)	<0.001 <sup>a</sup>
<i>Executive function</i>				
Matrix Reasoning	15.81(5.12)	12.29(4.44)	8.33(4.89)	<0.001 <sup>a, b</sup>
Design Fluency (switching condition)	6.83(2.04)	5.90(2.30)	4.44(3.09)	0.013
Digit Span backward length	5.22(1.05)	4.38(1.50)	4.22(0.88)	0.013
Stroop interference	−3.41(7.88)	−6.07(9.05)	−4.87(8.20)	0.33
<i>Attention</i>				
Digit Span forward length	7.72(1.14)	7.19(1.37)	7.11(1.45)	0.51
Digit Symbol Substitution	65.28(11.17)	50.38(15.56)	48.94(19.63)	0.001 <sup>a</sup>
<i>Language</i>				
Vocabulary test	47.56(9.60)	39.19(13.06)	36.12(10.29)	0.016
Animal fluency	17.36(5.24)	15.62(3.69)	14.17(2.90)	0.094
<b>Macro-Brain Variables</b>				
Total cerebral gray matter (cm <sup>3</sup> )	586.88 (43.04)	575.68(44.72)	560.06 (48.77)	0.10
Total cerebral white matter (cm <sup>3</sup> )	414.37 (44.46)	409.42 (43.89)	410.82(46.63)	0.91
Estimated Total Intracranial volume (cm <sup>3</sup> )	1485.01 (138.66)	1500.56(148.88)	1476.69 (175.64)	0.86

Abbreviations: aMCI single/multi, amnesic mild cognitive impairment, single domain/multidomains; naMCI single, nonamnesic MCI, single domain; CDR-SB, Clinical Dementia Rating Scale sum-of-boxes scores; FSRP, Framingham Stroke Risk Profile; LM, logical memory subtest; CVLT-II, California Verbal Learning Test-II. Note: All scores are raw scores;  $p$  indicates the result for the three-group overall comparison when controlling for the education effect;  $a$  indicates a significant difference between the HC group and the two aMCI groups; and  $b$  indicates a significant difference between the two MCI groups.

subtest ( $p = .04$ , Cohen's  $d = 0.73$  vs.  $p < .001$ , Cohen's  $d = 1.49$ ), and WAIS-3 digit symbol substitution subtest ( $p = .002$ , Cohen's  $d = 1.10$  vs.  $p = .001$ , Cohen's  $d = 1.02$ ). The two MCI groups exhibited comparable performance on all cognitive measures (all  $p$  values  $> 0.05$ ) except the matrix reasoning test ( $p = .013$ , Cohen's  $d = 0.85$ ).

### 3.2. Regional differences in morphometry among groups

The global measures of the total cerebral gray matter, cerebral white matter, and eTIV volumes did not differ significantly among the groups (all  $p$  values  $> 0.05$ , Table 1). Compared with the HC-NA group, the MCI-NA and MCI-PA groups demonstrated decreased right frontal cortical thickness ( $F_{(2,79)} = 4.30, p = .017; p = .01$ , Cohen's  $d = 0.71$  vs.  $p = .03$ , Cohen's  $d = 0.60$ ), right hippocampal volume ( $F_{(2,79)} = 5.46, p = .006; p = .02$ , Cohen's  $d = 0.61$  vs.  $p = .003$ , Cohen's  $d = 0.85$ ), and left hippocampal volume ( $F_{(2,79)} = 4.49, p = .014; p = .032$ , Cohen's  $d = 0.62$  vs.  $p = .008$ , Cohen's  $d = 0.71$ ). However, the two MCI groups exhibited similar morphometry across variables (all  $p$  values  $> 0.05$ ). Fig. 1 presents the residual (regressing out sex, eTIV, or both) standardized  $z$ -scores of the regional brain morphometric variables that reached statistical significance for the three groups.

### 3.3. DSI differences among the groups

The one-way ANCOVA with adjustment for sex revealed that the mGFA values of the left fornix ( $F_{(2,78)} = 4.18, p = .019$ , partial  $\eta^2 = 0.10$ ), bilateral dorsal frontal–striatal tracts (left:  $F_{(2,78)} = 3.55, p = .03$ , partial  $\eta^2 = 0.08$ ; right:  $F_{(2,78)} = 3.48, p = .036$ , partial  $\eta^2 = 0.08$ ), left anterior thalamocortical radiations–ventral frontal part ( $F_{(2,78)} = 3.47, p = .036$ , partial  $\eta^2 = 0.08$ ), and corpus callosum connecting the bilateral ventral prefrontal ( $F_{(2,78)} = 3.18, p = .047$ , partial  $\eta^2 = 0.08$ ) and inferior parietal lobule ( $F_{(2,78)} = 6.51, p = .002$ , partial  $\eta^2 = 0.14$ ) regions differed among the groups.

Post hoc analyses revealed that the MCI-NA and MCI-PA groups exhibited lower mGFA values for the left fornix than the HC-NA group did ( $p = .009$ , Cohen's  $d = 0.81$  vs.  $p = .045$ , Cohen's  $d = 0.53$ ); however, the mGFA values did not differ between the two MCI groups. Compared with the HC-NA and MCI-NA groups, the MCI-PA group had a lower mGFA value of the left dorsal frontal–striatal tract ( $p = .019$ , Cohen's  $d = 0.59$  vs.  $p = .023$ , Cohen's  $d = 0.57$ ), right dorsal frontal–striatal tract ( $p = .016$ , Cohen's  $d = 0.64$  vs.  $p = .032$ , Cohen's  $d = 0.56$ ), left anterior thalamocortical radiations–ventral part ( $p = .014$ ,

Cohen's  $d = 0.67$  vs.  $p = .040$ , Cohen's  $d = 0.54$ ), and corpus callosum–inferior parietal lobule ( $p = .001$ , Cohen's  $d = 0.76$  vs.  $p = .003$ , Cohen's  $d = 0.83$ ). The MCI-PA group had a lower mGFA value of the corpus callosum–ventral prefrontal regions than the HC-NA group did ( $p = .014$ , Cohen's  $d = 0.67$ ) (Fig. 2).

### 3.4. Associations between discrepancy scores and diffusion imaging variables

We computed Spearman's correlations between subjective–objective memory evaluation discrepancy scores and white matter variables. For the entire cohort, the results revealed that overestimation of objective memory functioning (i.e., higher discrepancy scores) was significantly associated with decreased mGFA values for the bilateral fornix (left  $r_s = -0.28, p = .006$ ; right  $r_s = -0.23, p = .02$ ), IC (left  $r_s = -0.24, p = .017$ ; right  $r_s = -0.23, p = .02$ ), IFOF (left  $r_s = -0.33, p = .001$ ; right  $r_s = -0.22, p = .021$ ), ventral frontal–striatal tract (left  $r_s = -0.31, p = .002$ ; right  $r_s = -0.25, p = .011$ ), anterior thalamocortical radiations–ventral part (left  $r_s = -0.34, p = .001$ ; right  $r_s = -0.27, p = .006$ ), and corpus callosum connecting the bilateral ventral prefrontal ( $r_s = -0.31, p = .002$ ), dorsolateral prefrontal ( $r_s = -0.25, p = .011$ ), and inferior parietal lobules ( $r_s = -0.32, p = .002$ ).

When restricting the analyses to patients with MCI, the results

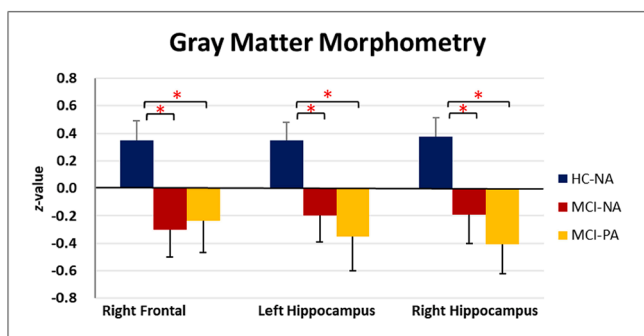


Fig. 1. Gray matter morphometry for the regions of interest (volumetric measure for the hippocampus and cortical thickness measures for other regions) in the three groups conducted using standardized  $z$ -scores after controlling for the effects of sex. Bilateral hippocampal volumes were additionally corrected for differences in head size by regressing out the estimated total cranial vault volume. Error bars denote standard error of the mean. HC-NA = healthy controls with normal awareness on memory deficit, MCI-NA = patients with mild cognitive impairment having normal awareness on memory deficit, and MCI-PA = patients with mild cognitive impairment having poor awareness on memory deficit. \*  $p < .05$ , \*\*  $p < .01$ , \*\*\*  $p < .005$ .

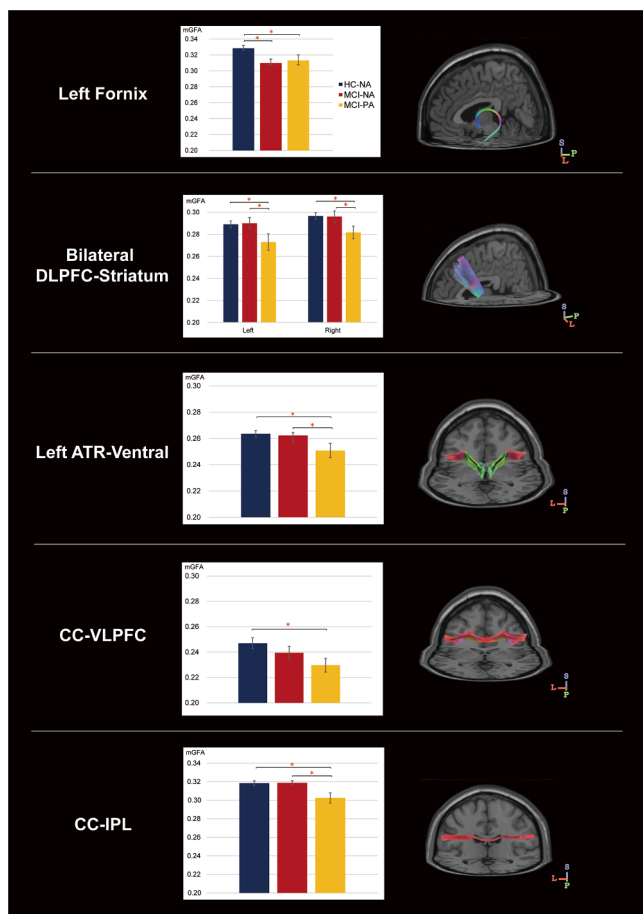
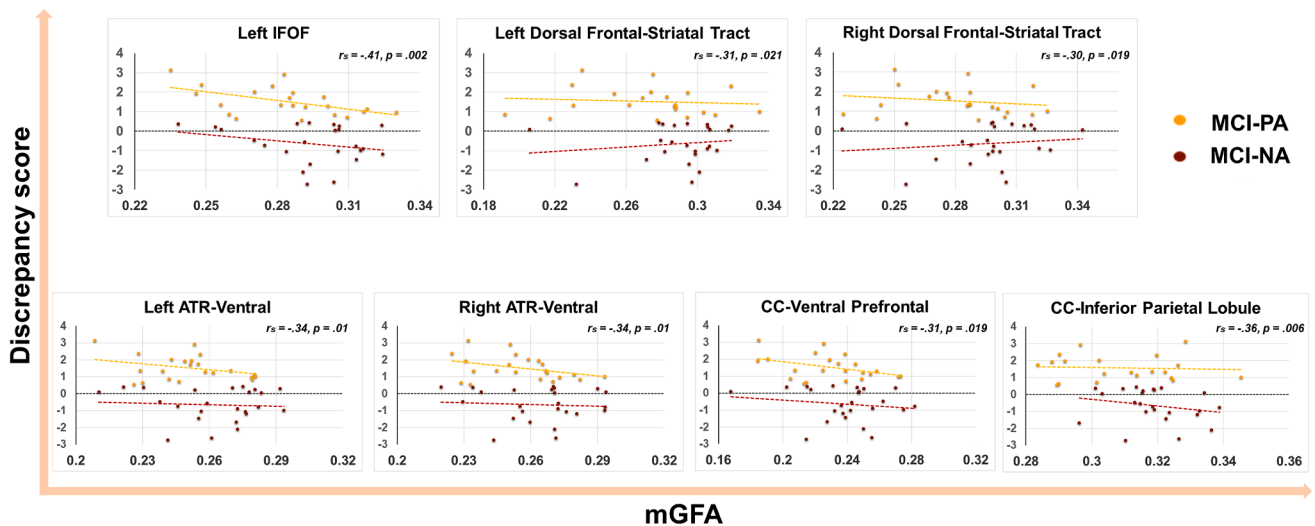


Fig. 2. Reconstructed white matter tracts derived through diffusion spectrum imaging and bar chart of the white matter tracts displaying significant group differences after controlling for the effects of sex. Bars and error bars of the bar chart denote the mean and standard deviation, respectively, of the generalized fractional anisotropy (GFA) value for each white matter tract within each group. ATR–ventral = anterior thalamocortical radiations–ventral frontal part, DLPFC–striatum = dorsal lateral prefrontal–striatal tract, and CC–VLPFC and CC–IPL = corpus callosum connected to the bilateral ventral lateral prefrontal cortices and inferior parietal lobules, respectively. \*  $p < .05$ .



**Fig. 3.** Associations between the integrity of the white matter tracts of interest as indicated by the mean GFA (mGFA, X-axis) and discrepancy scores between subjective and objective memory evaluations (Y-axis). The significant results were based on analyses restricting to the mild cognitive impairment cohorts. ATR-ventral = anterior thalamocortical radiations-ventral frontal part; CC-VLPFC and CC-IPL = corpus callosum connected to the bilateral ventral lateral prefrontal cortices and inferior parietal lobules, respectively; and IFOF = inferior fronto-occipital fasciculus. \*  $p < .05$ ; \*\*  $p < .01$ .

indicated that overestimation of objective memory functioning was significantly associated with decreased mGFA values for the left IFOF ( $r_s = -0.41$ ,  $p = .002$ ), bilateral dorsal frontal-striatal tract (left  $r_s = -0.31$ ,  $p = .021$ ; right  $r_s = -0.31$ ,  $p = .019$ ), bilateral anterior thalamocortical radiations-ventral part (left  $r_s = -0.34$ ,  $p = .01$ ; right  $r_s = -0.34$ ,  $p = .01$ ), and corpus callosum connecting the bilateral ventral prefrontal ( $r_s = -0.31$ ,  $p = .019$ ) and inferior parietal lobules ( $r_s = -0.36$ ,  $p = .006$ ) (Fig. 3).

#### 4. Discussion

The present study investigated the neuropsychological correlates and white matter network associated with poor memory awareness in MCI patients. To overcome the methodological drawbacks of previous relevant studies, we divided the MCI patients into two subgroups, namely those with PA and NA for their low objective memory function, according to a comprehensive neuropsychological test battery and ecologically relevant questions for assessing the discrepancy between objective and subjective memory evaluations. Moreover, we carefully defined the control group by including only cognitively unimpaired old adults with normal memory awareness (i.e., no overestimation of their objective memory function). By using this strategy, we found that although both MCI groups exhibited lower performance on episodic memory, reasoning, and visuomotor processing speed than the control group did, the performance of the two MCI groups was comparable across all cognitive tests, except the matrix reasoning test. Moreover, the MCI group with poor memory awareness exhibited decreased white matter integrity for the bilateral dorsal frontal-striatal tract, left anterior thalamocortical radiations-ventral part, and corpus callosum connecting the bilateral inferior parietal lobule and ventral prefrontal regions. This result could not be explained by morphometric differences in gray matter.

The first goal of the present study was to investigate the cognitive correlates of memory awareness deficits in patients with MCI. Although evidence concerning memory awareness deficits in patients with MCI is considerably inconsistent (Piras et al., 2016), several studies have reported that the nature of memory awareness deficits in MCI is mnemonic anosognosia (Perrotin et al., 2007; Piras et al., 2016; Ryals et al., 2019), in which awareness deficits are the product of a faulty personal knowledge base that results from the inability to consolidate memory failures over time (Mograbi et al., 2009; Morris and Mograbi, 2013). In

the present study, when examining the cognitive profiles of the two MCI groups, we found that although both MCI groups exhibited significantly higher cognitive difficulty than the HCs did, the MCI-PA group did not exhibit worse memory ability than the MCI-NA group. Although we could not rule out the contribution of memory deficits to decreased memory awareness, our results may support the hypothesis that memory deficits alone do not sufficiently account for anosognosia for memory deficits in MCI (Piras et al., 2016).

In the present study, we strategically included tests on different components of executive function, including switching, inhibition, working memory, and reasoning; however, the key group difference in the neuropsychological function concerning memory awareness was only observed in the test on the reasoning skill (i.e., the matrix reasoning test). Within the broad domain of executive function, our results may be in line with those of studies that have observed a positive relationship between executive dysfunction and anosognosia among patients with MCI (Chao et al., 2021; Senturk et al., 2017) and AD (Kashiwa et al., 2005; Shaked et al., 2014); however, the aforementioned finding has not been consistently replicated in different studies among MCI (Perrotin et al., 2007; Piras et al., 2016) or AD populations (Starkstein, 2014). Anosognosia has been reported to be correlated with tests that require verbal working memory in patients with MCI (Senturk et al., 2017) and switching ability (e.g., the trail-making test and design fluency task) (Lopez et al., 1994; Shaked et al., 2014) or inhibition ability (e.g., the Stroop test) (Kashiwa et al., 2005) in patients with AD. However, a close examination of previous studies reveals important nuances. First, the tests used to measure executive function in these studies were often limited to one or two components of executive function. Second, these studies were conducted on the basis of correlational analyses within one group. Furthermore, the patients' psychiatric conditions were not well controlled for and may have confounded the result. A meta-analysis of functional MRI (fMRI) results indicated that matrix reasoning has a bilateral frontal and parietal involvement with a right hemisphere predominance (Hobeika et al., 2016), and the frontoparietal network has been indicated to be critical for multiple aspects of self-awareness (Mondragon et al., 2019; Shaked et al., 2014). The results of the matrix reasoning test in the present study indicate that this test might serve as a diagnostic or complementary tool for evaluating anosognosia in MCI. Overall, although the design of the present study prevents us from specifying the individual role of memory versus executive functions to self-awareness of memory deficits, the study results suggest that

impaired self-awareness of memory deficits might occur when both memory and executive functions are impaired (Chao et al., 2021; Piras et al., 2016).

The second goal of the present study was to investigate the white matter microstructural network associated with self-awareness of memory impairment deficits in MCI. Several relevant tracts were identified to be vulnerable for the MCI-PA group relative to the MCI-NA and HC groups. These tracts are mainly the medial frontal–subcortical network and callosal fibers connecting the ventral prefrontal and inferior parietal regions. The findings of this research regarding the medial frontal and inferior parietal lobules are consistent with those of previous gray matter structural or functional imaging studies, which suggest that these regions are associated with memory anosognosia found in patients with MCI (Mondragon et al., 2019; Therriault et al., 2018; Vannini et al., 2017; Zamboni et al., 2013). Studies have proposed the medial prefrontal cortex and inferior parietal lobule as the “core-self” regions of the default mode network (Davey et al., 2016; Kim, 2020). In this network, the inferior parietal lobule plays roles in retrieving and integrating complex semantic information (Davey et al., 2016; Jouen et al., 2015), and the medial prefrontal cortex is responsible for regulatory gateway function, which enhances cognitive “reflective” thinking about oneself in relation to others (e.g., the autobiographical self-appraisal or self-referential process) (Kim, 2020; Moran et al., 2006). Although the statistical threshold was not reached in group analysis, a significant association between the IFOF, which is a long-range fiber tract, and memory awareness function was indicated by the correlational analyses conducted for the patients with MCI. The IFOF comprises a set of widespread long-range association bundles that extend from the frontal regions (including the lateral prefrontal and orbitofrontal cortices) to the distributed posterior cerebral regions (including the parietal, temporal–basal, and occipital regions). Studies have proposed that the IFOF is a “multifunction white matter bundle” (Luo et al., 2019; Sarubbo et al., 2013; Wu et al., 2016) that may serve multiple cognitive functions, including executive function, learning and memory, language ability, and visuospatial ability. Some studies have revealed an association between lesions on the IFOF and spatial awareness in stroke patients (Jang and Jang, 2018; Vaessen et al., 2016). Our study extends the findings on spatial awareness associated with IFOF disruptions to cognitive awareness and provides supporting evidence for the notion of the IFOF as a multifunction white matter bundle.

In the present study, the MCI-PA group exhibited significantly lower microstructural integrity of the anterior thalamic radiation than the MCI-NA group did. The left anterior thalamic radiation is a white matter bundle that connects the anterior and dorsomedial thalamic nuclei to the prefrontal cortex, mainly the orbitofrontal and dorsolateral prefrontal cortex, and it is involved in executive function and planning complex behaviors (Niida et al., 2018). Thalamus activation has been linked to dispositional mindfulness (Gartenschlager et al., 2017; Wang et al., 2014), and lesions on the anterior thalamic radiation have been identified to be associated with apathetic manifestations in MCI (Torso et al., 2015). Although our findings require further validation because we are the first to link the anterior thalamic radiation tract to memory awareness deficits in MCI, they may provide novel insights into the pathological mechanism of anosognosia in populations with MCI and AD.

This study also presents the first evidence that the corpus callosum connecting the ventral prefrontal and inferior parietal regions is linked to memory awareness deficits in patients with MCI. The specific role of the corpus callosum in self-awareness remains unclear. Although evidence obtained from clinical cases of alien hand syndrome has indicated that the posterior corpus callosum that interconnects the parietal areas plays a role in maintaining an integrated sense of self with regard to self-body representation and awareness (Uddin, 2011; van der Knaap and van der Ham, 2011), limited attention has been directed at investigating the psychological aspects of the self in individuals with lesions affecting the corpus callosum. Notably, a few studies that used DTI have reported

an association between the posterior corpus callosum and poor insights for psychiatric symptoms in patients with schizophrenia (Gerretsen et al., 2019; Kubota et al., 2012). In the present study, we extended previous evidence on the role of the posterior corpus callosum in self-awareness for body and psychiatric symptoms to cognitive domains. In addition to the posterior corpus callosum, we identified the involvement of the frontal callosal fibers in memory awareness. This finding is in line with the neuropsychological data of this study and our findings concerning the frontal–subcortical tract network, which indicate that both the medial and ventral lateral frontal lobe may serve as a hub for converging information relevant to self-awareness in memory. The corpus callosum is an important mediator of interhemispheric transfer; however, the nature of this mediation is unclear (van der Knaap and van der Ham, 2011). Two contrasting models have been suggested. According to the excitatory model, the callosal fibers integrate information from both cerebral hemispheres to facilitate interhemispheric connectivity (Bartha-Doering et al., 2021; Gazzaniga, 2000). By contrast, the inhibitory model postulates that callosal fibers inhibit homologous areas, which allows for independent functioning of the hemispheres (Cook, 1984). We found that decreased memory awareness was associated with decreased corpus callosum integrity, and we did not observe gray matter differences in frontal regions between the two MCI groups. Thus, the research results may support the excitatory model, in which the interhemispheric connectivity of the callosal fibers improved memory awareness. However, such a speculation warrants further validation through functional imaging studies conducted in combination with diffusion imaging data.

In the analyses, we included several tracts of the hippocampal and anterior temporal regions, which have been reported to be important for processing episodic memory and autobiographic information (Andrews-Hanna et al., 2010), including the fornix, IC, and uncus fasciculus. Similar to the results of previous studies that performed functional imaging of the hippocampus in MCI (Mondragon et al., 2019; Therriault et al., 2018; Vannini et al., 2017), we observed a significant correlation between hippocampal tracts (i.e., the fornix and IC) and the discrepancy scores of subjective–objective memory evaluations for the analysis of the entire cohort. However, the aforementioned association disappeared when the analysis was restricted to the patients with MCI, which indicates that this association is likely driven by a disease effect rather than a true brain–behavior relationship in memory awareness. A similar finding was obtained from our group comparison results, in which the two MCI groups exhibited significantly lower mGFA values for the left fornix tract than the control group did. However, the mGFA values of the MCI-PA group did not differ from those of the MCI-NA group for any tract of interest in the temporal regions. These results, reflecting a disease effect, was expected and is consistent with those in the literature (Lam et al., 2017; Wang et al., 2020). The results also mirrored the neuropsychological results, in which we did not observe significant differences between the two MCI groups across episodic memory measures.

Our null finding concerning temporal lobe regions in the diffusion imaging data for the MCI-PA group is inconsistent with the findings of studies concerning memory awareness deficits based on resting state fMRI or metabolic imaging in patients with MCI or AD (Nobili et al., 2010; Therriault et al., 2018; Vannini et al., 2017; Zamboni et al., 2013). This discrepancy is possibly related to differences in the composition of patients with MCI between the present study and other studies. Studies (Dong et al., 2020; Mito et al., 2018) have suggested that the subtle degeneration of hippocampal-related white matter tracts, such as the posterior cingulum or uncus fasciculus, are closely associated with etiologies such as vascular burden or inflammation rather than a neurodegenerative process (i.e., beta amyloid accumulation), especially in the early stage of prodromal AD. The MCI group in the present study had milder cognitive impairments than MCI groups in previous similar studies because our operational definition of objective cognitive impairment in MCI was  $-1$  standard deviation rather than  $-1.5$



standard deviations from the healthy average. Furthermore, by adopting a relatively comprehensive data collection strategy (e.g., a detailed survey on the participants' medical histories and matching of demographic and clinical variables among the groups), we reduced the possibility of recruiting participants with confounding variables, including vascular burden and traumatic brain injury history, which resulted in greater homogeneity within our MCI group than within MCI groups of other similar studies. Overall, the aforementioned methodological differences may account for the discrepancy in findings regarding hippocampal-related white matter tracts between this study and other studies. However, it is noted that similar to the findings of the neuropsychological tests in this study, we were unable to rule out the possibility that the involvement of hippocampal tracts by themselves may be a threshold, although insufficient, for memory awareness deficits. Impaired self-awareness of memory deficits might occur when the hippocampal related tracts and additional white matter tracts of frontal-subcortical and callosal fibers were all compromised.

The research findings for select tracts of interest appear to support bilateral white matter network involvement, which is in line with those of similar studies that used functional imaging (Nobili et al., 2010; Salmon et al., 2006; Zamboni et al., 2013). The observed white matter network disruptions involved in memory awareness in the present study also support the disconnection view of the nature of the anosognosia observed in other self-knowledge domains, such as spatial neglect (Thiebaut de Schotten et al., 2014) or body awareness (Monai et al., 2020). The disruption of the selected tracts of interest in this study might be associated with deficits in memory awareness caused by a reduction in functional activity in the frontal-parietal cortical-subcortical network connected by these white matter tracts. However, the underlying mechanism (e.g., hemodynamic or metabolic) of these disconnections requires further investigation. Evidence suggests that anosognosia serves as an independent predictor of conversion from MCI into AD (Gerretsen et al., 2017; Spalletta et al., 2014), and our findings suggest that disruption of white matter connectivity among different brain regions contribute to the memory awareness deficits observed in patients with MCI. The aforementioned information appears to be consistent with the cascading network failure model (Jones et al., 2016), which postulates that the development of AD may be due to connectivity changes over the course of disease progression. To confirm this hypothesis, the two MCI groups would have to be followed up longitudinally, and the differences in their trajectories of dementia development would have to be examined.

Despite its several innovations, the current study has certain limitations. First, we investigated white matter network involvement by dividing patients with MCI into two subgroups—one with NA and one with PA. Conceptualizing anosognosia categorically rather than continuously may result in decreasing ecological validity because unawareness may manifest in a continuous fashion ranging from marginal minimization to complete denial of problems clinically (Clare et al., 2005). To overcome this limitation, we conducted a correlational analysis based on the continuous variable of discrepancy scores. The correlational results based on the MCI cohorts are in agreement with the group difference analysis results and therefore support the validity of categorizing MCI patients. Second, the MCI sample comprised a mixture of amnesic and nonamnesic individuals, with the amnesic individuals being predominant. Such a sample composition may result in confounders related to the heterogeneity of the sample. However, the analyses conducted with and without the two patients with nonamnesic MCI did not change the results. Therefore, we believe that the results are robust and are not affected by the heterogeneity of the sample.

## 5. Conclusions

The present study is the first to investigate the associations between diffusion imaging variables and memory awareness in patients with MCI. Our findings suggest that episodic memory deficit is unable to

account for deficits in memory awareness in patients with MCI, and additional impairment of executive function may account for the deficit. Moreover, memory awareness deficits are likely to result from disconnection syndrome, in which the memory awareness function is subserved by a white matter network that comprises frontal-subcortical, parietal, and bilateral hemispheric interconnections in patients with MCI. Our findings promote the understanding of the brain and the behavioral basis of memory awareness deficits in individuals who are at risk of developing dementia. The research findings contribute to the development of models for the neural and cognitive correlates underlying memory awareness in human brain. It also provides a foundation upon which appropriate interventions can be developed to preserve or improve specific aspects of self-awareness.

## CRedit authorship contribution statement

**Yu-Ling Chang:** Conceptualization, Methodology, Formal analysis, Data curation, Funding acquisition, Writing - original draft. **Ruei-Yi Chao:** Data curation. **Yung-Chin Hsu:** Software, Resources. **Ta-Fu Chen:** Resources. **Wen-Yih Isaac Tseng:** Software, Resources.

## Acknowledgements

This research was supported by the Ministry of Science and Technology, Taiwan (grant numbers 109-2629-H-002-001-MY3 and 108-2410-H-002-106-MY2 to Y.L.C.). The authors would like to thank Ming-Yang Wang for figure preparation and the Imaging Center for Integrated Body, Mind, and Culture Research, National Taiwan University, for MRI facility support. The authors declare no conflict of interest.

## References

- Al-Aloucy, M.J., Cotteret, R., Thomas, P., Volteau, M., Benmaoui, I., Dalla Barba, G., 2011. Unawareness of memory impairment and behavioral abnormalities in patients with Alzheimer's disease: relation to professional health care burden. *J Nutr Health Aging* 15 (5), 356–360.
- Amariglio, R.E., Townsend, M.K., Grodstein, F., Sperling, R.A., Rentz, D.M., 2011. Specific subjective memory complaints in older persons may indicate poor cognitive function. *J. Am. Geriatr. Soc.* 59 (9), 1612–1617.
- Andrews-Hanna, J.R., Reidler, J.S., Sepulcre, J., Poulin, R., Buckner, R.L., 2010. Functional-anatomic fractionation of the brain's default network. *Neuron* 65 (4), 550–562.
- Baird, B., Cieslak, M., Smallwood, J., Grafton, S.T., Schooler, J.W., 2015. Regional white matter variation associated with domain-specific metacognitive accuracy. *J Cogn Neurosci* 27 (3), 440–452.
- Bartha-Doering, L., Kollndorfer, K., Schwartz, E., Fischmeister, F.P.S., Alexopoulos, J., Langa, G., Prayer, D., Kasprian, G., Seidl, R., 2021. The role of the corpus callosum in language network connectivity in children. *Dev Sci* 24 (2). <https://doi.org/10.1111/desc.v24.210.1111/desc.13031>.
- Berlinger, M., Ravasio, A., Cranna, S., Basilico, S., Sberna, M., Bottini, G., Paulesu, E., 2015. Unrealistic representations of "the self": A cognitive neuroscience assessment of anosognosia for memory deficit. *Conscious. Cogn.* 37, 160–177.
- Bertrand, J.M., Mazancieux, A., Moulin, C.J.A., Béjot, Y., Rouaud, O., Souchay, C., 2019. In the here and now: Short term memory predictions are preserved in Alzheimer's disease. *Cortex* 119, 158–164.
- Buckner, R.L., Head, D., Parker, J., Fotenos, A.F., Marcus, D., Morris, J.C., Snyder, A.Z., 2004. A unified approach for morphometric and functional data analysis in young, old, and demented adults using automated atlas-based head size normalization: reliability and validation against manual measurement of total intracranial volume. *Neuroimage* 23 (2), 724–738.
- Cabeza, R., Ciaramelli, E., Moscovitch, M., 2012. Cognitive contributions of the ventral parietal cortex: an integrative theoretical account. *Trends Cogn Sci* 16 (6), 338–352.
- Cabeza, R., Ciaramelli, E., Olson, I.R., Moscovitch, M., 2008. The parietal cortex and episodic memory: an attentional account. *Nat. Rev. Neurosci.* 9 (8), 613–625.
- Chang, Y.-L., Chen, T.-F., Shih, Y.-C., Chiu, M.-J., Yan, S.-H., Tseng, W.-Y., 2015. Regional cingulum disruption, not gray matter atrophy, detects cognitive changes in amnesic mild cognitive impairment subtypes. *J. Alzheimers Dis.* 44 (1), 125–138.
- Chao, R.-Y., Chen, T.-F., Chang, Y.-L., 2021. Executive function predicts the validity of subjective memory complaints in older adults beyond demographic, emotional, and clinical factors. *J. Prevent. Alzheimer's Dis.* 8 (2), 161–168.
- Chen, Y.H., Chen, R.H., 2002. Wechsler Adult Intelligence Scale-third edition (WAIS-III) Manual for Taiwan. The Chinese Behavioral Science Corporation, Taipei, Taiwan.
- Chen, Y.-J., Lo, Y.-C., Hsu, Y.-C., Fan, C.-C., Hwang, T.-J., Liu, C.-M., Chien, Y.-L., Hsieh, M.H., Liu, C.-C., Hwu, H.-G., Tseng, W.-Y., 2015. Automatic whole brain tract-based analysis using predefined tracts in a diffusion spectrum imaging template and an accurate registration strategy. *Hum. Brain Mapp.* 36 (9), 3441–3458.

- Chua, E.F., Schacter, D.L., Sperling, R.A., 2009. Neural correlates of metamemory: a comparison of feeling-of-knowing and retrospective confidence judgments. *J. Cogn. Neurosci.* 21 (9), 1751–1765.
- Clare, L., Marková, I., Verhey, F., Kenny, G., 2005. Awareness in dementia: A review of assessment methods and measures. *Aging Ment. Health* 9 (5), 394–413.
- Clare, L., Marková, I.S., Roth, I., Morris, R.G., 2011. Awareness in Alzheimer's disease and associated dementias: theoretical framework and clinical implications. *Aging Ment Health* 15 (8), 936–944.
- Cohen, J., 1977. *Statistical Power Analysis For The Behavioral Sciences*. Academic Press, New York.
- Cook, N.D., 1984. Callosal inhibition: the key to the brain code. *Behav. Sci.* 29 (2), 98–110.
- Cosentino, S., Metcalfe, J., Butterfield, B., Stern, Y., 2007. Objective metamemory testing captures awareness of deficit in Alzheimer's disease. *Cortex* 43 (7), 1004–1019.
- Cosentino, S., Metcalfe, J., Cary, M.S., De Leon, J., Karlawish, J., 2011. Memory awareness influences everyday decision making capacity about medication management in Alzheimer's Disease. *Int. J. Alzheimers Dis.* 2011, 1–9.
- D'Agostino, R.B., Wolf, P.A., Belanger, A.J., Kannel, W.B., 1994. Stroke risk profile: adjustment for antihypertensive medication. *The Framingham Study. Stroke* 25 (1), 40–43.
- Dale, A.M., Fischl, B., Sereno, M.I., 1999. Cortical surface-based analysis I. Segmentation and surface reconstruction. *Neuroimage* 9 (2), 179–194.
- Dale, A.M., Sereno, M.I., 1993. Improved localization of cortical activity by combining Eeg and Meg with Mri cortical surface reconstruction - a linear-approach. *J. Cognit. Neurosci.* 5, 162–176.
- Davey, C.G., Pujol, J., Harrison, B.J., 2016. Mapping the self in the brain's default mode network. *Neuroimage* 132, 390–397.
- DeFeis, B., Chapman, S., Zhu, C., Azar, M., Sunderaraman, P., Ornstein, K., Gu, Y., Cosentino, S., 2019. Reduced awareness of memory deficit is associated with increased medicare home health care use in dementia. *Alzheimer Dis. Assoc. Disord.* 33, 62–67.
- Delis, D.C., 2000. *California Verbal Learning Test*, 2nd ed. Psychological Corporation, San Antonio, TX.
- Delis, D.C., Kaplan, E., Kramer, J.H., 2001. *Delis-Kaplan Executive Function System (D-KEFS)*. Psychological Corporation.
- Dong, J.W., Jelescu, I.O., Ades-Aron, B., Novikov, D.S., Friedman, K., Babb, J.S., Osorio, R.S., Galvin, J.E., Shepherd, T.M., Fieremans, E., 2020. Diffusion MRI biomarkers of white matter microstructure vary nonmonotonically with increasing cerebral amyloid deposition. *Neurobiol. Aging* 89, 118–128.
- Elman, J.A., Klostermann, E.C., Marian, D.E., Verstaen, A., Shimamura, A.P., 2012. Neural correlates of metacognitive monitoring during episodic and semantic retrieval. *Cogn. Affect. Behav. Neurosci.* 12 (3), 599–609.
- Fischl, B., Salat, D.H., Busa, E., Albert, M., Dieterich, M., Haselgrove, C., van der Kouwe, A., Killiany, R., Kennedy, D., Klavness, S., Montillo, A., Makris, N., Rosen, B., Dale, A.M., 2002. Whole brain segmentation: automated labeling of neuroanatomical structures in the human brain. *Neuron* 33 (3), 341–355.
- Fischl, B., Sereno, M.I., Dale, A.M., 1999. Cortical surface-based analysis. II: Inflation, flattening, and a surface-based coordinate system. *Neuroimage* 9 (2), 195–207.
- Fischl, B., van der Kouwe, A., Destrieux, C., Halgren, E., Segonne, F., Salat, D.H., Busa, E., Seidman, L.J., Goldstein, J., Kennedy, D., Caviness, V., Makris, N., Rosen, B., Dale, A.M., 2004. Automatically parcellating the human cerebral cortex. *Cereb. Cortex* 14, 11–22.
- Gallo, D.A., Cramer, S.J., Wong, J.T., Bennett, D.A., 2012. Alzheimer's disease can spare local metacognition despite global anosognosia: revisiting the confidence-accuracy relationship in episodic memory. *Neuropsychologia* 50 (9), 2356–2364.
- Gartenschläger, M., Schreckenberger, M., Buchholz, H.-G., Reiner, I., Beutel, M.E., Adler, J., Michal, M., 2017. Resting Brain Activity Related to Dispositional Mindfulness: a PET Study. *Mindfulness (N Y)* 8 (4), 1009–1017.
- Gazzaniga, M.S., 2000. Cerebral specialization and interhemispheric communication: does the corpus callosum enable the human condition? *Brain* 123 (Pt 7), 1293–1326.
- Gerretsen, P., Chung, J.K., Shah, P., Plitman, E., Iwata, Y., Caravaggio, F., Nakajima, S., Pollock, B.G., Graff-Guerrero, A., Alzheimer's Disease Neuroimaging, I., 2017. Anosognosia is an independent predictor of conversion from mild cognitive impairment to alzheimer's disease and is associated with reduced brain metabolism. *J. Clin. Psychiatry* 78, e1187–e1196.
- Gerretsen, P., Rajji, T.K., Shah, P., Shahab, S., Sanches, M., Graff-Guerrero, A., Menon, M., Pollock, B.G., Mamo, D.C., Mulsant, B.H., Voineskos, A.N., 2019. Impaired illness awareness in schizophrenia and posterior corpus callosal white matter tract integrity. *npj Schizophr.* 5, 8.
- Golden, C.J., 1978. *Stroop Color and Word Test: A Manual For Clinical And Experimental Uses*. Stoelting, Chicago, IL.
- Green, P., Allen, L., 2004. *Memory Complaints Inventory*. Edmonton, Canada.
- Hobeika, L., Diard-Detoef, C., Garcin, Béatrice, Levy, R., Volle, E., 2016. General and specialized brain correlates for analogical reasoning: A meta-analysis of functional imaging studies. *Hum. Brain Mapp.* 37 (5), 1953–1969.
- Hsu, Y.-C., Hsu, C.-H., Tseng, W.-Y., 2012. A large deformation diffeomorphic metric mapping solution for diffusion spectrum imaging datasets. *Neuroimage* 63 (2), 818–834.
- Hsu, Y.-C., Lo, Y.-C., Chen, Y.-J., Wedeen, V.J., Isaac Tseng, W.-Y., 2015. NTU-DSI-122: a diffusion spectrum imaging template with high anatomical matching to the ICBM-152 space. *Hum. Brain Mapp.* 36 (9), 3528–3541.
- Hua, M.S., Chang, B.S., Lin, K.N., Yang, J.M., Lu, S.R., Chen, S.Y., 2005. *Wechsler Memory Scale-Third Edition (WMS-III) Manual for Taiwan*. The Chinese Behavioral Science Corporation, Taipei, Taiwan.
- Jak, A.J., Bondi, M.W., Delano-Wood, L., Wierenga, C., Corey-Bloom, J., Salmon, D.P., Delis, D.C., 2009. Quantification of five neuropsychological approaches to defining mild cognitive impairment. *Am. J. Geriatr. Psychiatry* 17 (5), 368–375.
- Jak, A.J., Urban, S., McCauley, A., Bangen, K.J., Delano-Wood, L., Corey-Bloom, J., Bondi, M.W., 2009. Profile of hippocampal volumes and stroke risk varies by neuropsychological definition of mild cognitive impairment. *J. Int. Neuropsychol. Soc.* 15 (6), 890–897.
- Jang, S.H., Jang, W.H., 2018. The allocentric neglect due to injury of the inferior fronto-occipital fasciculus in a stroke patient: A case report. *Medicine (Baltimore)* 97, e9295.
- Jones, D.T., Knopman, D.S., Gunter, J.L., Graff-Radford, J., Vemuri, P., Boeve, B.F., Petersen, R.C., Weiner, M.W., Jack Jr., C.R., Alzheimer's Disease Neuroimaging, I., 2016. Cascading network failure across the Alzheimer's disease spectrum. *Brain* 139, 547–562.
- Jouen, A.L., Ellmore, T.M., Madden, C.J., Pallier, C., Dominey, P.F., Ventre-Dominey, J., 2015. Beyond the word and image: characteristics of a common meaning system for language and vision revealed by functional and structural imaging. *Neuroimage* 106, 72–85.
- Kashiwa, Y., Kitabayashi, Y., Narumoto, J., Nakamura, K., Ueda, H., Fukui, K., 2005. Anosognosia in Alzheimer's disease: association with patient characteristics, psychiatric symptoms and cognitive deficits. *Psychiatry Clin. Neurosci.* 59 (6), 697–704.
- Kim, H., 2020. Stability or plasticity? - A hierarchical allostatic regulation model of medial prefrontal cortex function for social valuation. *Front. Neurosci.* 14, 281.
- Kubota, M., Miyata, J., Sasamoto, A., Kawada, R., Fujimoto, S., Tanaka, Y., Sawamoto, N., Fukuyama, H., Takahashi, H., Murai, T., 2012. Alexithymia and reduced white matter integrity in schizophrenia: a diffusion tensor imaging study on impaired emotional self-awareness. *Schizophr. Res.* 141 (2–3), 137–143.
- Kuo, L.-W., Chen, J.-H., Wedeen, V.J., Tseng, W.-Y., 2008. Optimization of diffusion spectrum imaging and q-ball imaging on clinical MRI system. *Neuroimage* 41 (1), 7–18.
- Lam, C.L.M., Yiend, J., Lee, T.M.C., 2017. Imaging and neuropsychological correlates of white matter lesions in different subtypes of Mild Cognitive Impairment: A systematic review. *NeuroRehabilitation* 41 (1), 189–204.
- Lenzoni, S., Morris, R.G., Mograbi, D.C., 2020. The Petrified Self 10 Years After: Current Evidence for Mnemonic anosognosia. *Front. Psychol.* 11, 465.
- Loewenstein, D.A., Acevedo, A., Small, B.J., Agron, J., Crocco, A., Duara, R., 2009. Stability of different subtypes of mild cognitive impairment among the elderly over a 2- to 3-year follow-up period. *Dement. Geriatr. Cogn. Disord.* 27 (5), 418–423.
- Lopez, O.L., Becker, J.T., Somsak, D., Dew, M.A., DeKosky, S.T., 1994. Awareness of cognitive deficits and anosognosia in probable Alzheimer's disease. *Eur. Neurol.* 34 (5), 277–282.
- Luo, D.-H., Tseng, W.-Y., Chang, Y.-L., 2019. White matter microstructure disruptions mediate the adverse relationships between hypertension and multiple cognitive functions in cognitively intact older adults. *Neuroimage* 197, 109–119.
- Miskowiak, K.W., Petersen, J.Z., Ott, C.V., Knorr, U., Kessing, L.V., Gallagher, P., Robinson, L., 2016. Predictors of the discrepancy between objective and subjective cognition in bipolar disorder: a novel methodology. *Acta Psychiatr. Scand.* 134 (6), 511–521.
- Mito, R., Raffelt, D., Dholander, T., Vaughan, D.N., Tournier, J.D., Salvado, O., Brodtmann, A., Rowe, C.C., Villemagne, V.L., Connelly, A., 2018. Fibre-specific white matter reductions in Alzheimer's disease and mild cognitive impairment. *Brain* 141, 888–902.
- Mograbi, D.C., Brown, R.G., Morris, R.G., 2009. Anosognosia in Alzheimer's disease—the petrified self. *Conscious. Cogn.* 18 (4), 989–1003.
- Monai, E., Bernocchi, F., Bisio, M., Bisogno, A.L., Salvalaggio, A., Corbetta, M., 2020. Multiple Network Disconnection in Anosognosia for Hemiplegia. *Front. Syst. Neurosci.* 14.
- Mondragón, J.D., Maurits, N.M., De Deyn, P.P., 2019. Functional neural correlates of anosognosia in mild cognitive impairment and Alzheimer's Disease: a Systematic Review. *Neuropsychol. Rev.* 29 (2), 139–165.
- Moran, J.M., Macrae, C.N., Heatherton, T.F., Wyland, C.L., Kelley, W.M., 2006. Neuroanatomical evidence for distinct cognitive and affective components of self. *J. Cogn. Neurosci.* 18 (9), 1586–1594.
- Morris, J.C., 1993. The Clinical Dementia Rating (CDR): current version and scoring rules. *Neurology* 43 (11), 2412–2412.
- Morris, R.G., Mograbi, D.C., 2013. Anosognosia, autobiographical memory and self knowledge in Alzheimer's disease. *Cortex* 49 (6), 1553–1565.
- Mui, A.C., 1996. Geriatric Depression Scale as a community screening instrument for elderly Chinese immigrants. *Int. Psychogeriatr.* 8 (3), 445–458.
- Niida, R., Yamagata, B., Niida, A., Uechi, A., Matsuda, H., Mimura, M., 2018. Aberrant anterior thalamic radiation structure in bipolar disorder: a diffusion tensor tractography study. *Front. Psychiatry* 9, 522.
- Nobili, F., Mazzei, D., Dessi, B., Morbelli, S., Brugnolo, A., Barbieri, P., Girtler, N., Sambucetti, G., Rodriguez, G., Pagani, M., 2010. Unawareness of memory deficit in amnesic MCI: FDG-PET findings. *J. Alzheimers Dis.* 22 (3), 993–1003.
- Perotini, A., Belleville, S., Isingrini, M., 2007. Metamemory monitoring in mild cognitive impairment: Evidence of a less accurate episodic feeling-of-knowing. *Neuropsychologia* 45 (12), 2811–2826.
- Petersen, R.C., Morris, J.C., 2005. Mild cognitive impairment as a clinical entity and treatment target. *Arch. Neurol.* 62, 1160–1163 discussion 1167.
- Piras, F., Piras, F., Orfei, M.D., Caltagirone, C., Spalletta, G., 2016. Self-awareness in Mild Cognitive Impairment: Quantitative evidence from systematic review and meta-analysis. *Neurosci. Biobehav. Rev.* 61, 90–107.

- Reese, T.G., Heid, O., Weisskoff, R.M., Wedeen, V.J., 2003. Reduction of eddy-current-induced distortion in diffusion MRI using a twice-refocused spin echo. *Magn. Reson. Med.* 49 (1), 177–182.
- Ryals, A.J., O’Neil, J.T., Mesulam, M.-M., Weintraub, S., Voss, J.L., 2019. Memory awareness disruptions in amnesic mild cognitive impairment: comparison of multiple awareness types for verbal and visuospatial material. *Neuropsychol. Dev. Cogn. B Aging Neuropsychol. Cogn.* 26 (4), 577–598.
- Salmon, E., Perani, D., Herholz, K., Marique, P., Kalbe, E., Holthoff, V., Delbeuck, X., Beuthien-Baumann, B., Pelati, O., Lespagnard, S., Collette, F., Garraux, G., 2006. Neural correlates of anosognosia for cognitive impairment in Alzheimer’s disease. *Hum. Brain Mapp.* 27 (7), 588–597.
- Sarubbo, S., De Benedictis, A., Maldonado, I.L., Basso, G., Duffau, H., 2013. Frontal terminations for the inferior fronto-occipital fascicle: anatomical dissection, DTI study and functional considerations on a multi-component bundle. *Brain Struct. Funct.* 218 (1), 21–37.
- Selmezy, D., Dobbins, I.G., 2017. Ignoring memory hints: The stubborn influence of environmental cues on recognition memory. *J. Exp. Psychol. Learn. Mem. Cogn.* 43 (9), 1448–1469.
- Senturk, G., Bilgic, B., Arslan, A.B., Bayram, A., Hanagasi, H., Gurvit, H., Emre, M., 2017. Cognitive and anatomical correlates of anosognosia in amnesic mild cognitive impairment and early-stage Alzheimer’s disease. *Int. Psychogeriatr.* 29 (2), 293–302.
- Shaked, D., Farrell, M., Huey, E., Metcalfe, J., Cines, S., Karlawish, J., Sullo, E., Cosentino, S., 2014. Cognitive correlates of metamemory in Alzheimer’s disease. *Neuropsychology* 28 (5), 695–705.
- Spalletta, G., Piras, F., Piras, F., Sancesario, G., Iorio, M., Fratangeli, C., Cacciari, C., Caltagirone, C., Orfei, M.D., 2014. Neuroanatomical correlates of awareness of illness in patients with amnesic mild cognitive impairment who will or will not convert to Alzheimer’s disease. *Cortex* 61, 183–195.
- Starkstein, S.E., 2014. Anosognosia in Alzheimer’s disease: diagnosis, frequency, mechanism and clinical correlates. *Cortex* 61, 64–73.
- Therriault, J., Ng, K.P., Pascoal, T.A., Mathotaarachchi, S., Kang, M.S., Struyfs, H., Shin, M., Benedet, A.L., Walpole, I.C., Nair, V., Gauthier, S., Rosa-Neto, P., Alzheimer’s Disease Neuroimaging, I., 2018. Anosognosia predicts default mode network hypometabolism and clinical progression to dementia. *Neurology* 90, e932–e939.
- Thiebaut de Schotten, M., Tomaiuolo, F., Aiello, M., Merola, S., Silvetti, M., Lecce, F., Bartolomeo, P., Doricchi, F., 2014. Damage to white matter pathways in subacute and chronic spatial neglect: a group study and 2 single-case studies with complete virtual “in vivo” tractography dissection. *Cereb. Cortex* 24 (3), 691–706.
- Torso, M., Serra, L., Giulietti, G., Spanò, B., Tuzzi, E., Koch, G., Caltagirone, C., Cercignani, M., Bozzali, M., Ginsberg, S.D., 2015. Strategic lesions in the anterior thalamic radiation and apathy in early Alzheimer’s disease. *PLoS ONE* 10 (5), e0124998.
- Tuch, D.S., 2004. Q-ball imaging. *Magnetic resonance in medicine* 52, 1358–1372.
- Tseng, W.-Y., Hsu, Y.-C., Chen, C.-L., Kang, Y.-J., Kao, T.-W., Chen, P.-Y., Waiter, G.D., 2021. Microstructural differences in white matter tracts across middle to late adulthood: a diffusion MRI study on 7167 UK Biobank participants. *Neurobiol. Aging* 98, 160–172.
- Uddin, L.Q., 2011. Brain connectivity and the self: the case of cerebral disconnection. *Conscious. Cogn.* 20 (1), 94–98.
- Vaessen, M.J., Saj, A., Lovblad, K.-O., Gschwind, M., Vuilleumier, P., 2016. Structural white-matter connections mediating distinct behavioral components of spatial neglect in right brain-damaged patients. *Cortex* 77, 54–68.
- van der Knaap, L.J., van der Ham, I.J.M., 2011. How does the corpus callosum mediate interhemispheric transfer? A review. *Behav. Brain Res.* 223 (1), 211–221.
- Vannini, P., Hanseeuw, B., Munro, C.E., Amariglio, R.E., Marshall, G.A., Rentz, D.M., Pascual-Leone, A., Johnson, K.A., Sperling, R.A., 2017. Anosognosia for memory deficits in mild cognitive impairment: Insight into the neural mechanism using functional and molecular imaging. *Neuroimage Clin* 15, 408–414.
- Wang, P., Zhou, B., Yao, H., Xie, S., Feng, F., Zhang, Z., Guo, Y., An, N., Zhou, Y., Zhang, X., Liu, Y., Yu, J.-T., 2020. Aberrant Hippocampal Functional Connectivity Is Associated with Fornix White Matter Integrity in Alzheimer’s Disease and Mild Cognitive Impairment. *J. Alzheimers Dis.* 75 (4), 1153–1168.
- Wang, X., Xu, M., Song, Y., Li, X., Zhen, Z., Yang, Z., Liu, J., 2014. The network property of the thalamus in the default mode network is correlated with trait mindfulness. *Neuroscience* 278, 291–301.
- Wedeen, V.J., Hagmann, P., Tseng, W.-Y., Reese, T.G., Weisskoff, R.M., 2005. Mapping complex tissue architecture with diffusion spectrum magnetic resonance imaging. *Magn. Reson. Med.* 54 (6), 1377–1386.
- Wedeen, V.J., Rosene, D.L., Wang, R., Dai, G., Mortazavi, F., Hagmann, P., Kaas, J.H., Tseng, W.Y.I., 2012. The geometric structure of the brain fiber pathways. *Science* 335 (6076), 1628–1634.
- Wedeen, V.J., Wang, R.P., Schmahmann, J.D., Benner, T., Tseng, W.Y.I., Dai, G., Pandya, D.N., Hagmann, P., D’Arceuil, H., de Crespigny, A.J., 2008. Diffusion spectrum magnetic resonance imaging (DSI) tractography of crossing fibers. *Neuroimage* 41 (4), 1267–1277.
- Wu, Y., Sun, D., Wang, Y., Wang, Y., 2016. Subcomponents and connectivity of the inferior fronto-occipital fasciculus revealed by diffusion spectrum imaging fiber tracking. *Front. Neuroanat.* 10, 88.
- Yeh, F.-C., Tseng, W.-Y., Valdes-Sosa, P.A., 2013. Sparse solution of fiber orientation distribution function by diffusion decomposition. *PLoS ONE* 8 (10), e75747.
- Zamboni, G., Drazich, E., McCulloch, E., Filippini, N., Mackay, C.E., Jenkinson, M., Tracey, I., Wilcock, G.K., 2013. Neuroanatomy of impaired self-awareness in Alzheimer’s disease and mild cognitive impairment. *Cortex* 49 (3), 668–678.