



Original research

Combined cataract extraction and trabeculotomy by the internal approach for coexisting cataract and open-angle glaucoma

Seyed Javad Hashemian, Arezoo Miraftebi*, Mohammad Ebrahim Jafari, Mohsen Rezaei Hemami

Eye Research Center, Rassoul Akram Hospital, Iran University of Medical Sciences, Tehran, Iran

Received 3 July 2016; accepted 10 September 2016

Available online 4 October 2016

Abstract

Purpose: To provide efficacy and safety of surgery with Trabectome combined with phacoemulsification in primary open-angle glaucoma.

Methods: In this interventional case series, 30 consecutive eyes that have had combined phacoemulsification with Trabectome were included. The main outcome measures were change in intraocular pressure (IOP), glaucoma medication use, and the rate of complications.

Results: Mean IOP was 18.25 ± 3.28 mmHg preoperatively which decreased to 13.50 ± 2.53 mmHg at 1 year. ($P < 0.05$). There was a corresponding drop in glaucoma medications from 2.52 ± 0.60 at baseline to 1.40 ± 0.53 at 12 months ($P < 0.01$). The preoperative BCVA (Log Mar) was improved from 0.68 ± 0.26 pre-operatively to 0.26 ± 0.19 , 0.18 ± 0.13 , 0.17 ± 0.13 , 0.11 ± 0.12 , at 5 days and 2, 6, and 12 months, respectively ($P < 0.01$). The only frequent complication was transient blood reflux resolving spontaneously within a few days. No vision-threatening complication occurred.

Conclusion: Combined phacoemulsification and Trabectome significantly lowered IOP and medication use, with early visual rehabilitation in the majority of patients.

Copyright © 2017, Iranian Society of Ophthalmology. Production and hosting by Elsevier B.V. This is an open access article under the CC BY-NC-ND license (<http://creativecommons.org/licenses/by-nc-nd/4.0/>).

Keywords: Phacoemulsification; Trabectome; Glaucoma

Introduction

Glaucoma is the second most common cause of irreversible blindness worldwide.¹ Many patients with glaucoma have concurrent cataracts. Some studies suggest that glaucoma itself is a risk factor for cataract development.^{2–4} The benefits of combined cataract and glaucoma surgeries include possible elimination or at least reduction of glaucoma medications in glaucoma patients who desire cataract surgery, but who are on multiple glaucoma medications.^{5,6}

Combined phacoemulsification (phaco) and trabeculectomy is considered the “treatment of choice” in patients with open-angle glaucoma and cataract; however, it is associated with postoperative complications such as hypotony, choroidal effusions, suprachoroidal hemorrhages, and endophthalmitis.^{7,8} Phacotrabeculectomy patients need intensive postoperative management even without complications.⁹

The combination of phacoemulsification with an established contemporary surgical technique such as Trabectome (NeoMedix Corp., Tustin, CA) or canaloplasty may result in a lower rate of complications.^{10–12} These procedures, in contrast to trabeculectomy and aqueous tube shunt, rely on the augmentation of the trabecular outflow pathway without the need for external drainage of aqueous.¹³ Therefore, many complications associated with external filtering procedures are reduced or eliminated. Combined phaco-Trabectome has the advantage of preserving conjunctiva by performing an ab-internal trabeculotomy using electro-ablation of the

Financial disclosure: No financial support was received for this submission.

* Corresponding author. Eye Research Center, Rassoul Akram Hospital, Niayesh Ave, Sattarkhan St, Tehran, Iran.

E-mail address: arezoomiraftebi@yahoo.com (A. Miraftebi).

Peer review under responsibility of the Iranian Society of Ophthalmology.

<http://dx.doi.org/10.1016/j.joco.2016.09.003>

2452-2325/Copyright © 2017, Iranian Society of Ophthalmology. Production and hosting by Elsevier B.V. This is an open access article under the CC BY-NC-ND license (<http://creativecommons.org/licenses/by-nc-nd/4.0/>).

meshwork and inner wall of Schlemm's canal with continuous aspiration of tissue debris.¹²

The purpose of this study is to evaluate results of combined phaco and Trabectome on intraocular pressure (IOP) of patients with primary open-angle glaucoma and cataract.

Methods

This study was an interventional case series of 28 patients (30 eyes) with uncontrolled open-angle glaucoma and cataract who had combined phacoemulsification and trabeculotomy by the internal approach at the Department of Ophthalmology at Iran University of Medical Sciences. Patients were in the planned phacoemulsification and trabeculotomy ab-interno group if they had cataract and mild to moderate primary open-angle glaucoma with uncontrolled IOP more than 21 mmHg while receiving maximum tolerable anti-glaucomatous therapy or controlled glaucoma with IOP less than 21 mmHg and cataract and desired to decrease the number of medications.

The target IOP was determined by the treating glaucoma specialist during follow-up according to standardized criteria such as optic nerve cupping and retinal nerve fiber layer loss, visual field loss, and clinical course. Patients with a history of previous ocular surgery or corneal opacity that impaired angle visualization were excluded. Possible alternatives, beneficial effects, and potential complications of the surgical procedure were explained in detail to all patients. Written informed consent was obtained from all participants. Study was in adherence to the tenets of the Declaration of Helsinki. Before surgical intervention, all patients had baseline examinations including measurements of best corrected visual acuity, visual field examination (30–2, Humphrey Field Analyzer, model 750, Zeiss), biomicroscopy, gonioscopy, Goldmann applanation tonometry, auto kerato refractometry, and corneal topography (Topcon KR-8100P Auto kerato refractometer, Topcon). Two experienced surgeons performed all operations. IOP was compared to a group of age-matched phaco patients after two months. We did not have a parallel phaco group, but we used the information of 44 age-matched phaco groups by the same surgeons for a comparison of IOP change. In this group, patients with glaucoma or ocular hypertension were excluded.

Surgical technique

In all cases, the ab-interno approach of the Trabectome (NeoMedix Corp., Tustin, CA) was performed first, followed by cataract extraction. Standard dilating drops comprising phenylephrine hydrochloride (Neo-Synephrine 1%) and tropicamide (Mydracyl 0.5%) were instilled 30 min before the operation. Under topical anesthesia, after the area was prepped and draped, a 1.6 or 1.7 mm keratome was used to make a near-limbal, temporal clear corneal incision. Preservative-free lidocaine 2% was injected into the anterior chamber. An ophthalmic dispersive viscosurgical device (OVD) such as hydroxypropyl methylcellulose (Ocucoat) was injected to form the anterior chamber. The head and microscope were tilted to give an optimal gonioscopic view of the angle. The

combined tilt was approximately 70–80°. The Trabectome goniosurgical lens (a modified Swann-Jacobs lens) was placed on the cornea to verify the angle landmarks. The Trabectome handpiece was inserted and advanced nasally across the anterior chamber with the infusion on. The pointed tip of the footplate was inserted through the trabecular meshwork into Schlemm's canal, and a footswitch activated the aspiration and bipolar electrodes. Using an initial power setting of 0.7–0.8 W, the surgeon slowly advanced the instrument along the meshwork first in a counterclockwise, then in a clockwise, direction using the limbal corneal incision as a fulcrum, ablating and removing a strip of trabecular meshwork unroofing the canal of Schlemm. The power was titrated up or down depending on the desire to ablate a wider strip of trabecular meshwork or to minimize charring of tissue, respectively. Verification of the cleft was performed, as the handpiece was removed, and the angle was viewed for evidence of blood reflux from the newly exposed collector channels. After filling the anterior chamber with an OVD, phacoemulsification and IOL implantation were then performed using the surgeon's preferred technique. At the conclusion of the procedure, depending on pupil size, for pupils more than 6 mm, acetylcholine chloride (Miochol) was instilled for prevention of peripheral anterior synechia. The amount of blood in the anterior chamber was assessed. If active bleeding was present, an air-bubble was injected into the anterior chamber. The corneal incision was then hydrated and checked for leakage.

Postoperative care varied according to clinical presentation but routinely included topical steroids (Fluorometholone) 8 times daily tapered over 6 weeks and topical antibiotics 4 times daily for 5 days.

Goldmann applanation IOPs and Snellen visual acuities were measured before and after surgery at each visit. Intraoperative and postoperative adverse events were tabulated, and numbers of preoperative and postoperative adjunctive medications were compared. To provide the raw data for analysis, autokeratometry and computerized corneal videokeratometry with the Topcon KR-8100P auto kerato refractometer were performed preoperatively and 5 days, and 2 and 6 months postoperatively. Autokeratometry results and simulated K-values of corneal topography were used to analyze surgically induced keratometric and topographic astigmatism, respectively.

Statistical analysis

Success was defined as final IOP ≤ 21 mmHg and one of the following: $\geq 20\%$ reduction of IOP or a reduction of 1 glaucoma medications with final IOP \leq baseline IOP if baseline IOP ≤ 21 mmHg. Failure was defined as a less than 20% decrease in IOP from baseline, no decrease in medications or additional need to medications or glaucoma surgery. For statistical analysis, analysis of variance (ANOVA) was used to compare changes in IOP and medications across different baseline IOP subgroups. Paired sample *t*-test was performed on the pre- and postoperative data.

Results

Table 1 shows phaco-Trabectome patient demographics. The mean preoperative IOP was 18.25 ± 3.28 mmHg with a mean of 2.52 ± 0.60 glaucoma medications (**Tables 2 and 3**). The range of postoperative IOP and number of medications at each time point are shown in **Tables 2 and 3** and **Fig. 1**. The data was available for all patients in month 6, however, 26% of patients were missed from the follow-up at one year. Success (i.e. 20% or greater drop in IOP or decrease in glaucoma medications without need for additional medications or glaucoma procedures, including laser trabeculoplasty) was 46.7% at 6 months (n = 30) and, 59.1% at 12 months (n = 22). The only significant intraoperative complication was hyphema that forms from blood reflux into Schlemm's from the aqueous collector channels which cleared within a few days after surgery. In the postoperative period, hyphema was the most frequent complication which was observed in three patients (10%). We had one case with an IOP spike of 3.3% which was controlled by medications, and one case of corneal edema (3.3%) which resolved spontaneously. There were no

Table 1
Patient demographics.

Parameter	Value
Patients (No. of patients/No. of eyes)	28/30
Age	
Mean \pm SD	69.90 \pm 7.5
Range	54–80
Sex, n (%)	
Male	17 (56.7%)
Female	13 (43.3%)
Cup-to-disc ratio, n (%)	
< 0.7	17 (56.7%)
0.7–0.8	12 (40.0%)
> 0.8	1 (3.3%)
Schaffer grade, n (%)	
I	0 (0.0%)
II	3 (10.0%)
III	27 (90.0%)
IV	0 (0.0%)
Visual field loss, n (%)	
Mild (MD 0 to –6.0 dB)	2 (6.7%)
Moderate (MD –6.0 to –12.0)	26 (86.7%)
Severe (MD > –12.0)	2 (6.7%)

No. = Number of eyes; MD = mean deviation;

Table 2
Intraocular pressure (IOP) preoperatively and postoperatively.

Time	Minimum IOP	Maximum IOP	Mean IOP (mmHg)	Reduction (%)	Number of eyes (n)
Preoperative	12	32	18.57 \pm 4.73	NA	30
1 day	8	20	14.21 \pm 3.41	20.21	29
5th day	9	28	13.59 \pm 3.53	22.61	29
2th month	10	20	14.10 \pm 2.47	20.26	30
6th month	10	20	13.90 \pm 2.50	21.35	30
12th month	9	19	13.86 \pm 2.66	24.77	22
18th month	12	20	14.31 \pm 2.18	19.48	13
24th month	12	15	13.33 \pm 1.51	28	6

Table 3
Number of glaucoma medications preoperatively and postoperatively.

Time	Mean	Minimum	Maximum	Reduction (%)	Number of eyes (n)
Preoperative	2.48 \pm 0.58	0	3	NA	27
5 day	1.00 \pm 0.00	1	1	56.41	26
2 month	1.10 \pm 0.55	0	2	52.47	27
6 month	0.87 \pm 0.43	0	2	61.73	27
12 month	1.00 \pm 0.62	0	2	57.02	19
18 month	1.00 \pm 0.58	0	2	55.56	12
24 month	1.00 \pm 0.00	1	1	55.56	6

complications such as hypotony, choroidal effusion or hemorrhage, aqueous misdirection, infection, bleb formation or wound leaks or cystoid macular edema.

Table 4 shows an analysis of IOP and glaucoma medication reduction stratified by baseline IOP level. Patients were separated into low pressure (<21 mmHg) group and high pressure (\geq 21 mmHg) group based on baseline IOP. The high pressure group had a statistically significant greater decrease in IOP level. No significant difference in medications drop was observed between the two groups (**Fig. 2** and **Table 4**).

The visual acuity (LogMar values) level from the preoperative period was statistically significantly different throughout follow-up. The preoperative BCVA (LogMar) was 0.68 ± 0.26 and was improved postoperatively to 0.26 ± 0.19 , 0.18 ± 0.13 , 0.17 ± 0.13 , 0.11 ± 0.12 , 0.13 ± 0.081 at 5 days and 2, 6, 12, and 24 months, respectively (P < 0.01).

The mean keratometry decreased slightly 2 months postoperatively and remained stable to 6 months postoperation. Changes in mean keratometry between preoperative and postoperative examinations were not statistically significant (P = 0.13). The mean surgical induced astigmatism (absolute keratometric changes) was 0.38 ± 0.28 D.

As mentioned before, 44 patients with only phaco surgery served as the control group for IOP comparison after 2 months. In the phaco group, the mean age was 63.36 ± 11.48 with a mean IOP of 14.73 ± 2.49 mmHg before surgery. Mean IOP was significantly different at baseline between these two groups because all cases in the phaco-Trabectome group had uncontrolled glaucoma (P < 0.05). IOP was reduced to 12.3 ± 2.5 mmHg two months after surgery, but this difference was not significant in contrast to the phaco-Trabectome group (**Fig. 3**). The decrease in IOP after 2 months in the phaco-Trabectome group was 4.4 ± 5.1 mmHg and 2.45 ± 2.19 mmHg in the phaco-group (P < 0.04).

Discussion

Glaucoma is the second cause of irreversible blindness in the world.¹ Glaucoma management has evolved during the past decade by the introduction of new methods of surgical techniques and medications. Glaucoma and cataract are common in older patients.² Although phacoemulsification in combination with trabeculectomy is effective for controlling pressure, complications such as hypotony, choroidal effusion and hemorrhage, leaking blebs, and endophthalmitis tend to

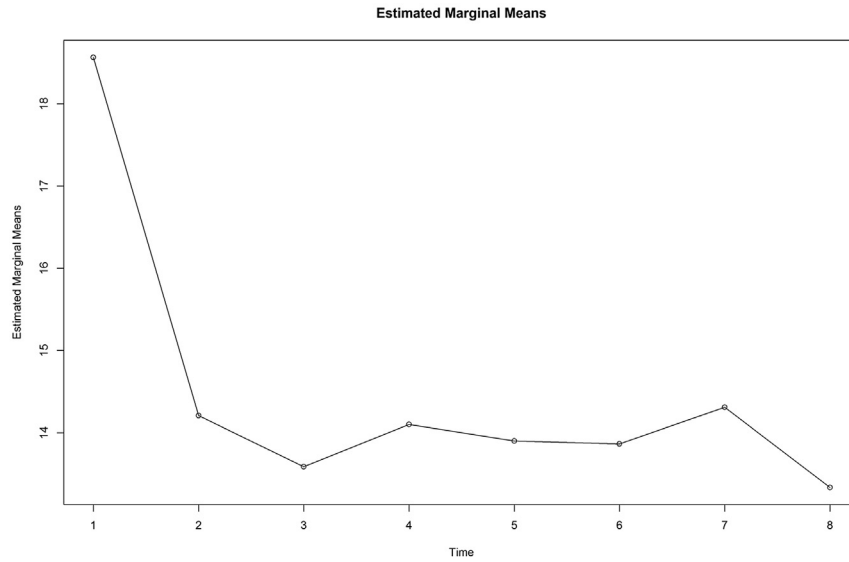


Fig. 1. Decreasing trend of intraocular pressure (IOP) during follow-up at 8 time points after surgery (from left, first day, 5th day, 2, 5, 6, 12, 18 and 24 months).

Table 4
Reduction in intraocular pressure (IOP) stratified by baseline IOP.

Time	Reduction (%)		P-value
	Low pressure (baseline IOP <21 mmHg)	High pressure (baseline IOP ≥21 mmHg)	
First day	15.04	40.03	0.02
Day 5	15.88	48.39	<0.01
Month 2	14.46	43.43	<0.01
Month 5	15.88	48.39	<0.01
Month 6	15.1	46.38	<0.01
Month 12	16.88	51.6	<0.01
Month 18	11.32	46.71	<0.01
Month 24	16.5	51	0.04

occur.^{7,8} Cataract surgery alone in glaucoma patients lowers IOP by 2–4 mmHg for a couple years.^{14–16} Even though phaco can reduce IOP, there is strong evidence for better long-term control of IOP in glaucoma patients with combined glaucoma surgery (trabeculectomy) and cataract extraction compared with cataract surgery alone.^{17,18}

A combination of phaco with new surgical techniques such as Trabectome, endoscopic cyclophotocoagulation (ECP), Solx Gold shunt, canaloplasty or express shunt result in a lower rate of complications.^{9–12} Given that Trabectome does not require the use of antifibrotic agents, risks associated with the use of mitomycin-C and 5-fluorouracil are therefore eliminated. Because the ab-interno approach of Trabectome completely spares the conjunctiva, any future standard filtering procedures remain available options if needed.¹⁹

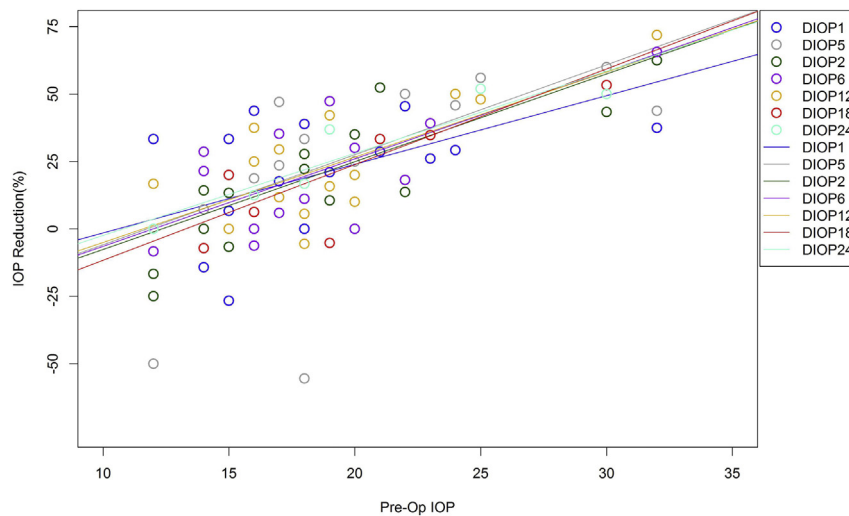


Fig. 2. Dot plot with fitted lines for all of the intraocular pressure (IOP) reduction (DIOP) at 8 time points after surgery (first day, 5th day, 2, 5, 6, 12, 18 and 24 months).

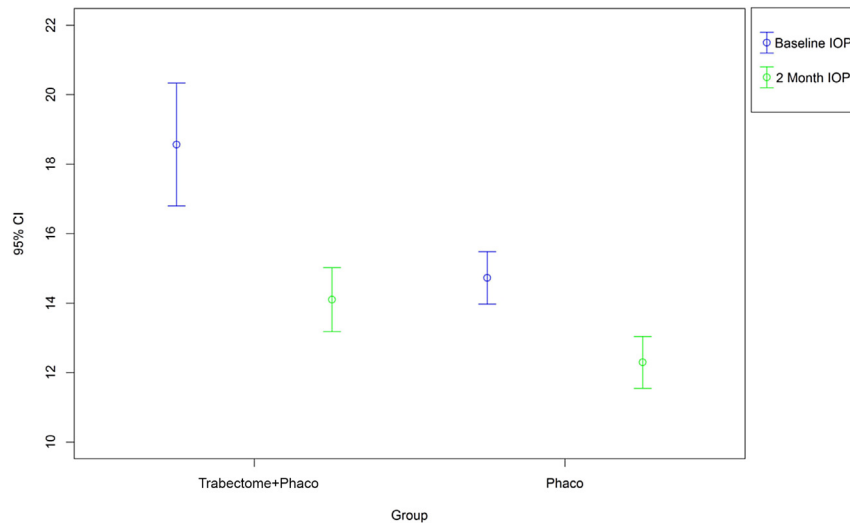


Fig. 3. Comparison of intraocular pressure (IOP) reduction between the two groups at 2 months after surgery.

In our study, the main outcome measurement was a change in IOP after the operation. The mean preoperative IOP was reduced from 18.2 ± 3.2 mmHg to 14.5 ± 2.3 mmHg at 6 months, and 13.5 ± 2.5 mmHg at 12 months.

Minckler et al reported that for 45 patients undergoing combined Trabectome and cataract extraction, the baseline IOP of 20.0 ± 6.2 mmHg was decreased to 15.9 ± 3.3 mmHg (18%), and medications decreased from 2.63 ± 1.12 to 1.50 ± 1.36 at 12 months.²⁰ In our study, 46.7% showed a reduction in the number of medications from 3 to 1 after 12 months of follow-up. In a study of 538 patients that had Trabectome surgery alone and 290 patients that had phaco combined, Mosaed et al reported a 31% IOP reduction and a 28% drop in medication usage in the Trabectome only group at 1 year of follow-up. In the combined group, a 18% IOP reduction and 33% drop in medication were reported.²¹ In a prospective case series comprised of 304 eyes with open-angle glaucoma and cataract, Francis et al reported a mean preoperative IOP 20.0 ± 6.3 mmHg preoperatively that decreased to 15.5 ± 2.9 mmHg at one year after combined Trabectome and phacoemulsification surgery. The glaucoma medications dropped from mean 2.56 ± 1.13 to a mean 1.44 ± 1.29 at one year.¹² In our study, glaucoma medication decreased from 2.48 ± 0.58 before surgery to 0.95 ± 0.38 at 6 months. At 12 months, the number of medications was 1.14 ± 0.53 . In the phaco group, IOP decreased from baseline, but the change was not significant compared to the phaco-Trabectome group.

The most common complication reported in the study of Francis et al was blood reflux, which was observed in 78.4% of patients.¹² Blood reflux was observed in 90.0% our patients.

Meanwhile, we observed significant improvement in VA and a small amount of induced astigmatism after surgery. Trabectome produces, during the early postoperative period, a reduction in the vertical corneal radius and results in with-the-rule (WTR) a change in corneal astigmatism.^{22,23} We observed less astigmatism in those patients who had combined phacoemulsification and ab-interno Trabectome

surgeries than those in reported trabectome studies using a Cairns-type technique.^{24,25}

When considering the cost associated with glaucoma medications and challenges of medical compliance, it is certainly noteworthy that combined surgery reduced medication use by about 57% in 12 months of follow-up in our study. Complications observed after surgery such as hyphema were transient, and complications such as hypotony and choroidal effusion were not observed in our study.

It seems that the combination of phaco with ab-interno Trabectome may be a good option for patients with mild to moderate glaucoma and cataract. It not only decreases IOP but also dependence on glaucoma medications.

The study had several limitations including small sample size, absence of a matched control group and short-term follow-up. Unfortunately, the data of about 26% of our patients was not available at one year of follow-up. Also, we did not have information of the Phaco group in the long-term as a parallel group. Considering that the primary goal of any glaucoma surgery is the reduction of IOP with the lowest requirement for adjunctive glaucoma medications while providing minimal risk of complications, our results showed that combining phacoemulsification and Trabectome lowered IOP and medication use, with early visual rehabilitation and stable refractive outcomes in the majority of our patients.

References

1. Quigley HA, Broman AT. Number of people with glaucoma world wide in 2010 and 2020. *Br J Ophthalmol.* 2006;90:262–267.
2. Xu L, Wang Y, Li Y, et al. Causes of blindness and visual impairment in urban and rural areas in Beijing: the Beijing Eye Study. *Ophthalmology.* 2006;113(7):1134–1141.
3. Hennis AJ, Wu SY, Nemesure B, et al. Nine year incidence of visual impairment in the Barbados Eye Studies. *Ophthalmology.* 2009;116(8):1461–1468.
4. Chandrasekaran S, Cumming RG, Rochtchina E, Mitchell P. Associations between elevated intraocular pressure and glaucoma, use of glaucoma

- medications, and 5-year incident cataract: the Blue Mountains Eye Study. *Ophthalmology*. 2006;113(3):417–424.
5. Shingleton BJ, Wooler KB, Bourne CI, O'Donoghue MW. Combined cataract and trabeculectomy surgery in eyes with pseudoexfoliative glaucoma. *J Cataract Refract Surg*. 2011;37(11):1961–1970.
 6. Krupin T, Feitl M, Bishop K. Postoperative intraocular pressure rise in open angle glaucoma patients after cataract or combined cataract-filtration surgery. *Ophthalmology*. 1989;96:579–584.
 7. Zacharia PT, Schuman JS. Combined phacoemulsification and trabeculectomy with mitomycin-C. *Ophthalmic Surg Lasers*. 1997;28(9):739–744.
 8. Belyea DA, Dan JA, Lieberman MF, Stamper RL. Midterm follow-up results of combined phacoemulsification, lens implantation, and mitomycin-C trabeculectomy procedure. *J Glaucoma*. 1997;6(2):90–98.
 9. Matlach J, Freiberg FJ, Leippi S, et al. Comparison of phacoemulsification-trabeculectomy versus phacoemulsification-canaloplasty in the treatment of patients with concomitant cataract and glaucoma. *BMC Ophthalmol*. 2013;29(13):1.
 10. Rosdahl JA, Chen TC. Combined cataract and glaucoma surgeries: traditional and new combinations. *Int Ophthalmol Clin*. 2010 Winter; 50(1):95–106.
 11. Shingleton B, Tetz M, Korber N. Circumferential viscodilation and tensioning of Schlemm canal (canaloplasty) with temporal clear corneal phacoemulsification cataract surgery for open-angle glaucoma and visually significant cataract: one-year results. *J Cataract Refract Surg*. 2008; 34:433–440.
 12. Francis BA, Minckler D, Dustin L, et al. Combined cataract extraction and trabeculectomy by the internal approach for coexisting cataract and open-angle glaucoma: initial results. *J Cataract Refract Surg*. 2008;34: 1096–1103.
 13. Francis BA, See RF, Rao NA, et al. Ab interno trabeculectomy: development of a novel device (Trabectome) and surgery for open-angle glaucoma. *J Glaucoma*. 2006;15:68–73.
 14. Pohjalainen T, Vesti E, Uusitalo RJ, Laatikainen L. Phacoemulsification and intraocular lens implantation in eyes with open angle glaucoma. *Acta Ophthalmol Scand*. 2001;79:313–316.
 15. Kim D, Doyle J, Smith M. Intraocular pressure reduction following phacoemulsification cataract extraction with posterior chamber lens implantation in glaucoma patients. *Ophthalmic Surg Lasers*. 1999;30: 37–40.
 16. Shingleton BJ, Pasternack JJ, Hung JW, O'Donoghue MW. Three and five year changes in intraocular pressures after clear corneal phacoemulsification in open angle glaucoma patients, glaucoma suspects, and normal patients. *J Glaucoma*. 2006;15:494–498.
 17. Mansberger SL, Gordon MO, Jampel H, et al. Reduction in intraocular pressure after cataract extraction: the OcularHypertension Treatment Study. *Ophthalmology*. 2012;119(9):1826–1831.
 18. Friedman DS, Jampel HD, Lubomski LH, et al. Surgical strategies for coexisting glaucoma and cataract: an evidence based update. *Ophthalmology*. 2002;109:1902–1915.
 19. Palanca-Capistrano AM, Hall J, Cantor LB, et al. Long-term outcomes of intraoperative 5-fluorouracil versus intraoperative mitomycin C in primary trabeculectomy surgery. *Ophthalmology*. 2009 Feb;116(2):185–190.
 20. Minckler D, Mosaed S, Dustin L, Francis B. Trabectome (trabeculectomy by internal approach): additional experience and extended follow up. *Am Ophthalmol Soc*. 2008;106:149–160.
 21. Mosaed S, Rhee DJ, Filippopoulos T. Trabectome outcomes in adult open-angle glaucoma patients: one-year follow-up. *Clin Surg Ophthalmol*. 2010;28:8.
 22. Kook MS, Kim HB, Lee SU. Short-term effect of mitomycin-C augmented trabeculectomy on axial length and corneal astigmatism. *J Cataract Refract Surg*. 2001;27:518–523.
 23. Egrilmez S, Ates H, Nalcaci S, et al. Surgically induced corneal refractive change following glaucoma surgery: nonpenetrating trabecular surgeries versus trabeculectomy. *J Cataract Refract Surg*. 2004;30: 1232–1239.
 24. Rosen WJ, Mannis MJ, Brandt JD. The effect of trabeculectomy on corneal topography. *Ophthalmic Surg*. 1992;23(6):395–398.
 25. Dietze PJ, Oram O, Kohnen T, et al. Visual function following trabeculectomy: effect on corneal topography and contrast sensitivity. *J Glaucoma*. 1997;6:99–101.