



Clinical course of pituitary function and image in IgG4-related hypophysitis

Takatoshi Anno¹, Fumiko Kawasaki¹, Maiko Takai¹, Ryo Shigemoto¹, Yuki Kan¹, Hideaki Kaneto², Tomoatsu Mune², Kohei Kaku¹ and Niro Okimoto¹

¹Department of General Internal Medicine 1, Kawasaki Medical School, Okayama, Japan and ²Department of Diabetes, Metabolism and Endocrinology, Kawasaki Medical School, Kurashiki, Japan

Correspondence
should be addressed
to T Anno

Email
anno-t@umin.ac.jp

Summary

A 76-year-old man had a hypopituitarism including adrenal insufficiency, hypogonadism and hypothyroidism. Based on various findings including the swelling of the pituitary gland, increase of serum IgG4 level and abundant IgG4-positive plasma cell infiltration in immunostaining of the pituitary gland, we diagnosed this subject as IgG4-related hypophysitis. In general, a high-dose glucocorticoid treatment is effective for IgG4-related disease. His clinical symptom, laboratory data and adrenal insufficiency were almost improved without any therapy. The serum IgG4 level was decreased and pituitary size was normalized with hydrocortisone as physiological replacement. This case report provides the possibility that IgG4 level is decreased spontaneously or with physiological dose of glucocorticoid therapy.

Learning points:

- We performed the pituitary gland biopsy and histochemical examination glucocorticoid therapy in a subject with IgG4-related hypophysitis.
- This case report provides the possibility that IgG4 level is decreased spontaneously or with a physiological dose of glucocorticoid therapy. We reported the clinical course of IgG4-related hypophysitis without a high-dose glucocorticoid treatment, although there were a few reports about the retrospective examination.
- Although the patient had still higher IgG4 level compared to normal range, his clinical symptom disappeared and his laboratory data were improved.
- We should keep in mind the possibility of IgG4-related hypophysitis when we examine one of the uncertain causes of a hypopituitarism including adrenal insufficiency, hypogonadism and hypothyroidism.

Background

IgG4-related disease is a multi- or single-organ disorder accompanied by the increase of serum IgG4 level (1). Recently, clinical characteristics of IgG4-related hypophysitis have emerged as a part of systemic IgG4-related disease (2). To diagnose IgG4-related disease, histopathology is the key, and one of the major features of this disease is a dense lymphoplasmacytic infiltrate rich in IgG4-positive plasma cells. The recent reports showed that IgG4-related hypophysitis might be detected in 30% of hypophysitis cases and 4% of all hypopituitarism

and/or diabetes insipidus (DI) cases (3). However, the pathogenesis of IgG4-related hypophysitis remains unclear due to the limited number of case reports because of certain limitations in this technique. Generally, it has been thought that a high-dose glucocorticoid treatment is effective for IgG4-related diseases, and thus, many clinicians have started the therapy with prednisolone in a dose of 0.6–1.0 mg/kg daily. After 2–4 weeks, the dose is tapered by 5 mg every 1–2 weeks according to clinical responses (4).



Case presentation

A 76-year-old man was hospitalized due to persistent general fatigue and appetite loss since approximately 2 months before. On admission, his vital signs were normal (temperature: 36.6°C; blood pressure was 98/50mmHg and heart rate was 62beats/min). He had eosinophilia (1098/ μ L, 19.1%) and hyponatremia (Na: 129mEq/L (reference range: 137–146mEq/L)), and his fasting plasma glucose level was 69mg/dL. Laboratory analyses showed this patient had a hypopituitarism including adrenal insufficiency (ACTH: 13.2pg/mL (7.2–63.3pg/mL), cortisol: 1.2 μ g/dL (4.5–21.1 μ g/dL)), hypogonadism (LH <0.10IU/mL (0.79–5.72IU/mL), FSH: 2.13IU/mL (2.00–8.30IU/mL), testosterone \leq 0.03ng/mL (1.31–8.71ng/mL)), hypothyroidism (TSH: 0.036 μ IU/mL (0.400–6.000 μ IU/mL), FT4: 0.56ng/mL (0.80–1.60ng/dL)) and elevated prolactin level (PRL: 19.3ng/mL (3.6–12.8ng/mL)). The posterior pituitary hormone antidiuretic hormone (ADH) level (1.0pg/mL (0.0–4.2pg/mL)), the passage of volumes (1900mL/24h), the urine osmolality (264mosmol/kg) and the serum osmolality (291mosmol/kg) were within normal range, and he did not have diabetes insipidus. Serum pituitary cell antibody was negative. We examined the hormone-loading tests 1 week after admission. As shown in Fig. 1A, TSH response to TRH was absent or low. Cortisol response to CRH was also not preserved in this subject although ACTH response to CRH was observed (Fig. 1B and C). In addition, in GHRP-2 test, GH response was also poor in this subject (peak GH level: 4.55ng/mL). Serum IgG and IgG4 levels were markedly elevated: 2800mg/dL (1000–1800mg/dL) and 1030mg/dL (4.8–105.0mg/dL) respectively. Furthermore, pituitary-enhanced magnetic resonance imaging (MRI) showed swelling of the stalk and anterior lobe of his pituitary (Fig. 2A). Next, we performed a biopsy from the pituitary gland via the sphenoid sinus 2 weeks after admission. Immunohistochemical staining of the two part specimens of anterior gland revealed abundant IgG4-positive plasma cell infiltration (Fig. 3A and B), although we failed to evaluate the specimens of dura mater due to tissue degradation during the process of sample collection. Based on such findings, we finally diagnosed him as having IgG4-related hypophysitis. In this case, any other organ was not involved in IgG4-related disease including autoimmune pancreatitis, Mikulicz's disease and there was not any other autoimmune disease (ANA <5.0 (–), rheumatoid factor <15IU/mL, anti-TPO antibodies

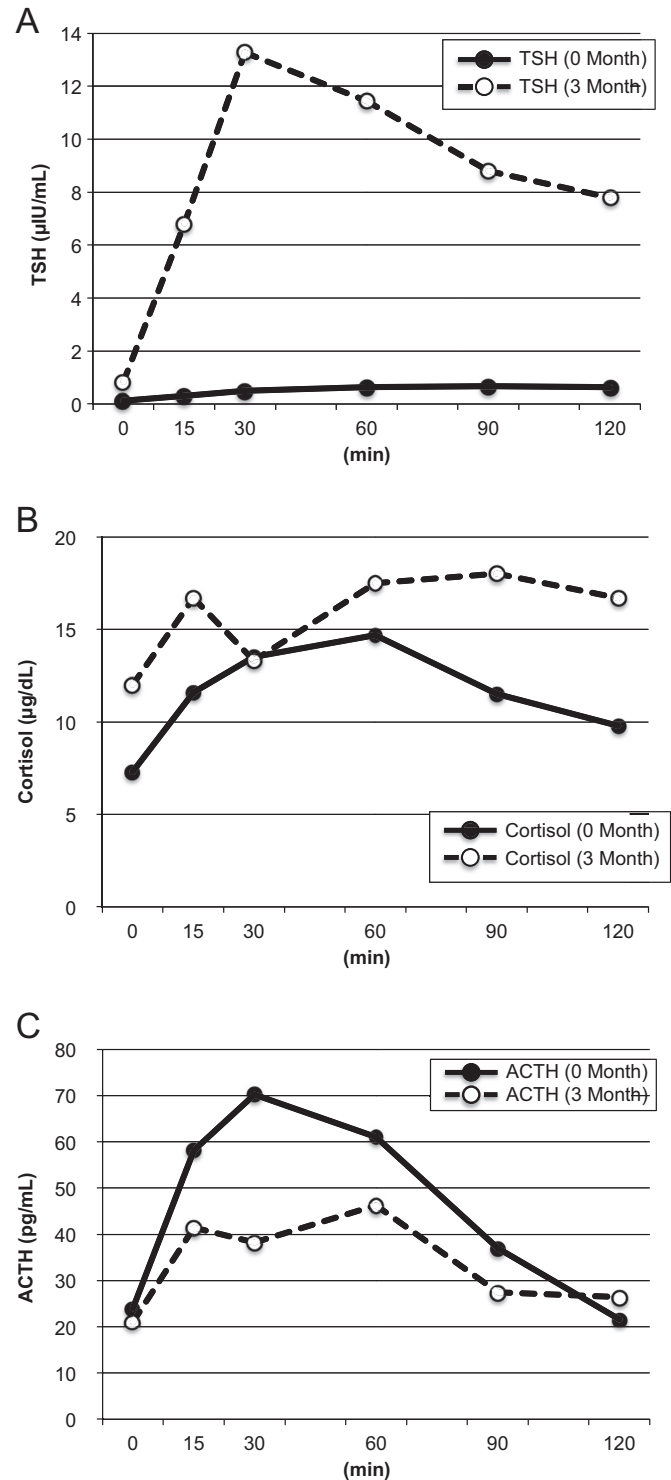


Figure 1 Anterior pituitary tolerance tests. (A) Responses of TRH to i.v. injection of TRH (500 μ g). (B) Responses of adrenal hormones to i.v. injection of CRH (100 μ g). (C) Responses of ACTH to i.v. injection of CRH (100 μ g).

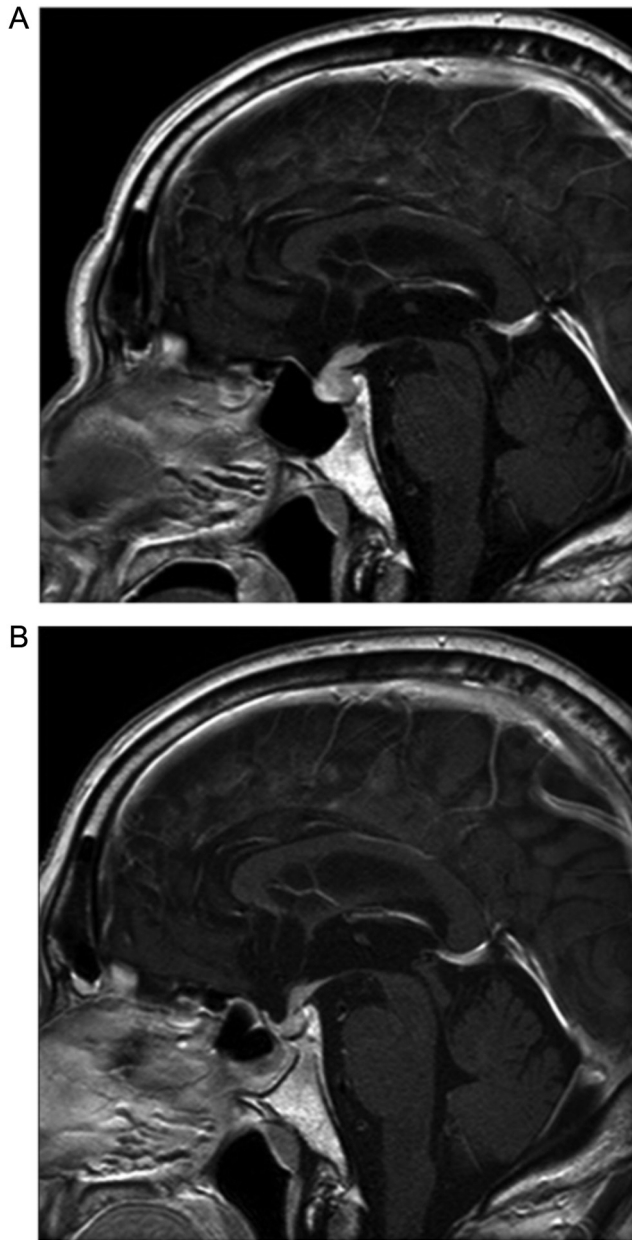


Figure 2
Enhanced magnetic resonance imaging (MRI) with T1-weighted image. (A) Swelling of the stalk and anterior lobe of patient pituitary on admission. (B) The improvement of such swelling of them 3 months later.

9.9 IU/mL, anti-thyroglobulin antibodies <10.0 IU/mL, SS-A/Ro antibodies <1.0 U/mL, SS-B/La antibodies <1.0 U/mL and serum pituitary cell antibody negative).

In general, clinical manifestations of IgG4-related disease respond well to glucocorticoid therapy. Therefore, glucocorticoid dose is usually tapered after a few days according to clinical response in each patient. To the best of our knowledge, however, no randomized treatment

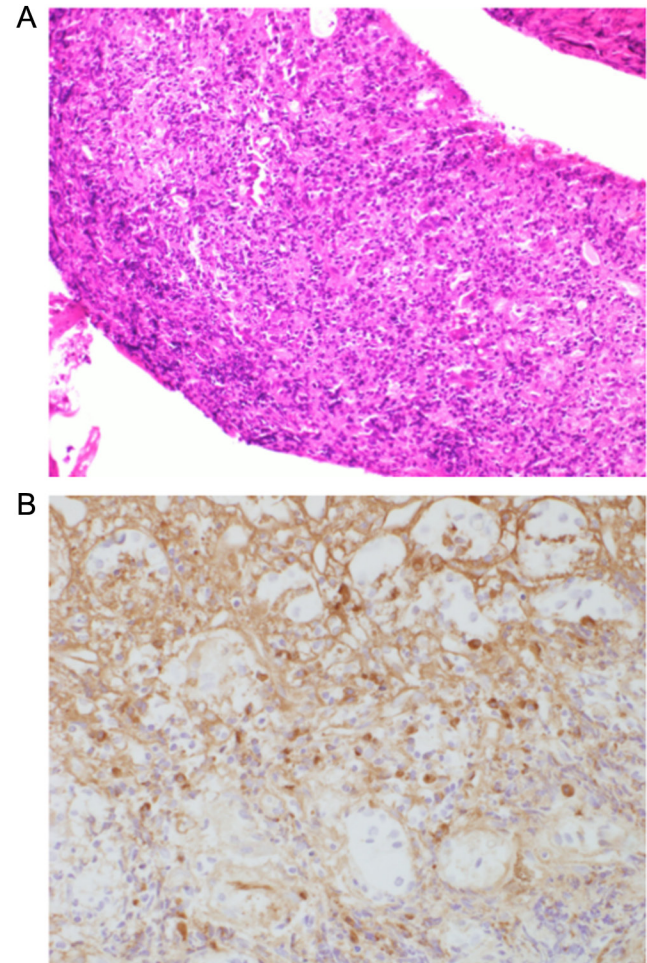


Figure 3
Histopathological findings. (A) The hematoxylin and eosin staining of the pituitary gland (magnification $\times 20$). (B) IgG4 staining of the pituitary gland ($\times 40$). There was a marked infiltration of lymphocyte and plasma cells. There was about 30% of IgG4-positive plasma cells, which were accounted for IgG-positive cells.

trials have been done yet, although there were a few reports about the retrospective examination. Therefore, we do not have enough information about the best therapy for IgG4-related hypophysitis as well as the clinical course of pituitary function and image in IgG4-related hypophysitis.

In this case, his clinical symptoms (general fatigue and appetite loss) were markedly reduced, and some laboratory data were normalized as follows: fasting plasma glucose, 91 mg/dL and Na, 138 mEq/L. Therefore, although this subject showed hypopituitarism including adrenal insufficiency, it seemed that the symptoms were markedly reduced before starting steroid therapy. These data suggest the possibility that the symptoms of IgG4-



Table 1 Endocrine hormone levels on admission and 3 months later.

	On admission	3 months later	Normal range
ACTH, pg/mL	13.2	21.0	7.2–63.2
Cortisol, µg/dL	1.2	12.0	4.5–21.1
TSH, µIU/mL	0.036	0.832	0.400–6.000
FT4, ng/dL	0.56	0.92	0.80–1.60
LH, µIU/mL	<0.10	<0.10	0.79–5.72
FSH, µIU/mL	2.13	0.63	2.00–8.30
Testosterone, ng/mL	<0.03	N.D.	1.31–8.71
GH, ng/mL	0.83	0.27	<0.13
IGF-1, ng/mL	40	68	50–181
PRL, ng/mL	19.3	7.0	3.6–12.8
ADH, pg/mL	1.0	1.0	0.0–4.2

related hypophysitis are spontaneously reduced without steroid therapy. In consideration of such improvement, we started 10mg/day of hydrocortisone as physiological replacement and 25µg/day of levothyroxine and continued the same dose for 3 months. Pituitary-enhanced MRI taken 3 months later showed a marked improvement (Fig. 2B). Serum IgG and IgG4 levels were decreased as follows: IgG: 2800mg/dL; IgG4: 1030mg/dL (at the beginning); IgG: 1778mg/dL; IgG4: 527mg/dL (1 month later); IgG: 1924mg/dL; IgG4: 674mg/dL (2 months later); IgG: 2013mg/dL and IgG4: 580mg/dL (3 months later). Consequently, as shown in Table 1, various endocrine hormone levels such as ACTH, cortisol, TSH, FT4 and PRL levels were normalized, although LH, FSH and testosterone levels remained low. Furthermore, as shown in Fig. 1A, TSH response to TRH was markedly improved in the hormone-loading tests.

Discussion

Herein we report a case of IgG4-related hypophysitis that we diagnosed with the pituitary gland biopsy. In this case, his clinical symptoms and adrenal insufficiency were improved without any therapy. Therefore, we did not perform a high-dose glucocorticoid treatment. Pituitary-enhanced MRI taken 3 months later showed a marked improvement. The anterior pituitary response to TRH was improved, and serum IgG and IgG4 levels were decreased. The response of cortisol to CRH also became better 3 months later, although the response was not completely normalized. Indeed, cortisol level at 90 min was increased to 18.0µg/dL, but cortisol level at 30 or 60 min was <18.1µg/dL, suggesting that this subject still had mild adrenal insufficiency (5).

The course of this patient provides three important clinical suggestions. First, we performed the pituitary gland biopsy and histochemical examination in a subject with IgG4-related hypophysitis. Second, we reported the clinical course of IgG4-related hypophysitis without a high-dose glucocorticoid treatment. Three month later, serum IgG and IgG4 levels were decreased, and pituitary size was normalized. Central adrenal insufficiency and thyroid insufficiency were also improved. Most of the cases with IgG4-related hypophysitis are accompanied by complications of pituitary insufficiency. On the other hand, Hattori *et al.* reported a case of IgG4-related hypophysitis without pituitary insufficiency (6). In this case, he had a hypopituitarism including adrenal insufficiency, hypogonadism and hypothyroidism; however, 3 months later, his IgG4 level was decreased spontaneously or with a physiological dose of glucocorticoid therapy. These reports suggested that IgG4-related hypophysitis has a variety of clinical conditions. We think that our case shows the time course of IgG4-related hypophysitis from the beginning to the improvement. Third, although the patient had still higher IgG4 level compared with normal range, his clinical symptoms disappeared and his laboratory data were improved. We think that after the disappearance of symptoms it is difficult to diagnose IgG4-related hypophysitis. In fact, the case reports of Hattori and coworkers showed that he had higher IgG4 levels without pituitary insufficiency (6). This case report provides the possibility that IgG4 level is decreased spontaneously or with a physiological dose of glucocorticoid therapy. Therefore, when we examine subjects with central adrenal insufficiency and/or thyroid insufficiency after the normalization of serum IgG4 level, it would be very difficult to diagnose IgG4-related hypophysitis.

There are some limitations in this case report. First, although we did not perform a high-dose glucocorticoid treatment, we used a physiological dose of glucocorticoid. Therefore, we cannot exclude the possibility that such treatment with a physiological dose of glucocorticoid facilitated the decrease in IgG4 level. We think it is possible that IgG4 level was not spontaneously recovered in this subject. Second, although IgG4 level was markedly decreased during the process, it was still higher compared to its normal range. Therefore, we cannot conclude at this point that IgG4-related disease in this subject was completely recovered. Further observation and/



or evaluation for a longer period would be necessary to conclude our hypothesis.

In conclusion, we should keep in mind the possibility of IgG4-related hypophysitis when we examine one of the uncertain causes of a hypopituitarism including adrenal insufficiency, hypogonadism and hypothyroidism.

Declaration of interest

H K has received honoraria for lectures and received scholarship grants from Sanofi, Novo Nordisk, Lilly, Boehringer Ingelheim, MSD, Takeda, Ono Pharma, Daiichi Sankyo, Sumitomo Dainippon Pharma, Mitsubishi Tanabe Pharma, Pfizer, Kissei Pharma, AstraZeneca, Astellas, Novartis, Kowa, Chugai and Taisho Pharma. K K has been an advisor to, received honoraria for lectures from and received scholarship grants from Novo Nordisk Pharma, Sanwa Kagaku Kenkyusho, Takeda, Taisho Pharmaceutical Co., Ltd, MSD, Kowa, Sumitomo Dainippon Pharma, Novartis, Mitsubishi Tanabe Pharma, AstraZeneca, Nippon Boehringer Ingelheim Co., Ltd, Chugai, Daiichi Sankyo and Sanofi.

Funding

This research did not receive any specific grant from any funding agency in the public, commercial or not-for-profit sector.

Patient consent

Written informed consent was obtained from the patient.

Author contribution statement

T A researched data and wrote the manuscript. F K, M T, R S and Y K researched data and contributed to discussion. H K, T M, K K and N O wrote and reviewed the manuscript.

References

- 1 Stone JH, Zen Y & Deshpande V 2012 IgG4-related disease. *New England Journal of Medicine* **366** 539–551. (doi:10.1056/NEJMra1104650)
- 2 Leporati P, Landek-Salgado MA, Lupi I, Chiovato L & Caturegli P 2011 IgG4-related hypophysitis: a new addition to the hypophysitis spectrum. *Journal of Clinical Endocrinology and Metabolism* **96** 1971–1980. (doi:10.1210/jc.2010-2970)
- 3 Bando H, Iguchi G, Fukuoka H, Taniguchi M, Yamamoto M, Matsumoto R, Suda K, Nishizawa H, Takahashi M, Kohmura E, *et al.* 2013 The prevalence of IgG4-related hypophysitis in 170 consecutive patients with hypopituitarism and/or central diabetes insipidus and review of the literature. *European Journal of Endocrinology* **170** 161–172. (doi:10.1530/EJE-13-0642)
- 4 Kamisawa T, Zen Y, Pillai S & Stone JH 2015 IgG4-related disease. *Lancet* **385** 1460–1471. (doi:10.1016/S0140-6736(14)60720-0)
- 5 Fleseriu M, Hashim IA, Karavitaki N, Melmed S, Murad MH, Salvatori R & Samuels MH 2016 Hormonal replacement in hypopituitarism in adults: an Endocrine Society Clinical Practice Guideline. *Journal of Clinical Endocrinology and Metabolism* **101** 3888–3921. (doi:10.1210/jc.2016-2118)
- 6 Hattori Y, Tahara S, Ishii Y, Kitamura T, Inomoto C, Osamura RY, Teramoto A & Morita A 2013 A case of IgG4-related hypophysitis without pituitary insufficiency. *Journal of Clinical Endocrinology and Metabolism* **98** 1808–1811. (doi:10.1210/jc.2013-1088)

Received in final form 28 March 2017

Accepted 31 March 2017