

Case Report

Detecting Foreign Bodies in a Head Laceration

Thomas R. Fowler, Steven J. Crellin, and Marna Rayl Greenberg

Department of Emergency Medicine, Lehigh Valley Hospital, USF Morsani College of Medicine, CC & I-78, Allentown, PA 18103, USA

Correspondence should be addressed to Marna Rayl Greenberg; mrgdo@ptd.net

Received 23 November 2014; Accepted 21 January 2015

Academic Editor: Aristomenis K. Exadaktylos

Copyright © 2015 Thomas R. Fowler et al. This is an open access article distributed under the Creative Commons Attribution License, which permits unrestricted use, distribution, and reproduction in any medium, provided the original work is properly cited.

Open wounds represent a potential area of medicolegal risk if foreign bodies are not identified prior to wound closure. The importance of imaging of lacerations was underscored by a recent case where a 20-year-old male collided with a friend's mouth on a trampoline sustaining a simple, superficial scalp laceration. The wound was evaluated in typical fashion including irrigation and local exploration and was prepared for closure. The friend was then evaluated and noted to have multiple extensive dental fractures. An increased index of suspicion generated further evaluation of the first patient's wound. Plain radiography obtained of the first patient's skull was noted to have bony foreign bodies consistent with teeth, which were then removed after further exploration. Superficial wounds are common and complications arising from retained foreign bodies are a potential source of substantial morbidity and consequently medical litigation. This case serves as a reminder to be vigilant and maintain a high index of suspicion regarding the potential for foreign body.

1. Introduction

Open wounds account for approximately 17.9% of all ED visits [1] and represent a potential area of medicolegal risk, especially when foreign bodies are not identified prior to wound closure. Complications such as dehiscence and infection from such wounds represent 14% of lawsuits and 5% of all legal settlements [2]. Standard evaluation of open wounds includes a thorough history, physical examination, wound exploration with irrigation, and occasionally debridement. Imaging should be strongly considered whenever there is concern for a potential foreign body.

2. Case Report

The importance of imaging of lacerations was underscored by a recent case where a 20-year-old male collided with a friend's mouth on a trampoline sustaining a simple, 2.6 cm by 0.5 cm superficial scalp laceration. The wound was evaluated in typical fashion including irrigation and local exploration and was prepared for closure. The friend was then evaluated and noted to have multiple extensive dental fractures. An increased index of suspicion generated further evaluation of the first patient's wound. Plain radiography obtained of the

first patient's skull was noted to have bony foreign bodies consistent with teeth, which were then removed after further exploration and without need for wound extension (Figure 1). The wound was then closed in standard fashion.

3. Discussion

Superficial wounds are common and complications arising from retained foreign bodies are a potential source of substantial morbidity and consequently medical litigation. In this case the foreign bodies were not readily visible even after a careful exploration. A high index of suspicion regarding the potential for foreign body is advised. Plain radiography is considered useful for viewing radiopaque foreign bodies such as metal, bone, teeth, pencil graphite, certain plastics, glass, gravel, stone, some fish spines, and wood [3]. Ultrasound may assist in detection of soft-tissue foreign bodies like glass, metals, plastics, stone, and wood with variable sensitivities because of variables like operator skill and the type of material of the foreign body [4, 5]. Other advanced imaging modalities, such as CT and MRI, may be appropriate depending on the clinical scenario. If the clinical scenario does not allow for imaging, the patient should receive explicit instructions

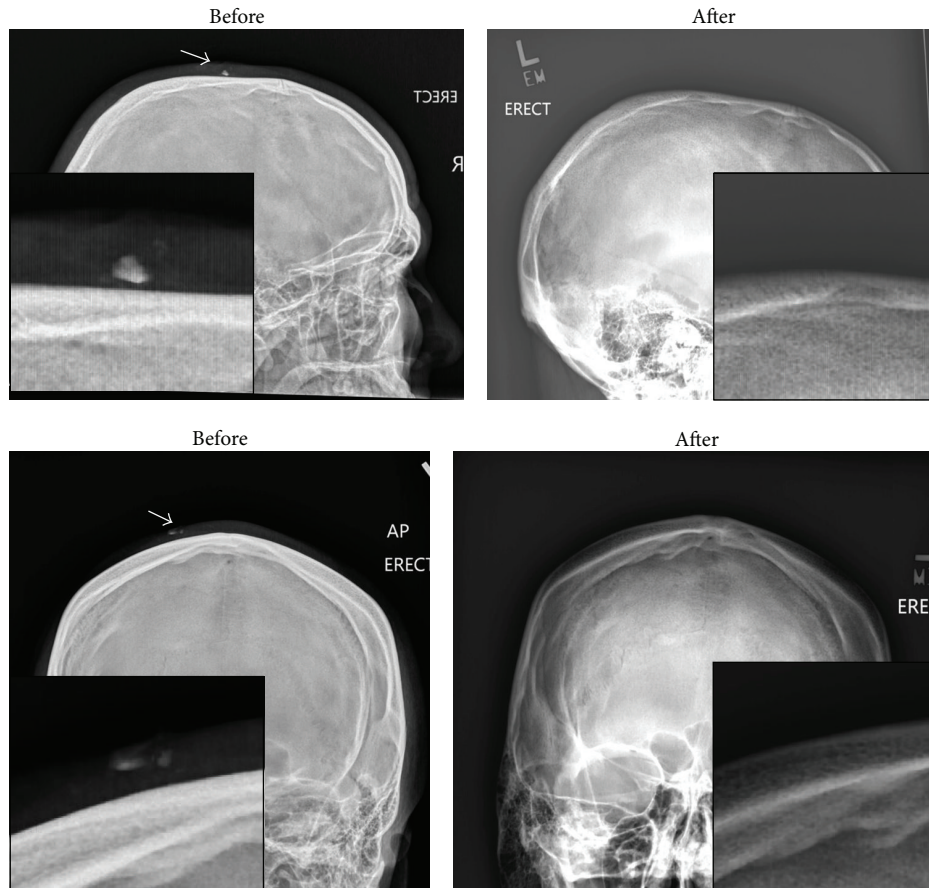


FIGURE 1: Before and after images of retained foreign bodies (fractured teeth).

about the possibility of retained foreign body and appropriate advice for follow-up and return.

This was a near miss event; to avoid it in the future, this case highlights the importance of constant vigilance for retained foreign bodies. It serves as a reminder to perform the appropriate radiographic investigation of simple lacerations prior to closure when the potential presence of foreign body exists.

Conflict of Interests

The authors declare that they have no conflict of interests.

References

- [1] US Department of Health and Human Services, Centers for Disease Control and Prevention, and National Center for Health Statistics, *Injury in the United States: 2007 Chartbook*, US Department of Health and Human Services, Centers for Disease Control and Prevention, National Center for Health Statistics, 2008.
- [2] C. D. Tibbles and W. Porcaro, "Procedural applications of ultrasound," *Emergency Medicine Clinics of North America*, vol. 22, no. 3, pp. 797–815, 2004.
- [3] O. Capellan and J. E. Hollander, "Management of lacerations in the emergency department," *Emergency Medicine Clinics of North America*, vol. 21, no. 1, pp. 205–231, 2003.
- [4] D. E. Manthey, A. B. Storrow, J. M. Milbourn, and B. J. Wagner, "Ultrasound versus radiography in the detection of soft-tissue foreign bodies," *Annals of Emergency Medicine*, vol. 28, no. 1, pp. 7–9, 1996.
- [5] G. W. Halaas, "Management of foreign bodies in the skin," *American Family Physician*, vol. 76, no. 5, pp. 683–688, 2007.