

Original Research Article

## The Usefulness of Preoperative Evaluation for Intractable Slow Transit Constipation by Computed Tomography

Hidejiro Kawahara<sup>1)</sup>, Nobuo Omura<sup>2)</sup> and Tadashi Akiba<sup>1)</sup>

1) Department of Surgery, Kashiwa Hospital, Jikei University School of Medicine, Chiba, Japan

2) Department of Surgery, Nishisaitama-chuo national Hospital, Saitama, Japan

### Abstract

**Objectives:** Total colectomy with ileorectal anastomosis is the gold standard surgical procedure for patients with slow transit constipation (STC). This operation's outcomes are highly variable; however, predictors of postoperative outcomes after surgical treatment of intractable STC remain unclear. This study aimed to clarify the usefulness of preoperative evaluation for intractable STC by computed tomography (CT) in predicting postoperative outcomes.

**Methods:** From January 2011 to December 2018, 22 patients with intractable STC underwent laparoscopic total colectomy with ileorectal anastomosis at the Kashiwa Hospital, Jikei University. They were divided into two groups, eighteen patients in the colonic inertia type (CI) group, and four patients in the spastic constipation type (SC) group, by preoperative CT according to specific criteria.

**Results:** There were no significant differences in the mean age, gender, mean operation time, or mean intraoperative blood loss. The SC group's postoperative hospital stay was significantly longer than that of the CI group. Postoperative gastric outlet obstruction occurred in two patients (11%) who underwent distal partial gastrectomy with R-Y reconstruction after the surgery in the CI group but no patients in the SC group. Postoperative pelvic outlet obstruction occurred in all four patients who underwent ileostomy within a year after surgery in the SC group but no patients in the CI group.

**Conclusions:** The outcomes of total colectomy in the treatment of intractable STC are highly variable. Preoperative evaluation for intractable STC by CT seems to be a useful predictor of postoperative outcomes.

### Keywords

slow transit constipation, total colectomy, computed tomography, colic inertia, pelvic outlet obstruction

J Anus Rectum Colon 2021; 5(2): 144-147

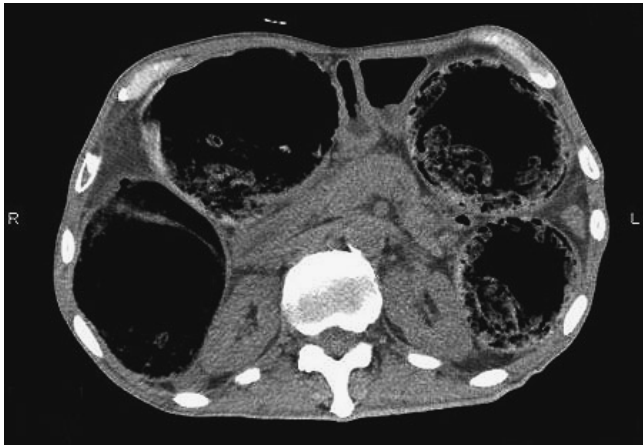### Introduction

Total colectomy with ileorectal anastomosis is the current gold standard surgical procedure for patients with slow transit constipation (STC)[1,2]. This operation's outcomes are highly variable in both satisfaction rates and the incidence of postoperative complications[3-6]. The predictors of postoperative outcomes after total colectomy in the treatment of intractable STC remain unclear. This study aimed to clarify

the usefulness of preoperative evaluation for intractable STC by computed tomography (CT) in predicting postoperative outcomes.

### Methods

The Ethics Committee for Biomedical Research of the Jikei Institutional Review Board approved the protocol [30-344 (9365)], and all patients or their family members pro-



**Figure 1.** Preoperative CT findings in the CI group. The CT revealed a dilated colon with a diameter of more than 1.5 times the vertebral body's diameter.

vided written informed consent to participate.

From January 2011 to December 2018, twenty-two patients with intractable STC underwent laparoscopic total colectomy with ileorectal anastomosis by our original procedure[7]. All patients' medical records were reviewed. The patients were divided into two groups, 18 in the colonic inertia type (CI) group, and 4 in the spastic constipation type (SC) group, by CT according to specific criteria.

#### *CT distinction criteria for the two groups*

The CI group was defined as those whose CT revealed a dilated colon with a diameter of more than 1.5 times the vertebral body's diameter in all the slices in which the colon was confirmed (Figure 1). The SC group was defined as those whose CT revealed a slightly dilated colon with 4–8 cm diameter spherical scybalum-like moniliforms, ranging from the cecum to the rectum (Figure 2).

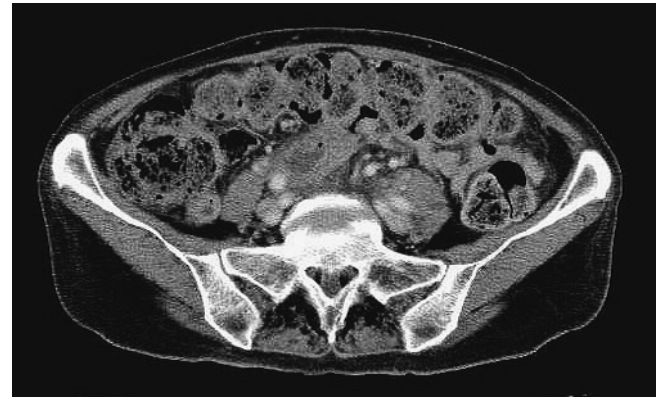
#### *Statistical analysis*

Continuous variables are expressed as means and ranges. The Wilcoxon rank-sum test was used to compare the continuous variables, and the Chi-square test was used to compare the categorical data. A p-value of less than 0.05 was considered statistically significant. All data were analyzed using the Statistical Package for Social Sciences (SPSS) 24.0 (IBM SPSS, Tokyo, Japan).

## **Results**

#### *Comparison of clinical features between the CI and the SC groups (Table 1)*

The mean age of patients in the CI group was 48.0 (29–75) years, while that of patients in the SC group was 57.8 (41–72) years. There was no significant difference between



**Figure 2.** Preoperative CT findings in the SC group. The CT revealed a slightly dilated colon with 4–8 cm diameter spherical scybalum-like moniliforms.

the two groups. There were no significant differences in gender, mean operation time, or mean intraoperative blood loss. The SC group's postoperative hospital stay was significantly longer than that of the CI group. Postoperative gastric outlet obstruction[8] occurred in two patients (11%) who underwent distal partial gastrectomy with R-Y reconstruction[9] after the surgery in the CI group but no patients in the SC group. Postoperative pelvic outlet obstruction[10] occurred in all four patients who underwent ileostomy within a year after surgery in the SC group but no patients in the CI group.

#### *Comparison of intestinal contents between the CI and the SC groups*

The CI patients had abundant soft stool in their dilated colons that could not be washed out with preoperative preparation. In the SC group, many spherical scybalum-like moniliforms with diameters of 4–8 cm ranged from the cecum to the sigmoid colon (Figure 3).


## **Discussion**

Total colectomy with ileorectal anastomosis is the most effective and widely used treatment strategy in patients with STC who do not respond to medical or rehabilitative therapy[11]. Previous studies have demonstrated a success rate of approximately 94%; however, one-third of patients had uncontrollable diarrhea or constipation persistently after surgery[12–14]. These differences were probably due to the lack of objective criteria for the definition of constipation and the incomplete diagnosis because of the frequent association of slow transit constipation symptoms with outlet obstruction constipation[15]. In the present study, we tried to evaluate intractable STC with CT before surgery. According to specific criteria, patients with intractable STC were divided into two groups, the CI group and the SC group, by

**Table 1.** Comparison of Characteristics between Colonic Inertia Type Group and Spastic Constipation Type Group.

Characteristic	Colonic inertia type group (n=18)	Spastic constipation type group (n=4)	p value
Mean age (range), years	48.0 (29-75)	57.8 (41-72)	0.459
Gender, n (%)			0.292
Male	4 (22)	2 (50)	
Female	14 (78)	2 (50)	
Operation time (range), minutes	221.9 (150-266)	193.8 (180-230)	0.165
Intraoperative blood loss (range), ml	8.3 (0-60)	22.5 (0-90)	0.542
Intestinal contents	Soft stool	Spherical scybalum	
Postoperative hospital stay (range), days	11.3 (8-14)	14.0 (14)	0.041
Postoperative problem, n (%)			
Gastric outlet obstruction	2 (11)	0 (0)	0.662
Pelvic outlet obstruction	0 (0)	4 (100)	< 0.001

The data are presented as mean (range) or as n (%).



**Figure 3.** View of the intestinal contents in the SC group. Many spherical scybalum-like moniliforms with diameters of 4–8 cm ranged from the cecum to the sigmoid colon.

### CT.

In the CI group, whose colon was expanded with soft stool, total colectomy was remarkably effective. However, the approximate 10% of patients who received distal partial gastrectomy with R-Y reconstruction[9], which can directly drain gastric contents into the small intestine, had postoperative gastric outlet obstruction after surgery. Patients who required gastrectomy had favorable appetite and defecation in the early postoperative period. Two or three months after the discharge from our hospital, their appetite was getting uncontrolled, and they vomited gastric contents several times a week. They underwent gastrectomy with R-Y reconstruction because they were diagnosed with gastric outlet obstruction, severe gastroparesis, stomach examination using contrast medium, and gastrografin. This severe gastroparesis represented an atonic extension of the stomach by the weight of gastric

contents. This clinical condition was similar to colonic inertia.

The colon was slightly expanded in the SC group with many spherical scybalum-like moniliforms, which had a diameter of 4–8 cm. Fewer high-amplitude propagated contractions led to functional disorders of the colon[16–18]. Even if the high-amplitude propagated contractions subsided, local contractions still maintained normally in the colon segment were divided by an approximately 3-cm interval by the plica semilunaris[19]. Those local contractions may have shaped the intestinal contents into spherical scybalum. All four patients who underwent ileostomy experienced postoperative pelvic outlet obstruction within a year after surgery. Those patients habitually and abundantly took oral psychotropic drugs. The four SC group patients could not undergo sufficient examination for their defecation preoperatively because large quantities of scybalum occupied their colons and rectums. They needed to remove scybalum in their rectum through the anus by disimpaction several times a week before the surgery. In the postoperative short-term, their property of stools was diarrhea. Two or three months after the discharge from our hospital, they needed to remove scybalum in their rectum through the anus by disimpaction several times a week again. Subsequently, they could not avoid undergoing ileostomy because of severe abdominal distension caused by pelvic outlet obstruction.

Hospitalization after surgery was significantly longer in the SC group than in the IC group. The property of stools turned diarrhea to soft stool soon after starting the meal in the CI group. In contrast, stools' property turned diarrhea to soft stool gradually after starting the meal in the SC group. Accordingly, their time to discharge from our hospital was longer.

In the postoperative short-term, all patients in both groups were satisfied with their surgery. The patients in the CI

group, excluding the patients who underwent gastrectomy, had been able to evacuate soft stool three to five times a day after our hospital discharge. They were extremely satisfied with their surgery. The SC group patients could evacuate diarrhea five to ten times a day after discharge from our hospital. Two or three months after discharge from our hospital, their stool frequency gradually decreased, and their abdominal distention frequency gradually increased. The abdominal distention was getting severe.

### Conclusions

The two groups differed in pathophysiology, which can be distinguished by preoperative CT. Preoperative evaluation of intractable STC by CT seems to be a useful predictor of postoperative outcomes.

#### Conflicts of Interest

There are no conflicts of interest.

#### Author Contributions

HK designed this work. All authors analyzed and interpreted the patient data and have helped draft the manuscript. TA gave final approval of the version to be published. All authors read and approved the final manuscript.

#### Approval by Institutional Review Board (IRB)

Approval code of IRB: 30-344 (9365)

The name of the institution that granted the approval: Jikei University

### References

- Lane WA. The results of operative treatment of chronic constipation. *Br Med J*. 1908; 1: 126-30.
- Lane WA. An address on chronic intestinal stasis. *Br Med J*. 1909 Jun; 1(2528): 1408-11.
- Redmond JM, Smith GW, Barofsky I, et al. Physiological tests to predict long-term outcome of total abdominal colectomy for intractable constipation. *Am J Gastroenterol*. 1995 May; 90(5): 748-53.
- Lubowski DZ, Chen FC, Kennedy ML, et al. Results of colectomy for severe slow transit constipation. *Dis Colon Rectum*. 1996 Jan; 39(1): 23-9.
- Platell C, Scache D, Mumme G, et al. A long-term follow-up of patients undergoing colectomy for chronic idiopathic constipation. *Aust N Z J Surg*. 1996 Aug; 66(8): 525-9.
- Ho YH, Tam M, Eu KW, et al. Laparoscopic-assisted compared with open total colectomy in treating slow transit constipation. *Aust N Z J Surg*. 1997 Aug; 67(8): 562-5.
- Kawahara H, Watanabe K, Tomoda M, et al. Single-incision clipless laparoscopic total colectomy. *Hepatogastroenterology*. 2014 Mar; 61(130): 453-5.
- Mohammed AA, Benmoussa A, Almeghaiseeb I, et al. Gastric outlet obstruction. *Hepatogastroenterology*. 2007 Dec; 54(80): 2415-20.
- Inokuchi M, Kojima K, Yamada H, et al. Long-term outcomes of Roux-en-Y and Billroth-I reconstruction after laparoscopic distal gastrectomy. *Gastric Cancer*. 2013 Jan; 16(1): 67-73.
- Hedrick TL, Friel CM. Constipation and pelvic outlet obstruction. *Gastroenterol Clin North Am*. 2013 Dec; 42(4): 863-76.
- Ripetti V, Caputo D, Greco S, et al. Is total colectomy the right choice in intractable slow-transit constipation? *Surgery*. 2006 Sep; 140(3): 435-40.
- Kamm MA. Role of surgical treatment in patients with severe constipation. *Ann Med*. 1990 Jan; 22(6): 435-42.
- Wexner SD, Daniel N, Jagelman DG. Colectomy for constipation: physiologic investigation is the key to success. *Dis Colon Rectum*. 1991 Oct; 34(10): 851-6.
- Pemberton JH, Rath DM, Ilstrup DM. Evaluation and surgical treatment of severe chronic constipation. *Ann Surg*. 1991 Oct; 214(4): 403-11; discussion 411-3.
- Lundin E, Kalborm U, Pahlman L, et al. Outcome of segmental colonic resection for slow-transit constipation. *Br J Surg*. 2002 Oct; 89(10): 1270-4.
- Bassotti G, Chiarioni G, Imbimbo BP, et al. Impaired colonic motor response to cholinergic stimulation in patients with severe chronic idiopathic (slow transit type) constipation. *Dig Dis Sci*. 1993 Jun; 38(6): 1040-5.
- Bassotti G, Chistolini F, Nzepa FS, et al. Colonic propulsive impairment in intractable slow-transit constipation. *Arch Surg*. 2003 Dec; 138(12): 1302-13.
- Shafik A, Shafik AA, El-Sibai O, et al. Colonic pacing. A therapeutic option for the treatment of constipation due to total colonic inertia. *Arch Surg*. 2004 Jul; 138(7): 1007-11.
- Kawahara H, Yanaga K. Herbal medicine Dai-Kenchu-To stimulates colonic motility directly. *Surg Today*. 2009 Feb; 39(2): 175-7.

Journal of the Anus, Rectum and Colon is an Open Access journal distributed under the Creative Commons Attribution-NonCommercial-NoDerivatives 4.0 International License. To view the details of this license, please visit (<https://creativecommons.org/licenses/by-nc-nd/4.0/>).