

Lipoma of the parietal peritoneum: an unusual cause of abdominal pain

Ibrahim Barut,* Omer Ridvan Tarhan,* Metin Ciris,† Ercan Tasliyar ‡

A lipoma is a very common benign soft tissue tumor that is composed of mature fat. It represents by far the most common mesenchymal neoplasm in adults, occurring throughout the whole body.¹⁻³ It can be single or multiple (lipomatosis) and superficially or deeply localized.² Most become apparent in patients between the ages 40 and 60 years and, when unexcised, persist for the remainder of life; they hardly increase in size after an initial growth period. Statistics as to incidence by sex vary, but most studies report a higher incidence in men.¹

Mature lipomas in adults have a predilection for the trunk. Deep lipomas have been reported in the thorax, mediastinum, chest wall, pelvis, retroperitoneum, and paratesticular region.⁴ In the gastrointestinal tract, lipomas are mainly found in the submucosa and subserosa of the small and large intestines, and are mostly an incidental finding at laparotomy and autopsy. They are solitary or multiple, and present as a sessile or pedunculated mass; sometimes they are associated with ulceration and bleeding, intussusception, Crohn's disease, or malignancies.¹ These benign tumors can cause various gastrointestinal symptoms such as obstruction and abdominal pain.⁵

Intraperitoneal lipoma is extremely rare.⁴ We encountered a case of a lipoma of the parietal peritoneum in 67-year-old woman presenting with acute abdominal pain.

Case

A 67-year-old female patient was admitted to the emergency clinic with a 4-day history of abdominal crampy pain, nausea, vomiting and constipation. She had suffered from transient abdominal pain and nausea for 3 years, and during the past 6 months she had experienced episodes of abdominal pain, distension and constipation. At physical examination the patient had abdominal distension, tenderness and muscular guarding. Bowel sounds were decreased. Abdominal plain films taken in the upright position and the results of laboratory examinations were all normal, except for mild leukocytosis ($14000/\text{mm}^3$). An abdominal ultrasound was normal.

We decided to perform diagnostic laparotomy. At operation we found a soft, yellow mass surrounded by a thin capsule originating from the parietal peritoneum onto the median umbilical ligament (Figure 1). There was no adhesion to the surrounding organs. The mass was completely excised. There was no pathology at exploration, except for this tumor. On gross examination, the mass was $6 \times 4 \times 2$ cm in size, encapsulated, homogeneous, and had a short peduncle (Figure 2). Microscopically, the tumor was composed of a well-formed fibrous capsule and mature fat cells (Figure 3). The cells showed only a slight variation in cellular size and shape. The nuclei of the cells were fairly uniform. Pathologically, the tumor was diagnosed as a lipoma.

*From *Suleyman Demirel University, School of Medicine, Department of General Surgery and †Department of Pathology, Isparta, Turkey, and ‡Sincan State Hospital, Department of Pathology, Ankara, Turkey.*

Correspondence and reprint requests:

*Ibrahim Barut, MD
SDU Tip Fakultesi Genel Cerrahi
Anabilim Dalı Ogretim Uyesi
32900
Isparta, Turkey
T: +90-246-211 2223
F: +90-246-223 4284
ibarutt@hotmail.com*

Ann Saudi Med 2006;26(5):388-390

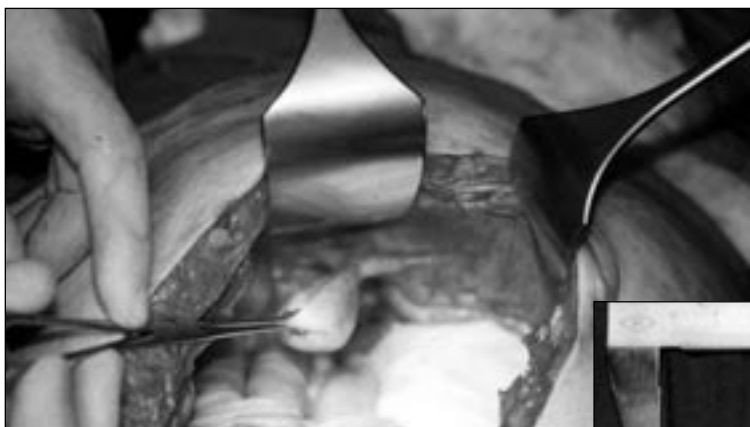

Figure 1. Lipoma of the parietal peritoneum, operative view.

The post-operative course was uneventful and the patient was discharged on the second day after the operation. She remained free of symptoms 12 months later.

Discussion

Primary peritoneal tumors are rare and not well-known malignancies.⁶ Subsequent to the recognition of intraperitoneal tumors of low potential for malignancy, clinicians have repeatedly faced the ambiguities inherent in a disease that seems aggressive on the basis of its wide distribution in the peritoneal cavity but benign on the basis of its histopathology and clinical course. Whereas the occasional case has been associated with extensive local reaction and ascites, except for a rare exception, these tumors are associated with prolonged survival and an absence of extra-abdominal extension.⁷

Lipomas are benign tumors with a low potential for malignant degeneration.² As a benign adipose tumor, very little is known about the pathogenesis of lipomas. An increased incidence is associated with obesity, diabetes mellitus, elevation of serum cholesterol, trauma, radiation, familial tendency, and chromosomal abnormalities, such as translocation of t(3;12) (q27;q13) and t(3;12) (q28;q14), rearrangement of band 12q14, and ring chromosomes.^{1,8} Obesity was determined as an etiologic factor in the present case.

Macroscopically, lipomas are soft, well-capsulated, oval and yellow. Lipomas generally form a slow-growing, nonlobulated, soft and mobile mass, which does not penetrate into the surrounding organs.⁴ The tumor from our patient was mobile, oval, soft, yellow, had a peduncle and was well-capsulated.

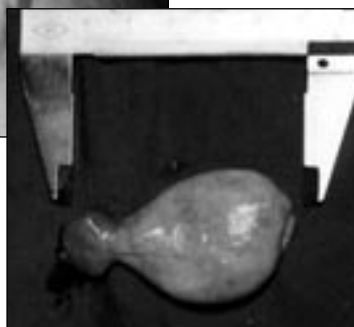


Figure 2. Lipoma of the parietal peritoneum, macroscopic view.

Deep lipomas are usually diagnosed only when the tumor grows very big or becomes symptomatic of its anatomical localization.^{9,10} The peritoneum is an extremely rare site for lipomas.^{1,2} Very occasionally they may cause intermittent abdominal pain, distension, small bowel volvulus, and constipation.^{3,4} The peritoneal lipoma in our patient had caused abdominal pain, distension and constipation.

Radiological examinations may show a well-demarcated, radiolucent area with or without intestinal obstruction, depending on the size of the tumor, while ultrasonography and CT give detailed information about the fatty nature of the tumor.^{3,4,11} Angiography and colored Doppler ultrasonography show that the tumor was avascular.¹² Neither roentgenography nor ultrasonography was effective in the diagnosis in our patient so we exposed the tumor during the diagnostic laparoscopy.

Lipomas differ little in microscopic appearance from surrounding fat. Like fat they are composed of mature fat cells, but the cells vary slightly in size and shape and are somewhat larger, measuring up to 200 μm in diameter.¹ In the differential diagnosis of peritoneal lipoma, lipoblastoma, lymphangioma, liposarcoma and lymphangioliipoma should all be considered.^{1,3,13-15} Lipoblastoma is a benign tumor of immature fat cells, and is localized in the extremities in 60% of cases. This lesion differs from lipoma by its cellular immaturity and close resemblance to the myxoid form of liposarcoma. Moreover, it is usually

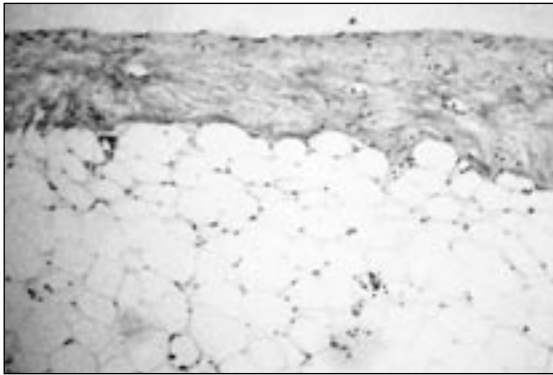


Figure 3. Lipoma of the parietal peritoneum, microscopic view (H&E stain, 40X).

seen in childhood.^{1,3,13,14} A lymphangioma is easily differentiated by its marked multiseptations and

cystic appearance, while lymphangioliipoma is differentiated by its cystic organization inside the tumor on ultrasonography and CT.^{3,11,13} A liposarcoma usually develops as a single mass. It is histologically classified as a differentiated or mucous type.¹⁵ The tumor in our patient was not detected with either roentgenography or ultrasonography.

The recurrence rate of all lipomas is less than 5% and is usually due to incomplete excision.^{9,16} For the present case, complete surgical excision was performed and recurrence did not occur in the follow-up examination in a 12-month period. Even though lipoma of the parietal peritoneum is rare, it should be considered in the differential diagnosis of patients with abdominal pain, distension and constipation. This neoplasm should be treated by total excision.

References

1. Enzinger FM, Weiss SW: *Soft Tissue Tumors* (ed 3). St Louis, MO, Mosby, 1995, pp 384-405.
2. Ozel SK, Apak S, Ozercan IH, Kazez A. Giant mesenteric lipoma as a rare cause of ileus in a child: report of a case. *Surg Today*. 2004; 34(5):470-2.
3. Sato M, Ishida H, Konno K, Komatsuda T, Naganuma H, Segawa D, Watanabe S, Ishida J. Mesenteric lipoma: report of a case with emphasis on US findings. *Eur Radiol*. 2002; 12(4):793-5.
4. Prando A, Wallace S, Marins JL, Pereira RM, de Oliveira ER, Alvarenga M. Sonographic features of benign intraperitoneal lipomatous tumors in children--report of 4 cases. *Pediatr Radiol*. 1990; 20(8):571-4.
5. Wolko JD, Rosenfeld DL, Lazar MJ, Underberg-Davis SJ. Torsion of a giant mesenteric lipoma. *Pediatr Radiol*. 2003; 33(1):34-6.
6. Clippe C, Freyer G, Bizollon MH, Raudrant D, Gilly F, Vitrey D, Ligneau B, Trillet-Lenoir V. Primary peritoneal tumors: report on a series of eight cases and review of the literature (with English abstract). *Bull Cancer*. 2002; 89(4):430-6.
7. Genadry R, Poliakoff S, Rotmensch J, Rosenshein NB, Parmley TH, Woodruff JD. Primary, papillary peritoneal neoplasia. *Obstet Gynecol*. 1981; 58(6):730-4.
8. Weiss SW. Lipomatous tumors. *Monogr Pathol*. 1996; 38:207-39.
9. Ilhan H, Tokar B, Isiksoy S, Koku N, Pasaoglu O. Giant mesenteric lipoma. *J Pediatr Surg*. 1999; 34(4):639-40.
10. Colovic R, Colovic N, Zogovic S. Mesenteric lipoma causing volvulus of the small intestine (with English abstract). *Srp Arh Celok Lek*. 2000; 128(5-6):205-7.
11. Radivoyevitch MA, Mirmiran-Yazdy SA. Lymphangioliipoma of the mesentery. *Am Surg*. 1989; 55(7):435-7.
12. Zanetti G. Benign lipoblastoma: first case report of a mesenteric origin. *Tumori*. 1988; 74(4):495-8.
13. Schulman H, Barki Y, Hertzanu Y. Case report: mesenteric lipoblastoma. *Clin Radiol*. 1992; 46(1):57-8.
14. Jimenez JF. Lipoblastoma in infancy and childhood. *J Surg Oncol*. 1986; 32(4):238-44.
15. Sato H, Minei S, Sugimoto S, Kishimoto Y, Yoshida T, Takimoto Y. Multicentric liposarcoma. *Int J Urol*. 2004; 11(12):1133-5.
16. Luo X, Gao W, Zhan J. Giant omental lipoma in children. *J Pediatr Surg*. 2005; 40(4):734-6.