



**CASE REPORT**

# Two mixed breed dogs with sensory neuropathy are homozygous for an inversion disrupting *FAM134B* previously identified in Border Collies

Pablo Amengual-Batle<sup>1</sup> | Clare Rusbridge<sup>2,3</sup> | Roberto José-López<sup>1</sup>  | Lorenzo Golini<sup>4</sup> | G. Diane Shelton<sup>5</sup> | Cathryn S. Mellersh<sup>6</sup> | Rodrigo Gutierrez-Quintana<sup>1</sup> 

<sup>1</sup>Small Animal Hospital, School of Veterinary Medicine, University of Glasgow, Glasgow, United Kingdom

<sup>2</sup>Fitzpatrick Referrals, Eashing, Surrey, United Kingdom

<sup>3</sup>Faculty of Health & Medical Sciences, University of Surrey, School of Veterinary Medicine, Vet School Main Building, Daphne Jackson Road, Guildford, GU2 7AL, United Kingdom

<sup>4</sup>Northwest Veterinary Specialists, Cheshire, United Kingdom

<sup>5</sup>Department of Pathology, School of Medicine, University of California, San Diego, San Diego, California

<sup>6</sup>Animal Health Trust, Newmarket, United Kingdom

**Correspondence**

Small Animal Hospital, School of Veterinary Medicine, University of Glasgow, Glasgow, United Kingdom.  
rodrigo.gutierrezquintana@glasgow.ac.uk

Two unrelated 8-month-old male mixed breed dogs were presented for evaluation of progressive ataxia, knuckling, and lack of pain perception in the distal limbs. Because of the similarity in age of onset, progression, and clinical findings with previously described sensory neuropathy in Border Collies, the affected dogs were screened for an *FAM134B* mutation and were determined to be homozygous for the mutation. Despite few phenotypic similarities with other breeds, genetic testing for specific diseases should be considered in mixed breed dogs with compatible clinical signs, especially if ancestry is unknown.

**KEYWORDS**

hereditary neuropathy, sensory-autonomic neuropathy, mutation, dog

## 1 | CASE 1

An 8-month-old male intact mixed-breed dog was referred to the Neurology Service of the University of Glasgow for investigation of a 1-month history of chronic progressive gait abnormalities. The owners had noticed that the dog was chewing its paw for 3–4 months before referral and then developed gradually deteriorating ataxia and knuckling over in the pelvic limbs during the month before evaluation. At that stage, urinary incontinence also was observed, with the dog passing urine intermittently, even when walking. CBC and serum biochemistry were unremarkable. Radiographs of the thoracolumbar vertebral column were obtained and no abnormalities were detected. No

information was available regarding ancestors or other littermates, but the circumstances suggested that the puppy was from a farm.

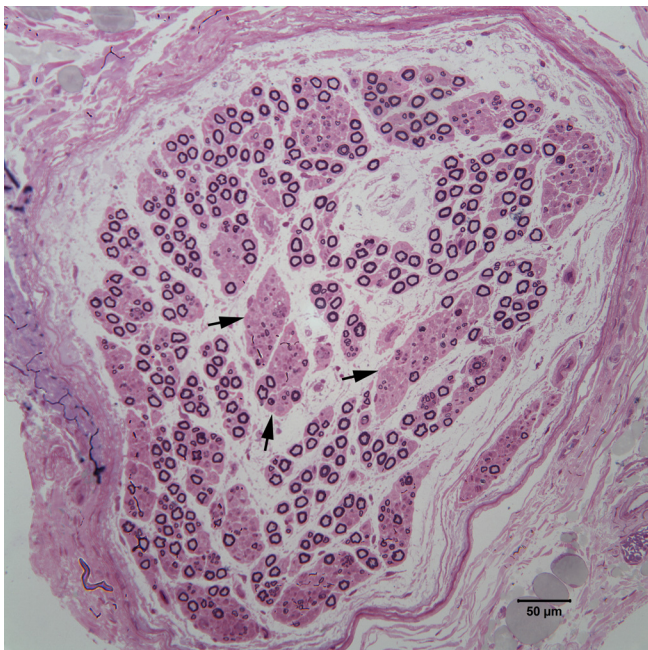
Physical examination findings included multiple wounds on the distal aspect of all 4 limbs. Neurological examination identified normal mentation and cranial nerve function. Gait assessment disclosed severe proprioceptive ataxia in all limbs with the pelvic limbs more severely affected including occasional knuckling of the hind paws. Paw positioning and hopping were decreased to absent in all limbs. Withdrawal reflex was absent in all limbs, but patellar, perineal, and cutaneous trunci reflexes were intact. Superficial and deep pain perception was absent distally in all limbs but present proximally, and in the tail, trunk, and head. Findings were consistent with a peripheral sensory neuropathy with partial autonomic involvement as suggested by the urinary incontinence.

**Abbreviation:** CBC, complete blood cell count

This is an open access article under the terms of the Creative Commons Attribution-NonCommercial License, which permits use, distribution and reproduction in any medium, provided the original work is properly cited and is not used for commercial purposes. © 2018 The Authors. *Journal of Veterinary Internal Medicine* published by Wiley Periodicals, Inc. on behalf of the American College of Veterinary Internal Medicine.

Repeated CBC and serum biochemistry profile did not identify any abnormalities. Serology testing for *Toxoplasma gondii* and *Neospora caninum* was negative. Electromyography disclosed mild spontaneous electrical activity in multiple distal appendicular muscles in all limbs. Motor nerve conduction velocity of the ulnar, sciatic, and common fibular nerves was within normal range. Muscle cryosections from the biceps femoris and gastrocnemius muscles were evaluated using a standard panel of histochemical stains and reactions. No specific abnormalities were identified in either muscle. A formalin-fixed biopsy from the common fibular nerve was embedded in resin and evaluated using 1  $\mu\text{m}$  sections (Figure 1). Multifocal areas of nerve fiber loss were present without obvious axonal degeneration or demyelination. It could not be determined if areas of nerve fiber loss involved mainly sensory or motor fibers in this mixed nerve. To our knowledge, a method of distinguishing motor from sensory fibers histologically in a mixed nerve is not available. A sensory nerve would have provided clarification but was not submitted for evaluation. A presumptive diagnosis of sensory neuropathy was established.

To decrease the frequency and severity of mutilations, treatment with pregabalin (Pregabalin Teva 25 mg capsules, TEVA UK Limited, Eastbourne, United Kingdom) was initiated (2 mg/kg PO q8h). Unfortunately, clinical signs continued to progress despite treatment, and the owner requested a second opinion from the neurology service of Fitzpatrick Referrals. Repeated neurological examination suggested progression of signs. The urinary incontinence was more pronounced and compatible with an autonomic bladder, with frequent pollakiuria, and fecal incontinence was present. The dog was indifferent to distal painful stimuli and had absent withdrawal reflexes in all 4 limbs. However, a behavioral response was observed to a painful stimulus when



**FIGURE 1** Resin-embedded thick sections (1  $\mu\text{m}$ ) of a common fibular nerve fascicle stained with toluidine blue-acid fuchsin. Numerous collagenous bundles consistent with resolving subperineurial edema are present in the subperineurium. Arrows depict representative areas of nerve fiber loss. The distribution of sensory and motor nerve fibers in this mixed nerve could not be determined

applied proximally on the thoracic limbs, with a very slight withdrawal reflex. Nociception was still present in the tail. Cutaneous trunci reflex was absent caudal to the level of the T10 vertebra. The perineal reflex, despite fecal incontinence, was intact. Patellar reflexes were absent. Cranial nerve function including facial sensation was intact. The dog failed to correct a knuckled over paw, in the thoracic limbs as well as in the pelvic limbs. The dog did, however, place the thoracic limbs normally and had normal hopping ability. Hopping ability was absent in the pelvic limbs. In addition, the dog recurrently chewed on its limbs. Unfortunately, clinical signs continued to progress and the owners elected euthanasia 4 months after the first neurological consultation.

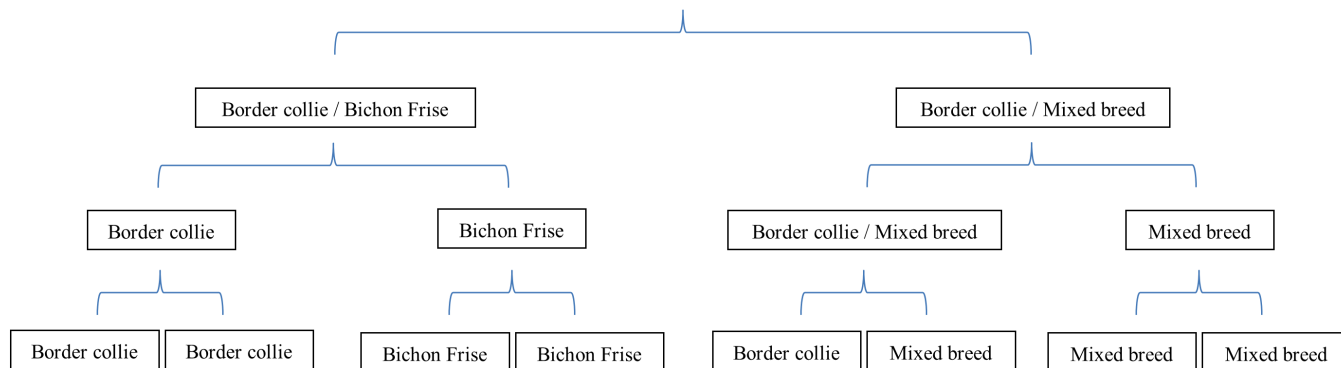
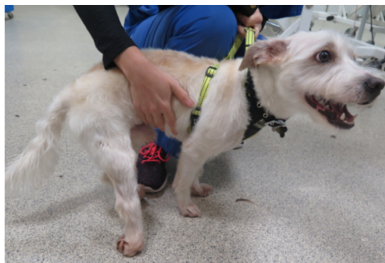
Because of clinical and histopathological similarities with previously reported Border Collie sensory neuropathy<sup>1</sup> and despite the fact that the dog did not resemble a Border Collie (Figure 2), it was decided to screen for the recently reported mutation in the *FAM134B* gene and the dog was found to be homozygous.

## 2 | CASE 2

An 8-month-old male intact mixed-breed dog of unknown ancestry was presented to the Neurology Service of Northwest Veterinary Specialists for evaluation of gait abnormalities similar to those of Case 1. The owners initially observed the clinical signs when the dog was approximately 6.5 months of age. Pelvic limb ataxia and occasional spontaneous knuckling were observed. Trial treatment with meloxicam (Metacam 1.5 mg/mL oral solution, Boehringer Ingelheim, United Kingdom; 0.2 mg/kg PO q24h for 7 days) followed by a combination of prednisolone (Prednisolone tablets B.P. [Vet], Millpledge Veterinary, United Kingdom; 1 mg/kg PO q12h for 5 days followed by 1 mg/kg PO q48h) and clindamycin (Clinacin tablets, Chanelle, United Kingdom; 7.5 mg/kg PO q12h for 5 days) was not effective, clinical signs progressively worsened, and the medications were discontinued. On referral, the patient had severe gait disturbance and was almost consistently standing on the dorsal aspects of its pelvic digits. The owner also described the occurrence of defecation during walking.

Physical examination disclosed multiple wounds in the distal aspect of all 4 limbs. Neurological examination identified normal mentation and cranial nerve function. Gait assessment disclosed severe proprioceptive ataxia in all limbs. The pelvic limbs were more severely affected, with bilateral hyperextended tarso-crural joints and standing on the dorsal aspect of the pelvic digits. Severe valgus deformity of both carpi was present. Paw positioning and hopping were absent in the pelvic limbs and decreased in the thoracic limbs. The withdrawal reflex was absent in all limbs, but patellar and perineal reflexes were intact. Deep and superficial pain perception was absent distally in all limbs and in the tail, but present proximally and in the trunk and head. The findings were consistent with a peripheral sensory neuropathy with partial autonomic involvement, as suggested by fecal incontinence.

A CBC and serum biochemistry profile did not identify any abnormalities, except for a mild increase in creatine kinase activity of 465 U/L (normal  $\leq 190$  U/L). Serology testing for *T. gondii* and *N. caninum* was negative. Again, because of the clinical similarities with previously reported Border Collie sensory neuropathy,<sup>1</sup> the dog was



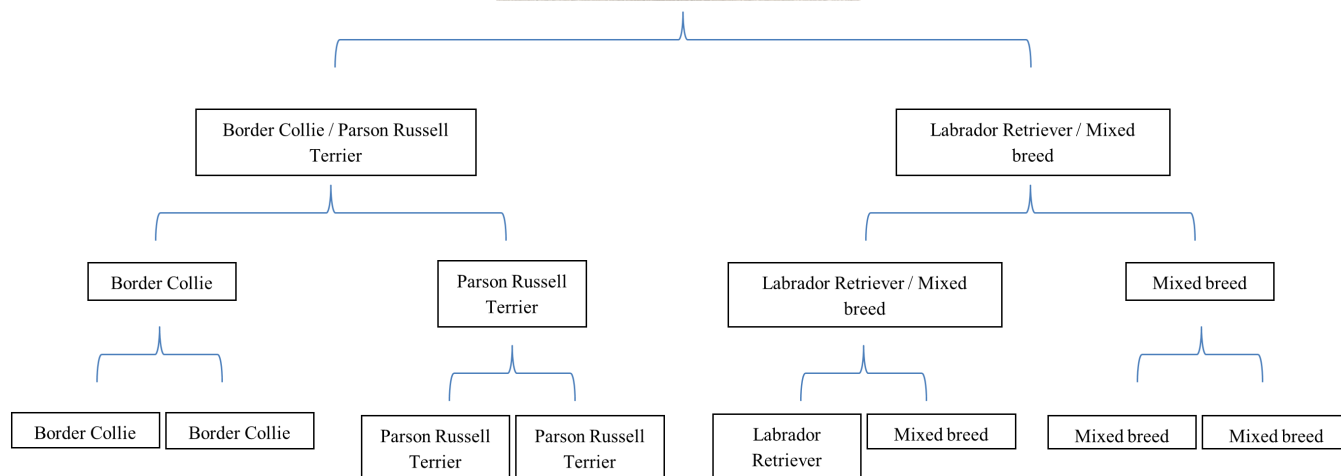
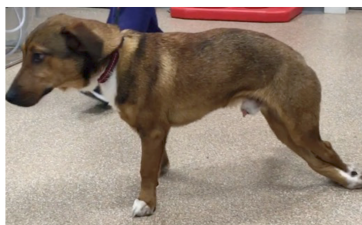**FIGURE 2** Diagram showing the ancestors of Case 1: 37.5% corresponded to Border Collie, 25% to Bichon Frise, and the rest (37.5%) to mixed breed groups

screened for the recently reported mutation in the *FAM134B* gene and found to be homozygous. Phenotypically, the dog did not resemble a Border Collie (Figure 3). The dog was lost to follow-up, and the post-mortem examination was declined by the owner.

Herein we describe 2 cases of sensory neuropathy caused by an inversion disrupting *FAM134B* in a dog other than a pure-breed Border Collie. Sensory neuropathy in the Border Collie is an autosomal recessive disease characterized by chronic and progressive proprioceptive ataxia, proprioceptive deficits, loss of nociception, self-

mutilation, and in some cases, autonomic signs such as urinary incontinence.<sup>1-4</sup> Recently, a genetic mutation was found affecting the *FAM134B* gene in Border Collies with clinical signs compatible with sensory neuropathy.<sup>1</sup> The *FAM134B* gene encodes a cis-Golgi protein found in sensory and autonomic neurons. Although not completely understood, this defect induces apoptosis in neurons of the dorsal root ganglia.<sup>1</sup>

Sensory neuropathies with or without autonomic involvement have been reported in other canine breeds, such as long-haired Dachshund,<sup>5,6</sup>



**FIGURE 3** Diagram showing the ancestors of the Case 2: 25% corresponded to Border Collie, 37.5% mixed breed groups, 25% Parson Russell Terrier, and 12.5% Labrador Retriever

Miniature Pinscher,<sup>7</sup> and Jack Russell Terrier<sup>8</sup> in which the responsible genetic mutation has not yet been identified, and in the Pointer,<sup>9-12</sup> English Springer Spaniel, and French Spaniel<sup>13</sup> breeds in which a mutation in the *GDNF* gene recently has been identified (Table 1).<sup>14</sup> A neurodegenerative disease affecting central and peripheral sensory and motor axons has been reported in Golden Retriever dogs and is caused by a deletion in the mitochondrial tRNA<sup>Tyr</sup> gene.<sup>15,16</sup>

Hereditary sensory and autonomic neuropathies (HSAN) are well described in humans and represent a group of seven (I-VII) disorders characterized by progressive sensory loss and ulcerative mutilation in combination with variable autonomic and motor disturbances associated with sensory and autonomic dysfunction.<sup>17,18</sup> Molecular genetics studies have identified disease-causing mutations in 12 genes. Some of the affected proteins have nerve-specific roles, for example, nerve growth factor and receptor. Underlying mechanisms also have been

shown to involve sphingolipid metabolism, vesicular transport, structural integrity, and transcription regulation.<sup>19</sup> Interestingly, although most of these disorders are autosomal recessive (II-VI), HSAN Types I and VII are dominant disorders. Type I HSAN is caused by a mutation in the *SPTLC1* gene. This gene encodes a serine palmitoyltransferase responsible for the synthesis of sphingolipids, ceramide, and sphingomyelin.<sup>20</sup> Similar to the sensory neuropathy in the Border Collie, *FAM134B* gene mutations have been found to cause HSAN II<sup>21</sup> and play a role in the etiology of some types of neoplasia such as esophageal squamous cell carcinoma and colorectal cancer in people.<sup>22,23</sup> A previous study in mice showed high expression of this gene in the dorsal root ganglia and reported that nociceptive neurons seem to be especially sensitive to deletion of *FAM134B*, therefore causing the characteristic clinical signs of HSAN II.<sup>21</sup> Separately, from HSAN, Charcot-Marie-Tooth (CMT) disease, is one of the most common

**TABLE 1** Hereditary sensory neuropathies previously described in dogs

Breed	Border Collie <sup>1-4</sup>	Jack Russell Terrier <sup>8</sup>	Long-haired Dachshund <sup>5,6</sup>	Pointer dogs <sup>11</sup>	French Spaniel <sup>13</sup>	Miniature Pinscher <sup>7</sup>
Age of presentation	2-7 months	6 years <sup>a</sup>	8-12 weeks	2-12 months	3.5-12 months	6 months <sup>a</sup>
Clinical signs	<ul style="list-style-type: none"> <li>Proprioceptive ataxia</li> <li>Knuckling</li> <li>Hyperextension of limbs</li> <li>Decreased or loss of proprioception and nociception</li> <li>Autonomic signs such as urinary/fecal incontinence</li> <li>Self-mutilation</li> </ul>	<ul style="list-style-type: none"> <li>Hypermetric gait</li> <li>Proprioceptive deficits</li> <li>Loss of nociception</li> </ul>	<ul style="list-style-type: none"> <li>Proprioceptive ataxia</li> <li>Decreased or loss of proprioception and nociception</li> <li>Autonomic signs such as vomiting or urinary incontinence</li> <li>Self-mutilation</li> </ul>	<ul style="list-style-type: none"> <li>Decreased pain perception proximal to the carpus and tarsus.</li> <li>Loss of pain perception to the distal aspect of the paw.</li> <li>Self-mutilation</li> </ul>	<ul style="list-style-type: none"> <li>Similar to Pointer dogs</li> </ul>	<ul style="list-style-type: none"> <li>Decreased pain perception in the distal pelvic limbs</li> <li>Hyperesthesia on palpation of the lumbar region</li> <li>Self-mutilation</li> </ul>
Diagnosis	<ul style="list-style-type: none"> <li>Decreased or absent sensory nerve compound action potentials</li> <li>Decreased or normal motor nerve conduction velocities</li> </ul>	Unknown	<ul style="list-style-type: none"> <li>Decreased or absent sensory nerve compound action potentials</li> <li>Normal electromyography</li> </ul>	<ul style="list-style-type: none"> <li>Normal electrodiagnostics</li> </ul>	<ul style="list-style-type: none"> <li>Normal electrodiagnostics</li> </ul>	Unknown
Treatment	Unknown	Unknown	Unknown	Unknown	Unknown	Unknown
Histopathology	<ul style="list-style-type: none"> <li>Axonal degeneration</li> <li>Endoneurial fibrosis</li> <li>Extensive large nerve fiber loss</li> </ul>	<ul style="list-style-type: none"> <li>Endoneurial and epineurial fibrosis</li> </ul>	<ul style="list-style-type: none"> <li>Decreased number of myelinated fibers</li> <li>Degeneration of unmyelinated axons, most predominant distally.</li> </ul>	<ul style="list-style-type: none"> <li>Decreased number of ganglionic cell bodies without remarkable neuronal degeneration</li> <li>Reduced fiber density and myelin staining in the spinal cord</li> <li>Lack of staining for substance P in the spinal cord</li> </ul>	<ul style="list-style-type: none"> <li>No abnormalities were detected</li> </ul>	<ul style="list-style-type: none"> <li>Reduced number of neurons in the lumbosacral spinal ganglia</li> <li>Loss of nerve fibers and endoneurial proliferation with Wallerian degeneration in the dorsal nerve roots</li> </ul>
Genetic mutation identified in	<i>FAM134B</i>	Unknown	Unknown	<i>GDNF</i>	<i>GDNF</i>	Unknown

<sup>a</sup> The age of presentation in Jack Russell Terrier and Miniature Pinscher remains unclear as this disease has been reported in one single case in both breeds.<sup>7,8</sup> In the Jack Russell, although the clinical signs worsened when the dog was 6 years old, progressive abnormal pelvic limb posture was noticed since birth. In the Miniature Pinscher, the dog presented at 18 months of age, although the clinical signs were first noticed 12 months prior.

motor and sensory inherited neuropathies in humans.<sup>24</sup> Affected people can present with a primary axonopathy or an axonopathy secondary to a myelination defect in Schwann cells.<sup>25</sup> Multiple studies have been performed and several genetic defects have been encountered. For example, approximately 75% of cases of the demyelinating form (CMT1) are caused by duplication in the short arm region of chromosome 17 in combination with mutations in *PMP22*, *MPZ*, or *GJB*.<sup>24</sup> Nevertheless, classification of HSN and CMT still is incomplete, and some clinical and genetic overlap may exist.

Intriguingly, mutation of *FAM134B* was responsible for the development of disease in these unrelated mixed breed dogs, despite the fact that they phenotypically looked more like a Jack Russell and a Parson Russell than a Border Collie, respectively (Figures 2 and 3). Because we were interested in knowing if the mutation was more widespread in the canine population than previously thought, or if there was any Border Collie ancestry in these dogs, a DNA sample was submitted for a commercially available canine breed ancestry test (Wisdom Panel, Mars Veterinary, Vancouver, WA, USA). The results suggested Border Collie ancestry in both dogs (Figures 2 and 3). However, these results should be interpreted with caution, because to our knowledge no scientific publications validate the sensitivity or specificity of the algorithm currently used for this test. Although, most likely the mutation arose from Border Collie ancestry, it is impossible to determine this possibility with certainty. The presence of a specific mutation causing the same neurodegenerative condition in > 1 breed has been described previously in veterinary medicine. For example, until recently, all mutations causing neuronal ceroid lipofuscinosis in dogs were reported to occur in members of a single breed, but 2 recent studies have reported a previously identified mutation in a second breed.<sup>24,25</sup> The fact that these gene alterations have been encountered in multiple breeds suggests that these diseases may be a consequence of more ancient mutations widely spread throughout the canine population.<sup>26</sup>

Also as previously reported, hereditary genetic diseases can affect mixed-breed dogs and characterizing them also may help other breeds.<sup>26-30</sup> In 2 recently published studies, it was found that a large number of mixed-breed dogs carried autosomal recessive mutations.<sup>29,30</sup> In these studies, the same commercially available canine breed ancestry test (Wisdom Panel, Mars Veterinary) was used, and it was found that many of the mixed-breed dogs carrying the alternate or mutant allele had the specific breed, in which the mutation initially was identified, in their ancestry.<sup>29,30</sup>

In conclusion, the genetic test for the *FAM134B* gene mutation is recommended when clinical signs are compatible with sensory neuropathy. Rare autosomal recessive genetic mutations previously identified in specific pure-breed dogs should be considered as a differential diagnosis in mixed-breed dogs with compatible clinical signs, especially if ancestry is unknown.

#### ACKNOWLEDGMENTS

The cases were seen at the University of Glasgow, Fitzpatrick Referrals, and Northwest Veterinary Specialists. The muscle and nerve biopsies were analyzed at the University of California and the genetic tests were performed at the Animal Health Trust.

#### CONFLICT OF INTEREST DECLARATION

One of the author works at an institution that offers the genetic test for sensory neuropathy in Border Collies commercially.

#### OFF-LABEL ANTIMICROBIAL DECLARATION

Authors declare no off-label use of antimicrobials.

#### INSTITUTIONAL ANIMAL CARE AND USE COMMITTEE (IACUC) OR OTHER APPROVAL DECLARATION:

Authors declare no IACUC or other approval was needed.

#### ORCID

Roberto José-López  <https://orcid.org/0000-0002-0661-5562>

Rodrigo Gutierrez-Quintana  <https://orcid.org/0000-0002-3570-2542>

#### REFERENCES

1. Forman OP, Hitti RJ, Pettitt L, et al. An inversion disrupting *FAM134B* is associated with sensory neuropathy in the Border collie dog breed. *G3 (Bethesda)* 2016;6:2687-2692.
2. Wheeler SJ. Sensory neuropathy in a Border collie puppy. *J Small Anim Pract.* 1987;28:281-289.
3. Vermeersch K, Van Ham L, Braund KG, et al. Sensory neuropathy in two Border collie puppies. *J Small Anim Pract.* 2005;46:295-299.
4. Harkin KR, Cash WC, Shelton GD. Sensory and motor neuropathy in a Border collie. *J Am Vet Med Assoc.* 2005;227:1263-1265.
5. Duncan ID, Griffiths IR. A sensory neuropathy affecting Long-haired Dachshund dogs. *J Small Anim Pract.* 1982;23:381-390.
6. Id D, Griffiths IR, Munz M. The pathology of a sensory neuropathy affecting long haired Dachshund dogs. *Acta Neuropathol.* 1982;58:141-151.
7. Bardagi M, Montoliu P, Ferrer L, et al. Acral mutilation syndrome in a Miniature Pinscher. *J Comp Pathol.* 2011;144:235-238.
8. Franklin RJM, Olby NJ, Targett MP, et al. Sensory neuropathy in a Jack Russell terrier. *J Small Anim Pract.* 1992;33:402-404.
9. Pivnik L. Comparative problems of acrodystrophic neuropathies in man and dogs. *Schweiz Arch Neurol Neurochir Psychiatr.* 1973;112:365-371.
10. Cummings JF, de Lahunta A, Winn SS. Acral mutilation and nociceptive loss in English pointer dogs. A canine sensory neuropathy. *Acta Neuropathol.* 1981;53:119-127.
11. Cummings JF, de Lahunta A, Braund KG, et al. Hereditary sensory neuropathy. Nociceptive loss and acral mutilation in Pointer dogs: canine hereditary sensory neuropathy. *Am J Pathol.* 1983;112(1):136-138.
12. Cummings JG, de Lahunta A, Simpson ST, et al. Reduced substance P-like immunoreactivity in hereditary sensory neuropathy of Pointer dogs. *Acta Neuropathol.* 1984;63(1):33-40.
13. Paradis M, de Jaham C, Page N, et al. Acral mutilation and analgesia in 13 French spaniels. *Vet Dermatol.* 2005;16(2):87-93.
14. Plassais J, Lagoutte L, Correard S, et al. A point mutation in a lincRNA upstream of *GDNF* is associated to a canine insensitivity to pain: a spontaneous model for human sensory neuropathies. *PLoS Genet.* 2016;29:e1006482.
15. Hultin Jäderlund K, Orvind E, Johnsson E, et al. A neurologic syndrome in Golden retrievers presenting as a sensory ataxic neuropathy. *J Vet Intern Med.* 2007;21:1307-1315.
16. Baranowska I, Jäderlund KH, Nennesmo I, et al. Sensory ataxic neuropathy in Golden Retriever dogs is caused by a deletion in the mitochondrial tRNATyr gene. *PLoS Genet.* 2009;5:e1000499.

17. Yozu A, Haga N, Funato T, et al. Hereditary sensory and autonomic neuropathy types 4 and 5: review and proposal of a new rehabilitation method. *J Neurosci Res.* 2016;104:105-111.
18. Rotthier A, Baets J, Timmerman V. Mechanisms of disease in hereditary sensory and autonomic neuropathies. *Nat Rev Neurol.* 2012;8:73-85.
19. Mroczek M, Kabzińska D, Kocharński A. Molecular pathogenesis, experimental therapy and genetic counseling in hereditary sensory neuropathies. *Acta Neurobiol Exp (Wars)* 2015;75:126-143.
20. Sapio MR, Goswami SC, Gross JR, et al. Transcriptomic analyses of genes and tissues in inherited sensory neuropathies. *Exp Neurol.* 2016;238:375-395.
21. Kurth I, Pamminger T, Hennings JC, et al. Mutations in FAM134B, encoding a newly identified Golgi protein, cause severe sensory and autonomic neuropathy. *Nat Genet.* 2009;41:1179-1181.
22. Haque MH, Gopalan V, Chan K, et al. Identification of novel FAM134B (JK1) mutations in oesophageal squamous cell carcinoma. *Sci Rep.* 2016;6:29173.
23. Islam F, Gopalan V, et al. Novel FAM134B mutations and their clinicopathological significance in colorectal cancer. *Hum Genet.* 2017;136:321-337.
24. Faller KM, Bras J, Sharpe SJ, et al. The Chihuahua dog: a new animal model for neuronal ceroid lipofuscinosis CLN7 disease? *J Neurosci Res.* 2016;94:339-347.
25. Kolicheski A, Johnson GS, O'Brien DP, et al. Australian Cattle dogs with neuronal ceroid lipofuscinosis are homozygous for a CLN5 nonsense mutation previously identified in Border Collies. *J Vet Intern Med.* 2016;30:1149-1158.
26. Bellumori TP, Famula TR, Bannasch DL, et al. Prevalence of inherited disorders among mixed-breed and purebred dogs: 27,254 cases (195-2010). *J Am Vet Med Assoc.* 2013;11:1549-1555.
27. Guo J, Johnson GS, Brown HA, et al. A CLN8 nonsense mutation in the whole genome sequence of a mixed breed dog with neuronal ceroid lipofuscinosis and Australian Shepherd ancestry. *Mol Genet Metab.* 2014;112:302-309.
28. Jolly RD, Hopwood JJ, Marshall NR, et al. Mucopolysaccharidosis type VI in a Miniature Poodle-type dog caused by a deletion in the arylsulphatase B gene. *N Z Vet J.* 2012;60:183-188.
29. Zierath S, Hughes AM, Fretwell N, et al. Frequency of five disease-causing genetic mutations in a large mixed-breed dog population (2011-2012). *PLoS One* 2017;12(11):e0188543.
30. Donner J, Anderson H, Davison S, et al. Frequency and distribution of 152 genetic disease variants in over 100,000 mixed breed and pure breed dogs. *PLoS Genet.* 2018;14(4):e1007361.

**How to cite this article:** Amengual-Batle P, Rusbridge C, José-López R, et al. Two mixed breed dogs with sensory neuropathy are homozygous for an inversion disrupting *FAM134B* previously identified in Border Collies. *J Vet Intern Med.* 2018; 32:2082–2087. <https://doi.org/10.1111/jvim.15312>