

# Facial Trauma 8 years after a Face Transplantation

Marion Goutard, MD\*†‡  
 Alexandre G. Lellouch, MD\*†‡  
 Bertrand Dussol, MD, PhD§  
 Laurent A. Lantieri, MD, PhD\*

**Summary:** Over the past 20 years, vascularized composite allografts (VCAs) have emerged as a realistic option in reconstructive surgery. Long-term follow-up reports indicate that face transplant patients have gained in quality of life and social integration. However, they require close monitoring of their immunosuppressive therapy because they are at high-risk for acute rejection episodes, leading eventually to chronic rejection and allograft loss. Reported acute rejection episodes in VCA recipients occur due to low immunosuppressive therapy (mainly due to lack of patient compliance or decreased doses of immunosuppressants to counter side-effects). Repeated mechanical traumas have recently been shown to trigger acute rejection episodes, especially in hand transplant patients. This article reports our experience of a 10-year follow-up of a 57-year-old face transplant patient and the management of his accidental facial trauma. To our knowledge, our patient is the first to undergo a major trauma on his VCA endangering his graft function and vitality. This report discusses the management of an acute surgical situation in those particular patients, and the challenges that arise to avoid acute rejection of the allograft. Ten years into his face transplant and at 18 months follow-up after his facial trauma, our patient shows great aesthetic and functional outcomes and remains rejection-free; a very encouraging result for all VCA candidates. (*Plast Reconstr Surg Glob Open* 2021;9:e3575; doi: [10.1097/GOX.0000000000003575](https://doi.org/10.1097/GOX.0000000000003575); Published online 21 May 2021.)

Face transplantation is limited to severely disfigured patients whose disfigurement cannot be addressed by autologous surgery.<sup>1</sup> To this day, 44 face transplants have been performed worldwide to treat large facial defects due to burns, ballistic injuries, or deforming diseases such as neurofibromatosis.<sup>2</sup> Follow-up reports indicate a true benefit in terms of quality of life for patients who get a second face.<sup>3</sup> We report here an uncommon surgical situation in a face transplant patient—a 57-year-old man who presented with a bifocal mandibular fracture and a nasal bone fracture due to a domestic accident 8 years after his partial face transplantation. Fifteen years after the first face

transplant ever performed, it remains crucial to report the outcomes in the mid- and long-term follow-up for each patient. Repeated traumas have recently been discovered to trigger a cell-mediated graft rejection.<sup>4</sup> However, no major trauma necessitating surgical treatment has been reported in VCA recipients, and the specific immunological challenges involved are yet to be determined.

## CASE REPORT

The patient, Mr. S, is a 57-year-old man who suffered a ballistic trauma of the mid lower face in 2009 during a hunting accident.<sup>2</sup> He had a history of ischemic cardiopathy and hypercholesterolemia for which he was prescribed Kardegic and statin. He benefited from a mid-lower face allograft in April 2011 at Henri Mondor Hospital, France. During follow-up, there was no major complication. Mr. S underwent several corrective surgeries until 2014. Since then, he has shown no sign of chronic rejection and has physically and socially adjusted to his new face.

Almost 8 years after his face transplant, Mr. S had a domestic accident falling down a staircase. On physical examination, he showed bilateral palpebral ecchymosis, a right deviation of his nasal bones, and edema of the lower part of his face. He had 2 open wounds in the inferior vestibules laying bare mandibular osteosynthesis material (Fig. 1). He had no other sign of associated trauma, and the rest of the examination was normal. A craniofacial CT

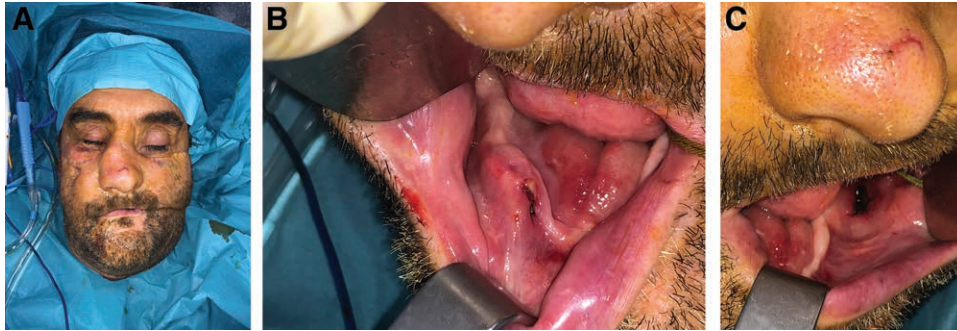From the \*Department of Plastic Reconstructive Surgery, European Georges Pompidou Hospital (AP-HP), Paris, France; †Division of Plastic and Reconstructive Surgery, Massachusetts General Hospital, Harvard Medical School, Boston, Mass.; ‡Vascularized Composite Allotransplantation Laboratory, Center for Transplantation Sciences, Massachusetts General Hospital, Harvard Medical School, Boston, Mass.; §Department of Nephrology and Transplantation, Assistance Publique-Hôpitaux de Marseille, Hôpital de la Timone, Marseille, France.

Received for publication December 16, 2020; accepted March 18, 2021.

Copyright © 2021 The Authors. Published by Wolters Kluwer Health, Inc. on behalf of The American Society of Plastic Surgeons. This is an open-access article distributed under the terms of the [Creative Commons Attribution-Non Commercial-No Derivatives License 4.0 \(CCBY-NC-ND\)](https://creativecommons.org/licenses/by-nc-nd/4.0/), where it is permissible to download and share the work provided it is properly cited. The work cannot be changed in any way or used commercially without permission from the journal.

DOI: [10.1097/GOX.0000000000003575](https://doi.org/10.1097/GOX.0000000000003575)

**Disclosure:** All the authors have no financial interest to declare in relation to the content of this article.



**Fig. 1.** Preoperative pictures. A, Facial deformities: bilateral palpebral ecchymosis, right deviation of nasal bones, and edema of the lower part of his face. B, Right parasymphyseal open wound. C, Left vestibular open wound.

was performed: it showed a bifocal fracture of the mandible and a nasal bone fracture (Fig. 2).

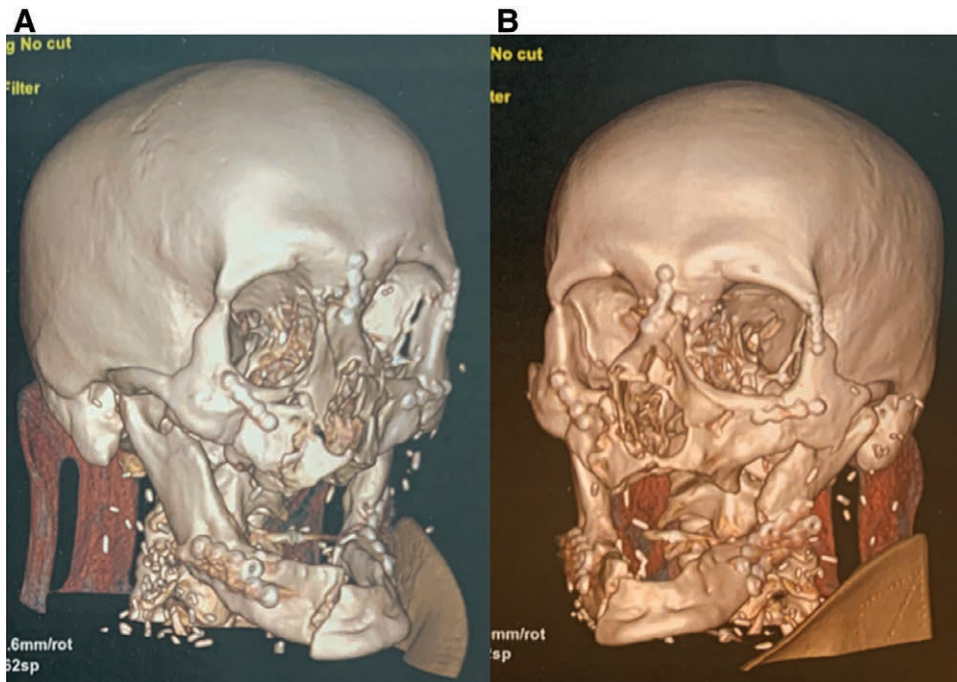
His immunosuppressive therapy included tacrolimus 2mg twice daily, mycophenolate mofetil 750mg twice daily, and corticosteroid 10 mg daily. Surgical treatment of his fractures was planned within a week after the trauma. Preoperative serum level of tacrolimus was 6.1 ng/ml (N 5: 10 ng/ml). Whole blood count and kidney function were normal.

The mandible left horizontal branch fracture was treated with a left cervical approach on the existing cervical scar at the junction between his own skin and the face transplant and was internally fixed using a 1.5-mm-thick pure titanium plate 3+3 holes (DePuy Synthes, MatrixMandible); the parasymphyseal fracture was treated with a vestibular approach using a 1.5-mm-thick pure titanium plate 2+2 holes (DePuy Synthes, MatrixMandible). The nasal fracture was reduced with external maneuvers. Skin biopsies were taken pre- and postoperatively.

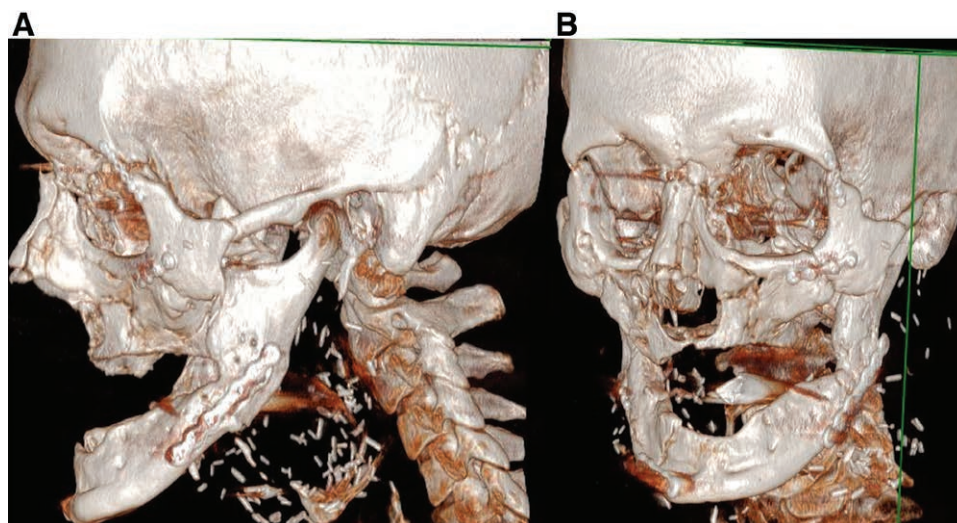
Mr. S recovered quickly in the postoperative immediate follow-up. The skin biopsies showed no sign of rejection with minimal dermal lymphocyte infiltrate. His immunosuppressive treatment was unchanged. Pain was controlled with a morphine pump until day 2, and he recovered his abilities to talk and eat solid food by that time. Postoperative craniofacial CT was performed at day 3 and showed a good reduction and osteosynthesis of both mandibular sites of fracture (Fig. 3). Mr. S was discharged from the hospital at postoperative day 6. After 18 months, Mr. S's facial function has returned to baseline. During this time, he maintained the immunosuppressive tri-therapy and showed no sign of rejection.

## DISCUSSION

This case reports an unusual surgical situation with a face transplanted patient. To our knowledge, this is the first described case of severe facial trauma in a



**Fig. 2.** 3D scanner reconstruction images showing the bifocal mandibular fracture with a right parasymphyseal fracture (A), a fracture on the left horizontal branch with torn osteosynthesis plates (B), and nasal bone fracture (A, B).



**Fig. 3.** T images at postoperative day 3 showing return to physiological anatomy of the bone fragments and stable osteosynthesis of both mandibular fracture sites. The mandible left horizontal branch fracture was fixed using a titanium plate (A); the parasymphiseal fracture was reduced and treated with a titanium plate (B). The nasal bones fracture was reduced (A, B).

face transplant recipient. The biggest challenge in the postoperative care of transplanted patients is to avoid rejection and metabolic complications by aiming for an optimal balance in immunosuppressive medications. Another challenge has risen in the past 2 decades of the VCA field: management of postoperative trauma and its immediate and long-term consequences. Mechanical trauma has recently been reported as a cause of atypical VCA rejection in hand transplanted patients.<sup>5</sup> Repeated mechanical micro-traumas are thought to induce recipient cell infiltration to the allograft, and therefore increase the risk of donor antigen recognition.<sup>6</sup> No studies have yet reported this issue in face transplant recipients. Fortunately, although the risk was high, our patient did not suffer any rejection episode following surgical treatment of his fractures. Episodes of stress are well known to be responsible for graft endangerment through an immunological vascular aggression to the graft.<sup>7</sup> We hypothesize that our patient remained rejection-free because he was not sensitized before his allograft and remained immunosuppression compliant through his entire follow-up period.

The mandibular fracture on the left horizontal branch appeared to be facilitated by a fibrous bony union between the allograft and the recipient's bone. This suboptimal bone healing, described in another face transplant patient, remains unexplained.<sup>8</sup> Whether it is due to a failure of skeletal integration, hypoperfusion of the bone, or linked to the use of osteopenic medications is still to be investigated. Long-term usage of steroids and calcineurin inhibitor is known to impact bone metabolism and increase the risk of fractures.<sup>9</sup> In our case, this is the first fracture the patient presented since the beginning of his treatment.

Steroid withdrawal has been reported in some patients during the long-term postoperative period without

increasing the risk of rejection. This strategy, alongside bisphosphonates medication, could be discussed in patients presenting with pathological fractures.

Fifteen years after the first successful face transplant,<sup>10</sup> our overview on long-term management and follow-up of these particular patients has demonstrated many challenges in the first 2 postoperative years, balancing social acceptance and intensive motor and sensitive rehabilitation with ideal immunosuppression dosing. Our patient is now almost 10 years past his face transplantation surgery; he shows no major metabolic complication and is socially reinstated.

*Alexandre G. Lellouch, MD*

Department of Plastic Reconstructive Surgery  
European Georges Pompidou Hospital (AP-HP)  
20 rue Leblanc, 75015 Paris  
France

E-mail: [alexandre.lellouch@aphp.fr](mailto:alexandre.lellouch@aphp.fr)

## PATIENT CONSENT

*The patient provided written consent for the use of his images.*

## REFERENCES

1. Lantieri L, Hivelin M, Audard V, et al. Feasibility, reproducibility, risks and benefits of face transplantation: a prospective study of outcomes. *Am J Transplant.* 2011;11:367–378.
2. Lantieri L, Grimbert P, Ortonne N, et al. Face transplant: long-term follow-up and results of a prospective open study. *Lancet.* 2016;388:1398–1407.
3. Lellouch AG, Lantieri LA. A second chance at life. *Camb Q Healthc Ethics.* 2019;28:463–467.
4. Etra JW, Raimondi G, Brandacher G. Mechanisms of rejection in vascular composite allotransplantation. *Curr Opin Organ Transplant.* 2018;23:28–33.



5. Etra JW, Shores JT, Sander IB, et al. Trauma-induced rejection in vascularized composite allotransplantation. *Ann Surg.* 2020;271:e113–e114.
6. Cetrulo CL Jr. Mechanical trauma and the skin immune system in hand transplant rejection. *Ann Surg.* 2020;271:e115.
7. Ng ZY, Lellouch AG, Rosales IA, et al. Graft vasculopathy of vascularized composite allografts in humans: a literature review and retrospective study. *Transpl Int.* 2019;32:831–838.
8. Mohan R, Fisher M, Dorafshar A, et al. Principles of face transplant revision: beyond primary repair. *Plast Reconstr Surg.* 2014;134:1295–1304.
9. Löfdahl E, Rådegran G. Osteoporosis following heart transplantation and immunosuppressive therapy. *Transplant Rev (Orlando).* 2017;31:232–239.
10. Devauchelle B, Badet L, Lengelé B, et al. First human face allograft: early report. *Lancet.* 2006;368:203–209.