

Case Report

Post-COVID-19 non-traumatic iliopsoas hematoma: A case report

Mohammed A. Al jumaan, MD^a, Nawaf Alahmari, MD^b, Ahmed Elnour, MD^c,
Saad Alshahrani, MD^c, Arif Mattoo, MD^c and Mohannad Alghamdi, MD^{a,*}

^a Emergency Medicine Department, College of Medicine, Imam Abdulrahman Bin Faisal University, Dammam, KSA

^b Emergency Medicine Department General Practitioner King Fahad Specialist Hospital, Dammam, KSA

^c Emergency Medicine Department, Dr Sulaiman AlHabib Hospital Khobar, KSA

Received 5 February 2022; revised 17 April 2022; accepted 5 July 2022; Available online 19 July 2022



المخلص

الخلفية: مرضى كوفيد-19 ذوي الحالات الحرجة لديهم مخاطر أعلى للإصابة بحالات فرط التخثر. في الوقت الحالي، تم إعطاء العديد من مرضى COVID-19 مضادات التخثر أو العلاجات المضادة للصفائح لتقليل خطر تجلط الدم المنتظم. الورم الدموي في العضلة القطنية هو أحد المضاعفات القاتلة والنادرة لاضطرابات النزيف أو العلاج المضاد للتخثر، والذي يتطور أحياناً ليصبح مهماً سريرياً. الغرض الرئيسي من مراجعة الحالة هذه هو التأكيد على أهمية تشخيص أورام العضلة القطنية الدموية وإمكانية مساهمة مضادات الصفائح في تطورها.

عرض الحالة: نعرض هنا حالة نادر لورم دموي في العضلة القطنية غير رضحي في مريض لا يتناول مضاد للتخثر. المريض رجل يبلغ من العمر 59 عاماً، مصاب بمرض السكري من النوع الثاني، ويتناول أدوية سكر الدم عن طريق الفم، بعد 3 أسابيع من الإصابة بكوفيد-19. كان قد بدأ تناول الأسبرين 81 ملغ عن طريق الفم، مرة واحدة يومياً، للوقاية من الأحداث التخثرية المرتبطة بعدوى كوفيد-19، دون استخدام مضادات التخثر ولا أدوية أخرى. قدم المريض إلى قسم الطوارئ، يشتكي من ضعف الطرف الأيمن التدريجي لمدة أسبوعين، وقد تم تأكيد تشخيص الورم الدموي في العضلة القطنية بناءً على الفحص الإشعاعي.

الاستنتاجات: ينبغي النظر في إمكانية حدوث ورم دموي في العضلة القطنية في المرضى الذين لا يستخدمون مضادات التخثر ولا يعانون من اضطرابات تخثر وراثية أو مكتسبة، ويشتكون من ضعف في الأطراف. يجب دراسة الصلة بين استخدام مضادات الصفائح في مريض كوفيد-19 وتطور نزيف الأنسجة الرخوة (مثل الورم الدموي في العضلة القطنية).

الكلمات المفتاحية: تقرير حالة؛ كوفيد-19؛ العضلة القطنية؛ ورم دموي؛ مضاد للصفائح

Abstract

Background: Critically ill COVID-19 patients have an elevated risk of experiencing hypercoagulable conditions. Currently, many COVID-19 patients have been administered anticoagulation or antiplatelet therapies to lower the risk of systematic thrombosis. Iliopsoas hematoma is a potentially fatal and rare complication of bleeding disorders or anticoagulation therapy which sometimes grows to become clinically significant. The main purpose of this case review is to emphasize the importance of diagnosing iliopsoas hematomas and the possibility of antiplatelet contribution to its development.

Case Presentation: We are reporting a rare presentation of non-traumatic iliopsoas hematoma in a non-anticoagulated patient. The patient is a 59-year-old male, with known type-2 diabetes, on oral hypoglycemic medications, 3-weeks post-COVID-19. He had started aspirin 81 mg orally, once daily, to prevent thrombotic events associated with COVID 19 infection, with no anticoagulant use and no other medications. He came in through the ED, presenting with two weeks history of progressive right lower limb weakness in which an iliopsoas hematoma diagnosis was confirmed based on radiological investigation.

Conclusion: The possibility of iliopsoas hematoma should be considered in non-anticoagulated patients with no inherited or acquired coagulation disorders presenting with limb weakness. The link between antiplatelet use in a COVID-19 patient and the development of soft tissue bleeding (e.g., iliopsoas hematoma) must be studied further.

Keywords: Antiplatelet; Case reports; COVID-19; Hematoma; Iliopsoas

* Corresponding address: Emergency Medicine Department, Imam Abdulrahman bin Faisal University, Dammam, P.O: 32256 – 4763, KSA.

E-mail: mohaghamdi@iau.edu.sa (M. Alghamdi)

Peer review under responsibility of Taibah University.



© 2022 The Authors.

Production and hosting by Elsevier Ltd on behalf of Taibah University. This is an open access article under the CC BY-NC-ND license (<http://creativecommons.org/licenses/by-nc-nd/4.0/>).

Background

The coronavirus disease 2019, first reported in Wuhan, China, has grown into a worldwide pandemic still being fought hard in many places across the globe. A distinct coagulation disorder has been observed in patients with COVID-19 disease with an increased risk of systematic thrombosis, which has a huge mortality risk in patients with COVID-19. Therefore, anticoagulation has been clinically indicated in severe COVID-19 patients as it significantly aids in reducing the risk of systematic thrombosis. On the other hand, the use of antiplatelets in COVID-19 is not recommended based on the RECOVERY and ACTIV-4B outpatient thrombosis prevention trial unless the patient has another indication of antiplatelet use.^{1,2} Despite that, some physicians still prescribe antiplatelet medications for COVID-19 patients to prevent thrombosis associated with the hypercoagulable state of COVID-19 infection. Soft tissue bleeding (e.g., iliopsoas hematoma) is rare and potentially fatal, and it usually occurs in patients who are on anticoagulation therapy or have inherited or acquired coagulation disorders.³ However, the use of antiplatelets is less likely to cause such complication.

The risk of developing iliopsoas hematoma in such patients has not been well documented. Therefore, this case report aims to substantiate the need to promptly diagnose and manage iliopsoas hematomas, especially with the ongoing COVID-19 pandemic, and to emphasize the risk of antiplatelet use with the possibility of its contribution to the development of iliopsoas hematoma.

Case presentation

A 59-year-old male with a known case of type-2 Diabetes mellitus on oral hypoglycemic medications presented to the ED with weakness in the lower right limb for two weeks. Three weeks before his presentation, he was diagnosed with COVID-19 infection through PCR of nasopharyngeal secretions after presenting to the ED with cough, fever, and generalized body ache. At the time, he was started on oral aspirin 81 mg once daily to prevent thrombotic events associated with COVID-19 infection, and paracetamol as needed for fever and body pain, with no anticoagulant use and no other medications. Three weeks later, He came in through our ED in a wheelchair. The patient's complaint was weakness in his lower right limb that began two weeks ago. Weakness was descending to the right foot and was gradually worsening day by day. The patient had no history of physical trauma or vomiting and no blurred vision, back pain, sphincters' involvement, or neurological deficit.

On examination, a well-looking male was in a wheelchair and was conscious, alert, and afebrile. His tympanic temperature was 36.7, blood pressure was 138/78 (sitting position), heart rate 88 beats per minute, oxygen saturation 98% on room air, and a normal respiratory rate.

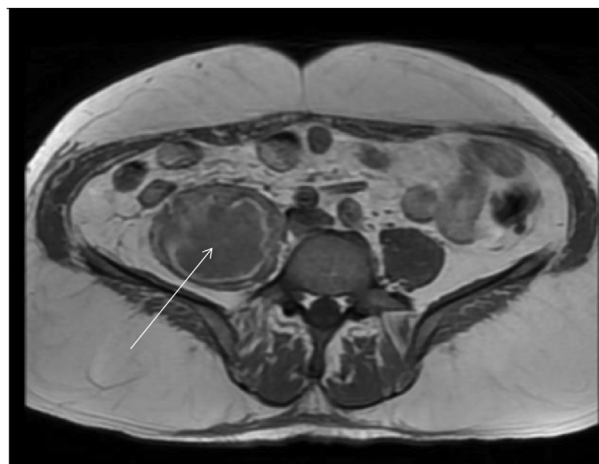


Figure 1: Axial view of a pelvic MRI with the white arrow pointing to the large intramuscular fluid collection.

A head to toe exam was significant for a small bed sore over the right gluteal area due to the patient's inability to walk in the last two weeks. Neurological examination revealed intact cranial nerves with weakness in power over the right leg descending up to the foot, with an inability to extend the hip. The rest of exam was normal.

Laboratory investigations revealed normal white blood cells; elevated C-reactive protein (CRP) levels, 11.6; elevated erythrocyte sedimentation rates (ESR), 54; and high platelets, 685. The patient had a decreased hematocrit of 35, with a hemoglobin of 11.2, a prothrombin time (PT) of 10.9, a partial thromboplastin time (PTT) of 24.2, and an international normalized ratio (INR) of 1.01.

An MRI of the pelvic area was conducted and read by a radiology consultant. The scan revealed the presence of large intramuscular and multilocular fluid collection within the right psoas muscle (Figure 1, Arrow) & (Figure 2, Arrow). The fluid collection measured 17 × 7 cm and contained internal hemorrhagic products. This likely represented a multilocular

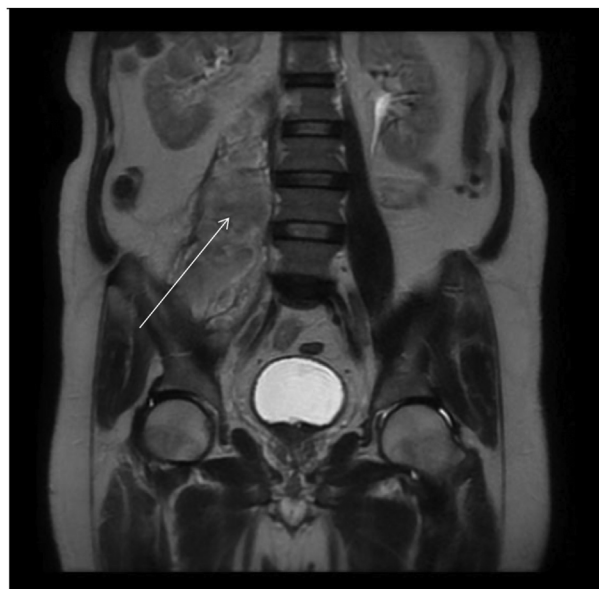


Figure 2: Coronal view of a pelvic MRI with the white arrow pointing to the large intramuscular fluid collection.

intramuscular hematoma. Another 6.4 × 1.4 cm intramuscular collection was noted within the left gluteus maximus muscle.

The patient was admitted as an iliopsoas hematoma for observation. Aspirin stopped, and the patient gradually improved without intervention. One week later, he regained full limb function and was discharged home without re-imaging. He was discharged on his oral hypoglycemic medications only. On follow-up one month later, the patient was doing fine with no deterioration.

Discussion

Spontaneous iliopsoas hematoma is a retroperitoneal collection of blood involving the iliopsoas muscle unit. The major causes of non-traumatic iliopsoas hematomas are hemophilia and anticoagulation or antiplatelet therapy.^{4–6} Critically ill COVID-19 patients experience hemostatic changes due to the cytokine storm accompanying the SARS-CoV-2 infection, leading to a hypercoagulable state development.⁷ An anticoagulant like heparin primarily works by inhibiting thrombin formation⁸; these anticoagulants may lead to hematoma. One to seven out of a hundred patients on anticoagulation therapy suffer from a bleeding complication every year.⁹ A recent study revealed that iliopsoas hematomas had an incidence rate of 7.6 per 1000 cases of hospitalized COVID-19 patients treated with low-molecular-weight heparin for micro-and macro-pulmonary thrombosis.⁷ On the other hand, antiplatelet medications such as aspirin are usually associated with gastrointestinal bleeding rather than iliopsoas hematoma. However, few case reports describing the incidence of muscular hematomas in antiplatelet users were found in the literature.^{10–12}

The diagnosis of iliopsoas hematoma is sometimes delayed due to a variety of its presentation forms with many differential diagnoses. Physicians should have a high index of suspicion of retroperitoneal hematoma (e.g., iliopsoas hematoma) in patients presenting with symptoms suggestive of femoral nerve compression and back pain, especially in anticoagulated patients or those with inherited coagulopathy. A delay in the diagnosis of retroperitoneal hematoma can lead to fatal consequences. Since the case report above reveals no history of trauma, normal hemostasis blood investigations, and normal liver and renal profiles, with no family history or personal history of coagulation disorders, the most likely cause of iliopsoas hematoma that was revealed in the MRI scan was the aspirin antiplatelet medication he had started to take. Based on the patient's presentation, absence of systemic manifestation of the infection, laboratory results, and the radiological picture as per the radiologist, the fluid collection is unlikely to be an abscess.

A similar case reported by Surgical Neurology International concluded that for patients on anticoagulation therapy or those with bleeding disorders such as hemophilia, the sudden onset of back pain should warrant clinical consideration of bleeding complications.¹³ However, the link between antiplatelet use and the development of iliopsoas hematoma is not well described in the literature, with only a few case reports of such presentations.^{11,14} A similar case report was published in 2001 by Nakao et al. about a patient who presented with back and abdominal pain with weakness and numbness along the femoral nerve distribution. He has been

on ticlopidine antiplatelet medication for four years since he was diagnosed with ischemic stroke. A CT scan of the patient's abdomen and pelvis showed an iliopsoas hematoma causing femoral nerve compression. His laboratory investigations showed normal hemostatic, liver, and renal profiles, which suggested that the antiplatelet medication played a role in the hematoma development.¹²

The management of such hematomas is controversial. Practitioners use various approaches such as observation, transarterial embolization, CT-guided percutaneous drainage,¹⁵ and surgical intervention.¹⁴ Control trials are few in this condition, as the cases are not frequent and have low incidence rates.¹⁶ However, recent studies show that conservative management is acceptable for stable patients. This can be done by discontinuing anticoagulant therapy and blood product resuscitation. In cases where patients present with active bleeding, the interventional approach is the best, such as embolization. Currently, it is thought that open surgery should only be considered in the case of patients who remain hemodynamically unstable even after volume resuscitation or where interventional radiology is not viable or is unavailable.¹⁷

Conclusion

The possibility of iliopsoas hematoma should be considered in non-anticoagulated patients with no inherited or acquired coagulation disorders presenting with limb weakness. The relation between antiplatelet use in COVID-19 patients and the development of soft tissue bleeding (e.g., iliopsoas hematoma) must be further studied. That being said, hematomas, whether a traumatic or spontaneous in occurrence, usually resolve spontaneously and without severe clinical complications, unless they are large, or are compressing the surrounding important structures.

Source of funding

The authors would like to acknowledge patients who participated in this study.

This research did not receive any specific grant from funding agencies in the public, commercial, or not for profit sectors.

Conflict of interest

The authors have no conflict of interest to declare.

Ethical approval

Verbal informed consent for publication was taken from the patient who has a full capacity.

Authors contributions

Literature review was done by MAJ and MAG. Patient's data and follow up was collected and done by SS. NBA and AEE wrote initial and final draft of article, and AIM provided logistic support and reviewed the article with contributed in writing the discussion and conclusion parts. MAJ had

reviewed the submission and followed the authors in all steps as the first author. MAG submitted the article for publication. All authors have critically reviewed and approved the final draft and are responsible for the content and similarity index of the manuscript.

References

1. RECOVERY Collaborative Group. Aspirin in patients admitted to hospital with COVID-19 (RECOVERY): a randomised, controlled, open-label, platform trial. **Lancet** 2022 Jan 8; 399(10320): 143–151. [https://doi.org/10.1016/S0140-6736\(21\)01825-0](https://doi.org/10.1016/S0140-6736(21)01825-0). Epub 2021 Nov 17. PMID: 34800427; PMCID: PMC8598213.
2. Connors JM, Brooks MM, Sciruba FC, et al. Effect of antithrombotic therapy on clinical outcomes in outpatients with clinically stable symptomatic COVID-19: the ACTIV-4B randomized clinical trial. **JAMA** 2021 Nov 2; 326(17): 1703–1712. <https://doi.org/10.1001/jama.2021.17272>. PMID: 34633405; PMCID: PMC8506296.
3. Balkan C, Kavakli K, Karapinar D. Iliopsoas haemorrhage in patients with haemophilia: results from one centre. **aemophilia** 2005; 11(5): 463–467. <https://doi.org/10.1111/j.1365-2516.2005.01123.x>.
4. Beyth RJ. Management of haemorrhagic complications associated with oral anticoagulant treatment. **Expert Opin Drug Saf** 2002 Jul; 1(2): 129–136. <https://doi.org/10.1517/14740338.1.2.129>. PMID: 12904147.
5. Brower TD, Wilde AH. Femoral neuropathy in hemophilia. **J Bone Joint Surg Am** 1966 Apr; 48(3): 487–492. PMID: 4286456.
6. Choa GPH, Lim CS. Iliopsoas haematoma: an uncommon differential diagnosis for groin pain. **Hong Kong J Emerg Med** 2011 May 3; 18(3): 173–176. <https://doi.org/10.1177/102490791101800309>.
7. Vergori A, Pianura E, Lorenzini P, et al. Spontaneous iliopsoas haematomas (IPHs): a warning for COVID-19 inpatients. **Ann Med** 2021; 53(1): 295–301. <https://doi.org/10.1080/07853890.2021.1875498>.
8. Kroll SS, Miller MJ, Reece GP, et al. Anticoagulants and hematomas in free flap surgery. **Plast Reconstr Surg** 1995; 96(3): 643–647.
9. Choa G, Lim C. Iliopsoas haematoma: an uncommon differential diagnosis for groin pain. **Hong Kong J Emerg Med** 2011; 18(3): 173–176. <https://doi.org/10.1177/102490791101800309>.
10. Jurisic D, Doko M, Glavan E, Vidovic D, Matkovic K, Pitlovic V. Spontaneous retroperitoneal haematoma associated with clopidogrel therapy mimicking acute appendicitis. **Br J Clin Pharmacol** 2006 Aug; 62(2): 248–249. <https://doi.org/10.1111/j.1365-2125.2006.02608.x>. PMID: 16842403; PMCID: PMC1885089.
11. Otrock ZK, Sawaya JI, Zebian RC, Taher AT. Spontaneous abdominal hematoma in a patient treated with clopidogrel and aspirin. **Ann Hematol** 2006 Oct; 85(10): 743–744. <https://doi.org/10.1007/s00277-006-0140-2>. Epub 2006 Jul 4. PMID: 16821017.
12. Nakao A, Sakagami K, Mitsuoka S, Uda M, Tanaka N. Retroperitoneal hematoma associated with femoral neuropathy: a complication under antiplatelets therapy. **Acta Med Okayama** 2001 Dec; 55(6): 363–366. <https://doi.org/10.18926/AMO/31998>. PMID: 11779099.
13. Basheer A, Jain R, Anton T, Rock J. Bilateral iliopsoas hematoma: case report and literature review. **Surg Neurol Int** 2013 Sep 20; 4: 121. <https://doi.org/10.4103/2152-7806.118561>. PMID: 24232386; PMCID: PMC3815018.
14. Kameda T, Fujita M, Takahashi I. Diagnosis of traumatic iliopsoas hematoma using point-of-care ultrasound. **Crit Ultrasound J** 2011; 3: 59–61. <https://doi.org/10.1007/s13089-011-0065-4>.
15. Risse JH, Keulers P, Günther RW. CT-gesteuerte perkutane drainage retro- und extra-peritonealer Abszesse und Flüssigkeitsverhalte [CT guided percutaneous drainage of retro- and extra-peritoneal abscesses and fluid collection]. **Rofo** 1998 Mar; 168(3): 281–286. <https://doi.org/10.1055/s-2007-1015126>. German. PMID: 9551116.
16. Katz SG, Nelson IW, Atkins RM, Duthie RB. Peripheral nerve lesions in hemophilia. **J Bone Joint Surg Am** 1991; 73(7): 1016–1019.
17. Kwon OY, Lee KR, Kim SW. Spontaneous iliopsoas muscle hematoma. **Emerg Med J** 2009; 26(12): 863. <https://doi.org/10.1136/emj.2008.066365>.

How to cite this article: Al jumaan MA, Alahmari N, Elnour A, Alshahrani S, Mattoo A, Alghamdi M. Post-COVID-19 non-traumatic iliopsoas hematoma: A case report. *J Taibah Univ Med Sc* 2023;18(1):61–64.