

arthropod-based transmission *F. philomiragia* has not been suspected. However, *F. philomiragia* DNA was found in 19% of a sample of dog ticks (*Dermacentor reticulatus*) in France (9). This finding suggests that *D. reticulatus*, which is now broadly distributed across Europe because of global warming and increased travel with pets, may have a role in the life cycle and transmission of *F. philomiragia* (10). The patient did not own a dog and did not recall having had contact with dogs. However, his job (a municipal gardener) constituted a risk factor for tick bites in urban green spaces.

Although multiple points for *F. philomiragia* to enter this patient were suspected, none were laboratory confirmed. Further investigation is needed to better define the natural life cycle of this organism, especially the role of tick species in its transmission.

Acknowledgments

We thank Michel Simonet for critically reading the manuscript.

Dr. Kreitmann is a resident in the Division of Internal Medicine at Lille University Medical Center (Lille, France). His main interests are host-pathogen interactions and the epidemiology and immunology of infectious disease.

References

1. Wenger JD, Hollis DG, Weaver RE, Baker CN, Brown GR, Brenner DJ, et al. Infection caused by *Francisella philomiragia* (formerly *Yersinia philomiragia*). A newly recognized human pathogen. *Ann Intern Med*. 1989;110:888–92. <http://dx.doi.org/10.7326/0003-4819-110-11-888>
2. Mailman TL, Schmidt MH. *Francisella philomiragia* adenitis and pulmonary nodules in a child with chronic granulomatous disease. *Can J Infect Dis Med Microbiol*. 2005;16:245–8.
3. Maurin M, Pelloux I, Brion JP, Del Baño JN, Picard A. Human tularemia in France, 2006–2010. *Clin Infect Dis*. 2011;53:e133–41. <http://dx.doi.org/10.1093/cid/cir612>
4. Duodu S, Larsson P, Sjödin A, Forsman M, Colquhoun DJ. The distribution of *Francisella*-like bacteria associated with coastal waters in Norway. *Microb Ecol*. 2012;64:370–7. <http://dx.doi.org/10.1007/s00248-012-0023-0>
5. Whitehouse CA, Kesterson KE, Duncan DD, Eshoo MW, Wolcott M. Identification and characterization of *Francisella* species from natural warm springs in Utah, USA. *Lett Appl Microbiol*. 2012;54:313–24. <http://dx.doi.org/10.1111/j.1472-765X.2012.03214.x>
6. Berrada ZL, Telford SR III. Diversity of *Francisella* species in environmental samples from Martha's Vineyard, Massachusetts. *Microb Ecol*. 2010;59:277–83. <http://dx.doi.org/10.1007/s00248-009-9568-y>
7. Brodie EL, DeSantis TZ, Parker JP, Zubieta IX, Piceno YM, Andersen GL. Urban aerosols harbor diverse and dynamic bacterial populations. *Proc Natl Acad Sci U S A*. 2007;104:299–304. <http://dx.doi.org/10.1073/pnas.0608255104>
8. Qu PH, Chen SY, Scholz HC, Busse HJ, Gu Q, Kämpfer P, et al. *Francisella guangzhouensis* sp. nov., isolated from air-conditioning systems. *Int J Syst Evol Microbiol*. 2013;63:3628–35. <http://dx.doi.org/10.1099/ijms.0.049916-0>
9. Bonnet S, de la Fuente J, Nicolle P, Liu X, Madani N, Blanchard B, et al. Prevalence of tick-borne pathogens in adult *Dermacentor* spp. ticks from nine collection sites in France. *Vector Borne Zoonotic Dis*. 2013;13:226–36. <http://dx.doi.org/10.1089/vbz.2011.0933>
10. Beugnet F, Marié JL. Emerging arthropod-borne diseases of companion animals in Europe. *Vet Parasitol*. 2009;163:298–305. <http://dx.doi.org/10.1016/j.vetpar.2009.03.028>

Address for correspondence: Nadine Lemaître, Laboratoire de Bactériologie-Hygiène, Centre de Biologie-Pathologie, CHRU Lille, boulevard Jules Leclercq, 59037 Lille CEDEX, France; email: nadine.lemaitre@chru-lille.fr.

Severe Ocular Cowpox in a Human, Finland

Paula M. Kinnunen, Juha M. Holopainen, Heidi Hemmilä, Heli Piiparinen, Tarja Sironen, Tero Kivelä, Jenni Virtanen, Jukka Niemimaa, Simo Nikkari, Asko Järvinen, Olli Vapalahti

Author affiliations: University of Helsinki, Helsinki, Finland (P.M. Kinnunen, J.M. Holopainen, H. Piiparinen, T. Sironen, T. Kivelä, J. Virtanen, O. Vapalahti); Finnish Defence Forces, Helsinki (P.M. Kinnunen, H. Hemmilä, H. Piiparinen, S. Nikkari); Helsinki University Hospital, Helsinki (J.M. Holopainen, T. Kivelä, A. Järvinen, O. Vapalahti); Natural Resources Institute Finland (Luke), Vantaa, Finland (J. Niemimaa)

DOI: <http://dx.doi.org/10.3201/eid2112.150621>

To the Editor: We describe cowpox with corneal involvement in a 31-year-old atopic woman who lived in southern Finland and was unvaccinated for smallpox. In August 2009, she noticed irritation and edema in her right eye and sought care from a local physician; she started topical antimicrobial drug therapy and oral cephalexin 2 days later. Over the following week, fever developed (37.6°C–39.0°C), edema developed on half her face, the eye became increasingly painful, and visual acuity decreased. The conjunctiva was severely chemotic and hyperemic, but the cornea was clear and the other eye unaffected.

Microbiologic samples taken from the eye 11 days after onset showed neither bacteria nor respiratory viruses. Orbital tomography results were normal. The patient was hospitalized, and broad-spectrum intravenous antimicrobial treatment (meropenem, vancomycin, valacyclovir, and fluconazole) was started, combined with topical corticosteroids and antimicrobial drugs. Within 2 weeks, the conjunctiva showed necrosis, and epithelial erosions appeared in the lower cornea, but visual acuity normalized (online Technical Appendix Figure, panels A, B, <http://wwwnc.cdc.gov/EID/article/21/12/15-0621-Techapp.pdf>).

A strong cytopathic effect was observed in Vero cells infected with conjunctival swab (online Technical Appendix

Table 1), but the virus was unidentifiable by routine methods. In electron microscopy, cell culture and tear fluid samples contained particles with typical orthopoxvirus (OPV) morphology. PCRs for hemagglutinin (1) and 14-kDa genes (2) verified OPV infection. Additional PCRs and sequencing confirmed zoonotic cowpox virus (CPXV) with strain designation FIN/K2009. Nucleotide sequences of the hemagglutinin, thymidine kinase, and A-type inclusion body protein genes were identical to those of CPXV strains T2000 and E1989 previously identified in Finland (3). In phylogenetic analysis (Figure), CPXV/FIN/K2009 clustered with strains from Austria and shared ancestry with vaccinia virus. OPV IgG and IgM were detected by immunofluorescence assay (3) in serum samples up to 5 months after symptom onset (online Technical Appendix Table 1).

The patient was started on intravenous polyclonal gammaglobulin and topical trifluorothymidine with in vitro anti-OPV effects; nevertheless, corneal erosions enlarged, corneal stromal edema ensued, and intraocular pressure increased (online Technical Appendix Figure, panel C), suggesting trabeculitis. Topical autologous serum drops had no effect. Periorbital edema slowly resolved, but corneal erosions persisted. Amniotic membrane transplantation (AMT) (4) was performed 2.5 months after onset. The inferior cornea melted, and the cornea lost transparency (online Technical Appendix Figure, panel D). AMT was repeated twice at 1-month intervals because of corneal thinning.

At 3.5 months after symptom onset, tecovirimat (400 mg 2×/d) was given orally for 14 days. Despite treatment,

ocular OPV PCR test results remained positive until 9 months after onset (online Technical Appendix Table 1), and corneal melting progressed (online Technical Appendix Figure, panel E). Corneal collagen cross-linking and a fourth AMT were performed at 5 months after onset with partial success (online Technical Appendix Figure, panel F).

At 1 year after symptom onset, corneal limbal stem cell deficiency with deep corneal neovascularization was evident. Autologous limbal stem cell transplantation from the patient's other eye and another AMT were performed, resulting in stable corneal surface 2 months later (online Technical Appendix Figure, panel G). Neovascularization regressed, the cornea cleared, and vision improved (online Technical Appendix Figure, panels H, I).

Cowpox is transmitted to humans sporadically from rodents or cats (5). We snap-trapped 23 wild rodents from the yard of the patient's home and from an adjacent meadow and trapped 136 rodents from 3 other regions 30–100 km from the patient's home (online Technical Appendix Table 2). We also collected 8 environmental samples from the patient's storehouse. In accordance with the Finnish Act on Use of Animals for Experimental Purposes (62/2006) and the Finnish Animal Experiment Board's later decision (May 16, 2007), the animal capture technique used is not an animal experiment and requires no ethics license.

Diluted blood for IFA was collected from all rodents (6), and DNA was extracted from rodent liver and lungs and from environmental samples. One vole and 1 mouse from the meadow were seropositive for OPV; however,

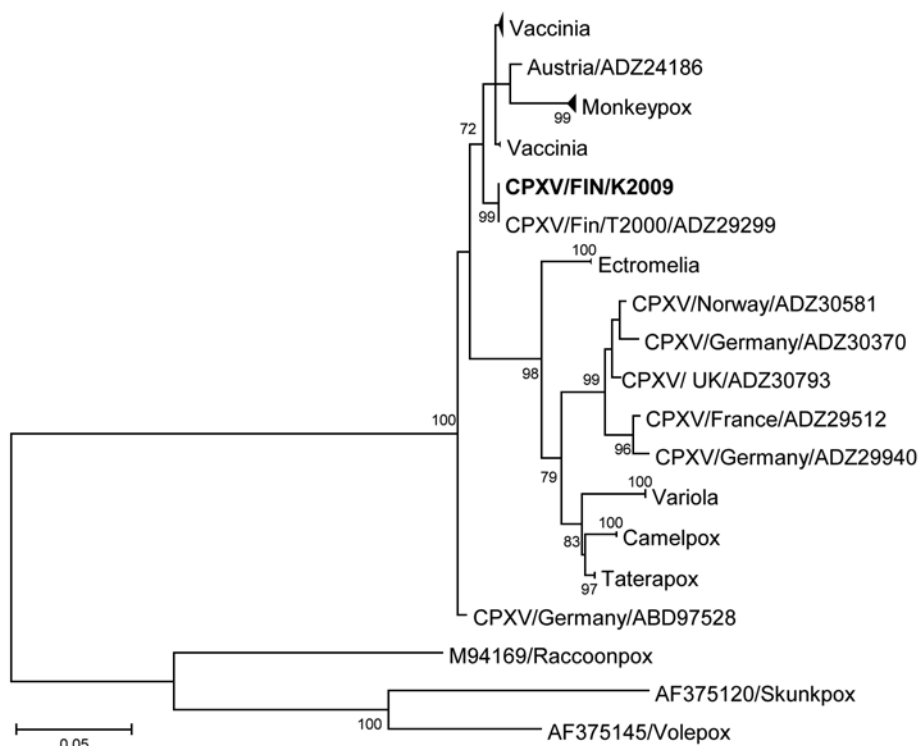


Figure. Phylogenetic tree of orthopoxviruses constructed on the basis of the hemagglutinin gene; boldface indicates the CPXV strain infecting the patient described in this article. The phylogeny shows that the sequence derived from this patient represents a locally circulating strain that shares ancestry with a few other CPXV strains and vaccinia virus. A maximum-likelihood tree was built with 1,000 bootstraps in MEGA 6.06 software (<http://www.megasoftware.net/>). MEGA was used to estimate the best nucleotide substitution model (general time reversible plus invariable sites). The sequence dataset was compiled from the Virus Pathogen Resource database (<http://www.viprbrc.org>) and aligned by using MUSCLE (<http://www.ebi.ac.uk/Tools/msa/muscle/>). Scale bar indicates nucleotide substitutions per site. CPXV, cowpox virus.

no CPXV DNA was amplifiable in the samples from the liver, lungs, or environment (online Technical Appendix Table 2).

CPXV infection may manifest in severe ocular forms along with self-limiting cutaneous pox (5). Our patient had keratitis with no other identifiable cause but CPXV. Culture and PCR from early conjunctival samples and serology confirmed the etiologic diagnosis.

Our case and that of another report (7) highlight the challenges of treating cowpox keratitis. Topical and systemic antiviral drugs and AMT appear ineffective during the acute phase. Corneal melting and scarring continued as long as CPXV was observed and until combined limbal stem cell and AMT treatment had favorable outcomes. Anamnesis of therapy-resistant keratitis should include information on rodent contacts.

We dated the infection to mid-August (incubation 7–21 days). Catching OPV-IgG-positive rodents close to the patient's home 2 months after onset showed that OPVs were circulating in the local rodent population and indicated the putative role of CPXV-infected voles as the source of infection.

The latest cowpox outbreak in Central Europe involved several humans and pets (8). This patient was born in 1977, after Finland ceased smallpox vaccinations. Declining cross-reactive smallpox-vaccination immunity enables emergence of unusual cowpox infections in humans (9).

Acknowledgments

We thank Katja Koskela with the Finnish Defence Forces for help with the sequence analysis program.

This research was partially funded by EU grant GOCE-2003-010284 EDEN.

References

- Putkuri N, Piiparinen H, Vaheri A, Vapalahti O. Detection of human orthopoxvirus infections and differentiation of smallpox virus with real-time PCR. *J Med Virol*. 2009;81:146–52. <http://dx.doi.org/10.1002/jmv.21385>
- Olson VA, Laue T, Laker MT, Babkin IV, Drosten C, Shchelkunov SN, et al. Real-time PCR system for detection of orthopoxviruses and simultaneous identification of smallpox virus. *J Clin Microbiol*. 2004;42:1940–6. <http://dx.doi.org/10.1128/JCM.42.5.1940-1946.2004>
- Pelkonen PM, Tarvainen K, Hynninen A, Kallio ERK, Henttonen H, Palva A, et al. Cowpox with severe generalized eruption, Finland. *Emerg Infect Dis*. 2003;9:1458–61. <http://dx.doi.org/10.3201/eid0911.020814>
- Mattila JS, Korsbäck A, Krootila K, Holopainen JM. Treatment of *Pseudomonas aeruginosa* keratitis with combined corneal cross-linking and human amniotic membrane transplantation. *Acta Ophthalmol*. 2013;91:e410–1. <http://dx.doi.org/10.1111/aos.12115>
- Haller SL, Peng C, McFadden G, Rothenburg S. Poxviruses and the evolution of host range and virulence. *Infect Genet Evol*. 2014;21:15–40. <http://dx.doi.org/10.1016/j.meegid.2013.10.014>
- Kinnunen PM, Henttonen H, Hoffmann B, Kallio ERK, Korthase C, Laakkonen J, et al. Orthopoxvirus infections in Eurasian wild rodents. *Vector Borne Zoonotic Dis*. 2011;11:1133–40. <http://dx.doi.org/10.1089/vbz.2010.0170>
- Graef S, Kurth A, Auw-Haedrich C, Plange N, Kern WV, Nitsche A, et al. Clinicopathological findings in persistent corneal cowpox infection. *JAMA Ophthalmol*. 2013;131:1089–91. <http://dx.doi.org/10.1001/jamaophthalmol.2013.264>
- Becker C, Kurth A, Hessler F, Kramp H, Gokel M, Hoffmann R, et al. Cowpox virus infection in pet rat owners: not always immediately recognized. *Dtsch Arztebl Int*. 2009;106:329–34.
- Rimoin AW, Mulembakani PM, Johnston SC, Lloyd Smith JO, Kisalu NK, Kinkela TL, et al. Major increase in human monkeypox incidence 30 years after smallpox vaccination campaigns cease in the Democratic Republic of Congo. *Proc Natl Acad Sci U S A*. 2010;107:16262–7. <http://dx.doi.org/10.1073/pnas.1005769107>

Address for correspondence: Paula M. Kinnunen, Finnish Food Safety Authority Evira, Mustialankatu 3, 00790 Helsinki, Finland; email: paula.kinnunen@helsinki.fi

Human Alveolar Echinococcosis, Czech Republic, 2007–2014

Libuše Kolářová, Jana Matějů, Jiří Hrdý, Hana Kolářová, Lubomíra Hozáková, Vita Žampachová, Herbert Auer, František Stejskal

Author affiliations: National Reference Laboratory for Tissue Helminthoses, General University Hospital, Prague, Czech Republic (L. Kolářová, J. Matějů); Charles University First Faculty of Medicine, Prague (L. Kolářová, J. Matějů, J. Hrdý, František Stejskal, H. Kolářová); University Hospital, Ostrava, Czech Republic (L. Hozáková); Masaryk University Faculty of Medicine, Brno, Czech Republic (V. Žampachová); St. Anne's University Hospital, Brno (V. Žampachová); Medical University Vienna, Austria (H. Auer)

DOI: <http://dx.doi.org/10.3201/eid2112.150743>

To the Editor: Human alveolar echinococcosis (AE) is a zoonotic parasitic disease caused by larvae of *Echinococcus multilocularis* tapeworms that manifests most often in the host's liver, although it can infect the lungs, brain, and other organs. Clinical symptoms usually develop after a long incubation period (5–15 years), causing considerable diagnostic difficulties and delay in treatment. The disease is reported in all countries neighboring the Czech Republic: Slovakia, Poland, Austria, and Germany (1,2). To complete data from central Europe, we present results on the occurrence of AE in the Czech Republic collected by the National Reference Laboratory for Tissue Helminthoses during 2007–2014.