

Correlation between the Time to Surgery and That to Recovery from Postoperative Diplopia Based on a Single-Center, Retrospective Experience: A Case Series of 11 Patients

Nam Hoon Kim, Seok Joo Kang

Department of Plastic and Reconstructive Surgery, Busan Paik Hospital, Inje University College of Medicine, Busan, Korea

Original Article

Background We conducted this study to identify the correlation between the time to surgery and that to recovery from postoperative diplopia.

Methods In the current single-center, retrospective study, we enrolled a total of 11 patients (n = 11) who were diagnosed with white-eyed blowout fracture and underwent surgical operation at our institution between January 2009 and January 2013. To identify the correlation between the time to surgery and that to recovery from postoperative diplopia, we divided our patients into the three groups: the group A (time to surgery, <2 days) (n = 4), the group B (time to surgery, 3–7 days) (n = 4) and the group C (n = 3) (time to surgery, 8–60 days). Then, we compared such variables as sex, age, signs of soft tissue injury, preoperative nausea/vomiting, the degree of preoperative diplopia and the side of the fracture on computed tomography scans between the three groups.

Results In our series, mean age at the onset of trauma was nine years (range, 5–16 years); the mean time to surgery was 30 days (range, 2–60 days); and the mean follow-up period was one year (range, 6 months–2 years). Our results showed that the time to recovery was shorter in the patients with a shorter time to surgery.

Conclusions We found that the degree of recovery from impaired ocular motility and diplopia was the highest in the patients undergoing surgical operations within 48 hours of the onset of trauma with the reconstruction of the fracture sites using implant materials.

Keywords Orbital fractures / Diplopia / Patients

Correspondence: Seok Joo Kang
Department of Plastic and Reconstructive Surgery, Busan Paik Hospital, Inje University College of Medicine, 75 Bokji-ro, Busanjin-gu, Busan 614-735, Korea
Tel: +82-51-890-6236
Fax: +82-51-894-7976
E-mail: sonydr@naver.com

No potential conflict of interest relevant to this article was reported.

Received: 5 Mar 2014 • Revised: 13 Jul 2014 • Accepted: 14 Jul 2014

pISSN: 2234-6163 • eISSN: 2234-6171 • <http://dx.doi.org/10.5999/aps.2014.41.5.486> • Arch Plast Surg 2014;41:486-492

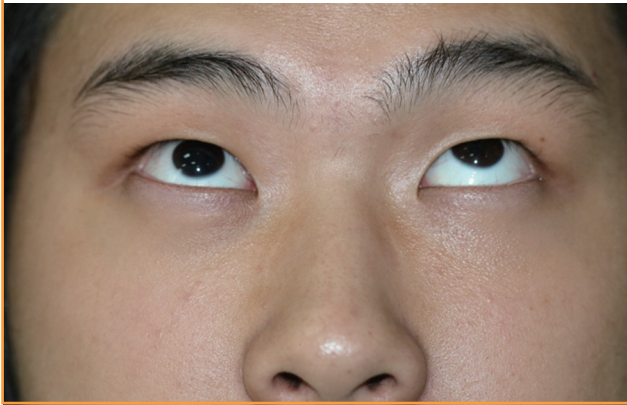INTRODUCTION

White-eyed blowout fracture was first described by Jordan et al. [1] in 1998, and it is characterized by double vision and upward gaze restriction in children (Fig. 1). It is generally observed as a small blowout fracture, on computed tomography (CT) scans,

with no other signs of soft-tissue injury despite severe trauma to the orbital wall [1]. It often remains undetected because of its small size on CT scans; this is particularly seen in patients without edema or subcutaneous/subconjunctival hemorrhage. A lack of signs of soft tissue injury poses a diagnostic challenge for surgeons [2]. Moreover, surgeons also encounter challenging

Fig. 1. Clinical presentations of white-eyed blowout fracture

Children with white-eyed blowout fracture are characterized by double vision and upward gaze restriction.



problems when they experience a difficulty in performing history taking or physical examination in younger children [3].

It has been hypothesized that there is a close relationship between the optimal timing of surgery and the time to recovery from postoperative diplopia in patients with white-eyed blowout fracture. That is, it has been presumed that a timely release of the muscle and soft tissue trapped in the fragments of orbital fractures would improve ocular motility and accelerate the time to recovery from diplopia.

There is a variability in the clinical manifestations of orbital blowout fracture between adults and children. Adults with orbital fracture are vulnerable to orbital floor defects. But children commonly present with linear fractures of the orbital floor. This makes them vulnerable to the herniation of the orbital contents. Ocular muscles or soft tissue can be entrapped between the fracture fragments; this may increase the intraocular pressure, followed by ischemia. Presumably, the ischemic muscle necrosis might lead to the muscle fibrosis, impaired ocular motility and persistent diplopia. It has been recently shown that it would be mandatory to release the entrapped muscle or soft tissue immediately after surgery in children with white-eyed blowout fracture. Thus, surgeons could obtain good postoperative outcomes. Furthermore, the upward gaze restriction arises from the entrapment of the inferior rectus muscle between the fracture fragments. It is therefore recommended that patients with white-eyed blowout fracture be surgically treated as promptly as possible.

Given the above background, we have speculated that it would be effective in promptly achieving a recovery of diplopia and promoting the recovery of postoperative diplopia if surgeons shorten the time to surgery in children with white-eyed blowout fracture. We therefore conducted this study to identify the correlation between the time to surgery and that to recovery from

postoperative diplopia.

METHODS

Study design and patients

We conducted the current single-center, retrospective study in a total of 11 patients ($n = 11$) who were diagnosed with white-eyed blowout fracture and underwent surgical operation at our institution between January 2009 and January 2013.

Inclusion criteria for the current study are as follows: 1) The patients aged 16 years or younger, 2) The patients with preoperative upward gaze limitation accompanied by diplopia, 3) The patients with unilateral orbital floor fracture confirmed on CT scans, 4) The patients with impaired ocular motility based on the difference in the lower margin of the pupil at upward gaze between the non-affected and affected side (Fig. 2), 5) The patients with a history of trauma, diplopia, upward gaze limitation and headache.

In our clinical series of patients, we made a diagnosis of white-eyed blowout fracture when there were orbital floor fractures on CT scans.

Exclusion criteria for the current study are as follows: 1) The patients aged 16 years or older, 2) The patient with a past history of trauma or ophthalmologic or neurological complications, 3) The patients with multiple fractures such as bilateral orbital ones, 4) The patients where the fracture involved more than 50% of the orbit on CT scans, 5) The patients with asymptomatic orbital fractures.

The current study was approved by the Institutional Review Board of our medical institution. Informed consent was waived due to the retrospective nature of the current study.

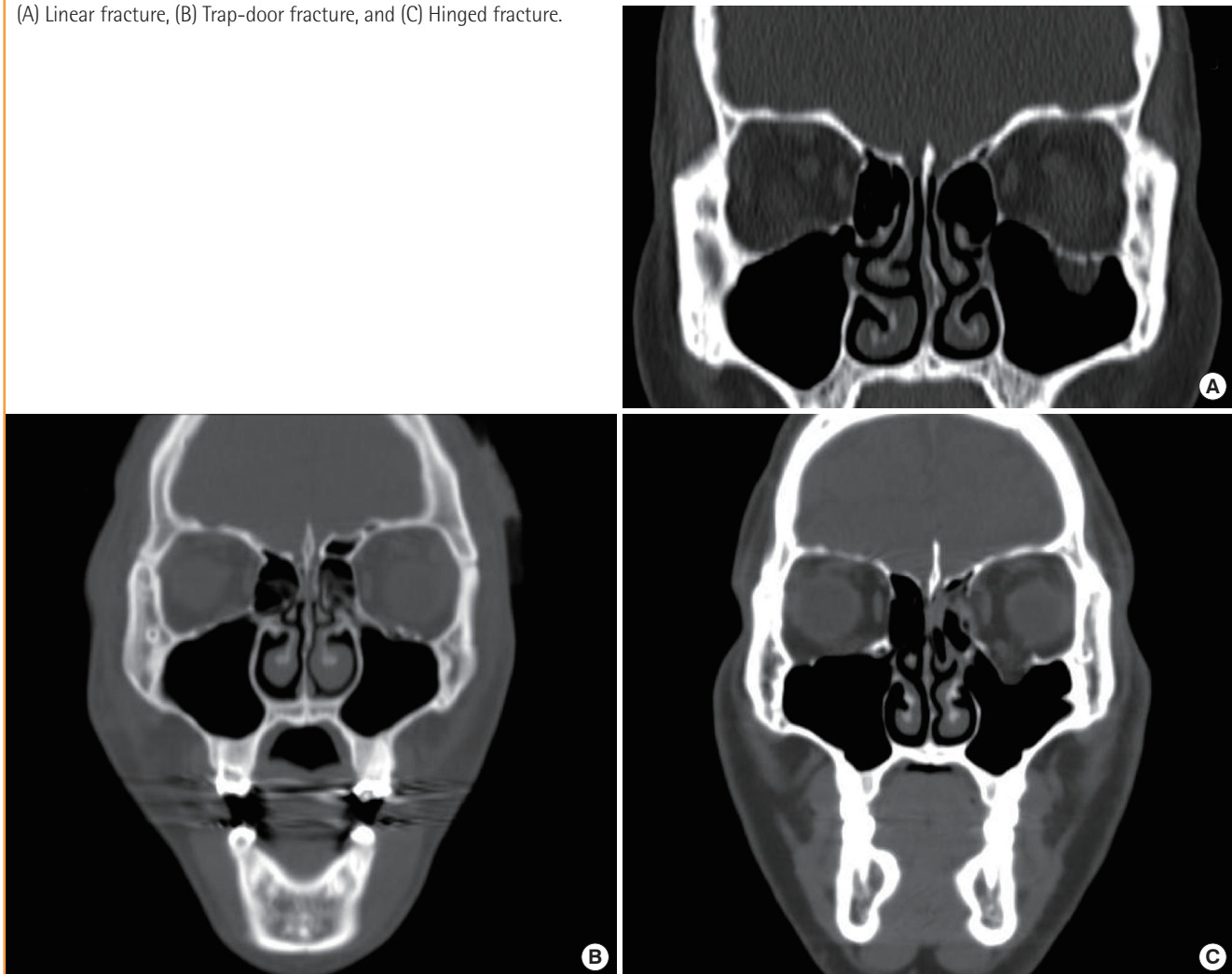
Through a retrospective analysis of the medical records, we evaluated the clinical symptoms, postoperative outcomes, such as ocular motility, diplopia and headache, and radiological findings.

Preoperative CT

On preoperative coronal and axial CT scans, we examined the type of nature of the fracture, the involvement of the orbital wall and the possibility of muscle or soft tissue entrapment [4]. We classified the fractures into the following types: 1) Linear, minimally displaced breaks that developed parallel and medial to the inferior orbital groove, 2) Trapdoor fractures that transiently separated near the groove and closed spontaneously, entrapping soft tissue, 3) Hinged fractures that separated along the inferior groove and pivoted at the inferior edge of the ethmoid, entering the maxillary sinus, 4) Comminuted fractures [5].

Fig. 2. Classification of the fractures on computed tomography

(A) Linear fracture, (B) Trap-door fracture, and (C) Hinged fracture.



Evaluation criteria and outcome measures

To identify the correlation between the time to surgery and that to recovery from postoperative diplopia, we divided our patients into the following three groups: 1) The group A ($n = 4$), the patients with a time to surgery of < 2 days; 2) The group B ($n = 4$), the patients with a time to surgery of 3–7 days; 3) The group C ($n = 3$), the patients with a time to surgery of 8–60 days.

We compared such variables as sex, age, signs of soft tissue injury, preoperative nausea/vomiting, the degree of preoperative diplopia and the side of the fracture on CT scans between the three groups. Then, we analyzed their correlations with the time to surgery in each group.

We also analyzed the correlations of the time to recovery from postoperative diplopia with the time to surgery, demographic variables, signs of soft tissue injury, preoperative nausea/vomiting, degree of preoperative diplopia and the side of the fracture on CT scans.

Operative procedure

All the 11 patients underwent unilateral orbital floor fracture repair via a subciliary incision under general anesthesia. We performed a dissection to the inferior orbital margin on the preseptal plane and elevated the periosteum off the floor. Thus, we exposed the inferior orbital wall fracture, as confirmed on CT scans. We found that there were edematous and ecchymotic changes in the inferior rectus muscle, but it was viable with no visible necrosis. Then, we released the entrapped muscle and soft tissue while restoring the ocular mobility on forced duction test (FDT). The herniated orbital contents were pressed back into the orbital cavity. This was followed by the FDT to confirm a complete release of the entrapped tissue. Finally, we reconstructed the fracture sites using a 1.0-mm thickness Medpor sheet (Porex Surgical Products Group, Newnan, GA, USA).

Table 1. Summary of cases

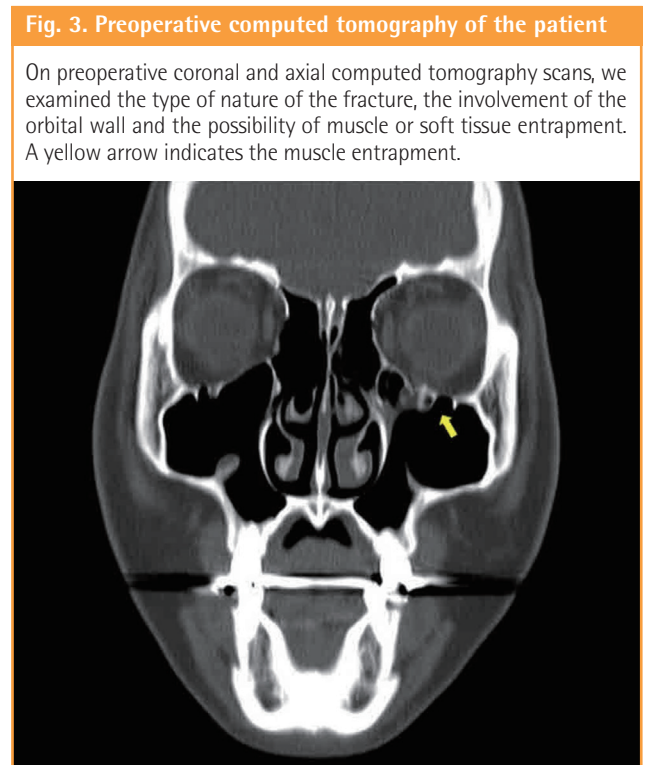
No.	Age (yr)	Sex	Signs of soft tissue injury	Preoperative nausea/vomiting	EOM limitation	Diplopia	Type of fracture	Time to surgery (day)
1	6	Male	None	Present	Present	Moderate	Trap-door	2
2	8	Male	Periorbital swelling	Absent	Present	Severe	Trap-door	2
3	11	Female	None	Present	Present	Severe	Trap-door	2
4	7	Male	Conjunctival injection	Present	Present	Severe	Hinged	2
5	7	Male	None	Absent	Present	Moderate	Trap-door	3
6	8	Female	None	Present	Present	Severe	Trap-door	4
7	12	Female	Periorbital swelling	Present	Present	Severe	Trap-door	7
8	8	Male	None	Present	Present	Moderate	Trap-door	7
9	5	Male	None	Absent	Present	Moderate	Linear	13
10	12	Male	None	Present	Present	Moderate	Trap-door	53
11	16	Male	Periorbital swelling	Present	Present	Moderate	Linear	60

EOM, extraocular muscles.

Table 2. Baseline characteristics of the patients

Variables	Patient groups		
	Group A (n = 4)	Group B (n = 4)	Group C (n = 3)
Sex			
Male	3 (75.0)	2 (50.0)	3 (100.0)
Female	1 (25.0)	2 (50.0)	0 (0.0)
Age			
Mean ± standard deviation (yr)	8.33 ± 2.52	9.00 ± 2.65	11.00 ± 5.57
Signs of soft tissue injury			
Absent	2 (50.0)	3 (75.0)	2 (66.7)
Periorbital swelling	2 (50.0)	1 (25.0)	1 (33.3)
Preoperative nausea/vomiting			
Present	3 (75.0)	3 (75.0)	2 (66.7)
Absent	1 (25.0)	1 (25.0)	1 (33.3)
Diplopia			
Moderate	1 (25.0)	2 (50.0)	3 (100.0)
Severe	3 (75.0)	2 (50.0)	0 (0.0)
Type of the fracture			
Trap-door	3 (75.0)	4 (100.0)	1 (33.3)
Linear	0 (0.0)	0 (0.0)	2 (66.7)
Hinged	1 (25.0)	0 (0.0)	0 (0.0)

Values are presented as number (%) or mean ± standard deviation.



RESULTS

Baseline and clinical characteristics of the patients are summarized in Tables 1, 2. Our clinical series of patients (n = 11) comprise eight boys and three girls, whose mean age at the onset of trauma was 9.09 ± 3.27 years (range, 5–16 years), all of whom were Asian.

Preoperatively, there were eight cases of nausea and vomiting, one case of conjunctival hemorrhage and three cases of mild periorbital swelling. On CT scans, there were eight, two and one cases of trap door-type, linear-type and hinged-type frac-

tures, respectively (Fig. 2). There were no cases of comminuted type of fracture. The mean time to surgery was 14.09 ± 21.29 days (range, 2–60 days) and the mean follow-up period was one year (range, 6 months–2 years).

All the patients were evaluated for the upward gaze at approximately 6 hours postoperatively, for which we measured the height of the lower margin of the pupil. In three patients, the height was higher by 1–2 mm on the affected side as compared with the non-affected side. In six patients, there was no difference in the height between the affected side and the non-affected side. In two patients, one of the group A and the other of the

Group B, the height was lower by 1–2 mm on the affected side as compared with the non-affected side. Both patients achieved improvement of diplopia during a follow-up period of 4–5 months, but did not achieve a complete recovery (Figs. 3-5).

The time to recovery from diplopia ranged between 1 and 8 months. That is, it was 1.5 months, 4 months, and 6 months in the group A, B, and C, respectively. Our results showed that the time to recovery was shorter in the patients with a shorter time to surgery.

DISCUSSION

In the current study, we analyzed the correlation between the timing of surgery and the time to recovery from diplopia. To do this, we evaluated the recovery rate. Our results showed that the rate of recovery from diplopia was higher in the group where surgical operations were performed immediately after the onset

of trauma. Even the patients undergoing surgical operations at delayed times would achieve a recovery from diplopia for longer periods of time. That is, it took less than 1.5 months for the patients undergoing surgery within 48 hours to achieve a recovery from diplopia. In the patients undergoing surgery after 48 hours of the onset of trauma, however, approximately five months elapsed until the recovery of postoperative diplopia. These results indicate that it would be desirable to perform surgical operations within 48 hours of the onset of trauma.

It is also noteworthy that we analyzed the postoperative ocular motility and diplopia, both of which are associated with a complete or lack of recovery from diplopia rather than the time to recovery from diplopia. Of the 11 patients, two had diplopia with a disease duration of 4–5 months although they received surgical operations, in a relatively timely manner, within seven days of the onset of trauma. These patients had a degree of ocular motility of 1–2 mm lower on the affected side as compared with the non-affected side at six hours postoperatively. These results indicate that a complete recovery from diplopia is associated with not only the optimal timing of surgery but also the postoperative ocular motility. In the current study, the diplopia had a direct correlation with the ocular motility. All the 11 patients with preoperative upward gaze restriction had a diplopia at forward or upward gaze. Of note, the diplopia had a direct correlation with the impaired ocular motility; it disappeared with the postoperative improvement of the ocular motility. Inconsistent with previous reports, the time to recovery from diplopia was shorter in the group with a shorter time to surgery. Several factors may be involved in the diplopia. In the current study, we confirmed that the diplopia occurred as a result of the entrapment of muscle and soft tissue on CT scans. Therefore, the impaired ocular motility disappeared with the immediate

Fig. 4. Preoperative photography of the patient

The patient presented with upward gaze restriction.

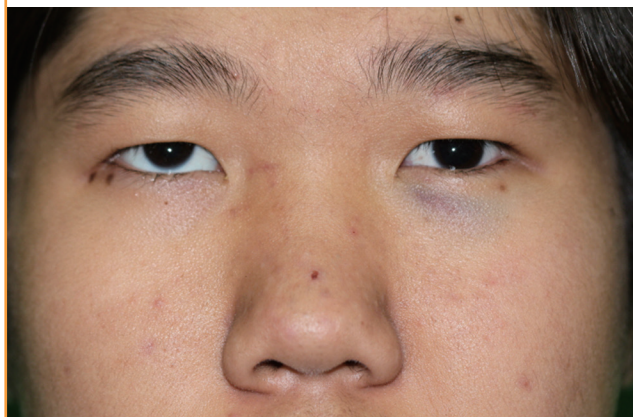
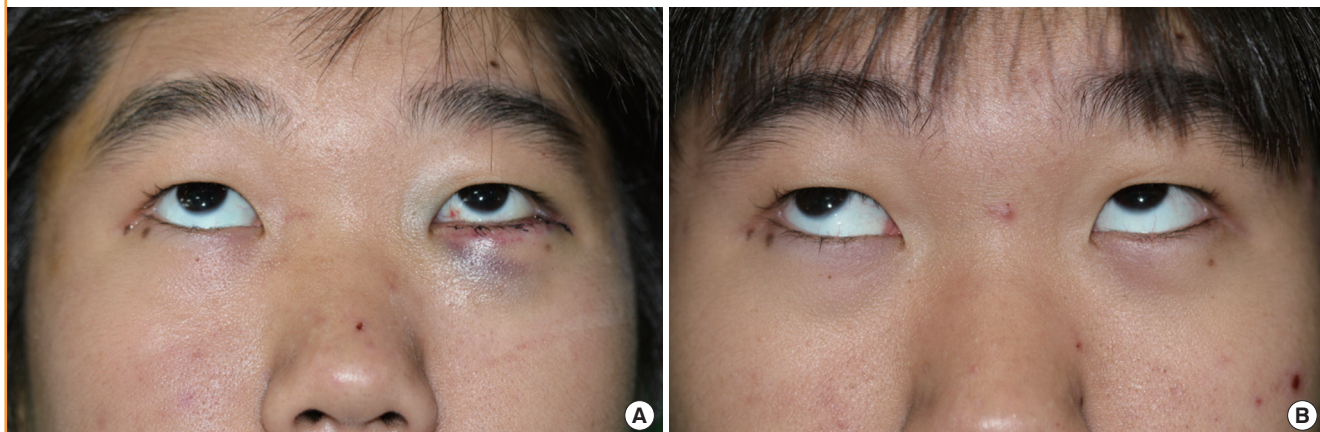


Fig. 5. Postoperative photography of the patient

(A) At 6 hours postoperatively, the patients could perform upward gaze but persistently had diplopia. (B) At 4 weeks postoperatively, the patient achieved a full motion without diplopia.



release of the entrapped muscle. Based on these results, it can be inferred that there is a close relationship between the ocular motility and diplopia in patients with white-eyed blowout fracture.

But there are some limitations of the current study as shown below: 1) We did not serve the control group, 2) We enrolled a small number of patients, and 3) We conducted the current study under the retrospective design.

It has been reported that successful postoperative outcomes are based on early surgical interventions in children with white-eyed blowout fracture. Grant et al. [6] conducted a retrospective study, showing that their clinical series of patients achieved a recovery of the ocular motility to a near-perfect degree after undergoing early surgical interventions, thus reporting that it would be mandatory to make an accurate diagnosis of white-eyed blowout fracture. Bansagi and Meyer [7] reported that pediatric cases of orbital fractures in which surgery was performed within 2 weeks of injury, recovered a greater degree of ocular motility. But Egbert et al. [8] showed no significant difference in the degree of the recovery from ocular motility between patients undergoing surgery after one month of the onset of trauma and those doing within seven days. These authors noted, however, that there was a significant difference in the time to recovery from ocular motility between the two groups (4 days in the group with a time to surgery of < 7 days vs. 10.5 days in the group with a time to surgery of > 7 days).

As mentioned above, successful postoperative outcomes are based on early surgical interventions in children with white-eyed blowout fracture. But it poses a diagnostic challenge for surgeons. It is termed due to a lack of clinical signs of soft tissue injury. This often leads surgeons to make a diagnosis of it as a benign condition.

Neinstein et al. [9] explained that children are vulnerable to white-eyed blowout fractures because of their facial bones, which are anatomically different from those of adults. In contrast to adults, children commonly exhibit a greenstick fracture when sustaining an external trauma. This is because the facial bones of children are still developing. Additionally, children have a higher cranial-to-facial ratio, a smaller cortical thickness and a higher elasticity as compared with adults. When external trauma unhinges the orbital rim, children's facial bones return to the normal position because of high elasticity. This transient buckling of the orbital floor results in a linear fracture of the thinner, more brittle, orbital floor along the obliquely situated canal of the infraorbital nerve. The anteromedial floor then passes inferiorly to the posterolateral floor. This overlap creates a "trapdoor" [10].

A CT is a key diagnostic modality for white-eyed blowout fracture because it allows surgeons to identify trap-door frac-

tures whose characteristics are different from those of extensive orbital floor fractures for which surgeons can make a diagnosis relatively easier. Moreover, surgeons can make an accurate diagnosis of white-eyed blowout fracture in patients presenting with impaired ocular motility and diplopia. Thus, they should decide on early surgery.

Children with white-eyed blowout fracture commonly present with diplopia and pain, for which surgical interventions should be performed. Pediatric trapdoor fractures are rarely, if ever, associated with peripheral rim fractures. Pain upon gazing upward and associated diplopia are often accompanied by headache and occasionally a marked vagal response (nausea, vomiting and bradycardia). Nausea and vomiting are generally considered indirect signs that a strong force is pushing against muscles or tissues; such pressure can create fractures and bone fragments. Bansagi and Meyer [7] reported that all 7 pediatric patients with trapdoor-type fractures presented with nausea and vomiting.

White-eyed blowout fractures are different from extensive orbital fractures in pediatric patients in that the orbital fractures are not difficult to diagnose because of wide fracture areas and accompanying symptoms such as edema around the eyelid, subconjunctival hemorrhage, and subcutaneous hemorrhage. In addition, this condition does not require early surgery.

Another factor that complicates the diagnosis of white-eyed blowout fractures in pediatric patients is the difficulty of obtaining an accurate case history. Ocular motility is often difficult to assess accurately, especially when the injury involves orbital edema. In most cases, pediatric patients are traumatized by the injury, fearful of being examined at the hospital, and too young to understand why they are experiencing a change in vision or diplopia.

In the current study, we focused on the time to surgery as well as the ocular motility in the immediate postoperative phase for the purposes of examining whether they have a predictive value for recovery from impaired ocular motility and diplopia. Moreover, we also evaluated the ocular motility at 6 hours postoperatively considering that it was another critical factor for achieving a full recovery from diplopia. Thus, we found that the degree of recovery from impaired ocular motility and diplopia was the highest in the patients undergoing surgical operations within 48 hours of the onset of trauma with the reconstruction of the fracture sites using implant materials. Our results also indicate not only that the insufficient ocular motility in the immediate postoperative phase is an indicative of insufficient restoration of the entrapped soft tissue and muscle but also that it would be difficult to achieve a full recovery from diplopia even after long periods of time. But further large-scale studies are warranted to establish our results.

Finally, we propose that surgeons should consider the possibil-

ity of white-eyed blowout fracture in children presenting with impaired ocular motility and diplopia. Moreover, it would also be mandatory to make a prompt diagnosis of it and perform surgical interventions, which is essential for improving clinical outcomes in this series [10].

REFERENCES

1. Jordan DR, Allen LH, White J, et al. Intervention within days for some orbital floor fractures: the white-eyed blowout. *Ophthalm Plast Reconstr Surg* 1998;14:379-90.
2. Tse R, Allen L, Matic D. The white-eyed medial blowout fracture. *Plast Reconstr Surg* 2007;119:277-86.
3. Park JH, Kim DH. Prognosis and clinical features of orbital wall fracture in preschool children. *J Korean Ophthalmol Soc* 2011;52:1490-5.
4. Chi MJ, Ku M, Shin KH, et al. An analysis of 733 surgically treated blowout fractures. *Ophthalmologica* 2010;224:167-75.
5. McCord CD, Tanenbaum M, Nunery WR. *Oculoplastic surgery*. New York: Raven Press; 1995.
6. Grant JH 3rd, Patrinely JR, Weiss AH, et al. Trapdoor fracture of the orbit in a pediatric population. *Plast Reconstr Surg* 2002;109:482-9.
7. Bansagi ZC, Meyer DR. Internal orbital fractures in the pediatric age group: characterization and management. *Ophthalmology* 2000;107:829-36.
8. Egbert JE, May K, Kersten RC, et al. Pediatric orbital floor fracture: direct extraocular muscle involvement. *Ophthalmology* 2000;107:1875-9.
9. Neinstein RM, Phillips JH, Forrest CR. Pediatric orbital floor trapdoor fractures: outcomes and CT-based morphologic assessment of the inferior rectus muscle. *J Plast Reconstr Aesthet Surg* 2012;65:869-74.
10. Fujino T, Makino K. Entrapment mechanism and ocular injury in orbital blowout fracture. *Plast Reconstr Surg* 1980;65:571-6.