



Case report

Amyloidosis of the Femoral Neck: An Unusual Cause of Pathologic Fracture

Christopher A. Worgul, MD^{*}, David M. Freccero, MD

Department of Orthopaedic Surgery, Boston Medical Center, Boston, MA, USA

ARTICLE INFO

Article history:

Received 1 February 2022

Received in revised form

8 March 2022

Accepted 10 March 2022

Keywords:

Amyloidosis

Femoral neck fracture

Lytic bone lesion

Pathologic fracture

Hemiarthroplasty

Hemodialysis

ABSTRACT

The deposition of amyloid within human tissue can be detrimental to the proper functioning of multiple organ systems. While the infiltration of the amyloid protein within the musculoskeletal soft tissues can lead to compressive neuropathies, tendon irritation or rupture, and joint stiffness, pathologic fracture as a result of amyloid deposition in bone is a rare manifestation of amyloidosis. We present a case of pathologic fracture of the femoral neck from amyloid deposition in a 59-year-old male on chronic hemodialysis who was found to have lytic lesions in his proximal femur. At the time of hemiarthroplasty, histopathologic analysis of a femoral head sample revealed apple-green birefringence of the deposits under polarized light, consistent with amyloid deposition. Clinicians should have a high index of suspicion for the atypical presentation of amyloidosis in a patient on chronic hemodialysis with lytic bone lesions.

Published by Elsevier Inc. on behalf of The American Association of Hip and Knee Surgeons. This is an open access article under the CC BY-NC-ND license (<http://creativecommons.org/licenses/by-nc-nd/4.0/>).

Introduction

Amyloidosis is a complicated multiorgan system disease characterized by the deposition and accumulation of amyloid, a misfolded protein in human tissue [1]. While the cardiac system is commonly affected, resulting in a restrictive cardiomyopathy and subsequent heart failure, orthopedic manifestations of amyloidosis are numerous and can affect the axial and appendicular musculoskeletal systems [1]. Deposition of the amyloid protein within the musculoskeletal system can result in a variety of clinical symptoms, such as bilateral carpal tunnel syndrome, chronic synovitis of large joints, and destructive arthropathy of the spine [2]. Amyloidosis has been reported as a frequent complication in patients who are on chronic hemodialysis, and there appears to be an incompletely understood association between hemodialysis and the accumulation of the amyloid protein [3]. Infrequently, large intraosseous accumulations of amyloid can deposit within the bone itself, creating a lytic lesion that can result in a pathologic fracture [3]. We present a case of pathologic fracture of the femoral neck as a result of amyloid deposition within the femoral head and neck.

Case history

The patient is a 59-year-old male who presented with 4 weeks of worsening left hip pain and inability to ambulate. He has a past medical history of end-stage renal disease secondary to diabetes mellitus and hypertension and was on hemodialysis 3 times per week for the past 6 years. He had also been followed by a rheumatology team for a history of monoclonal gammopathy of unknown significance and synovial hypertrophy in his bilateral shoulder, wrist, and knee joints. A prior knee synovial biopsy, with Congo red stain, was negative for amyloid in the past. The overall impression at that time was that his polyarticular arthritis was likely due to rheumatoid arthritis, and he was started on prednisone and etanercept.

Physical examination of the left hip revealed tenderness over the anterior groin and posterior buttock. Left hip range of motion was limited due to pain from approximately 30°–80° of flexion. Gentle internal and external rotation resulted in pain for the patient. The left foot was neurovascularly intact distally. Serology revealed a white blood cell count of 6.5 K/ μ L (4.0–11.0 K/ μ L), erythrocyte sedimentation rate of 108 mm/h (0–20 mm/h), and C-reactive protein of 93.4 mg/L (0–5.0 mg/L). Radiographs of the left hip revealed significant osteolytic lesions in the femoral head and neck area, concerning for an impending femoral neck fracture (Fig. 1). Computed tomography of the left hip again demonstrated osteolytic lesions in the femoral head and neck concerning for diffuse disease (Fig. 2).

^{*} Corresponding author. 1 Boston Medical Center Place, Boston, MA 02118. Tel.: +1 860 917 4468.

E-mail address: christopher.worgul@bmc.org

The patient underwent a fluoroscopy-guided aspiration of the left hip synovial fluid and an ultrasound-guided biopsy, which revealed minimal effusion but greatly thickened synovium of the left hip (Fig. 3). Microbiologic analysis of the synovial fluid revealed a total nucleated cell count of $12/\mu\text{L}$, no organisms, and no crystals. Cultures revealed no growth after 30 days. Pathologic analysis of the left hip synovium demonstrated dense fibroconnective tissue without inflammation. When a Congo red stain was performed on the specimen, Congo red-positive amyloid deposits were present, consistent with light-chain (AL)-type interstitial amyloid deposition. Given the diffuse disease present within the proximal femur and the absence of any lesions distally, the patient was indicated for a left hip hemiarthroplasty with a cemented femoral stem for prophylactic stabilization of the impending femoral neck fracture.

The patient underwent an uncomplicated left hip hemiarthroplasty via a direct anterior approach with a cemented femoral stem (DePuy Synthes/Johnson & Johnson, Warsaw, IN) and a metal bipolar head construct (Fig. 4). No obvious femoral neck fracture was noted intraoperatively. The femoral head was sent for histopathologic review, which revealed acellular pink amorphous material indicative of amyloid deposition. When the sample was stained with Congo red, the deposits displayed apple-green birefringence under polarized light (Fig. 5). Immunohistochemical staining of the bone marrow was positive for CD138+ plasma cells. The patient had an uneventful postoperative course and was able to bear full weight and ambulate without assistive devices by his 2-week postoperative appointment. Final radiographs at 16 months postoperatively revealed the components to be in stable position with an intact cement mantle and no evidence of osteolysis (Fig. 6).

The patient was made aware of our intentions to publish this case report detailing his condition and gave his verbal and written consent to proceed.

Discussion

AL amyloidosis involves the deposition of misfolded monoclonal immunoglobulin kappa or lambda light chains within human tissue and affects approximately 50 per 1 million people per year [1]. While several organ systems may be involved, including the cardiac, neurologic, renal, pulmonary, hepatic, and hematologic systems, the musculoskeletal system is also affected by amyloid deposition in the bones and soft tissues [4]. Biopsied tissues at the time of orthopedic intervention should be sent for permanent histologic analysis with hematoxylin and eosin staining, and Congo red staining should be performed as a screening test for amyloid fibrils [5]. Tissues positive for apple-green birefringence on polarized light microscopy after Congo red staining should undergo further immunohistochemistry for typing, and patients with AL kappa or lambda amyloid deposition should be referred to a hematologist for evaluation for plasma cell dyscrasia [1].

Amyloid deposition within bone can lead to lytic or cystic areas near large joints, and pathologic fractures of long bones as a complication of amyloid bone lesions can cause significant morbidity [5]. Lytic lesions causing cortical bone disruption can decrease torsional stress tolerance of bone by 60%, and lytic lesions affecting the endosteum significantly weaken long bones when greater than 50% of the bone diameter is involved [5]. Verhoeven et al. reported a case of a pathologic femoral neck fracture in an 87-year-old male who had elevated kappa AL monoclonal plasmacytes and positive Bence Jones proteinuria [6]. At the time of arthroplasty, histologic analysis of his femoral head revealed multifocal amyloid deposits, with osteolysis and a pseudotumoral aspect (amyloidoma) [6]. He also sustained a contralateral pathologic femoral neck fracture 6 months later secondary to amyloidosis.

Amyloidosis has been reported as a frequent complication in patients who are on chronic hemodialysis, and there appears to be

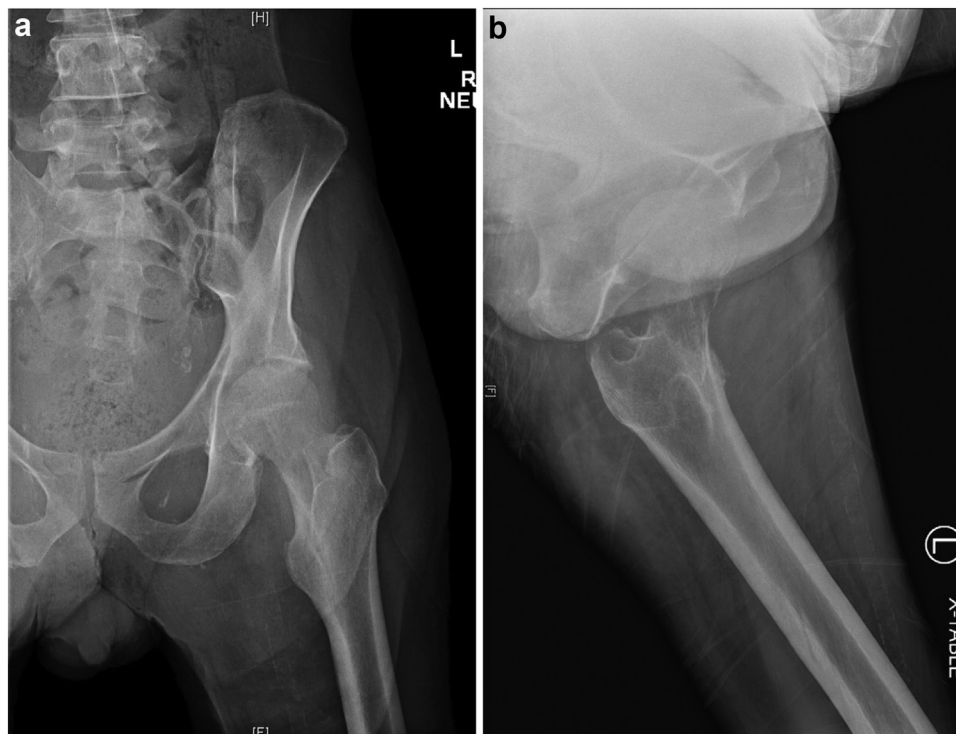

Figure 1. Preoperative radiographs. Anteroposterior (a) and lateral (b) radiographs of the left hip demonstrating significant lucencies of the femoral head and neck.

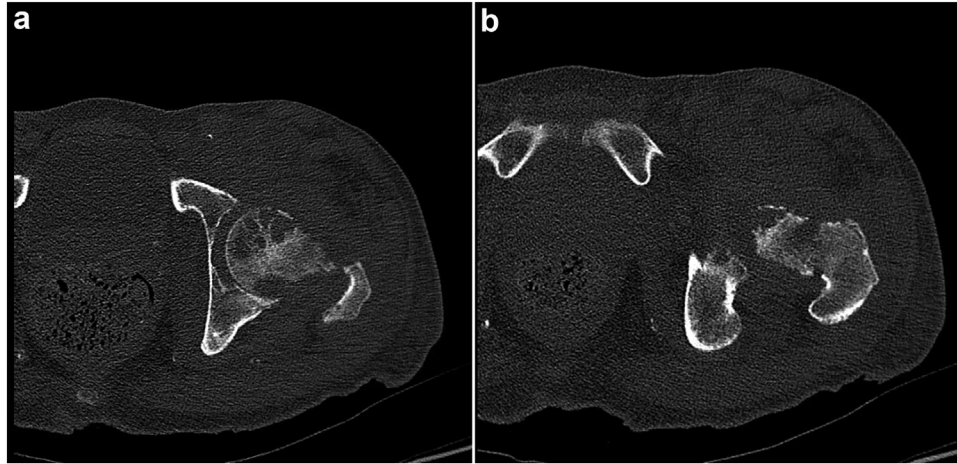


Figure 2. Preoperative CT scan. Axial cuts of the left femoral head (a) and neck (b) demonstrating extensive periarticular erosions and lytic lesions of the proximal femur, concerning for impending fracture.

an association between the extent of disease and the number of years of dialysis [3]. Beta-2-microglobulin, a small plasma protein metabolized only by the kidney and having an amino acid sequence similar to the constant region of the heavy chain of immunoglobulin G, has been recognized as the fundamental component of dialysis-associated amyloidosis [3]. Although the exact pathogenesis is not completely clear, it is believed that the chronic exposure to multiple antigens during the course of dialysis treatments (formaldehyde, dialysis membranes, silicone, blood products) may induce an inflammatory response that can increase beta-2-microglobulin concentrations and can result in amyloid deposition in bone [5]. These amyloid deposits are seen radiographically as lytic lesions, which weakens the bone matrix and can result in pathologic fractures.

Pathologic fractures of the femoral neck as a result of amyloid deposition have been described previously in the literature, with many of these patients on chronic hemodialysis. Naito et al. reported on 5 patients with impending fractures of the femoral neck due to amyloid bone lesions who underwent curettage and bone grafting [2]. Indications for the procedure included a lesion 2.5 cm or larger in size, greater than 50% of the cortex involved, or pain with weight-bearing [2]. All patients were found to have a mass of fibrous tissue filling the bone lesion in the femoral neck, and the articular cartilage appeared intact [2]. After curettage, the bone defect was filled with autogenous graft taken from the iliac crest

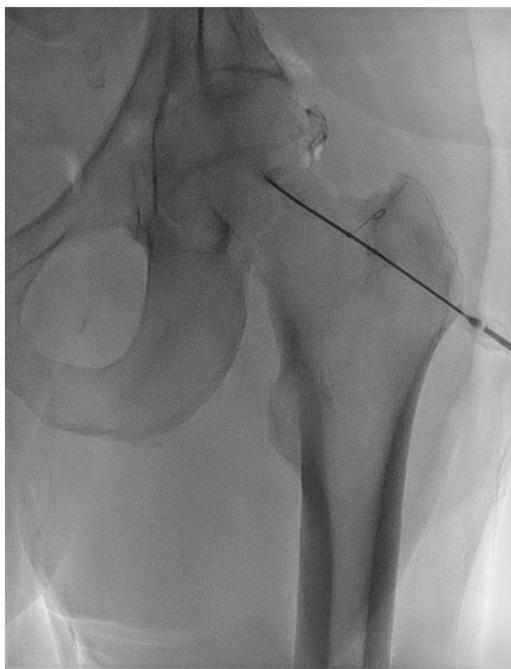

Figure 3. Aspiration of the left hip. Fluoroscopy-guided aspiration of the left hip. Contrast and saline measuring 1 cc were injected intraarticularly to confirm positioning.

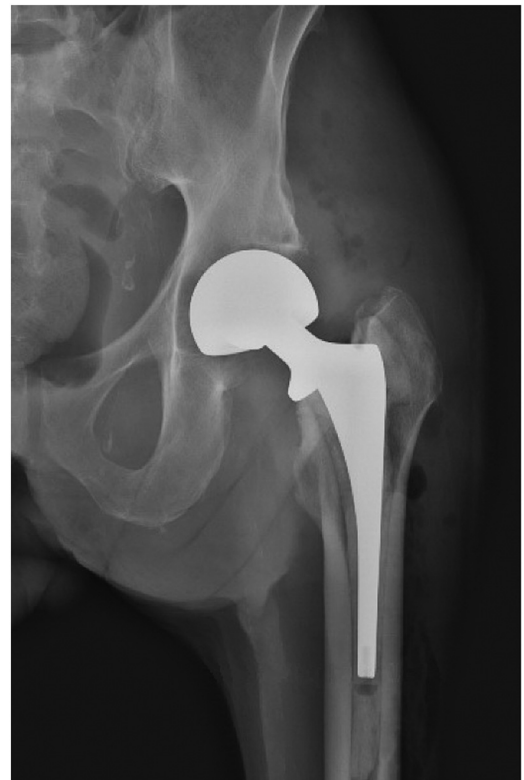

Figure 4. Postoperative radiograph of the left hip. Immediate postoperative anteroposterior radiograph of the left hip demonstrating a cemented bipolar prosthesis.

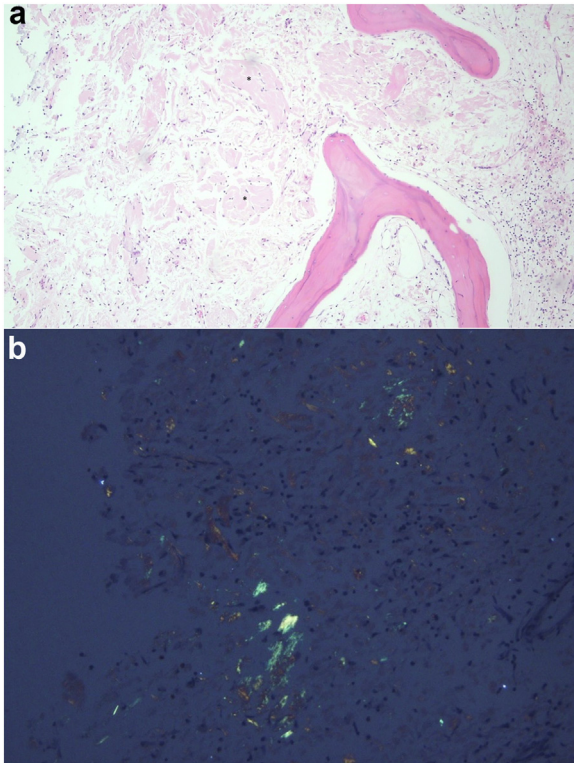


Figure 5. Histologic images of femoral head. Hematoxylin and eosin stain (a) demonstrating acellular pink amorphous material indicative of amyloid deposition. Congo red stain (b) showing apple-green birefringence of amyloid deposit under polarized light.

[2]. Biopsy specimens taken from the anterior capsule, synovium, and the curettings revealed fibrous tissue containing amyloid deposits in all patients [2]. Of note, all patients were maintained on chronic hemodialysis, with a mean duration of 15 years prior to curettage and bone grafting.

Campistol et al. described 5 cases of patients who sustained pathologic femoral neck fractures that occurred in areas of massive amyloid deposits [3]. All patients within this series were also on chronic hemodialysis, with a mean duration of 12 years prior to sustaining the fracture. In terms of treatment, 2 of the patients underwent hemiarthroplasty, 2 patients received a dynamic hip-screw and plate, and 1 patient underwent total hip arthroplasty. In all 5 patients, large amounts of amyloid were deposited in the capsule as masses of amorphous material that caused a significant enlargement of the capsule, and the amyloid deposits continued along the surface layers of the cartilage [3]. In select patients, amyloid deposits were found within the medullary space, eroding the trabeculae and producing osteolytic defects [3]. Immunohistochemical analysis was positive for beta-2-microglobulin in all specimens in this case series [3].

While amyloid bone lesions are commonly found in patients who have myeloma, isolated amyloid bone lesions are a rare manifestation in the absence of disseminated amyloidosis or other plasma cell dyscrasias. DiRaimondo et al. reported on 2 patients who were found to have pathologic femoral neck fractures through lytic lesions of the proximal femur [5]. Both patients were on chronic hemodialysis (12 years and 9 years) and presented with several weeks of worsening hip pain. During their preoperative evaluation, neither patient had evidence of disseminated amyloidosis on physical examination, skin biopsy, or bone marrow biopsy. Furthermore, serum protein electrophoresis and serum protein immunoelectrophoresis revealed no monoclonal

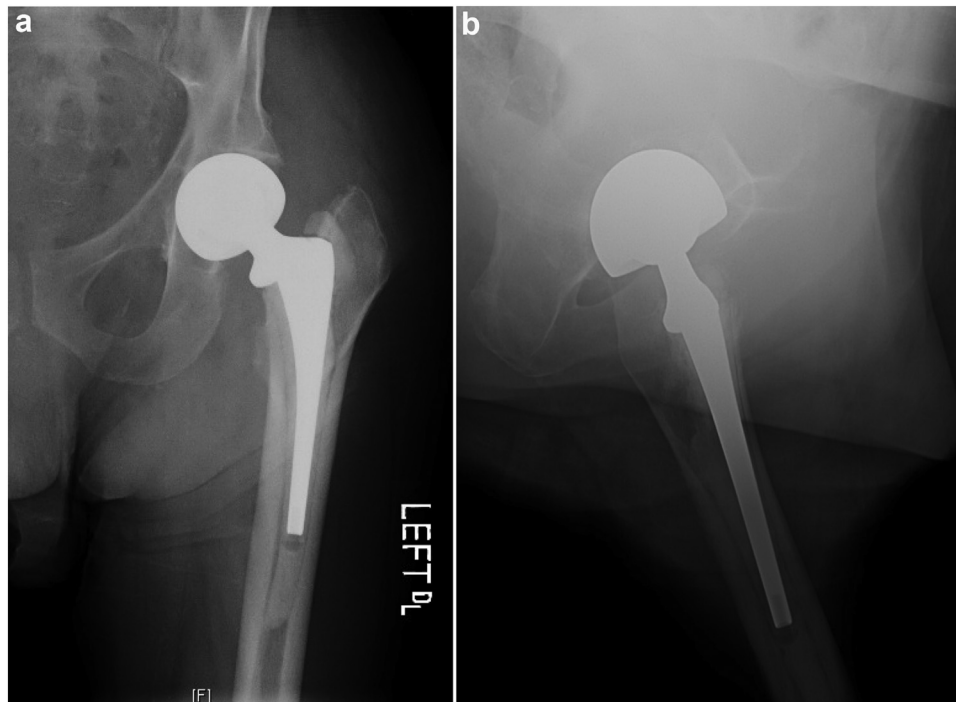


Figure 6. Radiographs at 16-month follow-up. Anteroposterior (a) and lateral (b) radiographs of the left hip at 16-month follow-up demonstrating stable components and no signs of osteolysis.

immunoglobulin or light chains in either patient. During histologic analysis, both patients were found to have replacement of large areas of normal bone with amorphous eosinophilic material, and after staining with Congo red, the deposits had the characteristic apple-green birefringence when examined under polarized light [5]. The authors suggested that amyloid should be included in the differential diagnosis of lytic bone lesions or pathologic fractures in chronic dialysis patients [5].

Our patient was on maintenance hemodialysis for 6 years prior to his pathologic femoral neck fracture, which is consistent with the other reports of pathologic fractures in chronic hemodialysis patients previously discussed. Additionally, he was being followed by a rheumatology team for monoclonal gammopathy of unknown significance, a monoclonal plasma cell disorder that likely placed him at increased risk for AL amyloidosis. While curettage/bone grafting and internal fixation with a dynamic hip-screw and plate construct were described earlier with satisfactory results, we believed that this patient would most benefit from a hemiarthroplasty given the extensive nature of the amyloidosis affecting his femoral head and neck. Although prosthetic loosening and infection is always a concern with poor bone quality in patients on chronic hemodialysis, our patient had reasonable bone quality and was found to be doing well at his final clinic follow-up appointment at 16 months postoperatively, with no evidence of component subsidence or osteolysis on radiographs.

The decision to perform a hemiarthroplasty on this patient rather than a total hip arthroplasty was also based on the patient's low activity level and medical comorbidities. He resided in a skilled nursing facility and reported he only ambulated short distances. Although he was 59 years old, he had multiple medical comorbidities including end-stage renal disease, diabetes, hypertension, and heart failure. Given the increased surgical and anesthesia time that a total hip arthroplasty would entail, combined with his multiple comorbidities and low functional level, the authors felt that hemiarthroplasty would provide him with a stable construct with the lowest risk of an intraoperative or postoperative complication. The authors also considered the increased risk of a prosthetic joint dislocation that is known to be associated with total hip arthroplasty, as a meta-analysis in 2012 suggested there is a 2.5-times greater risk of dislocation with total hip arthroplasty than with hemiarthroplasty [7]. The literature has shown cemented bipolar hemiarthroplasty to be an effective alternative to total hip arthroplasty, as a study published by van den Bekerom et al. in 2010 [8] and a 12-year follow-up study published in 2017 [9] compared total hip arthroplasty with cemented bipolar hemiarthroplasty. They found that duration of surgery was longer and blood loss was higher in the total hip arthroplasty group, and at the subsequent follow-up, there were no differences in hip function, identified using the Harris hip score [8]. The dislocation rate was 7% in the total hip arthroplasty group and 0% in the hemiarthroplasty group [8]. At the 12-year follow-up, there was no difference in hip function as measured by the Harris hip score, and there were no differences in complication, revision surgery, or mortality rates between the 2 groups [9]. Overall, given our patient's poor baseline mobility and activity level, poor physiological reserve, and medical comorbidities, the authors felt that hemiarthroplasty was a reasonable treatment for this patient who had low demand and was at high risk of a perioperative complication.

Summary

Pathologic fractures of the femoral neck as a result of amyloid deposition can be a source of considerable morbidity, and prophylactic fixation of large lesions may be crucial for fracture prevention. Although amyloidosis can affect several biologic systems, amyloid protein deposition within the musculoskeletal system can be the first manifestation, and orthopedic surgeons may find themselves at the forefront to prevent a pathologic fracture and coordinate further care in a patient with this complex disease.

Conflict of interest

D. M. Freccero has equity in ROMTech, receives research support from DePuy/Johnson & Johnson and Conformis, and is a member of the Patient and Public Relations Committee of the American Association of Hip and Knee Surgeons.

For full disclosure statements refer to <https://doi.org/10.1016/j.artd.2022.03.014>.

Informed patient consent

The author(s) confirm that informed consent has been obtained from the involved patient(s) or if appropriate from the parent, guardian, power of attorney of the involved patient(s); and, they have given approval for this information to be published in this case report (series).

Acknowledgment and funding sources

The authors would like to thank Charitha Vadlamudi, MD, and Hui Chen, MD, for their assistance with the preparation of the pathology slides.

References

- [1] Zhang D, Makni MC, Kang JD, Blazar P. Orthopaedic manifestations of amyloidosis. *J Am Acad Orthop Surg* 2021;29:488–96.
- [2] Naito M, Ogata K, Shiota E, Oyama M. Amyloid bone Cysts of the femoral neck. *J Bone Joint Surg* 1994;76:922–5.
- [3] Campistol JM, Sole M, Munoz-Gomez J, Riba J, Ramon R, Revert L. Pathological fracture in patients who have amyloidosis associated with dialysis. *J Bone Joint Surg* 1990;72:568–74.
- [4] Prokaeva T, Spencer B, Kaut M, et al. Soft tissue, joint, and bone manifestations of AL amyloidosis. *Arthritis Rheumatol* 2007;56:3858–68.
- [5] DiRaimondo CR, Casey TT, DiRaimondo CB, Stone WJ. Pathologic fractures associated with Idiopathic amyloidosis of bone in chronic hemodialysis patients. *Nephron* 1986;43:22–7.
- [6] Verhoeven F, Prati C, Wendling D. Amyloidoma, an Unusual cause of fracture. *Case Rep Rheumatol* 2014;4:24056.
- [7] Burgers PT, van Geene AR, van den Bekerom MP, et al. Total hip arthroplasty versus hemiarthroplasty for Displaced femoral neck fractures in the Healthy Elderly: a meta-analysis and Systematic review of Randomized Trials. *Int Orthop* 2012;36:1549–60.
- [8] van den Bekerom MP, Hilverdink EF, Sierevelt IN, et al. A Comparison of hemiarthroplasty with total hip replacement for Displaced Intracapsular fracture of the femoral neck: a Randomised Controlled Multicentre Trial in patients aged 70 Years and over. *J Bone Joint Surg Br* 2010;92:1422–8.
- [9] Tol M, van den Bekerom MP, Sierevelt IN, et al. Hemiarthroplasty or total hip arthroplasty for the treatment of a Displaced Intracapsular fracture in active Elderly patients: 12-year follow-up of Randomised Trial. *Bone Joint J* 2017;99-B: 250–4.