

# Uterine Artery Rupture After Induced Abortion and Extraction of an Intrauterine Device

Xiao-Ming Yu<sup>1</sup>, Jing Guan<sup>1</sup>, Ting-Ting Sun<sup>2</sup>

<sup>1</sup>Department of Reproduction Medicine, Peking University People's Hospital, Beijing 100044, China

<sup>2</sup>Department of Gynecology, Peking University Shougang Hospital, Beijing 100041, China

**Key words:** Induced Abortion; Intrauterine Device; Rupture; Uterine Arterial Embolization; Uterine Artery

An intrauterine device (IUD) is a safe, effective, simple, and reversible method for birth control, but some women with IUD may still become pregnant. Induced abortion is the main method for termination of pregnancy. If induced abortion is not well-managed in these patients, it may result in serious vaginal bleeding and uterine rupture. We report a case of uterine artery rupture after induced abortion combined with extraction of an IUD. This case highlights the necessity of a standard operation for complicated induced abortion, and the value of interventional therapy, such as uterine artery embolization (UAE), for controlling serious vaginal bleeding.

On August 13, 2015, a 37-year-old gravida 3, para 2 woman visited Emergency Department of Peking University People's Hospital due to sudden vaginal bleeding for 1 h. At admission, she appeared pale and her consciousness was clear, with a blood pressure of 88/50 mmHg (1 mmHg = 0.133 kPa) and heart rate of 140 beats/min. In the vaginal assessment, there were a lot of blood clots in the vagina. After removal of these clots, we observed that the cervix and vagina had no lacerations, and the uterus was soft with a normal size. However, blood poured out from her cervix. No other remarkable findings were observed in a physical examination. The volume of blood loss was estimated to be 1500 ml in 1 h. Immediate intravenous access and fluid resuscitation were started with an initial diagnosis of hemorrhagic shock. An emergency urine pregnancy test was negative, and the hemoglobin concentration was 85 g/L. Detailed ultrasonography showed a 0.9-cm heterogeneous echo band in the uterine cavity and a 1.3-cm hypoechoic mass in the left lower uterine cavity with fluid flow echo inside. There was no free fluid in the pelvic cavity. Considering the heavily acute vaginal bleeding from the uterus, and a history

of artificial abortion and extraction of IUD, we decided to perform emergent uterine artery embolism and treat shock simultaneously.

During the surgery, extravasation of contrast media from the left uterine artery indicated rupture of this artery and revealed the active bleeding site in the uterine cavity [Figure 1]. The right uterine artery was normal [Figure 2]. The left uterine artery was embolized with a microcoil and gelatin sponge particles (350–560  $\mu\text{m}$ ) [Figure 3]. The right uterine artery was embolized only with gelatin sponge particles. A final angiogram confirmed successful occlusion of the target artery. Postoperatively, the patient recovered well and was discharged with no vaginal bleeding 6 days later. Forty-two days later, her menses started and lasted for 5 days.

When we reviewed her previous history, we found that she underwent vaginal delivery twice in 2012 and 2014. She then received IUD insertion to prevent pregnancy 6 months after vaginal delivery in 2014. The patient's menstrual history was regular, and the last menstrual period was on July 6, 2015. However, unfortunately, ultrasonography showed intrauterine pregnancy combined with the IUD *in situ* on August 13, 2015. On the same day, she received artificial abortion and extraction of the IUD. Intraoperatively, the IUD was incarcerated and difficult to extract. After removing the complete IUD with sponge forceps, vaginal

**Address for correspondence:** Dr. Jing Guan,  
Department of Reproduction Medicine, Peking University People's  
Hospital, Beijing 100044, China  
E-Mail: guanjing6302@sina.vip.com

This is an open access article distributed under the terms of the Creative Commons Attribution-NonCommercial-ShareAlike 3.0 License, which allows others to remix, tweak, and build upon the work non-commercially, as long as the author is credited and the new creations are licensed under the identical terms.

**For reprints contact:** reprints@medknow.com

© 2016 Chinese Medical Journal | Produced by Wolters Kluwer - Medknow

**Received:** 23-11-2015 **Edited by:** Xin Chen  
**How to cite this article:** Yu XM, Guan J, Sun TT. Uterine Artery Rupture After Induced Abortion and Extraction of an Intrauterine Device. Chin Med J 2016;129:484-6.

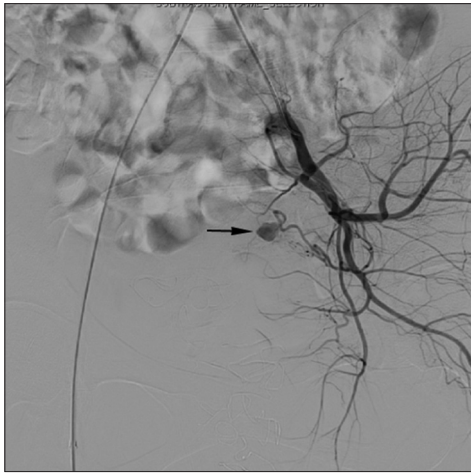
#### Access this article online

##### Quick Response Code:

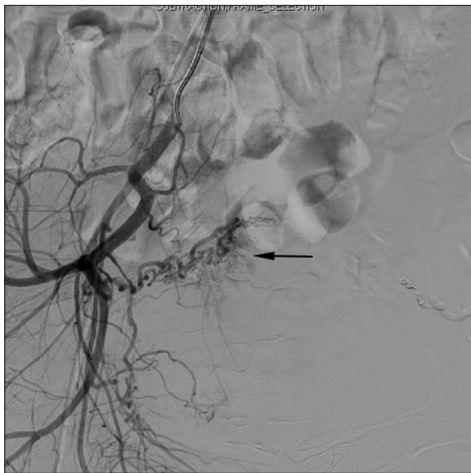


**Website:**  
www.cmj.org

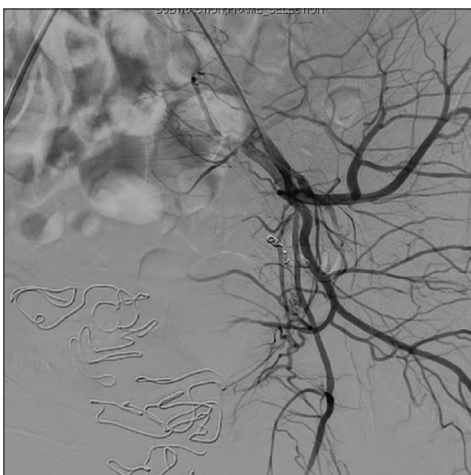
**DOI:**  
10.4103/0366-6999.176086



**Figure 1:** Left internal iliac arteriogram shows contrast medium extravasation (arrow) from a branch of the left uterine artery.



**Figure 2:** Right internal iliac arteriogram shows the right uterine artery (arrow) before embolization (no contrast medium extravasation).



**Figure 3:** Left internal iliac arteriogram shows postembolization of the left uterine artery using a microcoil and gelatin sponge particles (350–560 μm).

bleeding increased, and the complete gestational sac was subsequently aspirated. Intraoperative bleeding was 450 ml

and hemorrhage decreased after strengthening of uterine contractions. She experienced a sudden vaginal bleeding in 24 h after the surgery, and the amount of bleeding was estimated to be 1200 ml. Emergent treatment was initiated immediately, by using uterine packing oppression of water bag with 20 ml saline. The vaginal bleeding then decreased. On August 17, 2015, the water bag was extracted with little vaginal bleeding, and she was discharged.

Induced abortion combined with extraction of an IUD is complex. During pregnancy, the uterus is enlarged and the gestational sac may change the position of the IUD. Sometimes removing the IUD is difficult. When pregnant, the uterus is soft and easily damaged. Therefore, in abortion patients with an IUD, if the IUD is down to the cervix or has a tail, the IUD should be removed first. In patients with an IUD *in situ*, induced abortion should be performed first, and then the IUD should be removed when the uterus is contracted.

Error or a rough operation will lead to serious vaginal bleeding. Previous studies have suggested that uterine atony is the leading cause of postabortion bleeding (22/42, 52%), followed by placental abnormality (7/42, 17%), and cervical laceration (5/42, 12%).<sup>[1,2]</sup> Uterine vascular rupture is relatively rare, but can cause acute massive hemorrhage once it has occurred.<sup>[3-5]</sup> Ultrasound examination is usually performed as the primary diagnostic tool to assess patients. Conventional treatment of such cases involving uterine vessel rupture is a surgical operation.

We have often performed a laparotomy to have a hysterectomy or ligation of the uterine or iliac arteries. UAE is another rapid and effective way of controlling uterine bleeding, especially in patients who desire to become pregnant. UAE is an interventional therapy and can achieve rapid control of hemorrhage. UAE is widely used in the treatment of acute serious vaginal bleeding, such as postpartum hemorrhage, uterine fibroids, adenomyosis, uterine scar pregnancy, and placenta previa, and it significantly reduces the rate of hysterectomy. The success rate of UAE in selective operations is almost 100%, and 88% in emergency operations. The use of arterial embolization to control hemorrhage has a reported success rate of 90–95% in treating postpartum bleeding or bleeding after dilatation and curettage.<sup>[6-9]</sup> UAE is also safe and effective for treatment of massive hemorrhage in cesarean scar pregnancy.<sup>[10]</sup> Additionally, UAE enables visualization of the hemorrhage site of uterine arteries.

However, some complications have been described after UAE. There are some case reports of death as a result of complications after UAE, but this is a rare outcome. Major complication rates of UAE have been reported, ranging from 1% to 17%.<sup>[11]</sup> Common complications include fever, nausea, vomiting, and local pain. These complications usually occur 24 h after UAE, and can be relieved after symptomatic treatment. UAE may lead to endometrial lesions, intrauterine adhesion, premature ovarian failure, and amenorrhea. In our patient, her menses started 42 days after UAE. Besides the above-mentioned complications, UAE may also cause intimal injury to vessels, acute thrombosis, vessel rupture, infection,

adjacent organ damage, and contrast medium allergies. In rare cases, UAE may even lead to bradycardia, acute myocardial infarction, and shock. Failure of UAE may lead to separate step operative or conversion to other treatment methods.

Awareness of this rare complication during induced abortion in pregnant patients with an IUD *in situ* may be useful for its diagnosis and treatment. Emergent radiological intervention could provide an effective option for diagnosis and treatment in cases with massive vaginal bleeding after a uterine cavity operation. UAE has distinct advantages, such as being a less invasive procedure, it is more easily operated, and it has a lower incidence of operation-related complications compared with the traditional operation. Additionally, in UAE, there is no need for general anesthesia in potentially unstable patients, identifying the bleeding site is easy, there is a tendency for a low incidence of re-bleeding, and there is a high success rate. UAE can preserve uterine function and improve the quality of life, and is also an option for patients who cannot tolerate or are not suitable for laparotomy.

### Acknowledgments

The authors thank for the collaboration and support of Department of Reproduction Medicine of Peking University People's Hospital.

### Financial support and sponsorship

Nil.

### Conflicts of interest

There are no conflicts of interest.

### REFERENCES

1. Steinauer JE, Diedrich JT, Wilson MW, Darney PD, Vargas JE,

- Drey EA. Uterine artery embolization in postabortion hemorrhage. *Obstet Gynecol* 2008;111:881-9. doi: 10.1097/AOG.0b013e3181685780.
2. Song Y, Shin JH, Yoon HK, Kim JW, Ko GY, Won HS. Bleeding after dilatation and curettage: The efficacy of transcatheter uterine artery embolisation. *Clin Radiol* 2015;70:1388-92. doi: 10.1016/j.crad.2015.07.011.
3. Kim T, Shin JH, Kim J, Yoon HK, Ko GY, Gwon DI, *et al.* Management of bleeding uterine arteriovenous malformation with bilateral uterine artery embolization. *Yonsei Med J* 2014;55:367-73. doi: 10.3349/ymj.2014.55.2.367.
4. Moon G, Jeon S, Nam KH, Choi S, Sunwoo J, Ryu A. Pseudoaneurysm of uterine artery causing intra-abdominal and vaginal bleeding after cervical conization. *Obstet Gynecol Sci* 2015;58:256-9. doi: 10.5468/ogs.2015.58.3.256.
5. Black JD, Yuhasz M, Lee AY. Uterine artery rupture during the second stage of labor. *Int J Gynaecol Obstet* 2014;124:176. doi: 10.1016/j.ijgo.2013.08.007.
6. Pelage JP, Soyer P, Repiquet D, Herbreteau D, Le Dref O, Houdart E, *et al.* Secondary postpartum hemorrhage: Treatment with selective arterial embolization. *Radiology* 1999;212:385-9. doi: 10.1148/radiology.212.2.r99j105385.
7. Shin SM, Yi KW, Chung HH. Postpartum uterine bleeding from the inferior mesenteric artery: Case report and review of the literature. *Gynecol Obstet Invest* 2015;80:60-3. doi: 10.1159/000367598.
8. Li X, Wang Z, Chen J, Shi H, Zhang X, Pan J, *et al.* Uterine artery embolization for the management of secondary postpartum haemorrhage associated with placenta accreta. *Clin Radiol* 2012;67:e71-6. doi: 10.1016/j.crad.2012.07.021.
9. Pelage JP, Fohlen A, Le Pennec V. Role of arterial embolization in the management of postpartum hemorrhage. *J Gynecol Obstet Biol Reprod (Paris)* 2014;43:1063-82. doi: 10.1016/j.jgyn.2014.10.002.
10. Cao S, Zhu L, Jin L, Gao J, Chen C. Uterine artery embolization in cesarean scar pregnancy: Safe and effective intervention. *Chin Med J* 2014;127:2322-6. doi: 10.3760/cma.j.issn.0366-6999.20140196.
11. Toor SS, Jaber A, Macdonald DB, McInnes MD, Schweitzer ME, Rasuli P. Complication rates and effectiveness of uterine artery embolization in the treatment of symptomatic leiomyomas: A systematic review and meta-analysis. *AJR Am J Roentgenol* 2012;199:1153-63. doi: 10.2214/AJR.11.8362.