



## Case report

# Restoration of vaginal anatomy after extensive posterior wall resection utilizing human acellular dermal matrix



Amit K. Bhavsar<sup>a,\*</sup>, Kevin M. Lin-Hurtubise<sup>b</sup>, Charles S. Dietrich<sup>c</sup>

<sup>a</sup> Department of Obstetrics and Gynecology, Tripler Army Medical Center, Honolulu, HI, United States

<sup>b</sup> Department of General Surgery, Tripler Army Medical Center, Honolulu, HI, United States

<sup>c</sup> Department of Gynecologic Oncology, Tripler Army Medical Center, Honolulu, HI, United States

## ARTICLE INFO

### Article history:

Received 18 December 2015

Received in revised form 8 January 2016

Accepted 24 January 2016

Available online 27 January 2016

### Keywords:

Graft

Collagen

Vaginal reconstruction

Anal cancer

Alloderm

Exenteration

## 1. Patient background

A 51 year old female presented with a chief complaint of hematochezia, dyschezia, tenesmus and stool incontinence. She also reported a six month history of constipation and pencil thin stools. A colonoscopy demonstrated a near-circumferential friable and bulky rectal mass 4–5 cm from the anal verge (Fig. 1). Biopsy of the mass revealed a moderately differentiated adenocarcinoma presumed to be of rectal origin. Computed tomography was significant for regional lymphadenopathy without evidence of vaginal involvement.

The patient's past medical history was significant for stage IB2 squamous cell carcinoma of the cervix diagnosed in her early thirties. She was treated with external beam radiation and vaginal brachytherapy, resulting in mild vaginal stenosis. In her early forties, she developed stage I breast cancer and was treated with lumpectomy with adjuvant breast radiation plus hormonal therapy. Her past medical, surgical, social and family histories were otherwise noncontributory to her current condition.

On physical examination she had a patulous anus with poor resting anal tone and an easily palpable rectal mass approximately 4 cm from the anus involving about 75% of the luminal circumference. Staging

preoperative CT of abdomen and pelvis showed thickened rectum with left perirectal adenopathy but no evidence of vaginal involvement or distant metastasis.

The patient was counseled on the operative plan of an abdominal-perineal resection (APR) and end colostomy due to the low position of the rectal mass and clinical anal sphincter involvement.

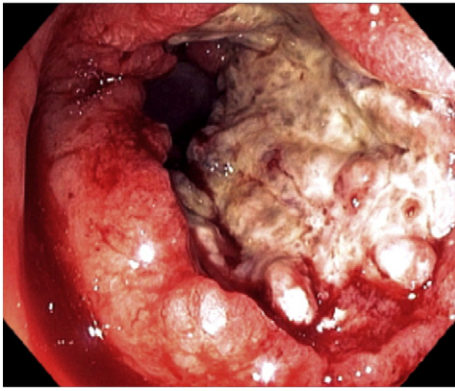
## 2. Operative course

APR was conducted via a vertical abdominal incision. Bilateral ureteral stents had been placed pre-operatively. Distortion of pelvic tissue planes was noted consistent with her history of pelvic radiation. Slow and meticulous dissection was carried out and resulted in removal of an en bloc specimen which included both internal and external anal sphincters, the rectum, sigmoid colon and a portion of the coccyx. End colostomy was constructed. The intraoperative frozen section of the cancer specimen revealed positive distal and anterior radial margins. The abdominal wound, fascia and skin were closed and the patient was repositioned in the prone jackknife position. Additional distal margin was resected through a wider perineal elliptical incision encircling the defect created by the previous APR which now incorporated a portion of the levator muscles. To achieve an adequate anterior radial margin, the distal portion of the rectovaginal septum, including the majority of the posterior vaginal wall was further resected.

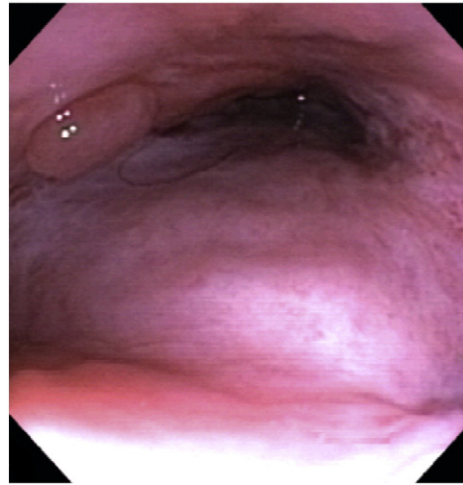Due to this extensive resection of vaginal tissue, a gaping defect had been created in the posterior vagina. The available tissue from the lateral aspects of the vagina was insufficient to cover the defect posteriorly and was compounded by her prior radiation. Options included performing a hysterectomy with complete vaginectomy versus flap reconstruction of the vagina. Due to the patient's strong desire to maintain sexual function, a hysterectomy with vaginectomy was not performed.

The operative team opted to perform a biologic graft repair of the posterior vagina. Specific consent for grafting could not be obtained by the team as vaginal reconstruction was not anticipated pre-operatively; however, she was consented for any and all such indicated procedures. A section of Alloderm®, an acellular collagen matrix was customized into a sheet 8 cm length and 4 cm in width. This was then used to bridge the gap between the left and right vaginal walls posteriorly and was sutured into place along the margins of the remaining vaginal mucosa using interrupted 3–0 Vicryl sutures (Figs. 2a, 2b). A Foley was placed in the uterus through the cervix in order to maintain

\* Corresponding author at: Department of Obstetrics and Gynecology, Tripler Army Medical Center, 1 Jarrett White Road, Honolulu, HI 96859, United States.  
E-mail address: [amit.k.bhavsar.mil@mail.mil](mailto:amit.k.bhavsar.mil@mail.mil) (A.K. Bhavsar).



**Fig. 1.** Rectal cancer detected on initial colonoscopy 4–5 cm from anal verge.



**Fig. 3.** Vaginoscopy 10 months after graft placement demonstrating normal appearing vaginal mucosa.

an outflow tract. A separate Jackson Pratt drain was then placed into the deep perineal space through the perineum. The perineal wound was closed primarily in layers using 0-Vicryl and 2–0 Vicryl sutures. Final pathology revealed a T4N0M0 grade 1 invasive rectal adenocarcinoma. The anterior radial margin of the perineal and vaginal tissue revealed a small residual focus of rectal carcinoma but no vaginal mucosal or submucosal invasion were present, thus clear surgical margins were achieved.

Three weeks postoperatively, the graft was viable with minimal vaginal drainage. Three months post operatively, the vagina remained patent and the graft was granulating well. Ten months after the surgery, vaginoscopy demonstrated a 7 cm vaginal vault without stricture or defects. The back wall of the biologically reconstructed vagina was well healed and the mucosa appeared physiologically normal (Fig. 3).

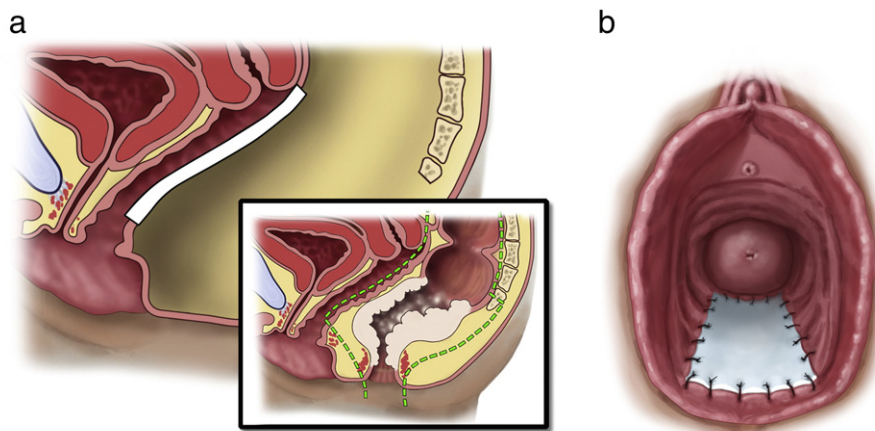
Patient was treated with 8 cycles of adjuvant capecitabine plus bevacizumab. She developed metastatic disease in her lungs and liver at 10 months and was started on irinotecan plus cetuximab and later switched to regorafenib. At three years follow-up, she appeared well-nourished and was functioning well. She reported some left perineal scar pain and denied recent sexual activities. On speculum exam, her vaginal vault was patent and nontender but narrowed; approximately 7 × 2 cm and her vaginal mucosa appeared atrophic.

**3. Discussion**

A comprehensive literature search was conducted on May 26, 2015. No other cases were found describing a vaginal wall reconstruction using an acellular collagen matrix graft following resection of a locally

advanced rectal mass. Alloderm® dermal allograft which was used in this case is constructed from human skin in which epidermis and cellular material are removed. Revascularization is facilitated along the collagen matrix of the graft (Supplementary figure).

Rectus abdominis myocutaneous (RAM) flap repair is the most common method of reconstruction in the setting of colorectal malignancy requiring vaginectomy (McArdle et al., 2012; D'Souza et al., 2003). Cases currently reported in the literature in which an allograft was used to create a neovagina are described for the correction of vaginal agenesis. One case series documents three patients in which such a repair took place as an alternative to a split thickness skin graft: a patient with vaginal agenesis, another with severe lichen sclerosis causing vaginal agglutination and a third patient with squamous cell carcinoma of the vagina (Stany et al., 2010). Another publication documented a case of vaginal agenesis in which acellular human dermal allograft was used to perform a modified McIndoe procedure. Although the immediate post-operative course was uncomplicated, she eventually suffered from stenosis of the vaginal apex attributed to inadequate vaginal dilator use in the post-operative period (Kuohung et al., 2007). The additional operative time of a flap reconstruction was considered but deemed to contribute significant morbidity to this case and therefore not pursued.



**Fig. 2.** a, and 2b: Sagittal illustration of vagina demonstrating position and location of allograft mesh, and en-block resection (inset). 2b: Depiction of vagina (lithotomy view) demonstrating position and location of allograft mesh. Illustration Courtesy Beth K. Lozanoff, CMI, John A. Burns School of Medicine, Honolulu, HI.

Acellular allograft reconstruction compares favorably to other less common alternatives used in the setting of vaginal agenesis. For example, autologous tissue for reconstruction purposes grown in culture from a vaginal biopsy has been described (Benedetti Panici et al., 2015). However, this technique requires substantial lead time and preparation in order to culture tissue, which may not be available or advisable in the setting of pelvic malignancy. The use of bowel segment has also been described for such reconstruction; however similar concerns would preclude this as an ideal technique for tissue reconstruction following oncologic surgery (Wright and Hanna, 2014).

Likelihood of complications must be extrapolated from current literature in which the use of an acellular matrix similar to the above has been described in the vaginal agenesis patient population with no severe post-operative complications among 53 patients. Granulomatous polyps at the introitus were seen in 11% of the study group which were able to be removed in the outpatient setting. Interestingly, sexual function was reported to be similar to healthy controls in the year after surgery (Zhu et al., 2013). More research is needed as these data may not be generalizable to the oncology population. Long term studies on allograft reconstruction are limited as well. One small study followed 33 women with vaginal wall prolapse corrected with AlloDerm® without documented significant complications. Most continued to be sexually active with only one subject reporting long term dyspareunia (greater than 45 months) since the procedure. No graft erosions or rejections were found other than one anterior wall breakdown that was related to hematoma formation from heparin therapy (Ward et al., 2007; Clemons et al., 2003).

Studies of acellular dermal matrix applied to irradiated tissues in mouse models demonstrate an initial short term period of decreased healing but overall graft thickness and fibroblast activity do not seem to be significantly affected (Dubin et al., 2000). Post graft radiation similarly does not seem to promote breakdown or infection, at least in animal models (Ibrahim et al., 2000). One small study of dermal matrix used in the setting of post breast cancer reconstruction demonstrated a small increase in wound infection but no breakdown was demonstrated for radiation administered to the area before or after graft placement (Nahabedian, 2009).

In our patient, the use of a tissue regenerating matrix allowed for the reconstruction of the posterior vaginal wall after a radical excision of locally advanced rectal cancer in which most of the posterior vaginal wall was resected en bloc with the cancer. Given our patient's strong desire to preserve sexual function following surgery, this technique spared the patient from a total vaginectomy. Favorable long term results have been reported utilizing a similar technique for non-oncologic surgery. Advantages to the use of a biologic graft include preservation of vaginal anatomy and sexual function, and the avoidance of increased morbidities associated with the extra operative time and procedures when autologous graft harvesting for flap reconstruction or other labor intensive techniques such as bowel segment reconstruction are performed. Ultimately, based on our case report allograft vaginal reconstruction following oncologic anorectal surgery has been shown to be feasible with preservation of vaginal anatomy and good functional outcomes, likely to decrease operative times and perioperative morbidity. More research is required, however to confirm these premises.

All authors report no financial support or conflicts of interest pertaining to this article.

A literature search was conducted on May 26, 2015 as follows:

PubMed, Embase, Google Scholar.

Mesh and Keywords: Biologic grafts AND cancer, Biologic grafts AND pelvic reconstructions, Biologic prostheses AND cancer, Biologic prostheses AND pelvic reconstructions, Biologic prostheses AND vaginal wall, Pelvic reconstructions allograft vagina, Allograft exenteration reconstruction, posterior vaginal wall AND synthetic mesh, pelvic reconstruction AND synthetic mesh, allograft mesh AND vaginal reconstructions, vaginal reconstruction AND allograft mesh, posterior vaginal wall AND allograft mesh, allograft mesh AND vagina reconstruct AND cancer, allograft mesh AND posterior vaginal wall, vaginal reconstruction AND posterior vaginectomy, vaginal reconstruction AND MRKH syndrome, acellular collagen biomesh AND vaginal reconstruction.

Mesh:

Pelvis[Mesh] AND "reconstructive surgical procedures [Mesh], Biology[Mesh] AND prostheses and implants [Mesh], Biology[Mesh] AND transplantation[Mesh], Allografts/transplantation [Mesh], Vagina/surgery[Mesh], Bioprosthesis [Mesh], Gynecologic surgical procedures[Mesh].

Supplementary data to this article can be found online at <http://dx.doi.org/10.1016/j.gore.2016.01.002>.

## References

- Benedetti Panici, P., Maffucci, D., Ceccarelli, S., Vescarelli, E., Perniola, G., Muzii, L., et al., 2015. Autologous in vitro cultured vaginal tissue for vaginoplasty in women with Mayer-Rokitansky-Kuster-Hauser syndrome: anatomic and functional results. *J. Minim. Invasive Gynecol.* 22 (2), 205–211 (Feb).
- Clemons, J.L., Myers, D.L., Aguilar, V.C., Arya, L.A., 2003. Vaginal paravaginal repair with an AlloDerm graft. *Am. J. Obstet. Gynecol.* 189 (6), 1612–1618 (discussion 1618–9, Dec).
- D'Souza, D.N., Pera, M., Nelson, H., Finical, S.J., Tran, N.V., 2003. Vaginal reconstruction following resection of primary locally advanced and recurrent colorectal malignancies. *Arch. Surg.* 138 (12), 1340–1343 (Dec).
- Dubin, M.G., Feldman, M., Ibrahim, H.Z., Tufano, R., Evans, S.M., Rosenthal, D., et al., 2000. Allograft dermal implant (AlloDerm) in a previously irradiated field. *Laryngoscope* 110 (6), 934–937 (Jun).
- Ibrahim, H.Z., Kwiatkowski, T.J., Montone, K.T., Evans, S.M., Rosenthal, D., Chalian, A.A., et al., 2000. Effects of external beam radiation on the allograft dermal implant. *Otolaryngol. Head Neck Surg.* 122 (2), 189–194 (Feb).
- Kuohung, W., Thompson, S.R., Laufer, M.R., 2007. Use of acellular human dermal allograft for vaginoplasty in Mayer-Rokitansky-Kuster-Hauser syndrome: a case report. *J. Reprod. Med.* 52 (9), 864–867 (Sep).
- McArdle, A., Bischof, D.A., Davidge, K., Swallow, C.J., Winter, D.C., 2012. Vaginal reconstruction following radical surgery for colorectal malignancies: a systematic review of the literature. *Ann. Surg. Oncol.* 19 (12), 3933–3942 (Nov).
- Nahabedian, M.Y., 2009. AlloDerm performance in the setting of prosthetic breast surgery, infection, and irradiation. *Plast. Reconstr. Surg.* 124 (6), 1743–1753 (Dec).
- Stany, M.P., Sunde, J., Bidus, M.A., Rose, G.S., Elkas, J.C., 2010. The use of acellular dermal allograft for vulvovaginal reconstruction. *Int. J. Gynecol. Cancer* 20 (6), 1079–1081 (Aug).
- Ward, R.M., Sung, V.W., Clemons, J.L., Myers, D.L., 2007. Vaginal paravaginal repair with an AlloDerm graft: long-term outcomes. *Am. J. Obstet. Gynecol.* 197 (6), 670.e1–670.e5, Dec).
- Wright, C., Hanna, M.K., 2014. Thirty-six vaginal constructions: lessons learned. *J. Pediatr. Urol.* 10 (4), 667–671 (Aug).
- Zhu, L., Zhou, H., Sun, Z., Lou, W., Lang, J., 2013. Anatomic and sexual outcomes after vaginoplasty using tissue-engineered biomaterial graft in patients with Mayer-Rokitansky-Kuster-Hauser syndrome: a new minimally invasive and effective surgery. *J. Sex. Med.* 10 (6), 1652–1658 (Jun).