

## The influence of chestnut wood and flubendazole on morphology of small intestine and lymphocytes of peripheral blood, spleen and jejunum in broiler chickens

M. LEVKUT Jr.<sup>1</sup>, V. REVAJOVÁ<sup>1\*</sup>, M. LEVKUTOVÁ<sup>1</sup>, E. SELECKÁ<sup>2</sup>, Z. ŠEVČÍKOVÁ<sup>1</sup>, V. KARAFFOVÁ<sup>1</sup>, M. LEVKUT Sr.<sup>1,3</sup>

<sup>1</sup>Department of Pathological Anatomy and Pathological Physiology, University of Veterinary Medicine and Pharmacy, Komenského 73, Košice, Slovakia; E-mail: [martin.levkut@uvlf.sk](mailto:martin.levkut@uvlf.sk), [viera.revajova@uvlf.sk](mailto:viera.revajova@uvlf.sk), [maria.levkutova@uvlf.sk](mailto:maria.levkutova@uvlf.sk), [zuzana.sevcikova@uvlf.sk](mailto:zuzana.sevcikova@uvlf.sk), [viera.karaffova@uvlf.sk](mailto:viera.karaffova@uvlf.sk); <sup>2</sup>Medivet, Školská 457/23, Dobrá Niva, E-mail: [selecka@mail.t-com.sk](mailto:selecka@mail.t-com.sk); <sup>3</sup>Institute of Neuroimmunology, Slovak Academy of Science, Dúbravská cesta 9, 845 10 Bratislava, Slovakia, E-mail: [mikulas.levkut@uvlf.sk](mailto:mikulas.levkut@uvlf.sk)

### Article info

Received January 31, 2019  
 Accepted August 25, 2019

### Summary

The study examined subpopulations of lymphocytes in peripheral blood, spleen, and jejunum including morphology of that segment in broiler chicken farm after treatment with flubendazole (Flimabend) and natural extract from chestnut wood (Farmatan). A total of 24 forty-day-old Kalimero-Super Master hybrid chickens were divided into 4 groups (n=6): the Fli group received Flimabend *per os*, 100 mg/g suspension in 1.43 mg of active substance/kg body weight during 7 day of experiment, Far group received Farmatan *per os* at 0.2 % concentration for 6 hours per day during 5 day (experimental days – from 3 to 7); the Far+Fli group received a combination of doses administered in the same way as for the first two groups; and control – C group with no active substance administration. The results demonstrated mild increase of leukocytes, lymphocytes, monocytes, leucocyte common antigen CD45, IgM+ and IgA+ cells in peripheral blood after administration of Flimabend. Similarly, subpopulations of followed lymphocytes (CD3+, CD4+, CD8+, IgM+) were increased in the jejunum after application of that drug. On the other hand, administration of Farmatan revealed opposite effect on determined immunocompetent cells what proves anti-inflammatory effect. Morphology of villi was also negatively influenced by administration of Flimabend. Administration of Farmatan suggests also its preventive administration in chickens. This tannin-containing drug as plant natural product may be used due to its antibacterial activity and as promising alternative to conventional drug with possible antihelminthic effect.

**Keywords:** Farmatan; Flubendazol; chicken; immunity; intestine

### Introduction

Flubendazole is a widely used antihelmintic drug belonging to benzimidazole group. The molecular mechanism of action of flubendazole is based on its specific binding to tubulin. Microtubule-targeted drugs are highly effective for treatment of fungal and parasitic infections (Chatterji *et al.*, 2011). They cause disruption of microtubule structure and function, also in the interference with the microtubule-mediated transport of secretory vesicles in absorptive tissues of helminths (Čaňová *et al.*, 2017). As the drugs act by

disrupting the tubulin-microtubule equilibrium in cells, this resulted to cessation of nutrient transport and eventual cell death. Flubendazole is a potent and efficacious antihelmintic for gastrointestinal nematode infections in poultry and domestic animals (Bradley *et al.*, 1983; Tarbiat *et al.*, 2016).

Flubendazole is usually administered orally and absorbed through the gastrointestinal tract. The drug is very poorly soluble in aqueous systems, causing its low absorption to the bloodstream and thus very low bioavailability (Michiels *et al.*, 1982).

Over the last years, the dietary role of tannins is receiving increas-

\* – corresponding author

ing interest as they may reduce the number of gastrointestinal parasites in birds (Marzoni *et al.*, 2005). Multiple reports suggest the efficacy of tannins or plant extracts in the control of zoonotic bacteria (Tosi *et al.*, 2013; Redondo *et al.*, 2014) and animal viruses (Lupini *et al.*, 2009) in gastrointestinal tract. Tannins can have beneficial effects on the digestion when incorporated into animal diets although their primary mode of action is often not sufficiently known to explain the final *in vivo* effects (Redondo *et al.*, 2014). Schiavone *et al.* (2008) found positive influence on growth performance, especially in young birds at the using up to 0.20 % natural extract of chestnut wood in diet. They did not observe any gross lesions at slaughtering as well as a lack of differences in intestinal length. Those results could indicate that toxicity of chestnut tannin used in their trial was low or absent. On the contrary, severe damage was reported in intestinal wall and other internal organs when doses higher than 30g/kg of tannic acid were administered to chicks (Singleton, 1981).

In the veterinary practice tannins are often use as additives with antihelmintic flubendazole for treatment of birds and to improve animal performance. We suggest that prolong application of flubendazole can be responsible for the modulation of immune response. On the other hand, moderate tannin level could improve health status of poultry.

That's why the goal of the paper is to follow the effect of flubendazole and extract of sweet chestnut (*Castanea sativa* Mill.) on the immunocompetent cells in peripheral blood, spleen and jejunal mucosa. Morphological parameters of intestinal wall evaluated in duodenum and jejunum included height and total area of villi. The potential immunomodulatory and antiparasitical effects are discussed.

## Materials and Methods

### *Chickens and diets*

The experiment was conducted in a commercial broiler chicken fattening farm. The broilers were housed in four floor pens identical with the same direction and covered area (0.12 m<sup>2</sup>/broiler chicken). Wooden barriers separated the individual groups of chickens from each other. Twenty four chickens 40 days old Kalimero-Super Master hybrid in finisher rearing period were included in the trial. The chickens were weighed, labelled and randomly divided into four groups of 6 chickens each (n=6): C (control), Far (Farmatan<sup>®</sup>), Fli (Flimabend<sup>®</sup>) and Far + Fli (Farmatan<sup>®</sup>+Flimabend<sup>®</sup>).

The animals had free access to feed and water. The diet corresponded to commercial diet for broiler chickens referred to Feeding Norms for Poultry in Slovakia (code of laws and decrees No. 440/2006). The diet included premix Tekro-finischer, extracted soya starch, wheat, maize, mineral additive. Composition of the diet (g.kg<sup>-1</sup>) was next: Crude protein: 240.84, Crude fat: 52.01, Crude fibre: 35.16; Crude ash: 62.12, Starch: 463.84, Total sugar: 58.13, Reducing sugar: 12.62; Calcium: 8.87; Phosphorus: 9.28; Sodium: 2.58; Methionine: 4.71; Lysine: 13.42; Cystine: 2.90. Chickens were

vaccinated against coccidiosis with Livacox Q on 5 day of age.

### *Administration of preparations and sampling*

Extract of sweet chestnut (*Castanea sativa* Mill.) was added into water (Farmatan<sup>®</sup> liquid, Tanin Sevnica d.d., Slovenia) of Far group chickens in 0.2 % concentration for 6 hours *per day* (8.00 – 14.00) during 5 days (from 3 to 7 experimental day). Chickens of Fli group received individually *per os* antihelminticum flubendazol (Flimabend<sup>®</sup>, 100 mg/g suspension, KRKA d.d., Slovenia) in 1.43 mg of active substance/kg body weight during 7 days of experiment. Group Far+Fli received Farmatan<sup>®</sup> liquid and Flimabend<sup>®</sup> in the similar way and for the same period as groups Fli and Far. Group C served as a negative control and fed with diet without supplementary Farmatan<sup>®</sup> or Flimabend<sup>®</sup>.

Two days after the administration of Farmatan<sup>®</sup> and Flimabend<sup>®</sup> all chickens were euthanized by intraabdominal injection of xylazine (Rometar 2 %, SPOFA, Czech Republic) and ketamine (Narkamon 5 %, SPOFA, Czech Republic) at doses 0.6 and 0.7 ml/kg body weight, respectively. The samples of peripheral blood were collected before euthanasia by wing vein bleeding from subcutaneous ulnar vein into Heparin (10-20 U/ml PBS, Zentiva, Czech Republic). Remaining samples were collected during the necropsy. Spleen and intestines for flow cytometry and immunohistochemistry were put into phosphate buffered saline (PBS, Sigma, Germany) and for morphometry into 10 % neutral buffered formalin (NBF, Formaldehyd p.a., Centralchem, Slovakia).

### *White blood cell count*

Leukocytes were counted in a haemocytometer using Fried-Lukačová solution (475 µl of solution plus 25 µl of blood). Differential cell counts of 100 cells per slide were done by light microscopy at 1000 magnification using blood smears stained with Hemacolor (Merck, Germany). The total numbers of different subtypes of white blood cells was then calculated: total leukocytes count x proportion of differential cells counted ( %) / 100.

### *Flow cytometry*

Peripheral blood lymphocytes were separated by Histopaque gradient sedimentation (1.077 g/mL, Sigma-Aldrich, Germany) according to Boyum (1974). Mouse anti-chicken monoclonal antibodies CD3, CD4, CD8 (T-cells), leucocyte common antigen CD45, IgA and IgM (B-cells) labelled with FITC (SouthernBiotech, USA) were used for immunophenotyping of lymphocytes by direct immunofluorescent method. The control antibody, polyclonal goat-anti mouse FITC-conjugated immunoglobulin F(ab')<sub>2</sub> fragment (Dako, Denmark) was used at a working dilution 1:50 with PBS. After separation the lymphocytes were washed twice with PBS. Fifty µL of cellular suspension (1.10<sup>6</sup> lymphocytes in PBS) and 2 µl of specific or control MoAbs were mixed and incubated in dark at 22 °C for 15 min. After being stained, the cells were washed once in 0.5 mL PBS, and resuspended in 0.2 mL of PBS with 0.1 % paraformaldehyde.

Table 1. Absolute count of white blood cells (WBC; G.L<sup>-1</sup>= 10<sup>9</sup>. L<sup>-1</sup>) in the peripheral blood of chickens (mean ± SD).

WBC	C	Far	Fli	Far+Fli
Leukocytes	13.72 ± 2.71	8.85 ± 2.92 <sup>a</sup>	14.58 ± 3.02 <sup>b</sup>	14.40 ± 3.46 <sup>b</sup>
Lymphocytes	6.68 ± 0.35	5.44 ± 1.57 <sup>a</sup>	8.63 ± 1.53 <sup>d</sup>	8.37 ± 0.72 <sup>d</sup>
Heterophiles	6.23 ± 2.44	2.65 ± 1.41	4.91 ± 2.39	4.63 ± 3.18
Eosinophiles	0.53 ± 0.23	0.47 ± 0.19	0.61 ± 0.34	0.88 ± 0.34
Monocytes	0.43 ± 0.06	0.29 ± 0.07 <sup>a</sup>	0.44 ± 0.14	0.46 ± 0.12 <sup>b</sup>

Specific superscripts in row indicate significant differences – <sup>ab</sup>P<0.05; <sup>ad</sup>P<0.001

Measurement and analysis of stained cells was performed on FACS system (Becton Dickinson, Germany) provided with a 15 mV argon ion laser. The analysis examined a dot plot of the leukocytes obtained by the forward and side scattering of the physical character of the lymphocyte population. Gates were drawn around lymphocytes based on 90° and forward-angle light scatter. The fluorescence data were collected on at least 10,000 lymphocytes using the Becton Dickinson CellQuest programme. The results are therefore expressed as the relative percentage of the lymphocyte subpopulation which was positive for a specific MoAb. Counting to absolute values was next: absolute count of lymphocytes x relative percentage of subpopulation's lymphocytes/100.

#### Immunohistochemistry

The jejunae were collected into phosphate-buffered saline (PBS; pH 7.6) and then frozen and cut at -20 °C with Thermo Scientific Cryotome E (Shandon, USA). Frozen 4 µm sections fixed in cold acetone and rinsed in PBS were stained in Shandon Coverplate Technology system (BU Thermo Shandon, Germany). A streptavidin-biotin amplified peroxidase detection system (VECTASTAIN Elite ABC kit, Mouse IgG, PK 6102, Vector Laboratories, USA) was used to detect CD3, CD4, CD8, CD45, IgM and IgA positive lymphocytes. Unlabelled primary mouse anti-chicken monoclonal antibodies (Southern Biotech, USA) for staining CD3 (CD3-UNLB, Clone CT-3, Cat. No. 8200-01), CD4 (CD4-UNLB, Clone CT-4,

Cat. No. 8210-01), CD8 (CD8α-UNLB, Clone CT-8, Cat. No. 8220-01), IgA (IgA-UNLB, Clone A-1, Cat. No.8330-01), IgM (IgM-UNLB, Clone M-1, Cat. No. 8300-01) were used in 1:10 dilution with PBS. Mouse IgG1-UNLB antibody (Clone 15H6, Cat. No. 0102-01, Southern Biotech, USA) was used as negative control. All incubations were done at room temperature according to the manual instructions. The sections were rinsed three times with PBS between the two consecutive incubations. The specific colour reaction was developed for 5 min with 3.5 mmol/L 3,3'-diaminobenzidine (DAB, Sigma, Germany), and 30 ppm hydrogen peroxide in 200 mmol/L Tris-HCl (pH 7.6). Subsequently the sections were counterstained with haematoxylin and mounted into Pertex (Histolab AB, Swedish). Quantification of labelled lymphocytes was performed under light microscope (NIKON Labophot 2, Germany) at a magnification of × 200 and by using of NIS-Elements version 3.0 software (Laboratory Imaging, Czech Republic). The photos from three jejunal sections at one slide were done and positive staining lymphocytes in 10 randomly chosen areas (a=60 000 µm<sup>2</sup>) were counted. Calculation to 1 mm<sup>2</sup> was done as follows: 1 000 000/60 000 x cell numbers.

#### Histology and morphometry of duodenum and jejunum

Routine histological method with haematoxylin-eosin staining was used. Height and surface area of the villi in duodenal and jejunal samples collected from five chickens were analysed. The histo-

Table 2. Subpopulations of lymphocytes in the peripheral blood (total counts = G.L<sup>-1</sup>) and spleen (relative percentage)(mean ± SD).

Groups	Peripheral blood					
	Subpopulations of lymphocytes (mean ± SD)					
	CD3	CD4	CD8	IgM	IgA	CD45
C	2.33 ± 0.79	1.32 ± 0.44	0.80 ± 0.20	0.85 ± 0.24	0.29 ± 0.26	4.32 ± 0.62
Far	2.37 ± 1.08	1.45 ± 0.63	0.72 ± 0.37	0.58 ± 0.23 <sup>a</sup>	0.13 ± 0.11 <sup>c</sup>	2.89 ± 1.01 <sup>a</sup>
Fli	3.12 ± 0.90	1.82 ± 0.71	0.84 ± 0.19	1.20 ± 0.32 <sup>c</sup>	0.70 ± 0.39 <sup>a</sup>	5.42 ± 1.05 <sup>d</sup>
Far+Fli	3.05 ± 0.73	1.99 ± 0.69	0.75 ± 0.18	0.95 ± 0.22	0.26 ± 0.12 <sup>c</sup>	5.18 ± 0.84 <sup>d</sup>
Spleen						
C	66.14 ± 10.02	16.39 ± 9.27	39.83 ± 7.94	14.88 ± 5.64 <sup>a</sup>	25.13 ± 17.25	29.53 ± 9.67
Far	66.29 ± 6.21	24.33 ± 7.24	39.72 ± 10.82	19.91 ± 6.99	16.87 ± 5.95	30.30 ± 5.82
Fli	66.65 ± 5.92	22.59 ± 6.08	39.79 ± 5.62	26.57 ± 7.80 <sup>b</sup>	19.97 ± 2.59	32.22 ± 5.90
Far+Fli	63.51 ± 11.10	19.51 ± 8.31	35.17 ± 13.07	18.26 ± 5.67	15.24 ± 3.42	32.76 ± 8.65

Specific superscripts in columns indicate significant differences – <sup>ab</sup>P<0.05; <sup>ac</sup>P<0.01; <sup>ad</sup>P<0.001

Table 3. Subpopulations of lymphocytes in jejunal mucosa (mm<sup>2</sup>).

Subpopulations	C	Far	Fli	Far+Fli
CD3	598.90 ± 204.20 <sup>d</sup>	312.00 ± 105.10 <sup>a</sup>	680.10 ± 186.80 <sup>d</sup>	672.30 ± 252.00 <sup>d</sup>
CD4	614.40 ± 187.00 <sup>d</sup>	282.00 ± 94.69 <sup>a</sup>	641.70 ± 185.40 <sup>da</sup>	547.10 ± 151.70 <sup>dc</sup>
CD8	770.10 ± 213.40 <sup>d</sup>	388.60 ± 159.50 <sup>a</sup>	794.20 ± 257.30 <sup>d</sup>	743.20 ± 220.20 <sup>d</sup>
IgM	203.90 ± 122.30 <sup>a</sup>	146.70 ± 91.80 <sup>c</sup>	216.00 ± 88.14 <sup>a</sup>	149.60 ± 73.22 <sup>bc</sup>
IgA	331.10 ± 162.40	250.80 ± 180.40	294.10 ± 200.20	274.60 ± 160.40

Specific superscripts in row indicate significant differences – <sup>ab</sup>P<0.05; <sup>ac</sup>P<0.01; <sup>ad</sup>P<0.001

logical samples were microphotographed (Nikon LABOPHOT 2 with a camera adapter DS Camera Control Unit DS\_U2, 4x) and then the NIS-Elements version 3.0 software (Laboratory Imaging, Czech Republic) was used. The heights of the villi were measured from the basal region, which corresponded to the higher section of the crypts, to the apex (µm). Total cutting surface area of separate intestinal segments included length and breadth of villi (µm<sup>2</sup>). The data were finally exported to MS Excel and subsequently statistically analysed.

#### Statistical analysis

Statistical analysis of obtained data was done by one-way analysis of variance (ANOVA) with the *post hoc* Tukey multiple comparison test using GraphPad Software, statistical version 5.0 (USA). The differences between the mean values for the groups of chickens were considered significant when P < 0.05. Values were expressed as means ± standard deviation (SD).

#### Ethical Approval and/or Informed Consent

All applicable national and institutional guidelines for the care and use of animals were followed.

## Results

#### Peripheral white blood cells

Increase in total number of leukocytes (Table 1) was found in Fli and Far+Fli groups when compared with Far group (P<0.05). Similarly, the number of lymphocytes was higher in Fli and Far+Fli groups than in Far group (P<0.001). Monocytes also demonstrated improved values in Fli and Far+Fli groups in comparison with Far group, but with significance only in Far+Fli group (P<0.01).

#### Phenotyping of lymphocytes in blood and spleen

In the peripheral blood the highest values in all determined subpopulation of lymphocytes (Table 2) were achieved in Fli group. Its levels outnumbered the counts in C and Far groups with exception to CD4+ cells in combined Far+Fli group. Density of CD3+ and CD4+ (T cells) showed no significant improvement in Fli and Far+Fli groups. Determination of B cells showed higher values of IgM+ cells in both Fli and Far+Fli groups when compared to Far group, but were significant (P<0.01) only for Fli group. IgA+ subpopulation demonstrated highest values (P<0.01) not only to Far but also to Far+Fli group. Density of leucocyte common antigen CD45 was increased in Fli and Far+Fli groups when compared with Far group (P<0.001).

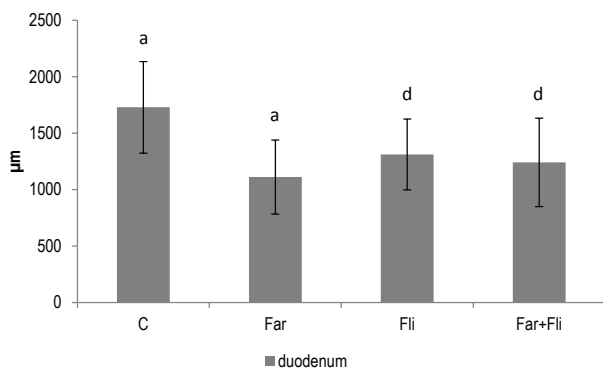


Fig. 1. Height of duodenal villi (mean±SD, <sup>ad</sup>P>0.001).

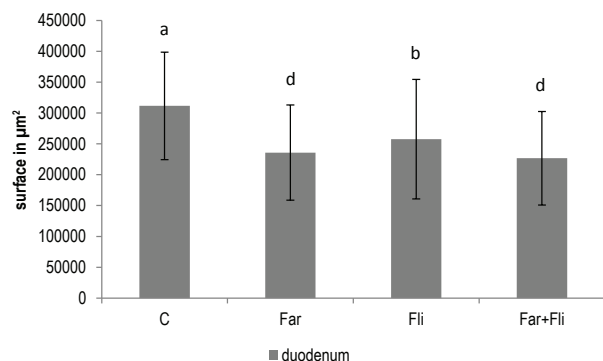


Fig. 2. Cutting surface of duodenal villi (mean±SD, <sup>ab</sup>P>0.05, <sup>ad</sup>P>0.001).

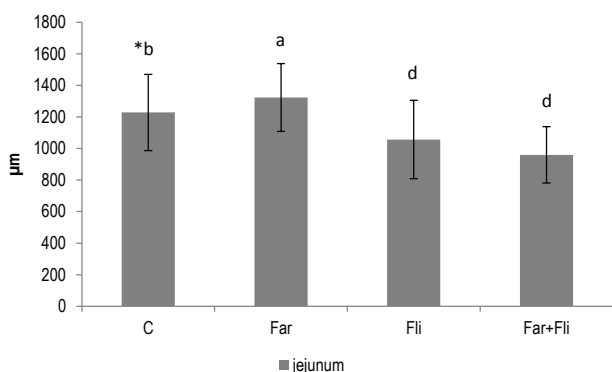


Fig. 3. Height of jejunal villi (mean±SD, <sup>ab</sup>P<0.05, <sup>ad</sup>P<0.001).

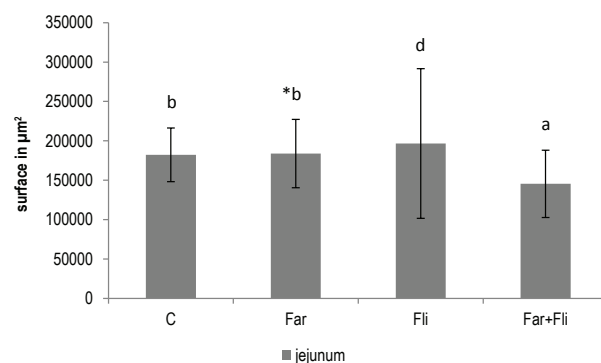


Fig. 4. Cutting surface of jejunal villi (mean±SD, <sup>ab</sup>P<0.05, <sup>ad</sup>P<0.001).

In spleen (Table 2) the T cell subpopulations (CD3+, CD4+, CD8+) did not change. Regarding the B cells an increase in IgM+ in Fli group was seen when compared to the control broilers (P<0.05). Density of IgA+ in experimental groups was higher. However, not significant when compared with controls.

#### Phenotyping of lymphocytes in jejunal mucosa

Jejunal mucosa in Far group (Table 3) showed lower number

of CD3+ lymphocytes than seen in Fli, Far+Fli and C broilers (P<0.001). In similar way, the numbers of CD4+ and CD8+ lymphocytes were lower in Far group when compared to Fli, Far+Fli and C groups (P<0.001). Moreover, CD4+ cells were increased in Fli group contrasting to Far+Fli group (P<0.01).

IgM+ cells were found to be lower in Far (P<0.01) and Far+Fli (P<0.05) groups than in C group. In contrast, decrease of IgM+ lymphocytes was found in Far+Fli group in comparison to Fli

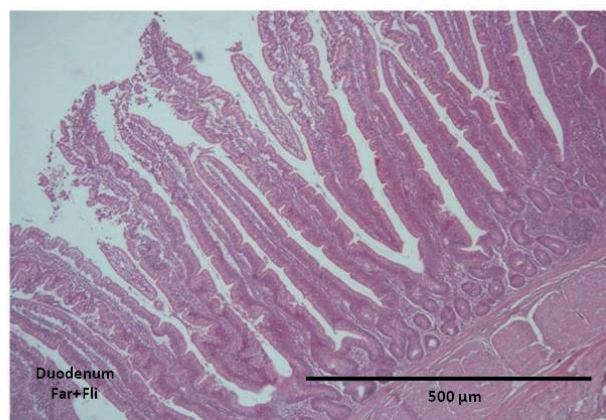
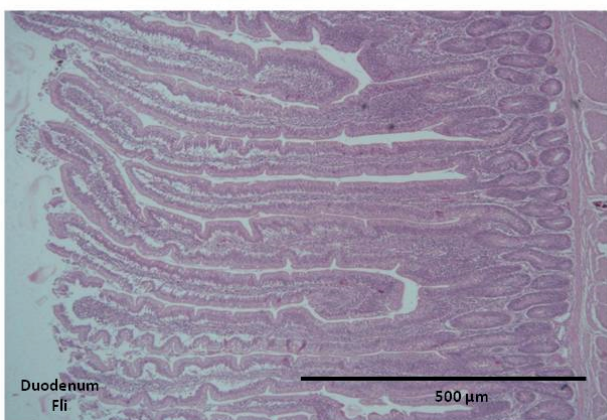
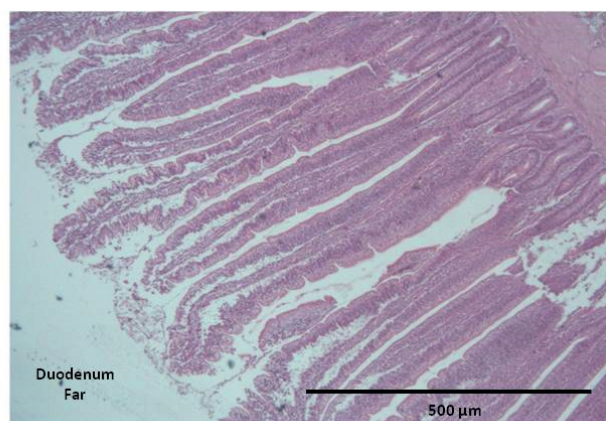
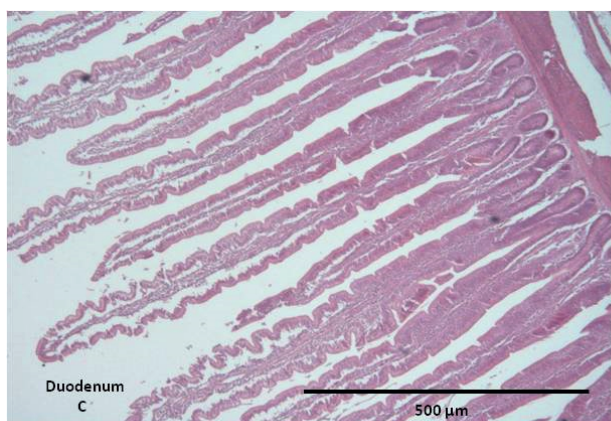


Fig. 5. Histological pictures from duodenum of different chicken' groups (HE stain).

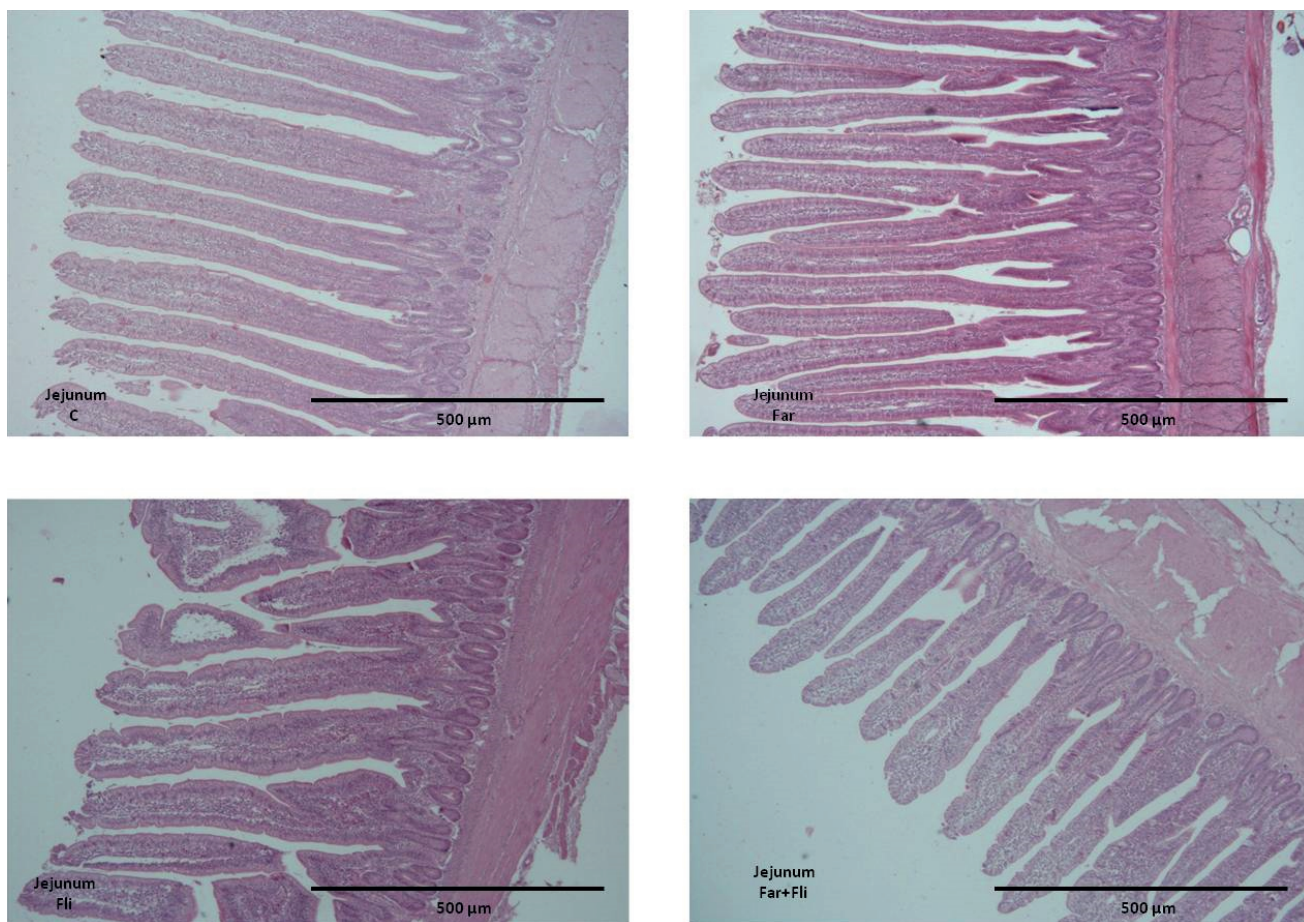


Fig. 6. Histological pictures from jejunum of different chicken' groups (HE stain).

( $P < 0.01$ ) group. The IgA+ subpopulation was downregulated in experimental group when compared to control broilers.

#### Morphometry of duodenum and jejunum

In duodenum the Far group showed decrease in height of villi (Fig. 1) as compared with Fli and Far+Fli ( $P < 0.001$ ). Similarly, significant decrease was found between Fli and Far+Fli groups when compared with control group ( $P < 0.001$ ). The highest differences were detected in duodenum (Fig. 5). In comparison to control the cutting surface of duodenal villi (Fig. 2) was lower in Far, Far+ Fli groups ( $P < 0.001$ ) and Fli group ( $P < 0.05$ ).

In jejunum Far and C groups showed increase in height of villi (Fig. 3, Fig. 6) when compared to Fli and Far+Fli groups ( $P < 0.001$ ). However, the Far group outnumbered C group ( $P < 0.05$ ). Cutting surface of jejunal villi (Fig. 4) was lowest in Far+ Fli group in comparison to Fli ( $P < 0.001$ ) and Far groups ( $P < 0.05$ ). Values of Far group were merely higher than values detected in C group ( $P < 0.05$ ).

#### Discussion

Flubendazole, one of the benzimidazole anthelmintics, is widely used for treatment and prevention of endoparasitic infections in poultry (Baliharová *et al.*, 2004). Commercially available flubendazole-based products are used mainly against helminth parasites of chickens as *Ascaridia galli*, *Heterakis gallinarum* and *Capillaria* spp. (Squires *et al.*, 2012). On the other hand, tannins included in low concentration of the diet have positive influence on the growth performance (Redondo *et al.*, 2014), reduce the spread/occurrence gastrointestinal parasites in birds (Marzoni *et al.*, 2005) and was proven to possess antimicrobial activity (Elizondo *et al.*, 2010). Beneficial properties of tannins prompted us to test this substance during administration of flubendazole.

*Ascaridia galli* is a common parasite in small intestine of chickens. After ingestion of the embryonated eggs, these are transported until they reach the duodenum and/or jejunioileum, where they hatch; larvae are released and penetrate the epithelium (Luna-Olivares *et al.*, 2015). From these reasons, the evaluation of immunocom-

petent cells and morphological parameters in intestine – jejunum – was selected.

Seven days administration of antihelmintic drug caused mild increase in the number of peripheral blood leukocytes, lymphocytes and monocytes in groups with flubendazole. Similarly, flubendazole modulated the level of IgM+, IgA+ cells and CD45 in peripheral blood, and IgM+ cells in spleen. Observed shift in immunocompetent cells suggests systemic immune response to antihelmintic drug. Our results are in accordance with results done in our laboratory (Karaffová *et al.*, 2019) where the upregulation of pro-inflammatory cytokines (IL-1 $\beta$  and IL-18) in Fli group was demonstrated. CD3+, CD4+, CD8+, IgM+ increase in chicken intestine after seven days flubendazole administration support the mild inflammatory role of drug in the chicken *duodenum*. On the other hand, five days administration of farmatan decreased the number of immunocompetent cells in chickens what suggest on tannins anti-inflammatory effect. Recently, many studies demonstrated the anti-inflammatory effect of tannins. Araújo-Neto *et al.* (2010) have shown the anti-inflammatory effect of tannins with *Sideroxylon obtusifolium* on paw oedema induced by carrageenan. Another study exploiting a wound model and skin healing in rats showed its topical anti-inflammatory and healing activity (Leite *et al.*, 2015). Finally, anti-inflammatory properties were found in ethyl acetate phase of *Anacardium occidentale* rich in tannins (de Araújo Vilar *et al.*, 2016). Recently, Williams *et al.* (2014) provided clear evidence of the direct antihelmintic effects of tannins against *Ascaris*. On the other hand, our working group in another paper (Karaffová *et al.*, 2019) demonstrated the upregulation of MUC-2 and IgA gene in the duodenum of chickens after administration of tannin. IgA forms the first line of defence to limit epithelial contact with and penetration by intestinal microbiota and other potentially dangerous antigens (Zhang *et al.*, 2015). MUC2 expression increases from anterior to posterior through the gastrointestinal tract (Jiang *et al.*, 2013), and protective role of mucins against parasites include the demonstration of trapping of worms in the mucus as well inhibition of parasite motility and feeding capacity (Khan *et al.*, 2008). Consistent increase of T cell subpopulations and MUC2 gene upregulation suggest subsequent mucus production in our experiment (Theodoropoulos *et al.* 2001).

Height of villi and cut surface of villi decreased in experimental groups comparing to control. This phenomenon can be explained by lower number of immunocompetent cells in the mucous including villi in Far group and negative effect of benzimidazoles on proliferation of enterocytes. It is known that benzimidazoles can affect also host tubulin (Mackenzie and Geary, 2011) and what can be connected with the decrease the height of villi in groups with benzimidazoles. Increased thickness of depth of crypts in Fli group also suggests mild inflammatory process with increased number of immunocompetent cells.

A normal morphology and intestinal permeability of the small intestine is important to prevent bacteria translocation from the intestinal tract to the body as well as for digestion and absorption

of nutrients (Quinteiro-Filho *et al.*, 2010; Awad *et al.*, 2017). An increase of immunocompetent cells in the peripheral blood and jejunal mucosa in our trial is likely to be indicative of a possible intestinal mucosa barrier dysfunction (Beatty *et al.*, 2017) and, consequently bacterial infection. Inflammatory infiltrate is suggests to be contributed to the production of proinflammatory cytokines observed in that experiment (Karaffová *et al.*, 2019) and affect on the intestinal epithelium's tight junctions, in turn increasing the mucous permeability to pathogenic bacteria.

In conclusion, the results in our study demonstrated mild inflammatory effect on leukocytes, lymphocytes, monocytes, leucocyte common antigen CD45, IgM+ and IgA+ cells in peripheral blood after administration of Flimabend. Similarly, subpopulations of followed lymphocytes (CD3+, CD4+, CD8+, IgM+) were increased in the intestine after application of that drug. On the other hand, administration of Farmatan revealed the opposite effect on immunocompetent cells what proves to have an anti-inflammatory effect. Morphology of villi and depth of crypts was negatively influenced by administration of Flimabend. Results obtained also suggest the utilisation of Farmatan as preventive – immunomodulatory substance reducing inflammation as well as the adjuvant in treatment with antihelmintics.

#### Acknowledgments

This work was supported by the Grant Agency for Science of the Slovak Republic VEGA 1/0112/18, 1/0355/19, Slovak Research and Developmental Agency APVV-15-0165 and the EU structural fund ITMS 26220220185 (Medipark).

#### Conflict of Interests

Authors state no conflict of interests.

#### References

- AWAD, W.A., HESS, C., HESS, M. (2017): Enteric pathogens and their toxin-induced disruption of the intestinal barrier through alteration of tight junction in chickens. *Toxins (Basel)*, 9(2): 60. DOI: 10.3390/toxins9020060
- ARAÚJO-NETO, V., BOMFIM, R.R., OLIVEIRA, V.O.B., PASSOS, A.M.P.R., OLIVEIRA, J.P.R., LIMA, C.A., MENDES, S.S., ESTEVAM, C.S., THOMAZZI, S.M. (2010): Therapeutic benefits of *Sideroxylon obtusifolium* (Humb. Ex Roem. & Schult.) T. D. Penn., Sapotaceae, in experimental models of pain and inflammation. *Rev. Bras. Farmacogn.*, 20(6): 933 – 938. DOI: 10.1590/S0102-695X2010005000043
- BALIHAROVÁ, V., VELÍK, J., SAVLÍK, M., SZOTÁKOVÁ, B., LAMKA, J., TAHOŤNÁ, L., SKÁLOVÁ, L. (2004): The effects of fenbendazole, flubendazole and mebendazole on activities of hepatic cytochromes P450 in pigs. *J. Vet. Pharmacol. Ther.*, 27(2): 85 – 90. DOI: 10.1111/j.1365-2885.2004.00557.x
- BOYUM, M.A. (1974): Separation of blood leukocytes, granulocytes

- and lymphocytes. *Tissue Antigens*, 4(4): 269 – 274
- BEATTY, J.K., AKIERMAN, S.V., MOTTA, J.P., MUISE, S., WORKENTINE, M.L., HARRISON, J.J., BHARGAVA, A., BECK, P.L., RIOUX, K.P., MCKNIGHT, G.W., WALLACE, J.L., BURET, A.G. (2017): *Giardia duodenalis* induces pathogenic dysbiosis of human intestinal microbiota biofilms. *Int. J. Parasitol.*, 47(6): 311 – 326. DOI: 10.1016/j.ijpara.2016.11.010
- BRADLEY, R.F., GUERRERO, J., BECKER, H.N., MICHAEL, B.F., NEWCOMB, K. (1983): Flubendazole: dose range and efficacy studies against common internal parasites of swine. *Am. J. Vet. Res.*, 44(7): 1329 – 1333
- ČAŇOVÁ, K., ROZKYDALOVÁ, L., RUDOLF, E. (2017): Anthelmintic flubendazole and its potential use in anticancer therapy. *Acta Medica*, 60(1): 5 – 11. DOI: 10.14712/18059694.2017.44
- DE ARAÚJO VILAR, M.S., DE SOUZA, G.L., DE ARAÚJO VILAR, D., LEITE, J.A., RAFFIN, F.N., BARBOSA-FILHO, J.M., NOGUEIRA, F.H.A., RODRIGUES-MASCARENHAS, S., DE LIMA MOURA, T.F.A. (2016): Assessment of phenolic compounds and antiinflammatory activity of ethyl acetate phase of *Anacardium occidentale* L. bark. *Molecules*, 21(8): 1087. DOI: 10.3390/molecules21081087
- DE BOEVER, S., VANGESTEL, C., DE BACKER, P., CROUBELS, S., SYS, S.U. (2008): Identification and validation of housekeeping genes as internal control for gene expression in an intravenous LPS inflammation model in chickens. *Vet. Immunol. Immunopathol.*, 122(3-4): 312 – 317. DOI: 10.1016/j.vetimm.2007.12.002
- EDGAR, R. C., HAAS, B. J., CLEMENTE, J. C., QUINCE, C., KNIGHT, R. (2011): UCHIME improves sensitivity and speed of chimera detection. *Bioinformatics*, 27(16): 2194 – 2200
- JIANG, Z., APPLGATE, T.J., LOSSIE, A.C. (2013). Cloning, annotation and developmental expression of the chickens intestinal MUC2 gene. *PLoS ONE*, 8, e53781. DOI: 10.1371/journal.pone.0053781
- ELIZONDO, A. M., MERCADO, E. C., RABINOVITZ, B. C., FERNANDEZ-MIYAKAWA, M. E. (2010): Effect of tannins on the in vitro growth of *Clostridium perfringens*. *Vet. Microbiol.*, 145(3 – 4): 308 – 314. DOI:10.1016/j.vetmic.2010.04.003
- CHATTERJI B.P., JINDAL B., SRIVASTAVA S., PANDA D. (2011): Microtubules as antifungal and antiparasitic drug targets. *Expert Opin. Ther. Pat.*, 21(2): 167 – 186. DOI: 10.1517/13543776.2011.545349
- KARAFFOVÁ, V., BOBÍKOVÁ, K., LEVKUT, M., REVAJOVÁ, V., ŠEVČÍKOVÁ, Z., LEVKUT, M. (2019): The influence of Farmatan® and Flimabend® on the mucosal immunity of broiler chicken. *Poult. Sci.* 98(3): 1161 – 1166. DOI: 10.3382/ps/pey517
- KHAN, W.I. (2008): Physiological changes in the gastrointestinal tract and host protective immunity: learning from the mouse-*Trichinella spiralis* model. *Parasitology*, 135(6), 671 – 682. DOI: 10.1017/S0031182008004381
- LEITE, N.S., LIMA, A.P., ARAÚJO-NETO, V., ESTEVAM, C.S., PANTALEÃO, S.M., CAMARGO, E.A., FERNANDES, R.P.M., COSTA, S.K.P., MUSCARÁ, M.N., THOMAZZI, S.M. (2015): Avaliação das atividades cicatrizante, anti-inflamatória tópica e antioxidante do extrato etanólico da *Sideroxylon obtusifolium* (quixabeira) [Evaluation of the cicatrizing, topical anti-inflammatory and antioxidant activities of the ethanol extract of *Sideroxylon obtusifolium*]. *Rev. Bras. Plantas Med.*, 17(1): 164 – 170. DOI: 10.1590/1983-084X/09\_189 (In Portuguese)
- LUNA-OLIVARES, L.A., KYVSGAARD, N.C., FERDUSHY, T., NEJSUM, P., THAMSBORG, S.M., ROEPSTORFF, A., IBURG, T.M. (2015): The jejunal cellular responses in chickens infected with a single dose of *Ascaridia galli* eggs. *Parasitol. Res.*, 114(7): 2507 – 2515. DOI: 10.1007/s00436-015-4450-y
- LUPINI, C., CECCHINATO, M., SCAGLIARINI, A., GRAZIANI, R., CATELLI, E. (2009): In vitro antiviral activity of chestnut and quebracho woods extracts against avian reovirus and metapneumovirus. *Res. Vet. Sci.*, 87(3): 482 – 487. DOI: 10.1016/j.rvsc.2009.04.007
- MACKENZIE, C.C., GEARY, T.G. (2011): Flubendazole: a candidate microfilaricide for lymphatic filariasis and onchocerciasis field programs. *Expert Rev. Anti Infect Ther.*, 9(5): 497 – 501. DOI: 10.1586/eri.11.30
- MARZONI, M., CASTILLO, A., ROMBOLI, I. (2005): Effect of dietary inclusion of quebracho (*Schinopsis lorentzii*) tannins on productive performances of growing pheasant females. *Ital. J. Anim. Sci.*, 4 (Suppl. 2): 507 – 509
- MICHELIS, M., HENDRIKS, R., HEYKANTS, J., VAN DEN BOSSCHE, H. (1982): The pharmacokinetics of mebendazole in animals and man. *Arch. Int. Pharmacodyn. Ther.*, 256(2): 180 – 191
- QUINTEIRO-FILHO, W.M., RIBEIRO, A., FERRAZ-DE-PAULA, V., PINHEIRO, M.L., SAKAI, M., SÁ, L.R., FERREIRA, A.J., PALERMO-NETO, J. (2010): Heat stress impairs performance parameters, induces intestinal injury, and decreases macrophage activity in broiler chickens. *Poult. Sci.*, 89(9): 1905 – 1914. DOI: 10.3382/ps.2010-00812
- REDONDO, L.M., CHACANA, P.A., DOMINQUEZ, J.E., FERNANDEZ MIYAKAWA, M.E. (2014): Perspectives in the use of tannins as alternative to antimicrobial growth promoter factors in poultry. *Front. Microbiol.*, 5: 118, 1 – 7. DOI: 10.3389/fmicb.2014.00118
- SCHIAVONE, A., GUO, K., TASSONE, S., GASCO, L., HERNANDEZ, E., DENTI, R., ZOCCARATO, I. (2008): Effect of a natural extract of chestnut wood on digestibility, performance traits, and nitrogen balance of broiler chicks. *Poult. Sci.*, 87(3): 521 – 527. DOI: 10.3382/ps.2007-00113
- SINGLETON, V. (1981): Naturally occurring food toxicant: phenolic substances of plant origin common in foods. *Adv. Food Res.*, 27: 149 – 242
- SCHLOSS, P.D., WESTCOTT, S.L., RYABIN, T., HALL, J.R., HARTMANN, M., HOLLISTER, E.B., LESNIEWSKI, R.A., OAKLEY, B.B., PARKS, D.H., ROBINSON, C.J., SAHL, J.W., STRES, B., THALLINGER, G.G., VAN HORN, D.J., WEBER, C.F. (2009): Introducing mothur: open-source, platform-independent, community-supported software for describing and comparing microbial communities. *Appl. Environ. Microbiol.*, 75(23): 7537 – 7541. DOI: 10.1128/AEM.01541-09
- SQUIRES, S., FISHER, M., GLADSTONE, O., ROERSON, S., MARTIN, P., MARTIN, S., LESTER, H., SYGALL, R., UNDERWOOD, N. (2012): Comparative efficacy of flubendazole and a commercially available herbal wormer against natural infections of *Ascaridia galli*, *Heterakis gallinarum* and intestinal *Capillaria* spp. in chickens. *Vet. Parasitol.*,



185(2-4): 352 – 354. DOI: 10.1016/j.vetpar.2011.09.034

TARBIAT, B., JANSSON, D.S., MORENO, L., LANUSSE, C., NYLUND, M., TYDÉN, E., HÖGLUND, J. (2016): The efficacy of flubendazole against different developmental stages of poultry roundworm *Ascaridia galli* in laying hens. *Vet. Parasitol.*, 218: 66 – 72. DOI: 10.1016/j.vetpar.2016.01.012

THEODOROPOULOS, G., HICKS, S.J., CORFIELD, A.P., MILLER, B.G., CARRINGTON, S.D. (2001): The role of mucins in host parasite interactions: Part II – helminth parasites. *Trends Parasitol.*, 17(3): 130 – 135. DOI: 10.1016/S1471-4922(00)01775-X

TOSI, G., MASSI, P., ANTONGIOVANNI, M., BUCCIONI, A., MINIERI, S., MA-

RENCHINO, L., MELLE, L. (2013): Efficacy test of a hydrolysable tannin extract against necrotic enteritis in challenged broiler chickens. *Ital. J. Anim. Sci.*, 12 (3): 123 – 132. DOI: 10.4081/ijas.2013.e62

WILLIAMS, A.R., FRYGANAS, CH., RAMSAY, A., MUELLER-HARVEY, I., THAMSBORG, S.M. (2014): Direct antihelmintic effects of condensed tannins from diverse plant sources against *Ascaris suum*. *PLoS ONE*, 9(5): e97053. DOI: 10.1371/journal.pone.0099738

ZHANG, Q., EICHER, S.D., APPLGATE, T.J. (2015): Development of intestinal mucin 2, IgA, and polymeric Ig receptor expressions in broiler chickens and Pekin ducks. *Poult. Sci.*, 94(2): 172 – 180. DOI: 10.3382/ps/peu064