




ELSEVIER

Contents lists available at ScienceDirect

Medical Mycology Case Reports

journal homepage: www.elsevier.com/locate/mmcr

Gastrointestinal granuloma due to *Candida albicans* in an immunocompetent cat

Anne-Claire Duchaussoy^a, Annie Rose^a, Jessica J. Talbot^b, Vanessa R. Barrs^{b,*}^a University of Melbourne, Veterinary Teaching Hospital 250 Princes Highway, Werribee 3030, Australia^b Faculty of Veterinary Science, Valentine Charlton Cat Centre, University of Sydney, NSW 2006, Australia

ARTICLE INFO

Article history:

Received 25 November 2015

Received in revised form

7 December 2015

Accepted 11 December 2015

Available online 12 December 2015

Keywords:

Cat

Gastrointestinal

Fungal

Candida albicans

ABSTRACT

A 3.5 year-old cat was admitted to the University of Melbourne Veterinary Teaching Hospital for chronic vomiting. Abdominal ultrasonography revealed a focal, circumferential thickening of the wall of the duodenum extending from the pylorus aborally for 3 cm, and an enlarged gastric lymph node. Cytology of fine-needle aspirates of the intestinal mass and lymph node revealed an eosinophilic inflammatory infiltrate and numerous extracellular septate acute angle branching fungal-type hyphae. Occasional hyphae had globose terminal ends, as well as round to oval blastospores and germ tubes. *Candida albicans* was cultured from a surgical biopsy of the duodenal mass. No underlying host immunodeficiencies were identified. Passage of an abrasive intestinal foreign body was suspected to have caused intestinal mucosal damage resulting in focal intestinal candidiasis. The cat was treated with a short course of oral itraconazole and all clinical signs resolved.

© 2015 International Society for Human and Animal Mycology. International Society for Human and Animal Mycology Published by Elsevier B.V. All rights reserved.

1. Introduction

There are more than 150 species of *Candida* but only a small percentage of these are frequent pathogens of humans. *Candida* spp. are commensals of humans and animals and normally inhabit the alimentary, upper respiratory and lower urogenital tracts. Complications secondary to local overgrowth and extension due to impairment of the mucosal barrier are the most common causes of invasive mycoses reported in people but have rarely been described in cats and dogs [1,2].

The ability of *Candida* to adhere to vaginal, gastrointestinal and oral epithelial cells is well documented [2]. However, to become pathogenic, interruption of normal defence mechanisms is necessary. In cats, this can occur as a result of naturally occurring disease including diabetes mellitus, feline immunodeficiency virus (FIV) and feline leukaemia virus (FeLV) infection, or from iatrogenic factors, especially therapeutic modalities such as antibiotic administration, surgery and indwelling urinary catheters [1]. Most reported cases of candidiasis in companion animals have involved the urinary tract of immunocompromised patients [3,4]. Peritonitis and visceral organ invasion has also been reported in dogs [1]. Here we report the first case of a gastrointestinal granuloma due to *Candida albicans* in a young immunocompetent cat.

2. Case

A 3.5 year-old domestic shorthair cat was referred to the University of Melbourne's Veterinary Teaching Hospital (Day 0) for investigation of chronic intermittent vomiting of 6 months duration. Vomiting occurred 2–3 h after eating every 2–3 days. Appetite was maintained and there was no weight loss. A dietary trial with a hypoallergenic diet (Hill's Z/d dry cat food) did not improve the clinical signs. No antibiotics had been prescribed and anti-inflammatory or intestinal worming treatments had not been administered in the previous 6 months. Deterioration with gradual increased frequency of vomiting and lethargy occurred before presentation to the teaching hospital.

Physical examination revealed a weight of 4.8 kg (body score condition 3/9), normothermia and normal respiratory and cardiovascular auscultation. A small firm mass was palpable in the cranial abdomen. No pain response was elicited on palpation. Fundoscopic examination was unremarkable. A complete blood count showed a mild peripheral eosinophilia ($3.7 \times 10^9/L$, reference interval [RI] $0-1.5 \times 10^9/L$) and normal haematocrit (37%, [RI] 30–45%) and total white cell count ($12.8 \times 10^9/L$, RI $5-19.5 \times 10^9/L$). Results of a serum biochemistry panel were within reference intervals. Serology for detection of FeLV antigens and FIV antibodies was negative (FASTest[®] FeLV-FIV, Diagnostik MEGACOR Germany).

On abdominal ultrasonography there was circumferential

* Corresponding author.

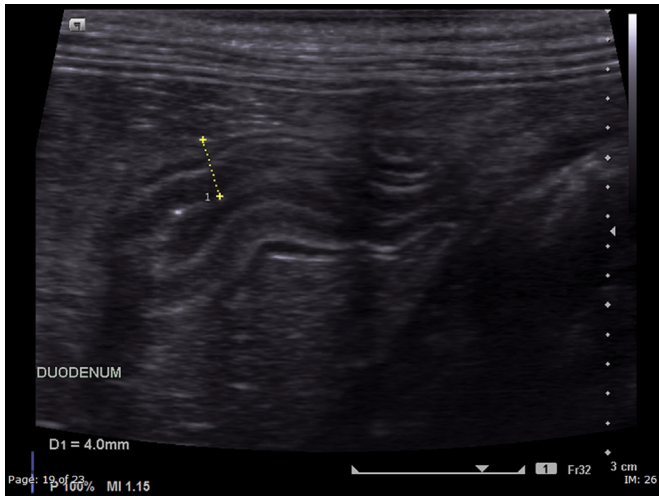


Fig. 1. Abdominal ultrasonographic image showing the focal, circumferential thickening of the descending duodenum.

thickening of the descending duodenum (wall thickness 4.5 mm RI < 3 mm) extending from the pylorus aborally for 3 cm. The muscularis layer was disproportionately thickened, and there was no loss of integrity of normal intestinal wall layering (Fig. 1). The regional gastric lymph node was markedly enlarged (14.9 mm × 8.1 mm), hypoechoic and rounded. The rest of the gastrointestinal tract appeared normal and no other abnormalities were identified.

Ultrasound-guided fine needle aspirates were collected from the thickened region of duodenal wall and enlarged gastric lymph node. On cytology of the gastric lymph node there was an inflammatory infiltrate consisting of abundant eosinophils and non-degenerate neutrophils and occasional well granulated mast cells and macrophages. Lymphoid cells comprised small lymphocytes (54–80%), intermediate lymphocytes (12–34%), large lymphocytes (4–11%) and plasma cells (1–4%). The smears of the duodenal mass were poorly cellular and mainly comprised eosinophils. Differential diagnosis included neoplasia, focal sterile or infectious granuloma (e.g. fungal, protozoal, bacterial or viral including feline infectious peritonitis), feline gastrointestinal eosinophilic sclerosing fibroplasia (FGESF) and an embedded foreign body.

Thoracic radiographs were unremarkable, and an exploratory laparotomy was performed on Day 1. The origin of the proximal duodenum circumferential mass was confirmed to be just cranial to the pyloric sphincter extending 3 cm along the proximal duodenum. The mass was firm and hyperaemic and incorporated the opening of the common bile duct into the duodenum (Fig. 2). Gastric and mesenteric lymph nodes were also enlarged. Full resection of the mass and cholecystojejunostomy was recommended

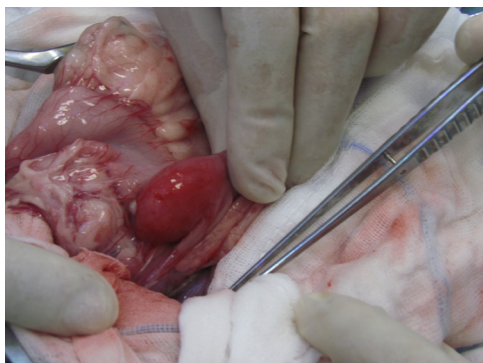


Fig. 2. Focal circumferential lesion in the proximal duodenum visualised during the exploratory laparotomy.

but declined by the owner due to financial constraints and potential complications of the procedure. Fine needle aspirates of the duodenal mass and gastric lymph node, full-thickness incisional biopsies of the mass, stomach, jejunum and ileum and excisional biopsies of the jejunal and gastric lymph nodes were performed. Repeat cytology of the duodenal mass revealed an eosinophil-rich inflammatory response and intralésional fungal elements (Fig. 3). Inflammatory cells comprised neutrophils (32–90%), eosinophils (2–44%), mast cells (0–18%), lymphocytes (6%), macrophages (0–2%) and occasional plasma cells (Fig. 1). In some of the cytological preparations there were numerous extracellular septate acute angle branching fungal hyphae (3–5 µm diameter), occasionally with a globose terminal end. Round to oval blastospores and germ tubes (2–3 µm diameter), some of which were intracellular within neutrophils, were also noted. Repeated cytology of the lymph node confirmed reactive lymphoid hyperplasia.

Histopathological features of the stomach and small intestine were assessed according to World Small Animal Veterinary Association criteria, and were normal [5], except for a mild increase in eosinophils within the lamina propria in the proximal portion of the ileum. There was marked chronic lymphoid hyperplasia of the gastric lymph node with a moderate to marked expansion of the parafollicular lymphocytes. Sinuses contained a small to moderate number of neutrophils and lymphocytes. In the mesenteric lymph node follicles were small with prominent germinal centres. One macrophage within medullary sinuses contained two small round thin-walled structures, suspected to be fungal elements.

On histopathology of the duodenal mass, the submucosa was markedly expanded by irregular connective tissue, fibroblasts, endothelium, and multifocal to coalescing infiltrates of macrophages, neutrophils, lymphocytes and plasma cells, consistent with moderate to marked, and chronic, focally extensive, pyogranulomatous enteritis involving the sub-mucosa. There was evidence of thickening of duodenal muscle layers, as noted on ultrasonography. This was attributed mainly to oedema and regional myofibre degeneration along with subserosal accumulations of eosinophils, neutrophils occasional macrophages and lymphocytes. Further fungal elements could not be identified on H&E or periodic acid Schiff stains on the excisional biopsy sample. Culture of the duodenal mass yielded a pure culture of narrow-necked ovoid, budding, non-capsulate yeasts, which produced germ tubes within 3 h of incubation in serum broth at 35 °C. A panfungal PCR amplification of the ITS1-5.8s-ITS2 region of ribosomal DNA was performed. On comparative sequence analysis there was 100% homology with reference strains of *C. albicans* (GenBank KP131671.1, KP 131658.1) (Irinnyi, Serena et al. 2015). Antifungal susceptibility testing was performed at the National Mycology Reference Centre, Adelaide (Table 1).

Fungal and bacterial urine cultures were negative. Post-operative recovery was unremarkable and the cat was treated with itraconazole (5 mg/kg q 12 h orally). Due to poor patient compliance treatment was stopped after 6 days. No further vomiting occurred and appetite and demeanor remained normal.

At a recheck examination 7 weeks after the surgery, the cat was well and had increased in body weight from 4.8 to 5.2 kg. Physical examination and ocular examination including fundoscopy was unremarkable. On repeat haematology there was normalisation of the previous eosinophilia, and serum biochemistry and urinalysis were within RI. Repeat abdominal ultrasonography revealed persistence of a relative thickening of the muscularis layer at the level of the pyloro-duodenal junction (1.3 mm thick, RI 0.05 mm [6]) for a segment of 8 mm length (previously 30 mm). This change occupied portions of the circumference of the proximal descending duodenum, whereas previously the changes were circumferential. The gastric lymph node was not present; the hepatic lymph node was visualised and was of normal size.

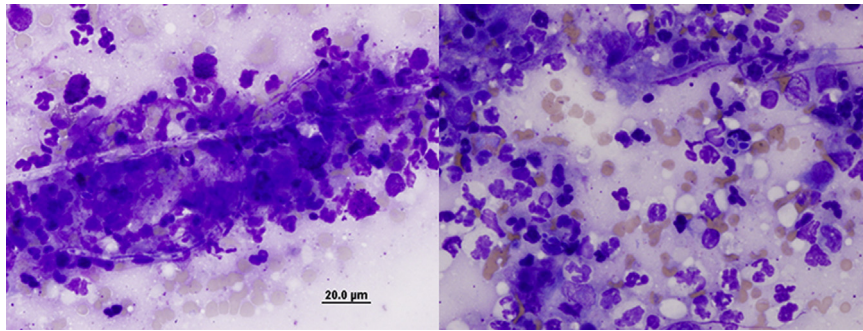


Fig. 3. Cytological preparation of the duodenal mass, modified Wright–Giemsa stain. Note the presence of visible hyphae (A) and round to oval blastospores and germ tubes of 2–3 μm (B).

Table 1
Antifungal susceptibility results for the intestinal *C. albicans* isolate.

Antifungal	MIC (mg/L)
Amphotericin B	0.25 N
5-Fluorocytosine	< 0.06 N
Fluconazole	0.5 S
Itraconazole	0.06 N
Voriconazole	< 0.008 S
Posaconazole	0.015 N
Caspofungin	0.06 S
Anidulafungin	0.06 S
Micafungin	0.015 S

MIC=Minimum inhibitory concentration
S=Sensitive, R=Resistant, I=Intermediate, SDD=Susceptible dose dependent
N=No interpretive criteria are available as yet for this species/drug.

The cat represented 7 months after surgery for 3 days of vomiting. Physical examination was unremarkable and the cat had not lost weight. On repeat abdominal ultrasonography the hepatic lymph node was of normal size and the duodenal lesion was unchanged from the last ultrasound. The previous granuloma was not considered the likely cause for the recent clinical signs. The cat responded to a hypoallergenic diet and improved after a day in hospital. No further vomiting was reported by the owners 9 months after surgery.

3. Discussion

This is the first report of gastro-intestinal candidiasis in a companion animal that is not associated with septic peritonitis secondary to a perforating duodenal ulcer or intestinal dehiscence after surgery [1]. The presence of a single pyogranulomatous intestinal lesion is unusual [7]. No underlying reason could be identified to explain an abnormal or disrupted gastrointestinal intestinal mucosal barrier leading to opportunistic candidiasis. Previously described underlying causes leading to the classical pathway of *Candida* invasion were not present [8]; there was no history of antibiotic, anti-acid, glucocorticoid or anti-inflammatory treatment [7]. Furthermore, in humans, the stomach and the duodenum have a physiologically more acidic environment and the lowest number of *C. albicans* compared to other regions of the gastrointestinal tract. This is likely to be similar in cats and dogs, but has not been confirmed. Hence the stomach and duodenum are unusual sites for candidiasis due to an abnormal or disrupted gastrointestinal microbiome [9]. An abrasive foreign body causing focal mucosal disruption was considered the most likely

explanation in this case, even though no foreign material was detected on histopathological examination of multiple sections of the intestinal mass. However, a foreign-body could have caused traumatic intestinal injury during passage without being retained.

Other possible, but less likely explanations for candidiasis in this case include a transient defective local immunity associated with a viral infection (e.g. Coronavirus, Rotavirus) and/or intestinal dysbiosis. Both pathogenic factors and an impaired intestinal mucosal barrier are required for invasive *C. albicans* infection. Virulence factors of *C. albicans* include the ability to adhere to epithelial cells and to form biofilms. The ability to form hyphae is also a virulence factor and is associated with active infection, since hyphal forms can invade epithelial cells and cause tissue damage [10]. In the case here, hyphae were visualised on cytological preparations of the intestinal lesion. This finding, in combination with culture and ITS-sequencing results is evidence of an active infection of *C. albicans*. No bacterial involvement was identified.

Several mechanisms are implicated in the development of *C. albicans* infection, including an inadequate host immune response (Yan, Yang et al. 2013). Induction of the initial mucosal immune responses occurs in the gut associated lymphoid tissue (GALT), within Peyer's patches and mesenteric lymph nodes [11]. Many host cellular pattern recognition receptors (PPARgamma and Dectin-1) have also been identified to interact with *C. albicans* [12,13]. Presence of bile acids and an abnormally increased gastric pH may promote *C. albicans* virulence [14]. Hence chronic gastroenteritis or long term treatment with anti-acids can lead to invasive candidiasis. *C. albicans* itself can delay gastrointestinal ulcer healing by releasing cytokines (IL-1beta and TNF-alpha) which perpetuate ongoing inflammation and promote conditions for gastrointestinal wall invasion and adherence [15]. Altered host/*C. albicans* interactions could lead to local and systemic infection. In our cat, no underlying disease, gastro-intestinal bacterial overgrowth, chronic inflammation or systemic debilitating diseases were identified. An improvement 6 weeks after the introduction of a hypoallergenic diet (Hills' Z/d) raises suspicion of a possible inflammatory disorder, which could have been the source of an altered host/*C. albicans* interaction, although the focal nature of the disease makes this less likely.

Recommended treatment for this active yeast infection includes surgical resection followed by medical treatment. In this case, due to financial constraints and poor patient compliance surgical resection was not possible and only a short oral course of itraconazole was administered. However, a dramatic improvement in both clinical signs and the size of the initial lesion was observed 8 weeks post-surgical biopsy (Day 60) and was sustained 9 months post-surgery (Day 275).

Conflict of interest

There are none.

Ethical form

Please note that this journal requires full disclosure of all sources of funding and potential conflicts of interest. The journal also requires a declaration that the author(s) have obtained written and signed consent to publish the case report from the patient or legal guardian(s).

The statements on funding, conflict of interest and consent need to be submitted via our Ethical Form that can be downloaded from the submission site www.ees.elsevier.com/mmcr. Please note that your manuscript will not be considered for publication until the signed Ethical Form has been received.

Acknowledgements

The authors thank Dr. Erin Bell from University of Melbourne Veterinary Teaching Hospital for her help in case management.

References

- [1] K. Bradford, J. Meinkoth, K. McKeirnen, B. Love, *Candida peritonitis* in dogs: report of 5 cases, *Veter. Clin. Pathol./Am. Soc. Veter. Clin. Pathol.* 42 (2) (2013) 227–233, Epub 2013/06/05.
- [2] M.J. Kennedy, P.A. Volz, C.A. Edwards, R.J. Yancey, Mechanisms of association of *Candida albicans* with intestinal mucosa, *J. Med. Microbiol.* 24 (4) (1987) 333–341, Epub 1987/12/01.
- [3] B.M. Pressler, S.L. Vaden, I.F. Lane, L.D. Cowgill, J.A. Dye, *Candida* spp. urinary tract infections in 13 dogs and seven cats: predisposing factors, treatment, and outcome, *J. Am. Anim. Hosp. Assoc.* 39 (3) (2003) 263–270, Epub 2003/05/21.
- [4] Y. Jin, D.L. Fungal, urinary tract infections in the dogs and cat: a retrospective study (2001–2004), *J. Am. Anim. Hosp. Assoc.* 41 (6) (2005) 373–381.
- [5] M.J. Day, T. Bilzer, J. Mansell, B. Wilcock, E.J. Hall, A. Jergens, et al., Histopathological standards for the diagnosis of gastrointestinal inflammation in endoscopic biopsy samples from the dog and cat: a report from the World Small Animal Veterinary Association Gastrointestinal Standardization Group, *J. Comp. Pathol.* 138 (Suppl 1) (2008) S1–43, Epub 2008/03/14.
- [6] M.D. Winter, L. Londono, C.R. Berry, J.A. Hernandez, Ultrasonographic evaluation of relative gastrointestinal layer thickness in cats without clinical evidence of gastrointestinal tract disease, *J. Feline Med. Surg.* 16 (2) (2014) 118–124, Epub 2013/08/03.
- [7] L. Yan, C. Yang, J. Tang, Disruption of the intestinal mucosal barrier in *Candida albicans* infections, *Microbiol. Res.* 168 (7) (2013) 389–395, Epub 2013/04/03.
- [8] J.C. Heseltine, D.L. Panciera, G.K. Saunders, Systemic candidiasis in a dog, *J. Am. Veter. Med. Assoc.* 223 (6) (2003) 821–824, Epub 2003/09/26.
- [9] S.J. O'Flaherty, T.R. Klaenhammer, Functional and phenotypic characterization of a protein from *Lactobacillus acidophilus* involved in cell morphology, stress tolerance and adherence to intestinal cells, *Microbiology* 156 (Pt 11) (2010) 3360–3367, Epub 2010/09/11.
- [10] P.E. Sudbery, Growth of *Candida albicans* hyphae, *Nat. Rev. Microbiol.* 9 (10) (2011) 737–748, Epub 2011/08/17.
- [11] D. Luongo, R. D'Arienzo, P. Bergamo, F. Maurano, M. Rossi, Immunomodulation of gut-associated lymphoid tissue: current perspectives, *Int. Rev. Immunol.* 28 (6) (2009) 446–464, Epub 2009/12/04.
- [12] L. Lefevre, A. Gales, D. Olganier, J. Bernad, L. Perez, R. Burcelin, et al., PPAR-gamma ligands switched high fat diet-induced macrophage M2b polarization toward M2a thereby improving intestinal *Candida* elimination, *Plos. one* 5 (9) (2010) e12828, Epub 2010/09/30.
- [13] A. Gales, A. Conduche, J. Bernad, L. Lefevre, D. Olganier, M. Beraud, et al., PPARgamma controls Dectin-1 expression required for host antifungal defense against *Candida albicans*, *Plos. Pathog.* 6 (1) (2010) e1000714, Epub 2010/01/12.
- [14] M. Nagi, K. Tanabe, Y. Takano, K. Kikuchi, Y. Miyazaki, M. Niimi, Serum or bile affects the in vitro azole susceptibilities of *Candida* spp., *Jpn. J. Infect. Dis.* 62 (4) (2009) 306–308, Epub 2009/07/25.
- [15] T. Brzozowski, M. Zwolinska-Wcislo, P.C. Konturek, S. Kwiecien, D. Drozdowicz, S.J. Konturek, et al., Influence of gastric colonization with *Candida albicans* on ulcer healing in rats: effect of ranitidine, aspirin and probiotic therapy, *Scand. J. Gastroenterol.* 40 (3) (2005) 286–296, Epub 2005/06/04.