



ELSEVIER

Contents lists available at ScienceDirect

Journal of Cardiology Cases

journal homepage: www.elsevier.com/locate/jccase

Case Report

Anticoagulation for hypercoagulability in severe critical COVID-19: A case series of fading and fatal cycles of microthrombosis



Diana Maria Ronderos Botero (MD)^{a,b,1}, Alaa Mabrouk Salem Omar (MD, MSc, PhD)^{b,c,d,e,1},
Marin Nicu (MD)^{b,c,d}, Eduard Sklyar (MD)^{b,c,d}, Jonathan N. Bella (MD)^{b,c,d},
Sridhar Chilimuri (MD)^{b,d,*}

^a Department of Pulmonary Medicine and Critical Care, BronxCare Health System, Bronx, NY, USA

^b Department of Medicine, BronxCare Health System, Bronx, NY, USA

^c Department of Cardiology, BronxCare Health System, Bronx, NY, USA

^d Icahn School of Medicine at Mount Sinai, New York, NY, USA

^e Department of Cardiology, Mount Sinai Morningside, New York, NY, USA

ARTICLE INFO

Article history:

Received 20 April 2021

Revised 21 August 2021

Accepted 26 August 2021

Keywords:

COVID-19

D-Dimer

Hypercoagulability

Anticoagulation

Fibrinolysis

ABSTRACT

The pathophysiology of the COVID-19 involves a systemic hypercoagulable state and systemic microthrombosis which can cause fatal consequences. Despite that anticoagulation seems an intuitive therapeutic option, the US National Institute of Health has issued a warning against its use in critically ill patients. We present five cases of imaging-proven or clinically suspected hypercoagulability with hemodynamic compromise despite therapeutic anticoagulation. We describe the patients with thoughts on links between pathophysiology and the laboratory values, clinical course, and imaging studies in each case. All patients presented to the hospital with symptoms and chest imaging suggestive of COVID-19 pneumonia. All patients presented with severe hypoxia requiring mechanical ventilation, and received full anticoagulation for treatment of hypercoagulable state suggested by elevated D-dimer. All but one patient received alteplase for thrombolytic therapy of suspected massive pulmonary embolism (PE). On the basis of this case series, hypercoagulability in COVID-19 is a late manifestation of the disease that persists despite anticoagulation, is cyclic in nature based on D-dimer despite thrombolysis, and is fatal if it rebounds. The use of anticoagulation and thrombolysis in these patients seemed harmful or non-beneficial. Early intervention before D-dimer elevation and hemodynamic compromise may benefit in preventing thromboembolic burden.

<Learning objective: Fatal and hemodynamically significant hypercoagulability in COVID-19 patients is cyclic in nature as evident by re-elevation of D-dimer levels during hospitalization. As suggested by the US National Institute of Health, anti-coagulation in these patients does not seem to prevent mortality. Cyclic thromboembolism seems to be a late manifestation of the disease during which stage it is already too late for the use of therapeutics. A signal of harm for anticoagulation in these patients may be related to a coagulopathy state.>

© 2021 Japanese College of Cardiology. Published by Elsevier Ltd. All rights reserved.

Introduction

The heterogeneity of COVID-19 poses a challenge toward therapeutics [1]. COVID-19 is being increasingly recognized as an endothelial disease, which may lead to an imbalance in the homeostasis between coagulation and fibrinolysis, leading to increasing

amounts of localized thrombosis. However, predictors of thrombosis, time of initiation of treatment, and effective management strategies remain to be clarified. Despite the thrombotic nature, the US National Institute of Health (NIH) has recently instructed to pause recruiting critical COVID-19 patients to anticoagulation clinical trials, as therapeutic doses of anticoagulation did not reduce the risk and were associated with a signal of harm [2]. In this article, we describe five patients with hemodynamically significant fatal hypercoagulability despite receiving therapeutic anticoagulation and/or systemic thrombolysis.

* Corresponding author at: BronxCare Hospital Center, 1650 Grand Concourse, Bronx, NY 10457, USA.

E-mail address: chilimuri@bronxleb.org (S. Chilimuri).

¹ Diana Maria Ronderos Botero and Alaa Mabrouk Salem Omar Contributed Equally.

Table 1
Demographic, clinical, laboratory, and imaging description of the 5 cases.

	Case 1	Case 2	Case 3	Case 4	Case 5
Age (year)	74	47	84	60	57
Gender	Female	Male	Male	Male	Male
Duration of symptoms	5 days	7 days	Weeks	3 days	Unknown
Medical history	DM	DM	HTN/DM	None	None
Blood pressure, systolic/diastolic (mmHg)	144/110	105/70	106/65	122/80	125/68
Temperature (°C)	37.2	36.4	36.9	36.9	37.2
Heart rate (beats/minute)	118	115	120	122	113
Respiratory rate (Cycle/minute)	24	33	48	18	22
Admission O2 saturation on room air	92%	78%	74%	86%	69%
X-ray chest infiltrates	No	Yes	Yes	Yes	Yes
Computed tomography of the chest	Infiltrates Scattered emboli	Not done	Not done	Infiltrates Emboli	Not done
Laboratory values on admission					
Hemoglobin (g/dl)	15.9	16.3	10.1	14.6	14.6
Total white cell count (10³/uL)	6.6	13.4	14.8	20.5	13.8
Neutrophils (10³/uL)	5.4	11.7	12.4	18.9	12
Lymphocytes (10³/uL)	0.6	0.9	1.0	1.0	1.1
Platelets (10³/uL)	229	268	267	241	269
D-Dimer on admission (Normal range: 0 -230 ng/ml)	1968	4331	22620	27741	3612
Prothrombin time (seconds)	10.5	15.6	16.5	17.5	12.9
International normalized ratio	0.89	1.31	1.38	1.47	1.09
Partial thromboplastin time (seconds)	25.5	29.8	27.4	31.3	24.9
High sensitivity C-reactive protein (mg/L)	123	205.3	219.2	255.7	131
Ferritin (mg/ml)	1858	597	805.3	240	654
Lactate dehydrogenase (units/L)	366	674	390	957	1430
Pro-brain natriuretic peptide (pg/ml)	3027	8471	Not done	586	1058
High sensitivity troponin (ng/L)	Not done	Not done	Not done	140	Not done
Sodium (Meq/L)	157	136	135	130	136
Potassium (Meq/L)	4.6	4.5	6.0	4.1	4.8
Creatinine (mg/dL)	1.1	1.1	2.2	1.4	1.4
Lactic acid (mmoles/L)	3	4.3	6.2	4.7	3.9
Echo findings					
Right ventricular strain	Not done	Yes	Yes	Yes	No
Left ventricular ejection fraction (%)	Not done	66%	51%	58%	63%
Right ventricular dilation	Not done	Yes	Yes	Yes	No
McConnell's sign	Not done	Yes	Yes	Yes	No
Fluttering septum	Not done	Yes	Yes	Yes	No
Right ventricular systolic pressure (mmHg)	Not done	58	93	91	39
Prior anticoagulation	No	No	No	No	No
Anticoagulation treatment for PE	Yes	Yes	Yes	Yes	Yes
Alteplase	No	Yes	Yes	Yes	Yes
Outcome	Sudden cardiac arrest	Sudden cardiac arrest	Sudden cardiac arrest	Sudden cardiac arrest	Sudden cardiac arrest
Duration of hospitalization	6 days	2 days	2 days	16 days	17 days

Case reports

We present five critical COVID-19 cases with hemodynamically significant hypercoagulability. Severe hypoxia was a common finding, requiring mechanical ventilation (MV) in the intensive care unit (ICU). No patient received anticoagulation prior to admission, and all received full therapeutic anticoagulation for treatment of hypercoagulable state based on imaging or rise of D-dimer. Four patients received alteplase for thrombolytic therapy. Anticoagulation and alteplase were administered in accordance with institutional protocol. No bleeding episodes were reported throughout the hospitalization. A summary of all cases is found in Table 1. Informed consents were obtained from the legal proxies of all patients.

Case 1

A 75-year-old diabetic female presented with 5 days severe nausea and multiple episodes of non-bloody, non-bilious vomiting and confusion. Electrocardiography (ECG) showed sinus tachycardia. Non-contrast computed tomography (CT) of the head showed

no acute findings. Contrast CT of the chest revealed bilateral acute segmental and sub-segmental pulmonary embolism (PE) (Fig. 1). Lower extremity ultrasound revealed bilateral femoral deep venous thrombosis. In the ICU, the patient was started on full dose of enoxaparin, however, in the last day the patient developed atrial fibrillation with rapid ventricular response and hypotension requiring vasopressors. Alteplase was prescribed but not given as the patient developed acute bradycardia then asystole without return of spontaneous circulation (ROSC) despite advanced cardiac life support (ACLS) protocol.

Case 2

A 47-year-old diabetic male presented with 1 week worsening sore throat, cough, fever, myalgia, and shortness of breath (SOB). Initial D-dimer value was 4331 ng/ml, and he was started on IV unfractionated heparin (UFH) [14 units/kg/hr with goal activated partial thromboplastin time (aPTT): 50-70 seconds]. aPTT levels were 40, 131, 173, and 52 sec and remained therapeutic thereafter. Vasopressors were started for management of shock with increasing MV requirements. Echocardiography on the second day

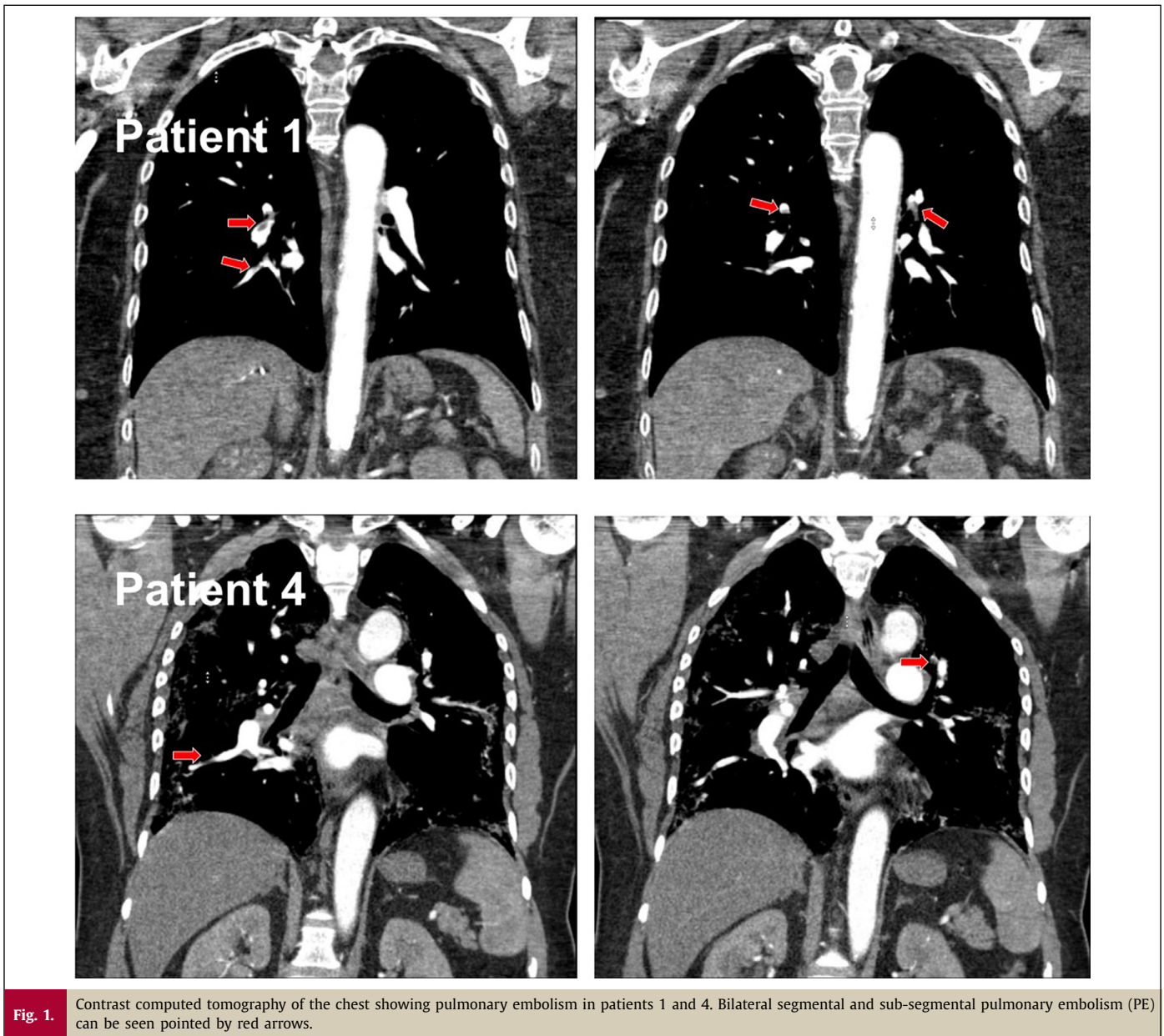


Fig. 1. Contrast computed tomography of the chest showing pulmonary embolism in patients 1 and 4. Bilateral segmental and sub-segmental pulmonary embolism (PE) can be seen pointed by red arrows.

showed right ventricle (RV) strain and severe pulmonary hypertension (PHTN). Accordingly, intravenous alteplase was initiated. The patient remained on MV, UFH, and vasopressors requirement decreased. On the third day, the patient developed asystole and died. Despite the possible multifactorial etiology of death, worsening oxygenation, echocardiographic findings, and rising D-dimer levels were considered highly suggestive of PE.

Case 3

An 84-year-old diabetic and hypertensive male presented with 2 weeks cough, myalgia, diarrhea, and SOB at rest. On admission, facial droop, slurred speech, and hypoxia were noted. CT of the head was free of pathology. ECG showed right bundle branch block and sinus tachycardia. D-dimer was 22620 ng/ml and therapeutic enoxaparin was started. On the second day, vasopressors were started for shock management. Echocardiography showed RV strain and severe PHTN. Intravenous alteplase was initiated, however transient sinus bradycardia and asystole then death quickly followed. Given the circulatory shock, echocardiographic findings,

death can be explained by severe hypoxia in the setting of PE and RV dysfunction.

Case 4

A 60-year-old male with no medical history presented with 3 days SOB, cough, fever, and pleuritic chest pain. Contrast CT of the chest showed small volume of pulmonary emboli in the left upper lobe and in the right lower lobe (Fig. 1). ECG showed sinus tachycardia. Admission D-dimer was 27741 ng/ml and enoxaparin was started. D-dimer levels decreased to 3377 on the 4th day. Later, MV and vasopressors were started due to severe hypoxia and shock, and a second peaking of D-dimer was noted (Fig. 2). Echocardiography on the 10th day showed RV strain and severe PHTN. Intravenous alteplase was initiated. Blood pressure improved and vasopressors were weaned, however, he remained on MV. On the 14th day, the patient became acutely hypoxic with increase in MV requirements. On the 15th day the patient suddenly developed asystole and died.

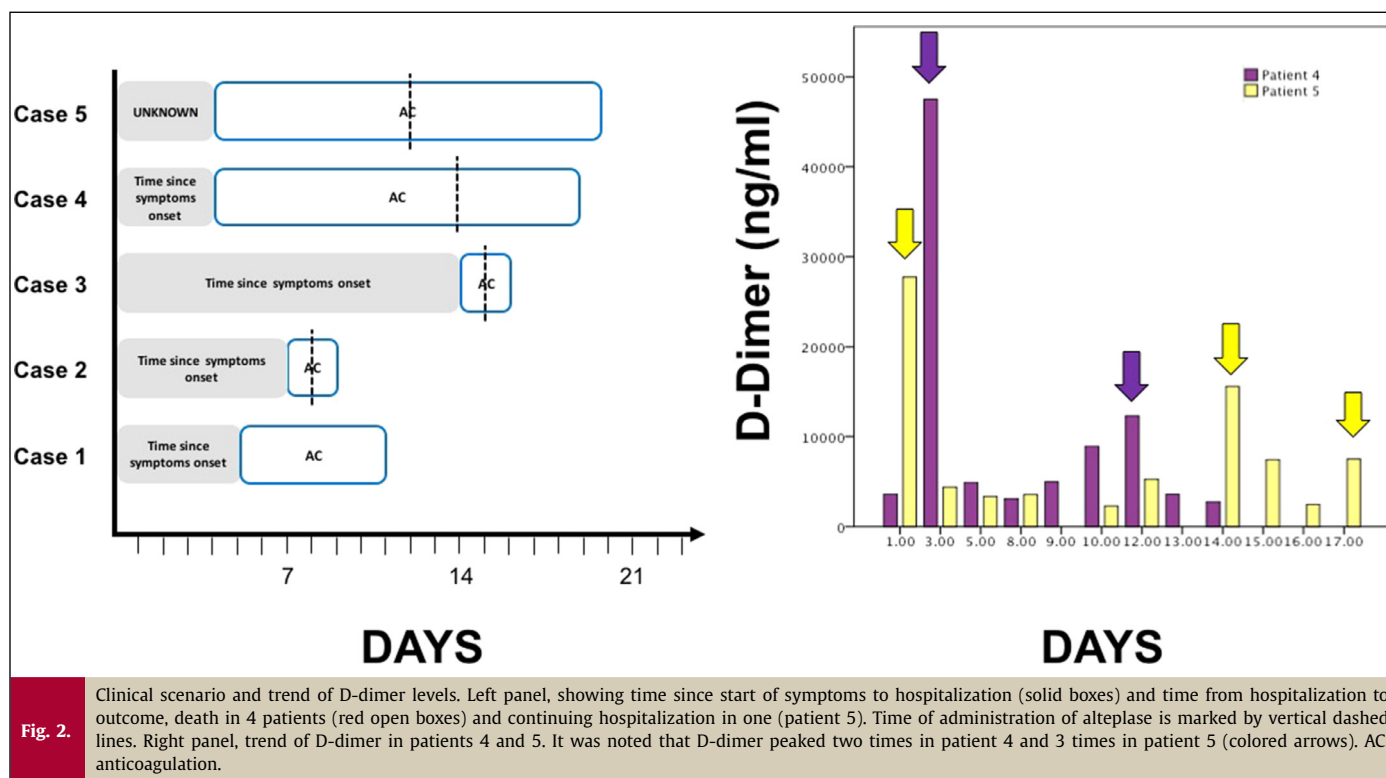


Fig. 2.

Clinical scenario and trend of D-dimer levels. Left panel, showing time since start of symptoms to hospitalization (solid boxes) and time from hospitalization to outcome, death in 4 patients (red open boxes) and continuing hospitalization in one (patient 5). Time of administration of alteplase is marked by vertical dashed lines. Right panel, trend of D-dimer in patients 4 and 5. It was noted that D-dimer peaked two times in patient 4 and 3 times in patient 5 (colored arrows). AC, anticoagulation.

Case 5

A 57-year-old male patient with unknown medical history complained of SOB at rest. In the emergency department the patient was hypoxic and ECG showed sinus tachycardia. D-dimer increased from 3612 to 47515 ng/ml in 24 hours and UFH was started (15 units/kg/hour, goal aPTT: 50-70 seconds). The patient developed severe acute kidney injury requiring hemodialysis. Echocardiography showed mild PHTN without RV strain. The patient's hypoxia continued to worsen without chest X-ray changes leading to suspicion of embolic event. Alteplase was administered and anticoagulation was resumed thereafter. The patient remained on MV, however O₂ saturation and D-dimer improved. On the 14th day, a second rise of D-dimer was noted (Fig. 2), and repeated echocardiogram showed worsening of right ventricular systolic pressure (RVSP) to 51 mmHg. On the 17th day, D-dimer rose again (Fig. 2), associated with sudden hypoxia, and need for vasopressors and later the patient developed asystole and died.

Discussion

Thromboembolism is at the forefront of COVID-19 pathophysiology [3]. Silent or evident hypoxia can be a deadly manifestation, and it remains debatable whether hypoxic death is the result of the pulmonary pathology (shunt) or vascular microthrombosis (dead space).

In our patients, we observed that hemodynamic compromise in critical COVID-19 may be related to thrombotic burden that persisted despite anticoagulation, seems to be a later manifestation such that it may be too late for therapeutic options, and rebounds fatally despite thrombolysis.

D-dimer elevation is related to thrombotic burden such as that of the pulmonary circulation [4] and its serial measurements can predict thromboembolic recurrence [5,6]. Mechanism of PE in COVID-19 can be hypoxia-mediated through the release of hypoxia inducible factors, or a result of local viral activation of neutrophils

and release of neutrophils, extracellular traps activating the coagulation cascade to contain the viral spread locally leading to pulmonary micro-thrombi in-situ. Dislodgment can lead to arterial and venous embolism and possible reseeding in vascular endothelium elsewhere despite anticoagulation [5].

Persistent thromboembolism while on systemic anticoagulation occurs in malignancy, anti-phospholipid syndrome (APS), paroxysmal nocturnal dyspnea, vasculitis, JAK-2 positivity, and hyperhomocysteinemia [7]. COVID-19 can cause an APS-like thrombotic state [8], and vasculitis-like endothelial dysfunction. This and the fact that thromboembolism in our report was a late manifestation may explain the lack of benefit of anticoagulation in the recent NIH report.

Importantly, hypercoagulability rebounded fatally despite thrombolysis, suggesting a cyclic pathology which can be explained by rebound viremia or dislodgment of in-situ thrombi. Re-elevation of D-dimer can simply be due to the mechanism of action of the thrombolytic medication itself [9]. In case 4 D-dimer levels remained elevated, however, they did not rise above prior levels, and in case 5, an elevation occurred immediately after alteplase, but a second unexplained re-elevation occurred after which the patient quickly died, both observations cannot be explained solely on the mechanism of action of alteplase. Interestingly, the absolute values of the D-dimer spikes tended to decrease with time which can be due to consumption of the coagulation factors and associated coagulopathy [prolonged prothrombin time, partial prothromboplastin time, and international normalized ratio in patients 2,3, and 4 (Table 1)], which can contribute to the signal of harm noted in the NIH cited clinical trials.

Finally, D-dimer can be elevated in a variety of causes in critically ill patients. However, COVID-19 hypercoagulability can occur de novo or as a part of the inflammation-induced thrombosis [10]. We believe that D-dimer elevation in COVID-19 is more of a manifestation of the latter. In either case, full anticoagulation seems intuitive. However, based on our current and previous observation, this use would only be of benefit if it was early before D-dimer rise [11].

COVID-19 is an extremely heterogeneous disease such that no solid rules can apply to any group of patients and as such, there is no straightforward answer to the question: when is it too late for anticoagulation? Our experience is that what is considered early for some can be late for others. We found that patients with asymptomatic, or mild disease tend to seek medical attention, if any, relatively later than with severe disease. Paradoxically, in the critically ill, earlier hospital admission was associated with worse prognosis, which can be due to more aggressive course in those patients that is still not clearly understood.

We think that COVID-19 involves dynamic interaction of multiple processes rather than snapshots in time and as such a specific treatment that may be beneficial at a specific point of time in a specific patient may not be for another patient or point of time. Therapies ranging from medications such as anti-inflammatory therapies, convalescent plasma, steroids, immunologic therapies, up to respiratory and circulatory support measures such as prone ventilation and extracorporeal membrane oxygenation have shown variable outcomes in COVID-19 patients, some patients benefit while others do not, probably due to the extensive degree of heterogeneity.

With that in mind, anticoagulation may be beneficial in specific patient groups and harmful in others. We have shown that, in critical COVID-19, anticoagulation may not be of benefit in patients with persistently low D-dimer, may be harmful in patients with persistently elevated D-dimer (similar to patients reported), however, may prevent in-hospital death if D-dimer behavior followed a fluctuating (high -low) course [12]. While the mechanisms remain unknown, even in this tight group of critically ill patients, heterogeneity is so extensive that management strategies may not have uniform outcomes.

We acknowledge the recent results of the signal of harm of anticoagulation in patients with critical COVID-19, however, we think that generalization is still premature. In-hospital longitudinal management strategies should be developed to guide the appropriateness and benefit of initiation or avoiding specific therapeutics. An example is D-dimer trend guided anticoagulation. We still do not recommend empiric therapeutic anti-coagulation to those admitted with low D-dimer especially if it remains persistently low (mild course of the disease that may not involve the coagulation cascade) and prophylactic anticoagulation may be sufficient. In patients with high D-dimer that remains persistently high (severe form of the disease that may have exhausted the coagulation cascade leading to DIC like behavior) we think that any form of anticoagulation may be harmful. However, anticoagulation may be of benefit in a special group of patients with severe symptoms that falls into the category of “developing thrombosis” who were admitted with normal D-dimer with the earliest signs of thrombosis or with any elevation of D-dimer.

Conclusions

Hypercoagulability in critical COVID-19 seems to be a late adverse presentation and is cyclic in nature leading to recurrent hypoxic episodes and hemodynamic instability. Intuitive therapeutics such as anticoagulation and thrombolysis at this stage seems not beneficial. Earlier anticoagulation before D-dimer elevation or with the earliest elevation in hypoxic patients may avert hemodynamic compromise, however, further studies are needed to determine the efficacy and safety.

Declaration of Competing Interest

None.

Acknowledgments

None.

References

- [1] Richardson S, Hirsch JS, Narasimhan M, Crawford JM, McGinn T, Davidson KW, the Northwell COVID-19 Research Consortium, Barnaby DP, Becker LB, Chelico JD, Cohen SL, Cookingham J, Coppa K, Diefenbach MA, Dominello AJ, Duer-Hefele J, et al. Presenting Characteristics, Comorbidities, and Outcomes Among 5700 Patients Hospitalized With COVID-19 in the New York City Area. *JAMA* 2020;323(20):2052–9.
- [2] NIH ACTIV Trial of blood thinners pauses enrollment of critically ill COVID-19 patients 2020 [Available from: <https://www.nih.gov/news-events/news-releases/nih-activ-trial-blood-thinners-pauses-enrollment-critically-ill-covid-19-patients>. 2020.
- [3] Ji HL, Zhao R, Matalon S, Matthay MA. Elevated Plasmin(ogen) as a Common Risk Factor for COVID-19 Susceptibility. *Physiol Rev* 2020;100(3):1065–75.
- [4] Keller K, Beule J, Balzer JO, Dippold W. D-dimer and thrombus burden in acute pulmonary embolism. *Am J Emerg Med* 2018;36(9):1613–18.
- [5] Ebersole JL, Novak MJ, Orraca L, Martinez-Gonzalez J, Kirakodu S, Chen KC, Stromberg A, Gonzalez OA. Hypoxia-inducible transcription factors, HIF1A and HIF2A, increase in aging mucosal tissues. *Immunology* 2018;154(3):452–64.
- [6] Eichinger S, Heinze G, Kyrle PA. D-dimer levels over time and the risk of recurrent venous thromboembolism: an update of the Vienna prediction model. *J Am Heart Assoc* 2014;3(1):e000467 p.
- [7] Thachil J. Recurrent venous thromboembolism while on anticoagulant therapy. *Blood reviews* 2012;26(4):175–81.
- [8] Zhang Y, Xiao M, Zhang S, Xia P, Cao W, Jiang W, Chen H, Ding X, Zhao H, Zhang H, Wang C, Zhao J, Sun X, Tian R, Wu W, et al. Coagulopathy and Antiphospholipid Antibodies in Patients with Covid-19. *N Engl J Med* 2020.
- [9] Knecht MF, Heinrich F, Spanuth E. Evaluation of plasma D-dimer in the diagnosis and in the course of fibrinolytic therapy of deep vein thrombosis and pulmonary embolism. *Thromb Res* 1992;67(2):213–20.
- [10] Aksu K, Donmez A, Keser G. Inflammation-induced thrombosis: mechanisms, disease associations and management. *Curr Pharm Des* 2012;18(11):1478–93.
- [11] Ronderos Botero DM, Omar AMS, Sun HK, Mantri N, Fortuzi K, Choi Y, Adrish M, Nicu M, Bella JN, Chilimuri S. COVID-19 in the Healthy Patient Population: Demographic and Clinical Phenotypic Characterization and Predictors of In-Hospital Outcomes. *Arterioscler Thromb Vasc Biol* 2020;40(11):2764–75.
- [12] Ronderos D, Omar A, Haider SW, Rehmani A, Arenas AG, Uralpu K, Nicu M, Bella J, Chilimuri S. D-DIMER TRENDS IN PATIENTS HOSPITALIZED WITH COVID-19: PATTERNS AND IN-HOSPITAL PROGNOSTIC SIGNIFICANCE. *Journal of the American College of Cardiology*, 2021;77(18):3031. doi:10.1016/S0735-1097(21)04386-2.