

# Intramuscular hemangioma within the biceps brachii causing the limitations of elbow extension and forearm pronation

## A case report

Yang Liu, MD, Ruijun Li, MD, PhD, Zhigang Liu, MD, PhD, Shuang Wang, MD, Lajin Lu, MD, PhD\*

### Abstract

**Rationale:** Intramuscular hemangiomas are rare benign vascular neoplasms, merely accounting for 0.8% of all hemangiomas. Moreover, there are few case reports of intramuscular hemangiomas in the upper extremities.

**Patient concerns:** A 24-year-old male patient presented with a 5-year history of intermittent pain of the right elbow joint. He had observed a swelling of the right cubital fossa over the past 2 years, leading to the limitations of elbow extension and forearm pronation.

**Diagnosis:** The patient was diagnosed with intramuscular hemangioma of the biceps brachii.

**Interventions:** Surgical excision of the tumor was performed for this patient and postoperative early functional exercises were permitted.

**Outcomes:** The movements of the right elbow and forearm reached the normal range of motion at 5 weeks after surgery. There was no evidence of recurrence during the 5-month follow-up.

**Lessons:** Optimal management of intramuscular hemangioma is critical, including precise evaluation, good microsurgical technique and early functional exercises, which may result in a satisfying outcome.

**Abbreviation:** MRI = magnetic resonance imaging.

**Keywords:** biceps brachii, functional exercises, intramuscular hemangioma, limitation of elbow extension, surgical excision

## 1. Introduction

Intramuscular hemangiomas are rare benign vascular neoplasms of the muscles, making up merely 0.8% of all hemangiomas.<sup>[1]</sup> It is remarkable that there are few case reports of intramuscular hemangiomas in the upper extremities. They attract much attention because of their rarity and their invariably confusing clinical presentation. Intramuscular hemangiomas commonly present in the early adulthood, and are more frequently found in females.<sup>[2]</sup> Because most patients have nonspecific clinical symptoms, the early diagnosis of intramuscular hemangioma is often difficult and can be easily missed.<sup>[3,4]</sup> For the management of this tumor, surgical excision remains the most preferred treatment.

Editor: N/A.

The authors have no funding and conflicts of interest to disclose.

Department of Hand and Foot Surgery, The First Hospital of Jilin University, Changchun, Jilin, China.

\* Correspondence: Lajin Lu, Department of Hand and Foot Surgery, The First Hospital of Jilin University, Changchun, Jilin, 130021, China (e-mail: swk0189@163.com).

Copyright © 2019 the Author(s). Published by Wolters Kluwer Health, Inc. This is an open access article distributed under the terms of the Creative Commons Attribution-Non Commercial License 4.0 (CCBY-NC), where it is permissible to download, share, remix, transform, and buildup the work provided it is properly cited. The work cannot be used commercially without permission from the journal.

Medicine (2019) 98:5(e14343)

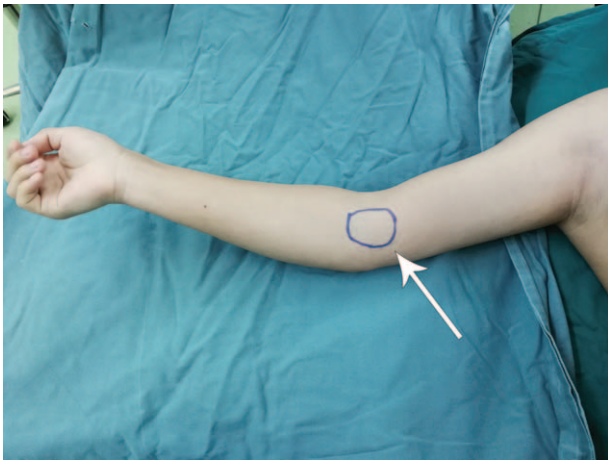
Received: 8 October 2018 / Received in final form: 3 January 2019 / Accepted: 9 January 2019

<http://dx.doi.org/10.1097/MD.0000000000014343>

To our knowledge, only one case of intramuscular hemangioma of the biceps brachii has been reported in the English language literature.<sup>[5]</sup> However, this case did not give rise to significant functional impairment. Here, we reported a rare case of intramuscular hemangioma of the biceps brachii with significant functional limitations of elbow extension and forearm pronation. The surgical therapy was performed for this patient, and the final histopathology diagnosis was a mixed-type intramuscular hemangioma.

## 2. Case report

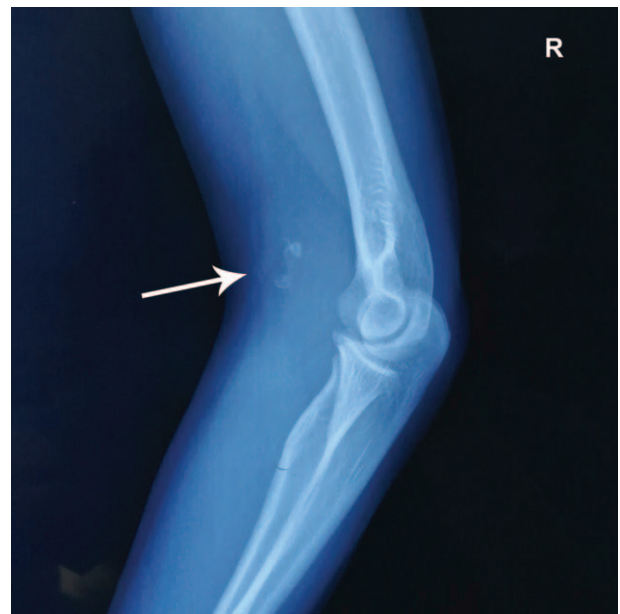
Our study was approved by the Ethics Committee of the First Hospital of Jilin University (the ethical approval number: 2018-357) and written informed consent was also obtained from the patient. A 24-year-old male patient presented with a 5-year history of intermittent pain of the flexor aspect of the right elbow joint. He had observed a swelling of the right cubital fossa over the past 2 years, leading to the limitations of elbow extension and forearm pronation. There was no history of significant trauma involving his right elbow. Physical examination showed a painful intramuscular mass measuring approximately 40 mm × 20 mm was located proximal to the right cubital fossa (Fig. 1). No bruit or thrill could be heard on auscultation of the swelling. Moreover, there was no local heat or redness on the overlying skin. The patient complained of the limitations of elbow extension and forearm pronation, but his right elbow flexion and forearm supination was observed in the normal range of motion. Conventional radiography of the right elbow showed a soft-tissue swelling with multiple diffuse phleboliths, seeming to be attached to the distal region of biceps brachii (Fig. 2). The



**Figure 1.** Preoperative photograph. A painful intramuscular mass was located proximal to the right cubital fossa (white arrow, the tumor).

presence of phleboliths was supposed to an indication of possible hemangioma. Besides, color Doppler ultrasound findings indicated a hypochoic mass, and there were some dot-like and linear blood flow signals in this tumor. The diagnosis of this patient was an intramuscular hemangioma of biceps brachii based on all the results above.

Surgical excision was performed via flexor approach with curvilinear incision under general anesthesia. Skin incision and delicate dissection were conducted to achieve complete resection of intramuscular hemangioma and to preserve the surrounding functional neurovascular structures (Fig. 3A). A 42 mm × 20 mm × 15 mm pathologic mass was found within the distal muscle belly of biceps brachii and to extend to the biceps brachii tendon. On intraoperative observation, the mass was a spongy and angiomatous tumor with relatively ill-defined margins. After resection of the entire abnormal looking mass, the elbow extension could reach the normal range of motion without further releasing the elbow (Fig. 3B). A short elbow plaster was applied and maintained for 2 weeks after operation. Histopathology of the excised tumor demonstrated that the mass was a venous-cavernous mixed type of intramuscular hemangioma.

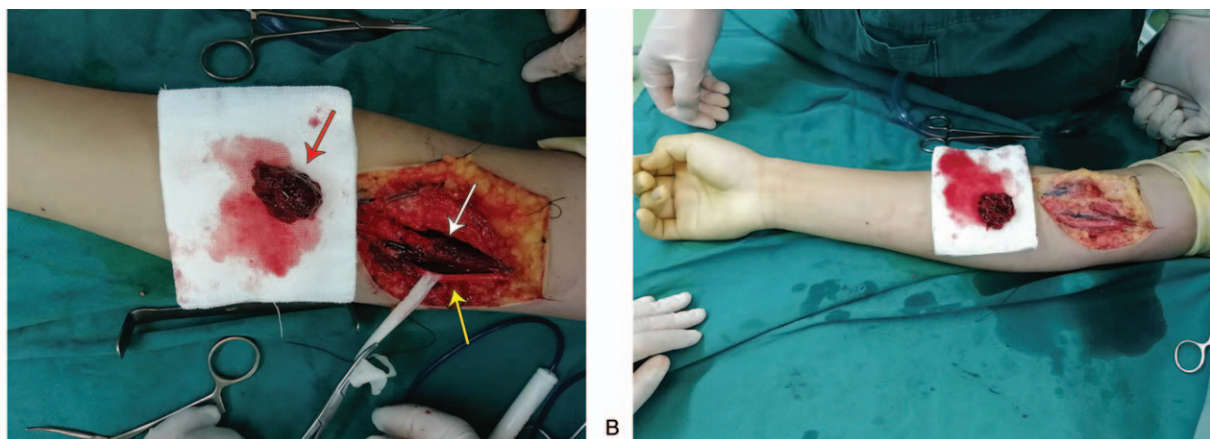


**Figure 2.** Preoperative plain radiograph of the right elbow region. A soft-tissue swelling with multiple diffuse phleboliths was observed at the distal region of biceps brachii (white arrow, the phleboliths).

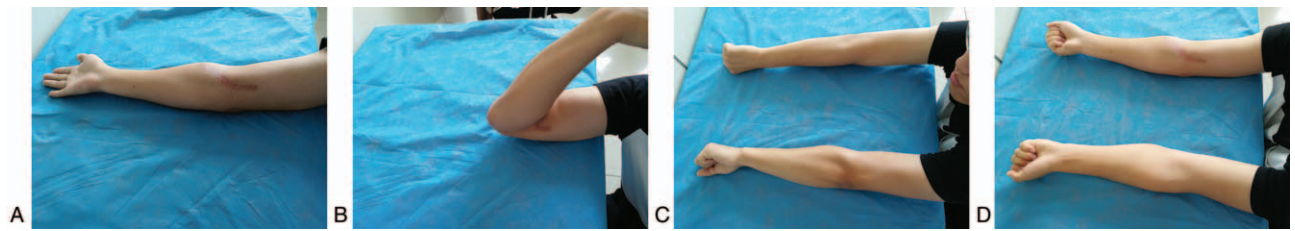
After removing the plaster at 2 weeks after surgery, the patient was permitted to initiate functional exercises of elbow with the help of physical therapy. As shown in Figure 4, all functional limitations of the right elbow and forearm were resolved at 5 weeks after surgery. The patient achieved full elbow extension, and the range of motion of pronation and supination of the right forearm was similar with that of the contralateral side. There was no evidence of recurrence during the 5-month follow-up.

### 3. Discussion

Intramuscular hemangioma, a relatively rare vascular tumor, accounts for less than 1% of all hemangiomas and usually occurs in the lower extremity, followed by the upper extremity.<sup>[1,6–8]</sup> The definite etiology of intramuscular hemangiomas remains



**Figure 3.** Intraoperative view of the resected mass. (A) A spongy and angiomatous tumor which involved the distal muscle belly and tendon of biceps brachii was completely excised (red arrow, the tumor; white arrow, the distal muscle belly of biceps brachii; yellow arrow, the median nerve). (B) The elbow extension could reach the normal range of motion after resection of the tumor.



**Figure 4.** The functional recovery at 5 weeks after surgery. The patient achieved the normal range of motion of elbow extension (A) and flexion (B), and the range of motion of pronation (C) and supination (D) of the right forearm was similar with that of the contralateral side.

unclear; their appearance or initial symptoms might be involved in minor trauma or excessive muscle contraction, but most investigators believe that these benign tumors are congenital in origin.<sup>[5,9,10]</sup> Most of them are observed in childhood or adolescence, and over 85% of the reported cases presented in the first 3 decades of life. Like the patient in this study, the symptoms of intramuscular hemangioma occurred before the age of 30.

Intramuscular hemangioma occurs as a slowly enlarging mass, and pain is a major symptom in approximately 60% of cases.<sup>[11]</sup> Features characteristic of hemangiomas like bruit, pulsation, or thrill are generally absent, which always cause the intramuscular hemangioma to be clinically misdiagnosed.<sup>[12]</sup> The intramuscular hemangioma can go undetected for a very long time until sudden growth leads to pain or functional impairment, such as deformity and limitation of movement. Though pain was the initial symptom of the current patient, it was significant limitations of elbow movement that attracted his attention. Moreover, we speculated that the intramuscular hemangioma might impair the elbow motor function due to the occurrence of extensive muscle involvement.

Histologically, intramuscular hemangiomas can be classified into 4 types on the basis of the vessel size: cavernous, capillary, venous, and mixed.<sup>[13]</sup> The cavernous and mixed subtypes are commonly related to a longer history of symptoms. The present case was of the mixed subtype, and a 5-year history of pain was observed in this patient. Whenever a soft-tissue mass is encountered within the skeletal muscle tissue in young patients, the possibility of hemangioma should be considered in the differential diagnosis.<sup>[14]</sup> Plain radiographs may show an area of increased soft-tissue density suggestive of a mass. In addition, the presence of phleboliths within a soft-tissue mass is specific for the diagnosis of hemangiomas though they are only present in 25% cases.<sup>[15]</sup> On ultrasound examination, the intramuscular hemangioma usually presents as a hyperechogenic structure,<sup>[16]</sup> but a hypoechoic mass was noted in our case. Besides, there were some dot-like and linear blood flow signals using Doppler flow imaging in this patient, though no Doppler signals was detected in the most cases due to the low blood flow inside hemangioma. To further evaluate and diagnose the intramuscular hemangioma, magnetic resonance imaging (MRI) may be the most important imaging method.<sup>[17]</sup> However, because of the low accessibility of MRI, ultrasonography might become a more important imaging tool to evaluate and monitor the intramuscular hemangioma before surgery. The clinical diagnosis of this patient was intramuscular hemangioma according to the symptoms, physical signs, plain radiographs, and ultrasound results.

The individualized treatment should be advocated in the management of intramuscular hemangioma according to the tumor location, size, infiltration extent, anatomical accessibility,

and cosmetic and functional considerations.<sup>[18,19]</sup> Conservative treatment is commonly recommended as the first-selected therapy, especially in situations where patient does not agree with the surgical excision or surgery is not recommended. Simple observation, injection of sclerosing agents and embolization are common conservative treatment options. The treatment failure rate of simple observation would increase over time and achieved 59% at 10-year follow-up;<sup>[20]</sup> sclerotherapy was a relatively simple and effective method, and severe complications were rare;<sup>[21]</sup> some authors believed that embolization was inadequate technique unless combined with surgery.<sup>[22]</sup> However, the surgical therapy remains the optimal management when patients present specific symptoms, with intractable pain, acceleration of tumor growth, cosmetic deformity, functional impairment, and suspicion of malignancy.<sup>[2]</sup>

Because significant functional limitations of the elbow occurred in the current case, the total resection of the tumor was performed along with a cuff of the surrounding muscle. Intraoperatively, the elbow extension could reach the normal range of motion after removing the tumor. Therefore, surgical releasing of the elbow was not essential for this patient. Moreover, the patient was permitted to initiate functional excises of the elbow with the help of physical therapy at 2 weeks after surgery. Fortunately, the functional limitations of elbow extension and forearm pronation were resolved after only 3-weeks therapeutic exercises. We believe that there are 2 major reasons for the excellent postoperative results. First, the en bloc resection of intramuscular hemangioma was achieved during the surgery,<sup>[23]</sup> and meanwhile the resolution of functional limitations was also confirmed. Secondly, relatively early initiation of rehabilitation resulted in a good recovery. The intramuscular hemangioma of biceps brachii was rarely reported in the medical literature. It is noteworthy that the tumor of our case caused the significant limitations of elbow extension and forearm pronation, which was first reported to the best of our knowledge. Optimal management of intramuscular hemangioma is critical, including precise evaluation, good microsurgical technique and early functional exercises, which may result in a satisfying outcome.

#### Author contributions

**Conceptualization:** Yang Liu, Laijin Lu.

**Formal analysis:** Ruijun Li.

**Investigation:** Shuang Wang.

**Project administration:** Zhigang Liu.

**Resources:** Yang Liu, Ruijun Li.

**Software:** Shuang Wang.

**Supervision:** Zhigang Liu.

**Writing – original draft:** Yang Liu.

**Writing – review & editing:** Laijin Lu.

## References

- [1] Cohen AJ, Youkey JR, Clagett GP, et al. Intramuscular hemangioma. *JAMA* 1983;249:2680–2.
- [2] Wild AT, Raab P, Krauspe R. Hemangioma of skeletal muscle. *Arch Orthop Trauma Surg* 2000;120:139–43.
- [3] Enzinger FM, Weiss SW. Benign tumors and tumorlike lesions of blood vessels. 3rd ed. Mosby, St Louis: *Soft Tissue Tumors*; 1995:579–626.
- [4] Ramon F. *Tumors and Tumor-like Lesions of Blood Vessels*. Berlin, Heidelberg: Springer; 2001.
- [5] Fergusson IL. Haemangiomas of skeletal muscle. *Br J Surg* 1972;59:634–7.
- [6] Allen PW, Enzinger FM. Hemangioma of skeletal muscle. An analysis of 89 cases. *Cancer* 1972;29:8–22.
- [7] Ciurea ME, Bondari S, Stoica LE, et al. Role of MRI in the diagnosis and evaluation of cavernous hemangioma of the arm. *J Med Life* 2014;7:46–50.
- [8] Ly JQ, Sanders TG, Sandiego JW. Hemangioma of the triceps muscle. *AJR Am J Roentgenol* 2003;181:544.
- [9] Chaudhary N, Jain A, Gudwani S, et al. Intramuscular haemangioma of head and neck region. *J Laryngol Otol* 1998;112:1199–201.
- [10] Ciurea ME, Ciurea RN, Bărbulescu AL, et al. Intramuscular hemangioma of the arm: ultrasonography and pathology features. *Rom J Morphol Embryol* 2016;57:521–4.
- [11] Muramatsu K, Ihara K, Tani Y, et al. Intramuscular hemangioma of the upper extremity in infants and children. *J Pediatr Orthop* 2008;28:387–90.
- [12] Sunil TM. Intramuscular hemangioma complicated by a Volkmann's like contracture of the forearm muscles. *Indian Pediatr* 2004;41:270–3.
- [13] Jeong E, Kim HS. Intramuscular hemangioma of the pronator quadratus muscle of forearm. *J Hand Surg Asian Pac Vol* 2016;21:262–5.
- [14] Nurlizams I, Kenalims MS, Sani A. Intramuscular haemangioma in the head and neck. *Med J Malaysia* 2007;62:409–10.
- [15] Morris SJ, Adams H. Case report: paediatric intramuscular haemangiomas—don't overlook the phlebolith!. *Br J Radiol* 1995;68:208–11.
- [16] Derchi LE, Balconi G, De FL, et al. Sonographic appearances of hemangiomas of skeletal muscle. *J Ultrasound Med* 1989;8:263–7.
- [17] Kayias EH, Drosos GI, Kazakos KI, et al. Intramuscular haemangioma of the extensor pollicis brevis muscle with periosteal reaction of the radius: a case report and review of the literature. *J Int Med Res* 2007;35:724–30.
- [18] Uslu M, Beşir H, Turan H, et al. Two different treatment options for intramuscular plantar hemangioma: surgery versus percutaneous sclerotherapy. *J Foot Ankle Surg* 2014;53:759–62.
- [19] Lu H, Chen Q, Yang H, et al. Aggressive intramuscular hemangiomas in the upper extremity. *Medicine* 2017;96:e5939.
- [20] Bella GP, Manivel JC, Thompson RC Jr, et al. Intramuscular hemangioma: recurrence risk related to surgical margins. *Clin Orthop Relat Res* 2007;459:186–91.
- [21] Winter H, Dräger E, Sterry W. Sclerotherapy for treatment of hemangiomas. *Dermatol Surg* 2000;26:105–8.
- [22] Calişaneller T, Ozdemir O, Yildirim E, et al. Cavernous hemangioma of temporalis muscle: report of a case and review of the literature. *Turk Neurosurg* 2007;17:33–6.
- [23] Scozzari G, Reddavid R, Conti L, et al. Intractable pain due to rectus abdominis intramuscular haemangioma. *Hernia* 2014;18:591–5.