

Case Report

Neurilemmoma of Deep Peroneal Nerve Sensory Branch : Thermographic Findings with Compression Test

Seung Jun Ryu, M.D.,¹ Ho Yeol Zhang, M.D., Ph.D.²

Department of Neurosurgery,¹ Severance Hospital, Yonsei University College of Medicine, Seoul, Korea

Department of Neurosurgery,² National Health Insurance Corporation Ilsan Hospital, Yonsei University College of Medicine, Goyang, Korea

We report a case of neurilemmoma of deep peroneal nerve sensory branch that triggered sensory change with compression test on lower extremity. After resection of tumor, there are evoked thermal changes on pre- and post-operative infrared (IR) thermographic images. A 52-year-old female presented with low back pain, sciatica, and sensory change on the dorsal side of the right foot and big toe that has lasted for 9 months. She also presented with right tibial mass sized 1.2 cm by 1.4 cm. Ultrasonographic imaging revealed a peripheral nerve sheath tumor arising from the peroneal nerve. IR thermographic image showed hyperthermia when the neurilemmoma induced sensory change with compression test on the fibular area, dorsum of foot, and big toe. After surgery, the symptoms and thermographic changes were relieved and disappeared. The clinical, surgical, radiographic, and thermographic perspectives regarding this case are discussed.

Key Words : Neurilemmoma · Peroneal nerve · Nerve compression test · Infrared thermography · Sciatica.

INTRODUCTION

Neurilemmoma is defined as “a neoplasm that arises from Schwann cells of the cranial, peripheral, and autonomic nerves”. Clinically, these tumors may present as cranial neuropathy, abdominal or soft tissue mass, intracranial lesion, or spinal cord compression. The terminology regarding neurilemmoma may be confusing with neurinoma, neurocytoma, peripheral glioma, perineurial fibroblastoma and schwannoma. Today, neurilemmoma and schwannoma are the most frequently used terms in the literature¹¹. They are the most common type of peripheral nerve sheath tumor (PNST), but they are rarely found in deep peroneal nerve sensory branch^{9,12,16,17}. We report an interesting case of neurilemmoma of deep peroneal nerve sensory branch that triggered sensory change with compression test on lower leg and induced changes on pre- and post-operative infrared (IR) thermographic images. IR thermography was taken at 23°C. It is the first to document a case of thermal change arising from neurilemmoma with compression test. The clinical courses and findings of this case are presented and discussed.

CASE REPORT

A 52-year-old woman had complained of pain at lower back and right leg for 9 months. A local clinician made a diagnosis of herniated lumbar disc (HLD) and performed a pain block on the patient's spine. The symptoms persisted, however, and a mass sized approximately 2 cm by 2 cm was palpated on the lateral side of leg, between right side of tibia and fibula, about 3.5 cm proximal to lateral malleolus. She was subsequently referred to our hospital.

Upon visiting our hospital, she initially presented with sensory change on the dorsal side of the right foot, particularly the big toe. The mass was palpable and soft. Percussion of the mass caused severe pain at fibular area, dorsal side of the right foot, and the big toe. No neurologic signs were examined except for sensory change with compression test and mild numbness at the fibula and dorsal area of foot.

Ultrasonography of the lower extremity discovered an oval-shaped mass sized 1.42 cm by 0.77 cm by 1.12 cm, considered as probably benign PNST arising from the right deep peroneal nerve sensory branch (Fig. 1).

After 1 month, the low back pain was relieved by medication,

• Received : February 21, 2014 • Revised : July 15, 2014 • Accepted : August 13, 2014

• Address for reprints : Ho Yeol Zhang, M.D., Ph.D.

Department of Neurosurgery, National Health Insurance Corporation Ilsan Hospital, Yonsei University College of Medicine, 100 Ilsan-ro, Ilsandong-gu, Goyang 10444, Korea

Tel : +82-31-900-0580, Fax : +82-31-900-0588, E-mail : hoyeolzhang@gmail.com

• This is an Open Access article distributed under the terms of the Creative Commons Attribution Non-Commercial License (<http://creativecommons.org/licenses/by-nc/3.0>) which permits unrestricted non-commercial use, distribution, and reproduction in any medium, provided the original work is properly cited.

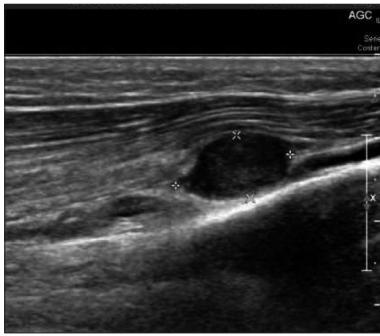

Fig. 1. Ultrasonographic image of the right leg suggesting approximately 1.42×0.77×1.12 cm sized, probably benign peripheral nerve sheath tumor (PNST) arising from right deep peroneal nerve sensory branch.

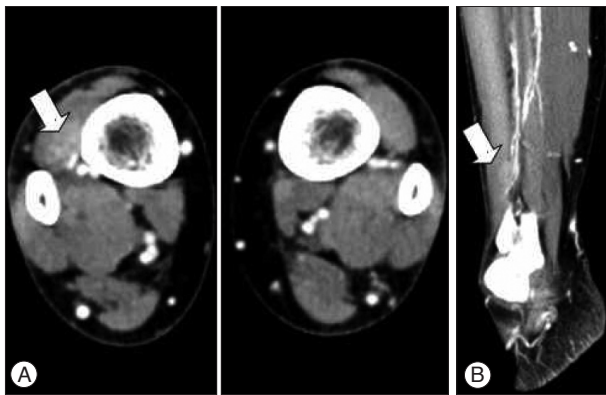


Fig. 2. Computed tomography (CT) scan with contrast. An axial (A) and sagittal (B) cut of CT scan with contrast shows a well-defined, enhanced lesion located near to the deep peroneal nerve sensory branch. A soft tissue mass, within the sensory branch of right deep peroneal nerve, was enhanced by contrast material.

but right leg pain remained, and an excision of the mass was planned.

A computed tomography (CT) scan with contrast of the both lower extremities was taken, which revealed a soft tissue mass within the sensory branch of right deep peroneal nerve (Fig. 2).

IR thermography of both legs was performed. Temperature was 31.08°C at fibular area, 31.06°C at dorsal area. When the palpable mass was compressed, the patient complained of sensory change, severe pain on fibula (upward from mass to below the knee) and dorsal area of foot, especially on fibular area and big toe. At that time, a thermal change was found on IR thermography, 31.83°C at fibular area, 31.45°C at dorsal area : specifically, the temperature of the fibular area was elevated by 0.75°C and dorsal area was decreased by 0.15°C (Fig. 3) (Table 1). It is similar to area of pain, sensory change with compression test.

A vertical skin incision was made under spinal anesthesia, and sharp and blunt dissection was used to expose the mass. An encapsulated, solitary soft tumor was found on deep peroneal nerve sensory branch. Gross identification demonstrated a mass sized 1.4 cm by 1.2 cm and shaped like a pigeon egg (Fig. 4). The tumor capsule was incised parallel to the running direction of nerve, and totally enucleated, with special attention paid to

deep peroneal nerve sensory branch in order to avoid damaging the nerve. The wound was sufficiently irrigated, and compressive sterile dressing was applied. The diagnosis of schwannoma was confirmed by pathologist.

The patient complained of mild sensory change on dorsum of foot, which was relieved partially over 1 month and completely over 2 months of period. IR thermography of both legs was performed at one month after operation. Temperature was 31.43°C at fibular area, 31.40°C at dorsal area. When the excision site was compressed, temperature was 31.49°C at fibular area, 31.32°C at dorsal area (Table 1). There is no severe sensory change, except mild op wound pain, and thermal elevation like pre-op status. The temperatures at dorsal foot area do not show any significant difference in pre- and post-op status.

DISCUSSION

Neurilemmoma, also known as schwannoma, is a common benign tumor of the peripheral nerve^{11,19}. Neurilemmomas usually arise at the intracranial cavity but may be found on other sites of the body. However, its involvement in the leg is unusual⁵. Odom et al.¹⁴ reviewed previous literature and reported that schwannoma of the leg comprise about 7.09% of all cases.

The initial impression of our case was herniated lumbar disc (HLD), which was ultimately found to be incorrect. There has been a previous case where a patient with schwannoma of the peroneal nerve presented with sciatica, which was initially misdiagnosed as HLD¹³. This patient's perceived sciatic pain or L5 dermatomal pain could have lead to the misdiagnosis. In our case, the patient underwent several sessions of pain block in a local hospital, and there was no clear sign of improvement of low back pain.

Causes of nerve irritational symptom include HLD, ischialgia, piriform muscle syndrome, polyneuropathy, peroneal nerve trauma, pressure upon peroneal nerve due to wearing immobilization, fracture or expansive process in the region of tibial head, lipoma, ganglioma, synovial cysts from popliteal region, anatomic variability, and others¹⁴, and differential diagnosis should be made after considering the innervation of the deep peroneal nerve.

The diagnostic modalities available for the differential diagnosis include CT scan, ultrasonography, magnetic resonance imaging, and electromyography, among other^{3,14,20}. Simple radiographs are not of much value when a patient presents with neurologic symptoms. Ultrasonography has been considered as a useful screening tool³, but it is difficult to perform such costly examination from the onset.

Our department has used IR thermography examination as one useful alternative method. This examination measures the change in temperature radiating from the body resulting from alteration of subcutaneous capillary blood flow. Thus, for the precise examination, it is important to maintain a constant temperature and environment in thermography laboratory. The ther-

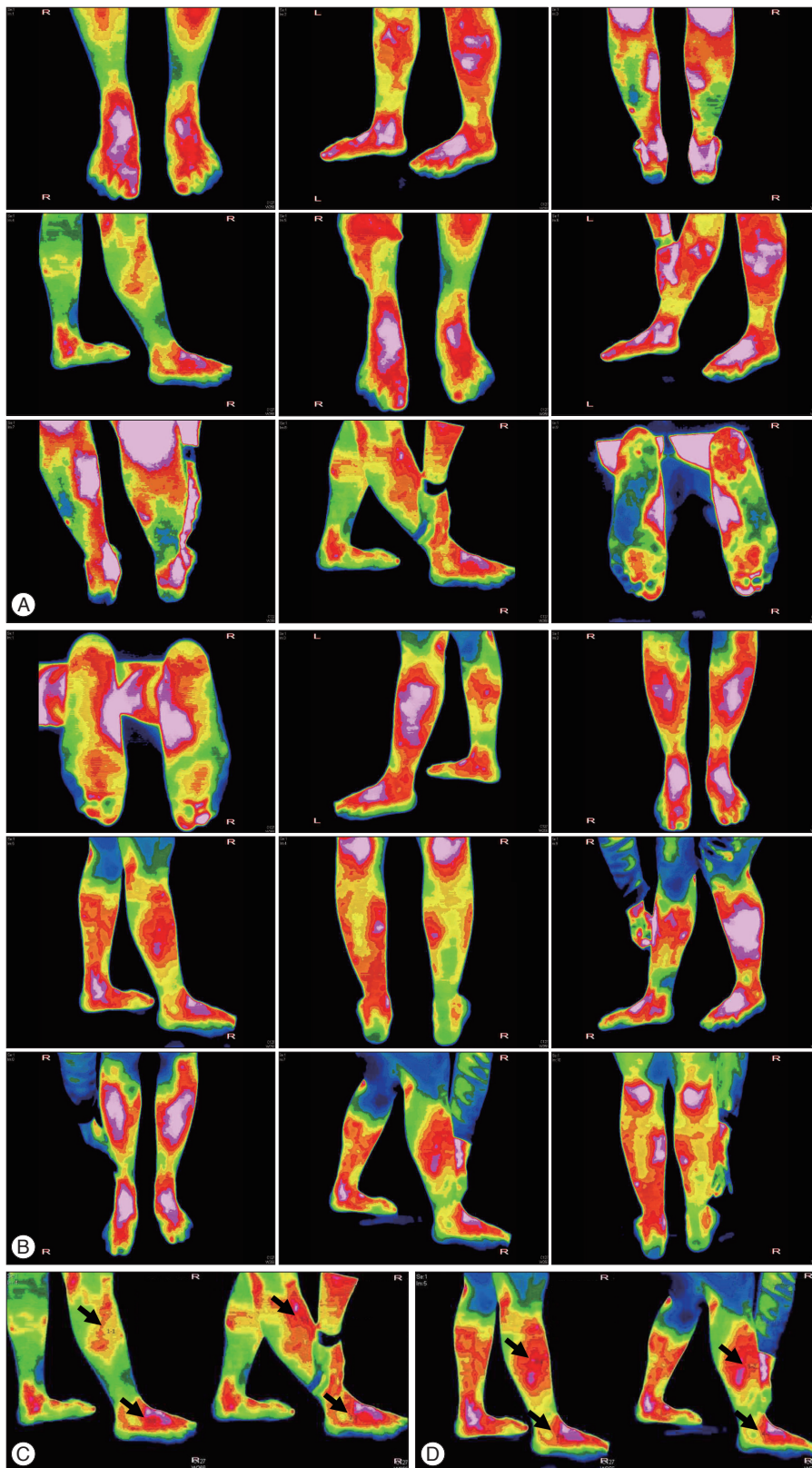


Fig. 3. IR thermography Images show thermal changes in pre-op (A and C) and post-op (B and D) as well as before and after compression of mass (thermography was taken at 23°C). A : Preop thermography (2013 December 19). B : Post operation date 1 month thermography (2014 January 20). C : Pre-op image 4, 8. IR thermography taken before operation. Right leg lateral side. Resting state and compression on subcutaneous mass. When the palpable mass was compressed, temperature of the fibular area was elevated by 0.75°C. D : Pre-op image 4, 8, IR thermography 1 month after operation. Right leg lateral side. There is no definite thermal changes between resting and compression state.

mography result according to changes in the environment can cause errors. This was first used by Lawson in 1956 for the diagnosis of breast cancer⁸⁾ and is now being used as a novel method objectively quantifying the subjective sense of pain²⁾.

In order to minimize the errors, our thermography lab maintains temperature at 23°C, we use difference between temperature of before and after compression of the lesion. The IR thermography demonstrated thermographic changes when the neurilemmoma induced sensory change with compression test on the fibular area, dorsal side of foot, and the big toe. The area of thermographic change was found to be related to the path of deep peroneal nerve sensory branch.

In HLD accompanied by leg pain, hyperthermic regions resulting from local dilation arise on the posterior lumbar skin that correlates to anatomic site of the compressed nerve due to antidromic stimulation. The information is transmitted to the recurrent meningeal nerve, or sinuvertebral nerve, located at the spinal cord, and consequently, the autonomic output caused by the reflex arc leads to local vasoconstriction and hypothermia^{2,8)}.

In our case, however, there was greater blood flow at the pain site, which further increased upon inducing sensory change with compression test, resulting in hyperthermia (Fig. 3). Such results obtained from IR thermography was of great assistance in diagnosing the disease.

While the degree of pain intensified in accordance with compression test, vasodilation and increased temperature of the skin was observed, rather than hypothermia and vasoconstriction caused by sympathetic nerves as seen in HLD. This may be explained by autonomic dysfunction following nerve injury (in this case, tumor growth on peroneal nerve sensory branch), including changes of the sympathetic tone and norepinephrine synthesis¹⁾.

Sympathetic nervous system usually induces vasoconstriction by secretion of adrenaline, but sometimes, the cholinergic fibers within the sympathetic nerves releases acetylcholine, which

may cause vasodilation and diaphoresis^{10,15)}. The former may be more significant in HLD, whereas in our case, the latter may have been the stronger factor.

Vasodilation resulting from the stimulation of the dorsal root, which is thought to be a separate entity from sympathetic nervous system, has been discovered. This arises from spinal gray matters, and the preganglionic fibers passes the dorsal root and dorsal root ganglions, changing postganglionic fiber and ultimately, peripheral ganglions and skin temperature²¹⁾. Furthermore, parasympathetic nerves are also involved in regulation of skin temperature, which may be a clue explaining the rise in temperature at fibular area and cutaneous blood flow following sensory change with compression test.

Interestingly the temperatures at dorsal foot area do not show any significant changes and were elevated more than fibular area.

The study performed by Zhang et al.²¹⁾ presents thermal data of the upper body measured indoor at 23°C. In this case, the mean temperatures of upper body sectors are distributed from 29°C to 32°C. This study demonstrates lower extremity temperature of our case, being maintained at 31.08°C to 31.83°C regardless of compression. In other words, our case of IR thermography data follows the temperature distribution pattern obtained at 23°C indoor.

The magnitude temperature of difference between left and right side of the same anatomic location was 0.1, 0.2, 0.3, and 0.4°C regardless of indoor temperature (20°C or 23°C), in both 1995 and 1999 study²¹⁾.

Therefore, the thermal symmetry of the superficial skin is maintained in our case. The elevated temperature of the foot dorsum compared to the fibula before the surgery (Table 1) may be attributed to tumor effect. The situation where the temperature of dorsum was 0.58°C higher instead of 0.3°C was determined as abnormal⁶⁾.

This is also well demonstrated in Uematsu, where carpal tunnel syndrome was correlated with electromyography (EMG)¹⁸⁾. The degree of median nerve lesion was classified as mild, moderate, or severe according to EMG findings, and mild and moderate compression group demonstrated thermal elevation while in severe compression group, both thermal elevation and depression was observed. In other words, palmar temperature rises as the severity of median nerve compression increases and then drops as thenar muscle atrophy develops as the result of chronic

Table 1. Temperatures of marked areas in IR thermography

Measure (°C)	Pre-op		Post-op 1month	
	1-fibular	2-dorsal	3-fibular	4-dorsal
Before comp	31.08	31.60	31.43	31.40
After comp	31.83	31.45	31.49	31.32
Δ T	+0.75	-0.15	+0.06	-0.08

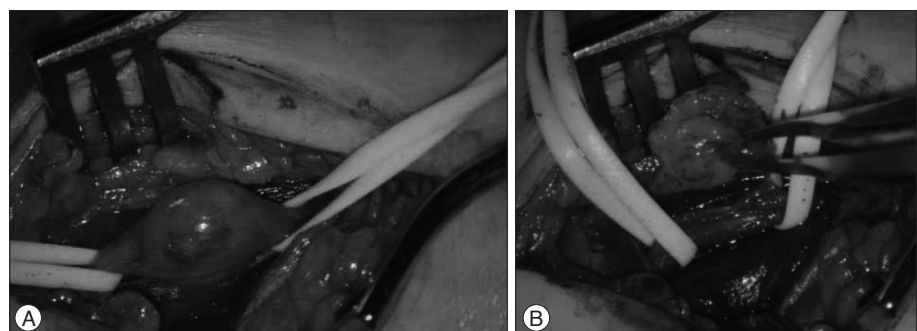


Fig. 4. An intraoperative photograph of the mass. A : The tumor mass, shaped like a pigeon egg, arising from sensory branch of the right deep peroneal nerve. B : Excised tumor mass and preserved nerve.

severe carpal tunnel syndrome.

Since peripheral nerves include sympathetic nerves involved in vasoconstriction of the anatomic area, the tumor located at sensory branch of the deep peroneal nerve may have suppressed the vasoconstriction of the surround area, resulting in vasodilation and the following hyperthermia of the right dorsum and toe compared to the left side.

There are numerous other factors influencing skin temperature, including emotional stress and depression, which can affect autonomic dysfunction⁴⁾, as well as the circadian rhythm, which results in diurnal variation of body temperature⁷⁾.

IR thermographic change seems to be specific or non-specific. It shows temperature change according to autonomic nervous system tone or change in circulation caused by various etiologies. Therefore, although it shows temperature changes, it does not clarify what the nature of the causative lesion is. Considering these variables, future studies and analyses controlling for these factors may be needed.

CONCLUSION

When the mass, PNST, was compressed, there is a IR thermographic-thermal elevation at PNST proximal part with subjective pain. Mass excision relieves the patient's symptom, and there is no definite thermal change at post-operative IR thermography. Those are unique findings of this case.

Differential diagnosis of PNST from HLD is to be made first by clinical findings. However, tumors that occurred in peroneal nerve have a similar symptoms with HLD, or symptoms caused by nerve irritation or compression. Although, IR thermographic findings are not specific, as discussed previously, there are differences in IR thermography, and it is useful and supportive in our case.

Therefore, there are possible usefulness of IR thermography in evaluating symptoms caused by nerve irritation or compression, and possible limitation from various etiologies. Further study will be needed to clarify which range of temperature change can be interpreted as significant result and to get specific result without numerous other factors influencing skin temperature.

References

1. Byun JH, Hong JT, Son BC, Lee SW : Schwannoma of the superficial peroneal nerve presenting as sciatica. *J Korean Neurosurg Soc* 38 : 306-308, 2005

2. Cho YE, Kim YS, Zhang HY : Clinical efficacy of digital infrared thermographic imaging in multiple lumbar disc herniations. *J Korean Neurosurg Soc* 27 : 237-245, 1998

3. De Vita VT, Hellman S, Rosenberg SA : *Cancer : Principle and Practice of Oncology*. Philadelphia : Lippincott-Raven, 1997, pp964-965

4. Gross D : Pain and the autonomic nervous system in Bonica JJ (ed) : *Advances in neurology*. New York : Raven Press, 1974, Vol 4, pp93-104

5. Kim DH, Kline DG : Management and results of peroneal nerve lesions. *Neurosurgery* 39 : 312-319; discussion 319-320, 1996

6. Kim YS, Cho YE, Zhang HY : Thermatomes of the lumbosacral nerve roots. *J Korean Neurosurg Soc* 24 : 33-46, 1995

7. Kräuchi K, Wirz-Justice A : Circadian rhythm of heat production, heart rate, and skin and core temperature under unmasking conditions in men. *Am J Physiol* 267 (3 Pt 2) : R819-R829, 1994

8. Lawson R : Implications of surface temperatures in the diagnosis of breast cancer. *Can Med Assoc J* 75 : 309-311, 1956

9. Lin HP, Lin HY, Lin WL, Huang AC : Effects of stress, depression, and their interaction on heart rate, skin conductance, finger temperature, and respiratory rate : sympathetic-parasympathetic hypothesis of stress and depression. *J Clin Psychol* 67 : 1080-1091, 2011

10. Mahajan M, Sharma R, Sharma P, Gupta A : Schwannoma of superficial peroneal nerve presenting as leg pain. *J Case Rep* 2 : 79-82, 2012

11. Maleux G, Brys P, Samson I, Sciot R, Baert AL : Giant schwannoma of the lower leg. *Eur Radiol* 7 : 1031-1034, 1997

12. Matoković D, Cesarik M, Drkulec V, Tomić Rajić M : Neurinoma of the superficial peroneal nerve-case report. *Neurol Croat* 59 : 3-4, 2010

13. Milnes HL, Pavier JC : Schwannoma of the tibial nerve sheath as a cause of tarsal tunnel syndrome--a case study. *Foot (Edinb)* 22 : 243-246, 2012

14. Odom RD, Overbeek TD, Murdoch DP, Hosch JC : Neurilemoma of the medial plantar nerve : a case report and literature review. *J Foot Ankle Surg* 40 : 105-109, 2001

15. Oh JI, Park YK, Lim DJ, Chung HS, Lee KC, Lee HK : MRI diagnosis of a ganglion cyst of the peroneal nerve. *J Korean Neurosurg Soc* 26 : 1723-1726, 1997

16. Sato A, Schmidt RF : Somatosympathetic reflexes : afferent fibers, central pathways, discharge characteristics. *Physiol Rev* 53 : 916-947, 1973

17. Spinner RJ, Atkinson JL, Tiel RL : Peroneal intraneural ganglia : the importance of the articular branch. A unifying theory. *J Neurosurg* 99 : 330-343, 2003

18. Uematsu S : Thermographic imaging of cutaneous sensory segment in patients with peripheral nerve injury. Skin-temperature stability between sides of the body. *J Neurosurg* 62 : 716-720, 1985

19. Wakisaka S, Kajander KC, Bennett GJ : Abnormal skin temperature and abnormal sympathetic vasomotor innervation in an experimental painful peripheral neuropathy. *Pain* 46 : 299-313, 1991

20. Zhang HY, Chin DK, Cho YE, Kim YS : Correlation between pain scale and infrared thermogram in lumbar disc herniations. *J Korean Neurosurg Soc* 28 : 253-258, 1999

21. Zhang HY, Kim YS, Cho YE : Thermatomal changes in cervical disc herniations. *Yonsei Med J* 40 : 401-412, 1999