

# Enteral lorlatinib after immune hyperprogression as a treatment option for anaplastic lymphoma kinase-positive non-small cell lung cancer: A case report

HUAN WANG, ZHENYAN WU, GUANGQING SHI, JING ZHOU and ZHENLIANG XIAO

Department of Respiratory and Critical Care Medicine, General Hospital of Western Theater Command, Chengdu, Sichuan 610083, P.R. China

Received June 6, 2023; Accepted September 25, 2023

DOI: 10.3892/ol.2023.14113

**Abstract.** Fusion of the anaplastic lymphoma kinase (ALK) gene is a rare driver in non-small cell lung cancer (NSCLC). Lorlatinib is a third-generation ALK inhibitor approved for the treatment of locally advanced or metastatic ALK<sup>+</sup> NSCLC. The traditional administration method of lorlatinib is whole tablet ingestion, while the efficacy effect of gastric tube injection after water dissolution remains unclear. In the present report, a marked response to lorlatinib in a 49-year-old patient with ALK<sup>+</sup> NSCLC who was administered lorlatinib through a gastric tube, was described. The patient had received chemotherapy combined with immune checkpoint inhibitors prior to targeted drug therapy and developed hyperprogression, which was mainly manifested as rapid enlargement of the primary lesion with multiple new systemic metastases, accompanied by poor performance status score, esophageal compression and difficulty eating. The patient was injected with pre-dissolved lorlatinib through the nasogastric tube. After 6 days, related symptoms, such as dyspnea and dysphagia, were relieved. After 18 days, the esophageal stenosis was significantly alleviated, and the gastric tube was removed. In conclusion, gastric tube injection be used as a means of lorlatinib administration in patients with ALK<sup>+</sup> NSCLC with dysphagia, regardless of previous immunotherapy-associated hyperprogression.

## Introduction

Lorlatinib is a highly effective third-generation oral tyrosine kinase inhibitor against anaplastic lymphoma kinase (ALK).

---

*Correspondence to:* Dr Jing Zhou, Department of Respiratory and Critical Care Medicine, General Hospital of Western Theater Command, 270 Tianhui Road, Rongdu Avenue, Jinniu, Chengdu, Sichuan 610083, P.R. China  
E-mail: zhou8111027@foxmail.com

*Abbreviations:* ALK, anaplastic lymphoma kinase; CT, computed tomography; NSCLC, non-small cell lung cancer

*Key words:* dysphagia, lorlatinib, ALK, immune hyperprogression

In cell experiments, lorlatinib was shown to be more effective than second-generation inhibitors, and had the broadest coverage of ALK-resistant mutations (1). Despite the resistance of previous ALK inhibitors (first generation, second generation or both), lorlatinib exhibits strong antitumor activity (2), particularly in terms of intracranial activity in patients with central nervous system metastases (including leptomeningeal metastases) (3). Lorlatinib has been approved by Food and Drug Administration for use in patients with locally advanced or metastatic non-small cell lung cancer (NSCLC) who were previously treated with at least one ALK inhibitor (4). First- and second-generation ALK inhibitors are available in oral capsule form (5,6). Lorlatinib is administered as an oral tablet and no intravenous administration preparation is available (7). In patients with esophageal obstruction, it is unclear whether administration through a gastric tube affects the drug efficacy.

Hyperprogression was first described in case reports and retrospective studies of patients using immunosuppressive checkpoint inhibitors (such as Nivolumab, Pembrolizumab), when certain patients with cancer appeared to show accelerated tumor growth after beginning immunotherapy (8-10). Retrospective observational studies revealed that in patients with epidermal growth factor receptor (EGFR) and ALK mutations, first-line immune checkpoint inhibitors have a limited benefit and increase the risk of tumor hyperprogression (11,12). However, it remains unclear whether the efficacy of the targeted drug is affected if an immune checkpoint inhibitor is used in patients with the mutation, and if hyperprogression occurs because of an inadequate assessment of the initial status.

The present case report describes a patient with advanced NSCLC who was first evaluated as negative for gene mutations, but developed hyperprogression combined with external esophageal pressure stenosis after first-line chemotherapy combined with immune checkpoint inhibitors. The ALK gene fusion mutation was detected during reevaluation of the patient, and second-line treatment via gastric tube injection of lorlatinib was effective. In the present case, dysphagia and dyspnea improved after treatment.

## Case report

In a 49-year-old male patient who underwent a physical examination at the Western Theater General Hospital

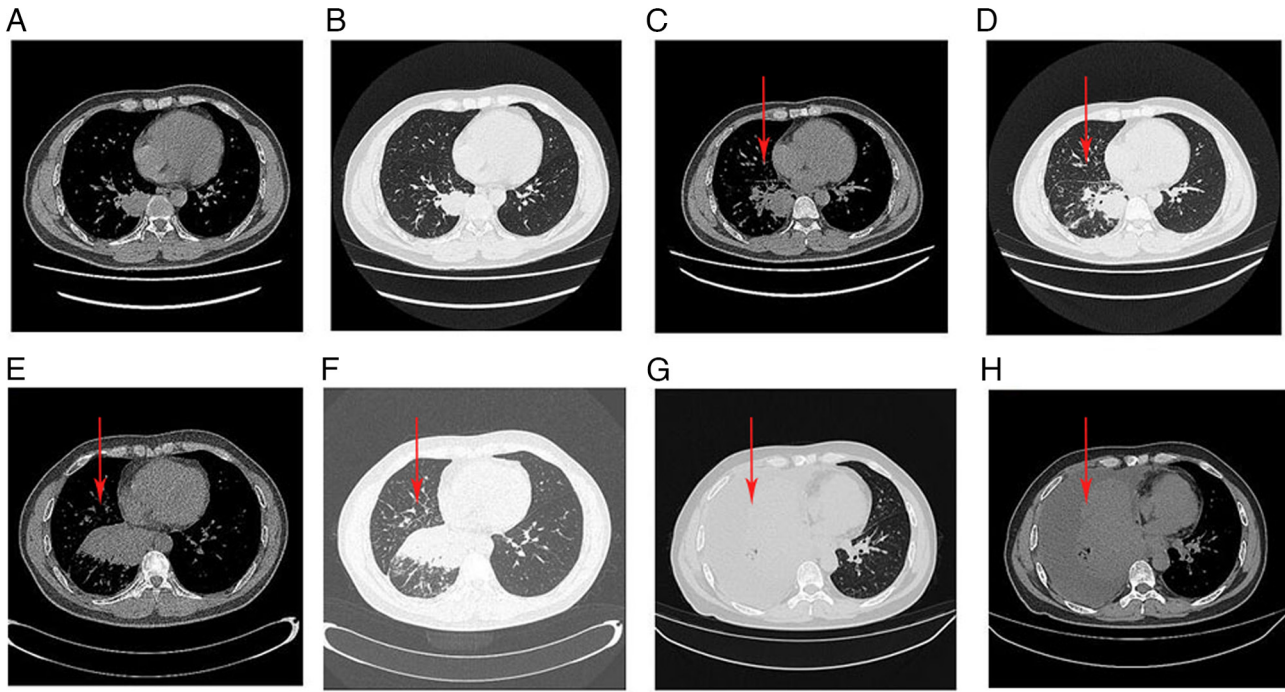


Figure 1. CT scans of the patient. (A) Mediastinal window of the lung mass in September 2021. (B) Pulmonary window where the lung mass was found in September 2021 (3.4x4.3x5.2 cm). (C) Mediastinal window of the lung mass in January 2022 and (D) shows the pulmonary window where the lung mass was found in January 2022 (4.0 x4.3x5.2 cm; red arrows). None of the aforementioned lung masses were treated. (E) Mediastinal window of chest CT after chemotherapy with pembrolizumab. (F) Pulmonary window of chest CT after chemotherapy with pembrolizumab. The lung mass is larger than before (red arrows). (G) Pulmonary window of chest CT after 5 cycles of treatment. (H) Mediastinal window of chest CT after 5 cycles of treatment. The pulmonary mass was significantly larger, which was considered to be caused by hyperprogression (red arrows). CT, computed tomography.

(Chengdu, China), a lung shadow with a size of 3.4x4.3x5.2 cm was observed on computed tomography (CT) in September 2021 (Fig. 1A and B). However, the patient did not recognize the severity of the disease. The patient was again admitted to the General Hospital of Western Theater Command (Chengdu, China) in January 2022 due to the presence of blood in the sputum. Reexamination of the chest CT images of the patient showed soft-tissue masses in the lower lobe of the right lung with a size of 4.0x4.3x5.2 cm (Fig. 1C and D). The pathological diagnosis of the patient was right lung adenocarcinoma with mediastinum, right hilar lymph nodes, pleura and bone metastases, stage IVB, based on CT-guided percutaneous pulmonary aspiration. Blood sampling was performed for next-generation sequencing (NGS) detection of lung cancer mutant genes conducted externally at Accbio due to an insufficient amount of biopsy tissue sample being available. Programmed death ligand 1 (PD-L1) expression was not detected, and mutations of EGFR, ALK, ROS proto-oncogene 1 and MET were negative. A total of three cycles (one cycle is 21 days) of chemotherapy consisting of pembrolizumab 200 mg, cisplatin 120 mg and pemetrexed disodium 800 mg injection were administered in February, March and April 2022. A chest CT at the end of May 2022 showed that the primary lesions were markedly enlarged, new lung consolidation had occurred, and right lung interstitial thickening with cancerous lymphangitis was more evident than that in the previous CT scans (Fig. 1E and F). The symptoms of the patient, such as cough and dyspnea, worsened, and hyperprogression was considered. Accordingly, two cycles of the treatment regimen consisting of cisplatin 120 mg, docetaxel 120 mg and bevacizumab 800 mg were administered.

The patient's tumor continued to grow, and considering that the rapid tumor growth may be caused by immunosuppressive checkpoint inhibitors, pembrolizumab was discontinued. The symptoms of the patient were not alleviated, and the patient refused further treatment and did not return to the clinic.

In October 18, 2022, the patient visited the physician again because of extreme dyspnea, complaining of nausea and vomiting after drinking water and inability to eat. A chest CT showed that the mass soft tissue density in the lower lobe of the right lung had increased in the shadow range. In addition, right lung interstitial thickening with carcinomatous lymphangitis was more evident than previously and numerous pleural effusions were detected on the right side (Fig. 1G and H). The patient had a performance status score of 2 (13). Pleural effusion puncture and drainage were performed, and adenocarcinoma cells were detected in the pleural effusion. The pleural effusion was sent again for genetic testing.

Gastroscopy revealed external pressure-associated esophageal stenosis, which could not be passed by the gastroscop (Fig. 2). A gastric tube was placed under the guidance of a guide wire under gastroscopy and X-ray imaging, and enteral nutrition support was provided through the gastric tube. Next-generation sequencing of the posterior pleural effusion showed that the cells were ALK (E13:A20) fusion mutation-positive.

It was decided that ALK inhibitors were to be administered, but the efficacy of administration through a gastric tube was unknown. Both crizotinib, a first-generation ALK inhibitor, and alectinib, a second-generation ALK inhibitor, are available as capsules and cannot be dissolved in water for injection through a gastric tube (5,6). The third-generation inhibitor lorlatinib

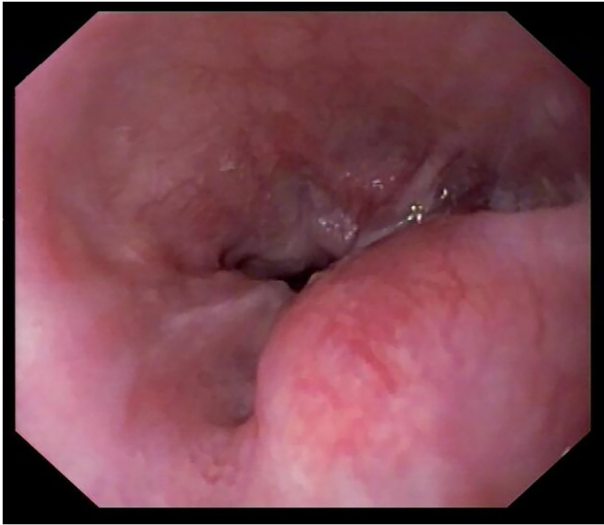

Figure 2. External pressure-induced esophageal stenosis observed through gastroscopy.




Figure 3. (A) Image showing lorlatinib being dissolved in a syringe. (B) Image showing lorlatinib injected into a gastric tube.

was administered to the patient as a tablet in October 2022 with patient's consent. The drug was dissolved in water at room temperature and injected through the gastric tube as follows: The gastric tube was rinsed with 20 ml warm water and the 100 mg (1 piece) tablets were placed in a syringe containing 20 ml warm water. The syringe was inverted for 5 min until the tablets had disintegrated (Fig. 3A), after which the solution was immediately injected into the gastric tube. The gastric tube and syringe were rinsed with warm water again to ensure that all of the drug had entered the stomach (Fig. 3B). A total of 6 days after this administration, the dyspnea and dysphagia of the patient had markedly improved and there was no increase in pleural effusion. After 18 days of lorlatinib treatment, the chest CT lesions of the patient were notably smaller than those

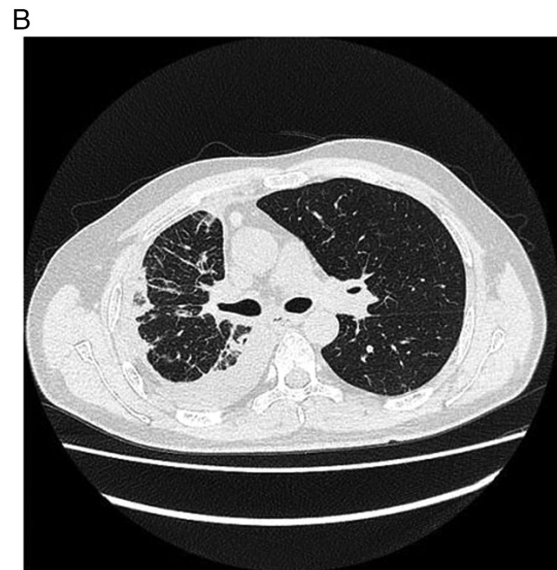
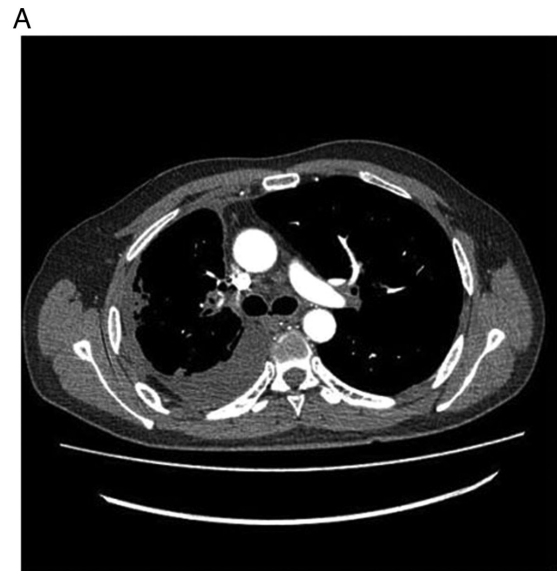


Figure 4. (A) Mediastinal and (B) pulmonary windows of chest CT after 18 days of treatment with lorlatinib. The mass of the lung is smaller than before.

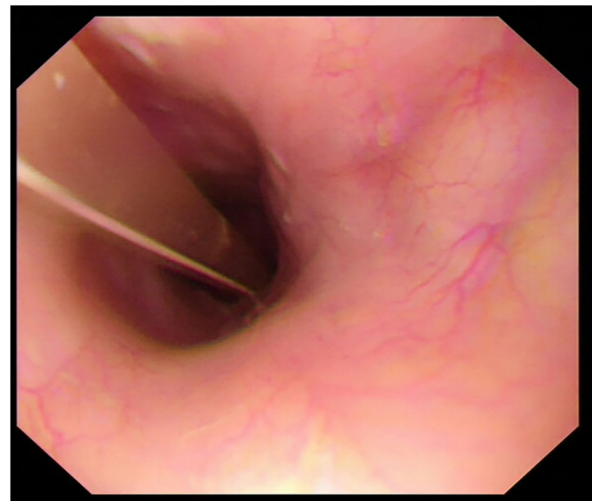


Figure 5. After 18 days of treatment with lorlatinib, gastroscopy showed that the external pressure esophageal stenosis disappeared.

observed previously (Fig. 4A and B). Gastroscopy showed that anterior esophageal stenosis was significantly relieved and the gastric mucosa was normal (Fig. 5). Thus, the gastric tube was removed and oral medication was taken autonomously. Subsequently, the patient was given oral lorlatinib and the tumor lesions continued to shrink.

After 18 days of taking lorlatinib, the patient was examined for blood lipids and developed hyperlipidemia. Atorvastatin 10 mg each time, once a day was given to reduce blood lipids. After 1 month of taking lorlatinib and atorvastatin, the patient's blood lipids returned to normal. Except for hyperlipidemia, other adverse events, such as edema, weight gain, diarrhea and constipation (7), were not observed at follow-up.

## Discussion

As a potent third-generation ALK inhibitor, lorlatinib inhibits almost all known mutated ALK types, including G1202R (14). G1202R is the most common secondary resistant ALK mutant in patients post progression with second generation ALK inhibitor (15). In the B7461001 study, second-line treatment with lorlatinib in patients who previously received crizotinib achieved an overall response rate of 72.9% and progression-free survival of 11.1 months (2). In the CROWN clinical trial, first-line use of lorlatinib exhibited superior efficacy compared with that of crizotinib in head-to-head studies, with an overall response rate of 77.2% and progression-free survival of at least 66 months (16). There is a tendency to use lorlatinib as a first-line treatment rather than as a second-line therapy. The CROWN phase 3 clinical trial of lorlatinib did not include patients with immunotherapy-associated hyperprogression who could not take the drug orally, and therefore, there are few studies on the administration of lorlatinib by gastric tube (17).

In preclinical studies, advantageous pharmacokinetic properties have been reported for lorlatinib, including a moderate volume of distribution, good oral bioavailability and low plasma clearance (15,18). Hibma *et al* (19) compared the bioavailability of a single oral dose of 100 mg and an intravenous dose of 50 mg of lorlatinib. The adjusted geometric mean (90% confidence interval) for the absolute oral bioavailability was 80.78% (75.73-86.16%), and the mean plasma elimination half-life was 25.5 h for oral administration and 27.0 h for intravenous administration, indicating the high bioavailability of oral lorlatinib. However, current targeted drugs for ALK gene mutations are only available as oral tablets, limiting the feasibility to administer these drugs to patients with dysphagia (5,6). As described in the present case report, lorlatinib was dissolved to obtain a suspension and injected into the gastric tube of the patient, leading to a notable curative effect. Thus, gastric injection may be used as a therapeutic approach for patients with advanced lung cancer who have dysphagia.

Immune hyperprogression is a serious condition experienced by a small number of patients treated with immune checkpoint inhibitors, the reported incidence of which varied between 4 and 29% (20). The mechanism and potential predictors of this process remain unclear. The survival time of patients with immune hyperprogression is shorter than that of other patients. Ferrara *et al* (21) showed that hyperprogression and non-hyperprogression PFS (1.4 vs. 4.9 months,  $P < 0.05$ ). In patients with lung cancer showing epidermal

growth factor receptor and ALK fusion, regardless of their PD-L1 expression, the overall survival of cases treated with first- or second-line immunotherapy followed by tyrosine kinase inhibitor treatment was significantly shorter than that of patients who were negative for gene mutations (22). This result may be related to the immunosuppressive state of the tumor microenvironment containing the gene mutation. The tumor immune microenvironment associated with the ALK fusion mutation lacks CD8<sup>+</sup> T cells and activated memory CD4<sup>+</sup> T cells; therefore, tumor immunogenicity is low (23). It has been shown that the co-existence of certain gene mutations is significantly associated with adverse outcomes of immunotherapy (24). Thus, further evaluation is needed to examine gene mutations in patients with advanced NSCLC before administering immune checkpoint inhibitor therapy. If a negative result is obtained when blood samples are used for genetic testing, the possibility of a false-negative result should be considered, particularly if the patient shows a poor response to immunotherapy, and repeated genetic testing should be performed.

In the present case report, the patient responded rapidly to treatment with lorlatinib, demonstrating another potential advantage of this drug. This effect was also observed in another patient with esophageal stenosis (25). In this previous study, the patient with ALK<sup>+</sup> NSCLC with esophageal metastasis showed rapid improvement of dysphagia symptoms after 5 days of treatment with lorlatinib without local therapy. In another study similar to the present study, within three days, the patient's consciousness improved (26). In the present case, dysphagia and dyspnea improved after 6 days of treatment. After 18 days of treatment, the patient showed significant improvement in cardiac orifice stenosis and the gastric tube was removed. The patient was able to eat normally and avoid the risk of esophageal stenting or gastrostomy. The efficacy of lorlatinib, given its rapid objective response, makes this therapeutic agent a good treatment choice after treatment with two or more tyrosine kinase inhibitors, and may be effective in patients with whom rapid tumor shrinkage is required.

## Acknowledgements

Not applicable.

## Funding

No funding was received.

## Availability of data and materials

The data generated in the present study are not publicly available, as the patient has not agreed to the public availability of the raw sequencing data, but may be requested from the corresponding author.

## Authors' contributions

HW and JZ conceptualized the present study. HW was the principal person responsible for the study and wrote the original manuscript. GS and ZW provided the case report details described in the manuscript. GS and ZW contributed to the

acquisition, analysis and interpretation of data and performed analysis and interpretation of CT imaging data. ZX performed a critical literature review, contributed to analysis and interpretation of data and contributed to the drafting of the Introduction and Discussion sections. JZ reviewed and edited manuscript. JZ and ZX confirm the authenticity of all the raw data. All authors have read and approved the final version of the manuscript. All authors have checked and confirmed the authenticity of the raw data generated during the study.

### Ethics approval and consent to participate

Not applicable.

### Patient consent for publication

The patient provided written informed consent for the publication of any data and/or accompanying images.

### Competing interests

The authors declare that they have no competing interests.

### References

- Horn L, Whisenant JG, Wakelee H, Reckamp KL, Qiao H, Leal TA, Du L, Hernandez J, Huang V, Blumenschein GR, *et al*: Monitoring therapeutic response and resistance: Analysis of circulating tumor DNA in patients with ALK+ lung cancer. *J Thorac Oncol* 14: 1901-1911, 2019.
- Solomon BJ, Besse B, Bauer TM, Felip E, Soo RA, Camidge DR, Chiari R, Bearz A, Lin CC, Gadgeel SM, *et al*: Lorlatinib in patients with ALK-positive non-small-cell lung cancer: Results from a global phase 2 study. *Lancet Oncol* 19: 1654-1667, 2018.
- Bauer TM, Shaw AT, Johnson ML, Navarro A, Gainor JF, Thurm H, Pithavala YK, Abbattista A, Peltz G and Felip E: Brain penetration of lorlatinib: Cumulative incidences of CNS and non-CNS progression with lorlatinib in patients with previously treated ALK-positive non-small-cell lung cancer. *Target Oncol* 15: 55-65, 2020.
- USFDA. FDA approves lorlatinib for metastatic ALK-positive NSCLC. <https://www.fda.gov/drugs/resources-information-approved-drugs/fda-approves-lorlatinib-metastatic-alk-positive-nsclc>. Accessed September 29, 2023.
- US FDA. Crizotinib prescribing information. [www.accessdata.fda.gov/drugsatfda\\_docs/label/2016/202570s0161bl.pdf](http://www.accessdata.fda.gov/drugsatfda_docs/label/2016/202570s0161bl.pdf). Accessed September 29, 2023.
- US FDA. Alectinib prescribing information. [www.accessdata.fda.gov/drugsatfda\\_docs/label/2017/208434s0031bl.pdf](http://www.accessdata.fda.gov/drugsatfda_docs/label/2017/208434s0031bl.pdf). Accessed September 29, 2023.
- US FDA. Lorlatinib prescribing information. [www.accessdata.fda.gov/drugsatfda\\_docs/label/2018/210868s0001bl.pdf](http://www.accessdata.fda.gov/drugsatfda_docs/label/2018/210868s0001bl.pdf). Accessed September 29, 2023.
- Chubachi S, Yasuda H, Irie H, Fukunaga K, Naoki K, Soejima K and Betsuyaku T: A case of non-small cell lung cancer with possible 'disease flare' on nivolumab treatment. *Case Rep Oncol Med* 2016: 1075641, 2016.
- Kazemi NY, Langstraat C and John Weroha S: Non-gestational choriocarcinoma with hyperprogression on pembrolizumab: A case report and review of the literature. *Gynecol Oncol Rep* 39: 100923, 2022.
- Champiat S, Derclé L, Ammari S, Massard C, Hollebecque A, Postel-Vinay S, Chaput N, Eggermont A, Marabelle A, Soria JC and Fertet C: Hyperprogressive disease is a new pattern of progression in cancer patients treated by anti-PD-1/PD-L1. *Clin Cancer Res* 23: 1920-1928, 2017.
- Kato S, Goodman A, Walavalkar V, Barkauskas DA, Sharabi A and Kurzrock R: Hyperprogressors after immunotherapy: Analysis of genomic alterations associated with accelerated growth rate. *Clin Cancer Res* 23: 4242-4250, 2017.
- Zhang L, Bai L, Liu X, Liu Y, Li S, Liu J, Zhang S, Yang C, Ren X and Cheng Y: Factors related to rapid progression of non-small cell lung cancer in Chinese patients treated using single-agent immune checkpoint inhibitor treatment. *Thorac Cancer* 11: 1170-1179, 2020.
- Azam F, Latif MF, Farooq A, Tirmazy SH, AlShahrani S, Bashir S and Bukhari N: Performance status assessment by using ECOG (eastern cooperative oncology group) score for cancer patients by oncology healthcare professionals. *Case Rep Oncol* 12: 728-736, 2019.
- Nagasaka M, Ge Y, Sukari A, Kukreja G and Ou SI: A user's guide to lorlatinib. *Crit Rev Oncol Hematol* 151: 102969, 2020.
- Zou HY, Li Q, Engstrom LD, West M, Appleman V, Wong KA, McTigue M, Deng YL, Liu W, Brooun A, *et al*: PF-06463922 is a potent and selective next-generation ROS1/ALK inhibitor capable of blocking crizotinib-resistant ROS1 mutations. *Proc Natl Acad Sci USA* 112: 3493349-8, 2015.
- Solomon BJ, Bauer TM, Ignatius Ou SH, Liu G, Hayashi H, Bearz A, Penkov K, Wu YL, Arrieta O, Jassem J, *et al*: Post hoc analysis of lorlatinib intracranial efficacy and safety in patients with ALK-positive advanced non-small-cell lung cancer from the phase III CROWN study. *J Clin Oncol* 40: 3593-3602, 2022.
- Shaw AT, Bauer TM, de Marinis F, Felip E, Goto Y, Liu G, Mazieres J, Kim DW, Mok T, Polli A, *et al*: First-line lorlatinib or crizotinib in advanced ALK-positive lung cancer. *N Engl J Med* 383: 2018-2029, 2020.
- Johnson TW, Richardson PF, Bailey S, Brooun A, Burke BJ, Collins MR, Cui JJ, Deal JG, Deng YL, Dinh D, *et al*: Discovery of (10R)-7-amino-12-fluoro-2,10,16-trimethyl-15-oxo-10,15,16,17-tetrahydro-2H-8,4-(metheno)pyrazolo[4,3-h][2,5,11]-benzoxadiazacyclotetradecine-3-carbonitrile (PF-06463922), a macrocyclic inhibitor of anaplastic lymphoma kinase (ALK) and c-ros oncogene 1 (ROS1) with preclinical brain exposure and broad-spectrum potency against ALK-resistant mutations. *J Med Chem* 57: 4720-4744, 2014.
- Hibma JE, O'Gorman M, Nepal S, Pawlak S, Ginman K and Pithavala YK: Evaluation of the absolute oral bioavailability of the anaplastic lymphoma kinase/c-ROS oncogene 1 kinase inhibitor lorlatinib in healthy participants. *Cancer Chemother Pharmacol* 89: 71-81, 2022.
- Frelaut M, Le Tourneau C and Borcoman E: Hyperprogression under Immunotherapy. *Int J Mol Sci* 20: 2674, 2019.
- Ferrara R, Caramella C, Texier M, Audigier Valette C, Tessonnier L, Mezquita L, Lahmar J, Mazieres J, Zalcman G, Brosseau S, *et al*: Hyperprogressive disease (HPD) is frequent in non-small cell lung cancer (NSCLC) patients (pts) treated with anti PD1/PD-L1 monoclonal antibodies (IO). *Ann Oncol* 28 (Suppl 5): v464-v465, 2017.
- Peters S, Gettinger S, Johnson ML, Jänne PA, Garassino MC, Christoph D, Toh CK, Rizvi NA, Chaft JE, Carcereny Costa E, *et al*: Phase II trial of atezolizumab as first-line or subsequent therapy for patients with programmed death-ligand 1-selected advanced non-small-cell lung cancer (BIRCH). *J Clin Oncol* 35: 2781-2789, 2017.
- Liu SY, Dong ZY, Wu SP, Xie Z, Yan LX, Li YF, Yan HH, Su J, Yang JJ, Zhou Q, *et al*: Clinical relevance of PD-L1 expression and CD8+ T cells infiltration in patients with EGFR-mutated and ALK-rearranged lung cancer. *Lung Cancer* 125: 86-92, 2018.
- Kang YK, Reck M, Nghiem P, Feng Y, Plautz G, Kim HR, Owonikoko TK, Boku N, Chen LT, Lei M, *et al*: Assessment of hyperprogression versus the natural course of disease development with nivolumab with or without ipilimumab versus placebo in phase III, randomized, controlled trials. *J Immunother Cancer* 10: e004273, 2022.
- Longo V, Catino A, Montrone M, Pizzutillo P, Ugenti I, Lacalamita R, Del Bene G, Pesola F, Marech I and Galetta D: Esophageal stricture caused by ALK-positive NSCLC esophageal metastasis resolved after a few days of lorlatinib therapy without stent placement. *JTO Clin Res Rep* 1: 100044, 2020.
- Sasaki K, Yokota Y, Isojima T, Fujii M, Hasui K, Chen Y, Saito K, Takahata T, Kindaichi S and Sato A: Enteral lorlatinib after alectinib as a treatment option in anaplastic lymphoma kinase-positive non-small cell lung cancer with triple problems: Carcinomatous meningitis, poor performance status, and dysphagia-a case report. *Respirol Case Rep* 9: e00796, 2021.

