

Colonic obstruction caused by accessory spleen torsion

A rare case report and literature review

Chuanzeng Ren, MD^{a,*}, Yongqing Liu, MD^a, Rongge Cao, MD^a, Tao Zhao, MD^a, Dong Chen, MD^a, Lingli Yao, MD^b, Zhili Pan, MD^c

Abstract

Rationale: Accessory spleen torsion is a rare cause of the acute abdomen. The complications of accessory spleen torsion, such as intestinal obstruction, are rarer. We herein report a case of colonic obstruction caused by accessory spleen torsion because of the unusual condition.

Patient concerns: A 15-year-old patient presented with acute intestinal obstruction with signs of peritoneal irritation. Abdominal computed tomography (CT) and ultrasonography examinations revealed a soft tissue mass in the left midabdomen. Systemic inflammatory response syndrome (SIRS) was observed in this case.

Diagnoses: The diagnosis of peritonitis and colonic obstruction secondary to accessory spleen torsion was made. Pathologic examination showed infarcted splenic tissue.

Interventions: We performed emergency laparotomy and found that accessory spleen torsion pressured against splenic flexure and descending colon, and caused colon obstruction. The patient underwent accessory splenectomy and enteral decompression.

Outcomes: At 6 months follow-up, the patient recovered well with perfect digestion.

Lessons: Accessory spleen torsion and its complications are extremely rare. This entity should be considered in differential diagnosis of acute abdomen. However, in case of acute abdomen with critical clinical situation, emergency surgical intervention is necessary for timely diagnosis and treatment.

Abbreviations: BP = blood pressure, BT = bacterial translocation, CT = computed tomography, MODS = multiple organ dysfunction syndrome, MRI = magnetic resonance imaging, SIRS = systemic inflammatory response syndrome.

Keywords: accessory spleen, acute abdomen, large bowel obstruction, torsion

1. Introduction

Accessory spleen is a congenital anomaly, with the incidence of approximately 10% to 30% in the population.^[1,2] However, most accessory spleens are asymptomatic. Accessory spleen torsion is a rare entity causing acute abdominal pain with occasional complications such as infarction, spontaneous rupture and hemorrhagic shock, infection and peritonitis, and intestinal obstruction.^[2–6] Here we report a rare case of colonic obstruction caused by accessory spleen torsion, and review the relevant literatures.

Editor: Alberto Stephano Tagliafico.

The authors have no conflicts of interest to disclose.

^a Department of Emergency Surgery, ^b Department of Pathology, ^c Department of Radiology, Anhui Provincial Hospital, Anhui Medical University, Hefei, Anhui, China.

* Correspondence: Chuanzeng Ren, Department of Emergency Surgery, Anhui Provincial Hospital, Anhui Medical University, 17 Lujiang Road, Hefei 230001, Anhui, China (e-mail: renchuanzeng@163.com).

Copyright © 2017 the Author(s). Published by Wolters Kluwer Health, Inc. This is an open access article distributed under the terms of the Creative Commons Attribution-Non Commercial License 4.0 (CCBY-NC), where it is permissible to download, share, remix, transform, and buildup the work provided it is properly cited. The work cannot be used commercially without permission from the journal.

Medicine (2017) 96:39(e8116)

Received: 16 May 2017 / Received in final form: 13 August 2017 / Accepted: 1 September 2017

<http://dx.doi.org/10.1097/MD.00000000000008116>

2. Case report

A written informed consent was obtained from the patient's legal guardian for publication of this case report, and the study was approved by the ethics committee of Anhui Provincial Hospital affiliated to Anhui Medical University.

A 15-year-old boy was admitted to our emergency department with a 3-day history of intense, constant pain in the left side of the abdomen, accompanied by nausea, vomiting, and a failure to pass flatus or bowel movements. His medical history was unimportant except for exercise 3 days ago. On admission the patient had moderate pyrexia (38.5°C), his blood pressure [BP] was 114/74 mm Hg, respiratory rate was 25 breaths/min and pulse was 135 beats/min. Physical examination revealed fullness in the left upper quadrant, there was tenderness to palpation of the whole abdomen, the point of the greatest tenderness with signs of peritoneal irritation in the left upper quadrant and left flank. The bowel sounds were hyperactive. Laboratory examination revealed white blood cell count of 18,400 cells/mm³ (normal values 3500–9500 cells/mm³) with 83.9% neutrophilia. The abdominal plain radiography revealed the dilation of the large bowel (Fig. 1). Abdominal ultrasonography showed an oval hypoechoic mass in the left midabdomen, about 9 × 7 × 4.5 cm, and a small amount of free peritoneal fluid. Computed tomography (CT) scan demonstrated a small amount of ascites and a well-defined, soft tissue mass in the left midabdomen, about 9 × 7 × 4 cm with edema in the surrounding fat (Fig. 2). Dilated gas-filled transverse colon was observed. The liver, spleen, kidneys, stomach, and pancreas were in normal location and

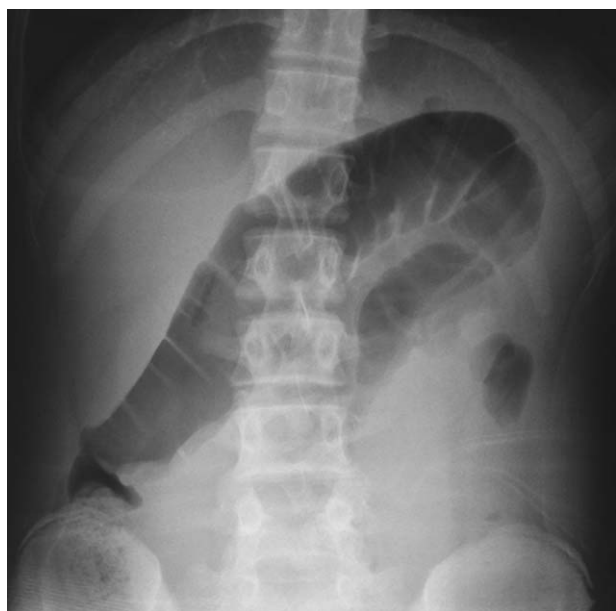


Figure 1. Abdominal plain radiography showed distended colon loop.

without any morphological changes (Fig. 3). We made the diagnosis of peritonitis and acute mechanical intestinal obstruction secondary to intraperitoneal tumor, and performed an emergency laparotomy. On exploration, a grossly distended transverse colon with air-fluid content was found; there was a bluish, congested, soft mass anterior to colonic splenic flexure and descending colon, about 10 × 7 × 4.5 cm. The mass was attached to splenic hilum and twisted around a vascular pedicle with a 720° torsion, compressing splenic flexure and descending colon. About 200 mL of cloudy, greenish-yellow free fluid was observed in the peritoneal cavity. A spleen with normal appearance was found in the orthotopic site. There was no intestinal necrosis or other abnormalities after further abdominal examination. We made the diagnosis of colonic obstruction caused by accessory spleen torsion, and performed accessory splenectomy and enteral decompression. Hematoxylin and eosin stain of the specimen showed red pulp, white pulp, and infarcted tissue; malignant cell was not observed (Fig. 4). In addition, the mass came from splenic hilum and cut surface was

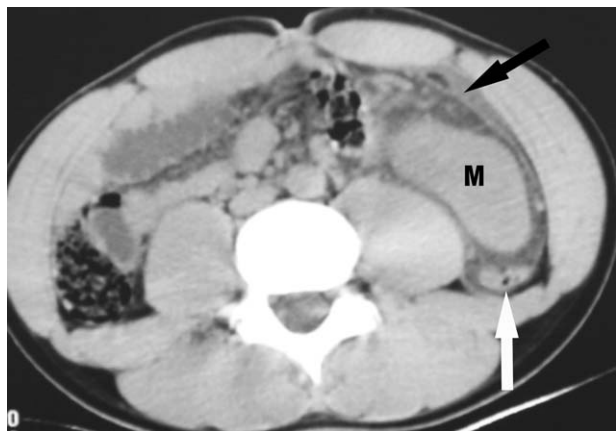


Figure 2. Noncontrast-enhanced axial CT image demonstrated a soft tissue mass (M) anterior to the descending colon (white arrow), a small amount of ascites was noted (black arrow).

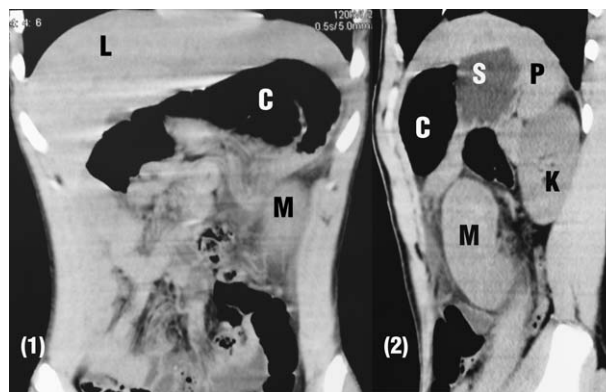

Figure 3. The coronal CT image (1) and sagittal CT image (2) showed a soft tissue mass (M) in the left midabdomen and dilated gas-filled transverse colon (C). The liver (L), spleen (P), kidneys (K), stomach (S) were in normal positions.

similar to spleen. The diagnosis of accessory spleen infarction was made postoperatively. The patient made an uneventful recovery and was discharged 7 days after surgery. In retrospect, a pedicle originating from splenic hilum to the mass was identified on CT image (Fig. 5). At 6 months follow-up, the boy recovered well with perfect digestion.

3. Discussion

The spleen develops from mesenchymal tissue in the dorsal mesogastrium during the fifth week of fetal life. An accessory spleen may arise from incomplete fusion of these mesenchymal buds.^[5,7] Because the spleen originates in the dorsal mesogastrium and then rotates to the left side of the abdomen, accessory spleens are always located in the left side of the body. The most common sites of accessory spleens are in the splenic hilum (75%) and in the pancreatic tail (20%), the remaining 5% of the sites include the gastrosplenic ligament, splenicocolic and gastrocolic ligaments, splenic artery, greater omentum, mesentery, left scrotum, and mediastinum.^[2,3,7,8] Accessory spleens generally range in size from 2 to 4 cm and receive blood supply from the branches of the splenic artery; only a few cases of large accessory spleen more than 10 cm in size have been reported.^[6,9,10] In our case, the patient had large accessory spleen.

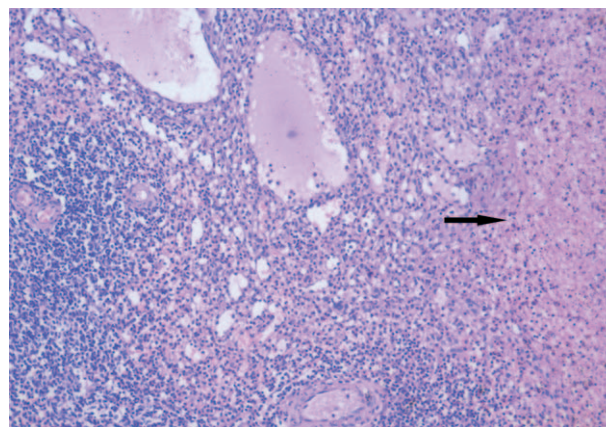


Figure 4. Postoperative pathology: hematoxylin and eosin staining showed red pulp (middle part), white pulp (left lower part), and infarcted tissue (black arrow).

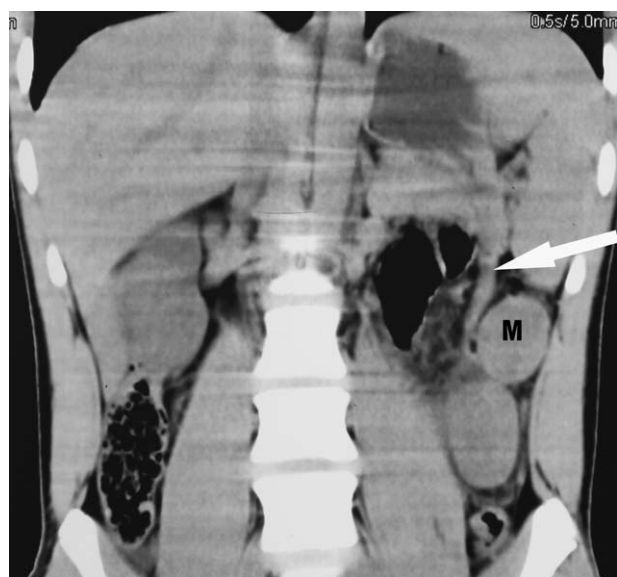

Figure 5. The coronal CT image showed a pedicle (white arrow) from splenic hilum to the mass (M).

Accessory spleen torsion is a rare entity, and only 31 cases (including this case) were reported in English literatures.^[1–28] Torsion of an accessory spleen generally presents as nonspecific acute abdominal pain, some of which is accompanied by fever, nausea, vomiting, leukocytosis, and ascites. These clinical manifestations are related to 3 features: First, torsion of an accessory spleen will undergo infarction and strangulation, producing acute inflammation.^[6,11] Second, twisting of the vascular pedicle results in venous congestion, causing enlargement and swelling of the accessory spleen.^[12] Third, direct mechanical interference to adjacent organs.^[3] All 3 of these features were observed in our case. Although there was no evidence of relationship between size, origin, and torsion, exercise may be a cause of accessory spleen torsion in this case.

Other complications of accessory spleen torsion are even rare, such as spontaneous rupture and hemorrhagic shock, infection and peritonitis, and intestinal obstruction. Only 1 case of intestinal obstruction caused by accessory spleen torsion was reported previously in which small bowel and colon were adherent to accessory spleen.^[3] However, our case is distinct because accessory spleen torsion pressured against splenic flexure and descending colon, and caused mechanical colon obstruction. This presentation may relate to the enlargement of accessory spleen due to venous congestion and the location approaching to splenic flexure and descending colon.

Interestingly, systemic inflammatory response syndrome (SIRS) was observed in the patient, whose body temperature was 38.5°C (>38°C), heart rate was 135 beats/min (>90 beats/min), respiratory rate was 25 breaths/min (>20 breaths/min), the white blood cell count was 18,400 cells/mm³ (>12,000 cells/mm³). These clinical parameters fulfilled all 4 SIRS criteria recommended by the American College of Chest Physicians/Society of Critical Care Medicine Consensus Conference.^[29] To the best of our knowledge, this is the first report of SIRS in such cases. We cannot completely explain the clinical presentation. Nonetheless, the presentation of SIRS is likely to be related to intestinal obstruction with resultant bacterial translocation (BT)^[30] and accessory spleen infarction with resultant inflammatory

changes. Many studies have shown that BT or gut-derived factors may provoke SIRS.^[31,32]

Preoperative diagnosis of accessory spleen torsion is very difficult, even with the modern imaging tools. Abdominal CT and ultrasonography examinations are helpful to make diagnosis.^[5] CT scan may disclose the mass and evaluate the shape, size, and changes of surrounding tissues, and contrast-enhanced CT may reveal a hypodense mass with peripheral enhancement.^[9] However, it is impossible to make accurate diagnosis unless a twisted vascular pedicle can be found.^[13] Ultrasonography findings include a well-defined, hypoechoic, and homogeneous mass.^[11] Doppler ultrasonography may confirm the avascular nature, but cannot distinguish between a cystic mass and accessory spleen torsion.^[14] Magnetic resonance imaging (MRI), scintigraphy and angiography can provide significant information, but they are not always available in an emergency condition.^[7,15] In our case, emergency laparotomy was performed to arrest strangulated intestinal obstruction and avoid the progression to multiple organ dysfunction syndrome (MODS) from SIRS.^[33] There was not enough time to perform contrast-enhanced CT, MRI, scintigraphy, and angiography.

Differential diagnosis should be considered preoperatively. A presumptive diagnosis of intraperitoneal tumor was made due to routine CT and ultrasonography revealing soft tissue mass. Enhanced CT might establish the nature of the mass but was of unknown origin. Intussusception was suspected because of abdominal mass and intestinal obstruction, but a target or sandwich sign on ultrasonography and a targetlike appearance on CT scan may confirm the diagnosis of intussusception. Abscess was another possibility, which appeared as a hypoattenuating lesion on CT scan and the presence of gas was typical CT findings.^[19]

In conclusion, accessory spleen torsion and its complications, such as intestinal obstruction, are extremely rare. It is very difficult to make an accurate diagnosis preoperatively. This entity should be considered in differential diagnosis of acute abdomen. However, in case of acute abdomen with critical clinical situation, emergency surgical intervention is necessary for timely diagnosis and treatment.

References

- Alexander RC, Romanes A. Accessory spleen causing acute attacks of abdominal pain. *Lancet* 1914;184:1089–91.
- Gardakis S, Pitiakoudis M, Sigalas I, et al. Infarction of an accessory spleen presenting as acute abdomen in a neonate. *Eur J Pediatr Surg* 2005;15:203–5.
- Settle EB. The surgical importance of accessory spleens: with report of two cases. *Am J Surg* 1940;50:22–6.
- Babcock TL, Coker DD, Haynes JL, et al. Infarction of an accessory spleen causing an acute abdomen. *Am J Surg* 1974;127:336–7.
- Padilla D, Ramia JM, Martin J, et al. Acute abdomen due to spontaneous torsion of an accessory spleen. *Am J Emerg Med* 1999;17:429–30.
- Kitchin RJ, Green NA. Torsion of an accessory spleen presenting as acute appendicitis. *Br J Surg* 1962;50:232–3.
- Grinbaum R, Zamir O, Fields S, et al. Torsion of an accessory spleen. *Abdom Imaging* 2006;31:110–2.
- Wacha M, Danis J, Wayand W. Laparoscopic resection of an accessory spleen in a patient with chronic lower abdominal pain. *Surg Endosc* 2002;16:1242–3.
- Perez Fontan FJ, Soler R, Santos M, et al. Accessory spleen torsion: US, CT and MR findings. *Eur Radiol* 2001;11:509–12.
- Bard V, Goldberg N, Kashtan H. Torsion of a huge accessory spleen in a 20-year-old patient. *Int J Surg Case Reports* 2014;5:67–9.
- Seo T, Ito T, Watanabe Y, et al. Torsion of an accessory spleen presenting as an acute abdomen with an inflammatory mass. US, CT, and MRI findings. *Pediatr Radiol* 1994;24:532–4.

- [12] Valls C, Monés L, Gumà A, et al. Torsion of a wandering accessory spleen: CT findings. *Abdom Imaging* 1998;23:194–5.
- [13] Mendi R, Abramson LP, Pillai SB, et al. Evolution of the CT imaging findings of accessory spleen infarction. *Pediatr Radiol* 2006;36:1319–22.
- [14] Impellizzeri P, Montalto AS, Borruto FA, et al. Accessory spleen torsion: rare cause of acute abdomen in children and review of literature. *J Pediatr Surg* 2009;44:E15–8.
- [15] Jans R, Vanslebrouck R, Van-Hoe L, et al. Torsion of accessory spleen in an adult patient: imaging findings at CT, MRI and angiography. *J Belge Radiol* 1997;80:229–30.
- [16] Alexander RC. Accessory spleen with recurring torsion of its pedicle. *Lancet* 1929;2:29.
- [17] Hems TEJ, Bellringer JF. Torsion of an accessory spleen in an elderly patient. *Postgrad Med J* 1990;66:838–9.
- [18] Dahlin LB, Agagnostaki L, Delshammar M, et al. Torsion of an accessory spleen in an adult. Case report. *Eur J Surg* 1995;161:607–9.
- [19] Corsi A, Summa A, De Filippo M, et al. Acute abdomen in torsion of accessory spleen. *Eur J Radiol Extra* 2007;64:15–7.
- [20] Zhang KR, Jia HM. Symptomatic accessory spleen. *Surgery* 2008;144:476–7.
- [21] Kim TH, Kim JK, Park MJ, et al. Education and imaging. Hepatobiliary and pancreatic: torsion of an accessory spleen. *J Gastroenterol Hepatol* 2009;24:1308.
- [22] Yousef Y, Cameron BH, Maizlin ZV, et al. Laparoscopic excision of infarcted accessory spleen. *J Laparoendosc Adv Surg Tech A* 2010;20:301–3.
- [23] Ishibashi H, Oshio T, Sogami T, et al. Torsion of an accessory spleen with situs inversus in a child. *J Med Invest* 2012;59:220–3.
- [24] Sadro CT, Lehnert BE. Torsion of an accessory spleen: Case report and review of the literature. *Radiol Case Rep* 2013;8:802.
- [25] Lhuairé M, Sommacale D, Piardi T, et al. A rare cause of chronic abdominal pain: recurrent sub-torsions of an accessory spleen. *J Gastrointest Surg* 2013;17:1893–6.
- [26] Mocanu SN, Sierra Vinuesa A, Muñoz-Ramos Trayter C, et al. Accessory spleen torsion in a teenager. *ANZ J Surg* 2015;85:987–9.
- [27] Ozeki M, Asakuma M, Go N, et al. Torsion of an accessory spleen: a rare case preoperatively diagnosed and cured by single-port surgery. *Surg Case Rep* 2015;1:100.
- [28] Bass RT, Tao Yao S, Freeark RJ. Torsion of an accessory spleen of the cecum presenting as acute appendicitis. *New Engl J Med* 1967;277:1190–1.
- [29] American College of Chest Physicians/Society of Critical Care Medicine Consensus Conference Definitions for sepsis and organ failure and guidelines for the use of innovative therapies in sepsis. *Crit Care Med* 1992;20:864–74.
- [30] Sagar PM, MacFie J, Sedman P, et al. Intestinal obstruction promotes gut translocation of bacteria. *Dis Colon Rectum* 1995;38:640–4.
- [31] Deitch EA, Xu D, Kaise VL. Role of the gut in the development of injury- and shock induced SIRS and MODS: the gut-lymph hypothesis, a review. *Front Biosci* 2006;11:520–8.
- [32] Shiomi H, Shimizu T, Endo Y, et al. Relations among circulating monocytes, dendritic cells, and bacterial translocation in patients with intestinal obstruction. *World J Surg* 2007;31:1806–12.
- [33] Haga Y, Beppu T, Doi K, et al. Systemic inflammatory response syndrome and organ dysfunction following gastrointestinal surgery. *Crit Care Med* 1997;25:1994–2000.