

## Case Report

# Mandibular Canines with Two Roots and Two Root Canals: Case Report and Literature Review

Hugo Plascencia,<sup>1</sup> Álvaro Cruz,<sup>2</sup> Gerardo Gascón,<sup>3</sup> Beatriz Ramírez,<sup>3</sup> and Mariana Díaz<sup>1</sup>

<sup>1</sup>Endodontic Postgraduate Program, CUCS-CUAltos, University of Guadalajara, Guadalajara, JAL, Mexico

<sup>2</sup>Research Institute in Biomedical Sciences, CUCS, University of Guadalajara, Guadalajara, JAL, Mexico

<sup>3</sup>Endodontic Postgraduate Program, CUCS, University of Guadalajara, Guadalajara, JAL, Mexico

Correspondence should be addressed to Hugo Plascencia; endohugo81@hotmail.com

Received 6 April 2017; Revised 11 July 2017; Accepted 6 August 2017; Published 13 September 2017

Academic Editor: Stefan Ioan Stratul

Copyright © 2017 Hugo Plascencia et al. This is an open access article distributed under the Creative Commons Attribution License, which permits unrestricted use, distribution, and reproduction in any medium, provided the original work is properly cited.

Usually, the mandibular canine only has one root and one root canal. However, there has been a noticeable increment in evidence showing variations in its morphology, such as the presence of two roots and two root canals. The aim of this article was to present a case of a mandibular canine with two roots and two root canals and to review the available literature on this anatomic variation. Root canal treatment of tooth #43 with such morphology was performed in a 47-year-old woman. Careful inspection of the preoperative radiograph indicated the presence of more than one canal. The 12-month follow-up showed normal periapical tissues, with no pain or tenderness. Literature review revealed that the overall prevalence of such root canal configuration is 5.7%, with a strong preference for female sex (87.5%). Although mandibular canines with two roots and two root canals are not common, clinicians should always anticipate the presence of possible variations. Therefore, timely diagnosis and meticulous exploration of such mandibular canines allow for planning of an individualized treatment protocol, tailored to their peculiar morphology, focused on avoiding excessive weakening or even perforation of the roots.

## 1. Introduction

The mandibular canine is a strategically important tooth in the dental arch. Its long and stable root is useful for prosthetic support due to its proprioceptive properties that regulate or guide masticatory function, combined with its role in occlusal guidance during the eccentric movements and posterior disocclusion [1]. Therefore, considerable effort is directed to its preservation, even though there may be diverse morphologic challenges.

Usually, the mandibular canine only has one root and one root canal [2]. However, since the beginning of the 21st century, due to introduction of new technologies related to intraoperative vision magnification and innovative radiological imaging systems, there has been a noticeable increment in the number of clinical studies, *in vitro/ex vivo* studies, and case reports that have revealed morphological variations, such as the presence of two roots and two root canals in the mandibular canine. Finding variations, such as this,

is unpredictable and the clinician must assume that any mandibular canine could morphologize with variation, so that any unforeseen treatment complications related to unusual root canal anatomy can be avoided. The objective of this article was to present a case of a mandibular canine with two roots and two root canals and to perform a literature review regarding this anatomical variation.

## 2. Case Presentation

A 47-year-old female patient visited the Endodontic Department of the University of Guadalajara, Mexico, for a checkup of the tooth #43 (right mandibular canine). She was referred by a general dentist, being asymptomatic, with caries located in the buccocervical region of the crown, which had reached the pulp chamber. The general dentist performed an initial cleaning of the caries two weeks prior, but given its depth and extent, the patient was referred for a specialized assessment. She had no history of systemic or allergy problems. In the

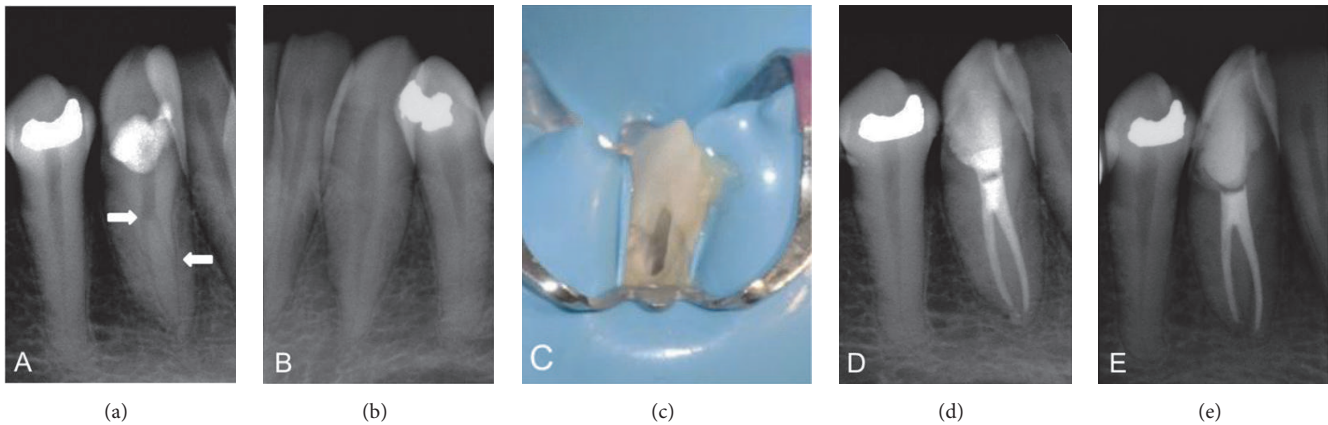


FIGURE 1: (a) Preoperative radiograph shows sudden loss in the continuity of the canal and the presence of a groove in the outer part of the root (arrows). (b) Counterpart canine radiograph reveals typical root features. (c) Buccal access cavity due to dental giroversion. (d) Post-treatment radiograph. (e) 12-month follow-up radiograph shows normal periapical tissues.

clinical examination, a dental giroversion, with a maladjusted temporary restoration surrounded by recurrent cavities, was observed. Under magnification, it was confirmed that the caries was in clear communication with the pulp chamber. Response to the sensitivity test was intense and transitory. Radiographic examination revealed a sudden loss in the continuity of the canal (Figure 1(a)) and the presence of a groove in the outer part of the root, findings that suggest the presence of a mandibular canine with two independent, narrow, and curved canals. Radiographic images of the counterpart canine showed normal characteristics (Figure 1(b)). On the basis of the clinical and radiographic findings, a diagnosis of asymptomatic irreversible pulpitis and normal periapical tissues was established, and root canal treatment was planned.

After the patient provided signed informed consent, local anesthesia was administered and a dental dam was placed; the temporary restoration and decayed tissue were removed. As the dental giroversion impeded the lingual conventional opening, cameral access was created from the buccal side (Figure 1(c)). With the aid of magnification throughout the treatment, the pulp chamber roof and the lingual cervical ridge were eliminated to obtain access to the second canal. As the initial clinical and radiographic findings indicated the presence of a second root canal, the radicular pulp space was carefully screened with the DG-16 endodontic explorer (American Eagle, CA, USA), and the entrances of two root canals were found, one buccal and one lingual. On the basis of this information, the treatment protocol was focused on avoiding removal of excessive tooth structure or perforation of the roots. Under abundant irrigation with 1% sodium hypochlorite (NaOCl), the canals were explored with a size #15 K-file, and cervical flaring was carefully performed with #2 Gates Glidden bur. The working length was determined with a radiograph and corroborated with an electronic apex locator. Cleaning and shaping of the apical thirds were performed with rotatory NiTi files (S1, S2, and F1 Universal Pro-Taper, Dentsply, Tulsa, OK), followed by manual instrumentation with a size #35 Flexo-file in both root canals, irrigating with 1% NaOCl between the use of each instrument. Due to

time constraints, intracanal dressing with calcium hydroxide was placed and the access was sealed with a temporary cement.

After 7 days, the intracanal medication was removed with 17% ethylenediaminetetraacetic acid (EDTA) irrigation and ultrasonic activation. Once both canals were dried, the lingual canal was first filled, to prevent visibility obstruction, followed by the buccal root canal. They were filled with a mix of gutta-percha and resin-based sealer (AH-Plus), using lateral cold compaction. The access opening was sealed with temporary cement, and a final radiograph was taken (Figure 1(d)). The 12-month follow-up showed the access cavity restored with a composite-based sealing material, with no pain or tenderness and normal periapical tissues upon clinical and radiographic examinations (Figure 1(e)).

### 3. Literature Review

**3.1. Information Sources and Search Strategy.** The electronic databases PubMed (<https://www.ncbi.nlm.nih.gov/pubmed>), Cochrane (<http://www.cochrane.org>), and Scientific Electronic Library Online (SciELO) (<https://www.scielo.org>) were searched to locate relevant articles (last access was on April 06, 2017). The following keyword combinations were used: “mandibular canine”, “two root canals”, “root canal anatomy”, and “anterior teeth”. Moreover, extensive manual search by two individuals (H. P. and M. D.) of four relevant scientific magazines (Journal of Endodontics, International Endodontic Journal, Oral Surgery Oral Medicine Oral Pathology Oral Radiology & Endodontics, and Dental Traumatology) was performed, including the reference section of each relevant article with the objective of finding additional works. Furthermore, endodontic textbooks and arbitrated and indexed magazines that did not appear in these electronic databases were inspected.

**3.2. Selection Criteria.** A total of 2324 articles were identified, 2266 in the electronic databases and 58 from the manual searches. After eliminating duplicate articles, the

titles/abstracts of all manuscripts were reviewed to check if the articles fulfilled the following inclusion criteria, in sequential order:

- (1) Analyze the root canal anatomy of the mandibular canine.
- (2) Report the presence of mandibular canine with two roots and two root canals.

Subsequently, all the works were thoroughly and independently inspected by two expert endodontists (H. P. and M. D.). In cases where there was lack of concordance between the reviewers, a third reviewer made the final decision (B. R.).

**3.3. Data Extraction.** Of the 2324 articles initially identified, only 44 fulfilled both inclusion criteria. The 44 articles were classified according to the type of study as follows: clinical studies, *in vitro/ex vivo* studies, and case reports. From the clinical studies and the *in vitro/ex vivo* studies, the following information was obtained:

- (1) Study author(s)
- (2) Country where the study was conducted
- (3) Sample size (number of mandibular canines and their origin, if it was specified)
- (4) Method used for the study of the internal anatomy
- (5) Prevalence of two roots and two root canals in the mandibular canine
- (6) Root canal system configuration of the mandibular canine according to Vertucci's classification (Tables 1 and 2) [3].

For each case report, the following information was registered:

- (1) Study author(s)
- (2) Country where the study was conducted
- (3) Tooth
- (4) Patient age and sex
- (5) Root canal system configuration of the mandibular canine according to Vertucci's classification (Table 3) [3].

#### 4. Discussion

This study aimed to present a case of a mandibular canine with two roots and two root canals and to review the available literature on this anatomical variation. In general, the mandibular canine is considered to have a high prevalence of Vertucci's type I configuration [2, 3, 14], which is in agreement with our result obtained from the literature review (85%) (Tables 1 and 2). However, the classic articles of Hess (1921, 1925) [50, 51] reported a noticeable low prevalence of single root canal in the mandibular canine (57.1%), which shows that anatomic variations in this tooth are a latent possibility. In fact, anthropologic findings have revealed that

the mandibular canine with two roots was a common feature in Europeans from the 11th to the 19th century, in contrast to the null detection in the Asian population [52]. Such affirmation differs from the contemporary concepts, where it has been demonstrated that alterations in the number of roots and/or root canals tend to present higher prevalence in populations with Mongoloid features [53].

Without performing extensive imaging examinations, it is difficult to precisely determine by clinical means whether a mandibular canine presents only one root with two independent apical foramina or actually has two separate roots. Thus, the decision was made to group both alterations. With respect to this, only 18 articles (Tables 1 and 2) specified in detail the root canal system configuration of the mandibular canine, where the findings of two root canals and two independent apical foramina were the most common anatomical variations (5.7%). Two studies have focused on the morphological analysis specifically of two-rooted mandibular canines and evaluated diverse parameters of endodontic interest [54, 55].

Despite the fact that the mandibular canine is one of the least studied teeth, the first case report of finding a mandibular canine with two roots was published in 1886 (Table 3) [24]. We found 25 other reports on that entity of which 22 were published between the years 2000 and 2017. We found that the variation has a strong preference for the female sex (87.5%), mainly in patients with an average age of 38.1-years (range 17–60 years).

Early detection of a mandibular canine with two roots and two root canals favorably influences the success rate of endodontic treatment, as it allows the use of specific diagnostic tools and the setting of individualized strategies based on the anatomical particularity of the tooth. Therefore, it is crucial to carefully inspect the diagnostic radiographs; it is helpful to be aware of the importance of detection of a sudden loss in the continuity of the root canal lumen or a radiolucent groove in the lateral part of the root, which are findings that hint to the presence of more than one canal [56]. If a morphological alteration is suspected, acquiring angled radiographs (20°–25° or Clark technique) facilitates the detection of extra canals [57, 58]. If necessary, the use of limited field-of-view cone beam computed tomography will help to confirm the internal variations that are not clearly distinguishable with conventional methods [59]. Unfortunately, this technology also has some limitations, such as administration of a high radiation dose to the patient, possible artifact generation, high levels of scatter and noise, and variations in dose distribution, which should be considered when selecting the appropriate imaging modality in endodontic cases [60].

However, a mandibular canine with two roots can present bifurcation at different root levels, which implies a certain degree of difficulty according to the zone where it is located. When the division is located apically, there is a higher degree of difficulty during the localization and mechanical preparation of the root canals. In contrast, when the division is located more cervically, there are increased risks of perforating the bifurcation during the search for the additional canal. Therefore, performing an access opening in a straight line is crucial, as it improves visualization of the whole pulp chamber and aids with the determination

TABLE 1: Prevalence of mandibular canines with two roots and two root canals reported in clinical studies ( $n = 5$  articles).

Author/year	Materials and methods	Country	Number of mandibular canines ( $n$ )	Type I (I) (%)	Root canal configuration* Prevalence of 2 apical foramina (%)
Aminsobhani <i>et al.</i> 2013 [4]	CBCT	Iran	608 (298 males and 310 females)	71.8%	19.8% (4.7% bi-rooted, 12.8% type IV [2], and 2.3% type V [1, 2])
Altunsoy <i>et al.</i> 2014 [5]	CBCT	Turkey	1604 (805 males and 799 females)	92.7%	3.9% (1.3% type IV [2] and 2.6% type V [1, 2])
Han <i>et al.</i> 2014 [6]	CBCT	China	1291 (645 right and 646 left)	93.7%	1.8% (1.3% bi-rooted and 0.5% type V [2])
da Silva <i>et al.</i> 2016 [7]	CBCT	Brazil	200	90.5%	4.5% (2.5% type IV [2] and 2% type V [1, 2])
Soleymani <i>et al.</i> 2017 [8]	CBCT	Iran	300 (172 females and 128 males)	89.7%	1% (all type V)

\*Vertucci's root canal configuration.

TABLE 2: Prevalence of mandibular canines with two roots and two root canals reported in *in vitro/ex vivo* studies ( $n = 13$  articles).

Author/year	Materials and methods	Country	Number of mandibular canines (n)	Root canal configuration*	
				Type I (I) (%)	Prevalence of 2 apical foramina (%)
Pineda and Kuttler 1972 [9]	Periapical radiographs	Mexico	187	81.5%	5% (birooted)
Green 1973 [10]	Microscopic inspection of longitudinal sections	USA	100	87%	3% (type IV [2])
Kerekes and Tronstad 1977 [11]	Microscopic inspection of cross-sections	Norway	20	90%	10% (5% birooted and 5% type V [1-2])
Hession 1977 [12, 13]	Periapical radiographs and contrast dye	Australia	9	88.9%	11.1% (birooted)
Vertucci 1974 [14] and 1984 [3]	Clearing and staining with China ink	USA	100	78%	6% (type IV [2])
Pécora et al. 1993 [15]	Clearing and staining with China ink	Brazil	830	92.2%	2.9% (1.7% birooted and 1.2% type IV [2])
Matzer 1993 [16]	Clearing and staining with China ink	Guatemala Republic	50	96%	4% (birooted)
Calışkan et al. 1995 [17]	Clearing and staining with China ink	Turkey	100	80.3%	1.9% (type V [2])
Sikri and Kumar 2003 [18]	Periapical radiographs and clearing	India	100	70%	12% (10% type IV [2] and 2% type V [1-2])
Sert and Bayirli 2004 [19], Sert et al. 2004 [20]	Clearing and staining with China ink	Turkey	200	76%	1.5% (type IV [2])
Oliveira and Lorio 2007 [21]	Periapical radiographs and clearing and staining with China ink	Brazil	1040	91.9%	1.1%
Rahimi et al. 2013 [22]	Clearing and staining with China ink	Iran	149	80.5%	12% (birooted)
Amardeep et al. 2014 [23]	CBCT	India	250	79.6%	2% (type V [1-2])

\*Vertucci's root canal configuration.

TABLE 3: Case reports of mandibular canines with two roots and two root canals ( $n = 26$  articles).

Author/year	Country	Tooth	Age (y)/sex	Root canal configuration*
Vawter 1886 [24]	USA	#43	45 (female)	Birooted
Koskins 1926 [25]	USA	#33, #33, #33	35 (female), 35 (female), and 35 (female)	All type V (1-2)
Slowey 1974 [26]	USA	#33	Unspecified	Type IV (2)
Rahmatulla and Wyne 1993 [27]	Yemen	#43	28 (female)	Type V (1-2)
D'Arcangelo et al. 2001 [28]	Italy	#43, #43	48 (female) and 60 (female)	Both type IV (2)
Wang et al. 2009 [29]	China	#43, #43	46 (female) and 40 (female)	Type II (2-1) and IV (2)
Victorino et al. 2009 [30]	Brazil	Bilateral	40 (female)	Both type V (1-2)
Oporto et al. 2010 [31]	Chile	#33	37 (female)	Type V (1-2)
Maden et al. 2010 [32]	Turkey	#43	17 (female)	Type IV (2)
Andrei et al. 2010 [33]	Romania	#43	54 (female)	Type IV (2)
Gaikwad 2011 [34]	India	#33	20 (female)	Type V (1-2)
Fonseca et al. 2011 [35]	Brazil	#33	39 (male)	Type V (1-2)
A. Bhardwaj and A. Bhardwaj 2011 [36]	India	#43	18 (female)	Type V (1-2)
Andrei et al. 2011 [37]	Romania	#43	59 (female)	Type IV (2)
Saberi 2011 [38]	United Kingdom	#43	30 (male)	Type V (1-2)
Moogi et al. 2012 [39]	India	#43	32 (female)	Type V (1-2)
Batra et al. 2012 [40]	India	#33	35 (female)	Type V (1-2)
Ramírez-Sotelo et al. 2013 [41]	Brazil	#33	21 (female)	Finding of birooted mandibular canine in CBCT and panoramic radiograph
Mithunjith and Borthakur 2013 [42]	India	#43	42 (female)	Type IV (2)
Fuentes and Borie 2013 [43]	Chile	Bilateral	44 (female)	Finding of birooted mandibular canines in panoramic radiograph
Stojanac et al. 2014 [44]	Serbia	#33, #33, #33, #43	42 (male), 38 (female), 44 (female), and 46 (female)	Types V (1-2), IV (2), V (1-2), and IV (2)
Mukhaimer and Arandi 2014 [45]	Palestine	#43	23 (female)	Type V (1-2)
Ganesh et al. 2014 [46]	India	#33	46 (female)	Type IV (2)
Gandhi and Bhat 2014 [47]	India	#43	39 (male)	Type IV (2)
Fumei et al. 2014 [48]	Italy	#43	30 (female)	Type V (1-2)
Kulkarni et al. 2016 [49]	India	#43	54 (female)	Type IV (2)

\* Vertucci's root canal configuration.

of the accurate division point, preferably with the combined use of vision magnification and tactile examination with the DG-16 endodontic explorer. Moreover, it is useful to measure, through the root canal, the exact distance between the incisal reference point and the bifurcation zone, either with a periodontal probe or with a type K-file. Subsequently, by using ultrasound tips or long shaft burs, the pericervical dentin, which usually obstructs lingual canal access, should be carefully removed up to the distance that was previously

determined, by performing small and progressively deeper movements. It is important to be careful with these types of movements, as they could excessively weaken the remaining root structure. The use of such strategies in combination with adequate operator skills could establish straight-line access to the root canals.

Versiani et al. (2011) [55] reported that in all two-rooted mandibular canines, the main apical foramen tends to be located eccentrically; therefore, the possibility of



overinstrumentation is high. Thus, it is recommended to use an electronic apex locator to precisely locate the apical constriction. Furthermore, the timely detection of a mandibular canine with two roots and two root canals allows planning for a conservative mechanical instrumentation approach (apical size no larger than ISO #35), focusing on the preservation of the structure of the slim curved roots, which are susceptible to lateral perforation. Likewise, the abundant presence of accessory canals in this type of mandibular canine emphasizes the importance of adequate irrigation and obturation. According to Sharma et al. (1998) [54] and Versiani et al. (2011) [55], the prevalence of lateral communications and furcation canals is high, oscillating between 68.9% and 29%, respectively. Therefore, the use of final irrigation based on an apical negative pressure system, ultrasonic agitation, and 17% EDTA increases the removal of organic and inorganic tissue from the zones untouched by the instruments [61], which is complemented by the use of the continuous wave obturation technique for improving the sealing of the inaccessible anatomic zones [62].

## 5. Conclusion

Although the literature indicates that the occurrence of mandibular canines with two roots and two root canals is not common, these anatomical variations are associated with technical difficulties during endodontic treatment. Therefore, it is important to carefully inspect the preoperative radiograph for signs suggesting anatomical variations. Sudden loss in the continuity of the root canal lumen and a radiolucent groove in the lateral part of the root are findings that indicate the presence of more than one canal. Timely diagnosis and meticulous exploration of the internal anatomy of a mandibular canine with two roots and two root canals allow for the planning of an individualized treatment protocol, tailored to their peculiar morphology, focused on avoiding excessive weakening or perforation of the roots.

## Conflicts of Interest

The authors declare that they do not have any conflicts of interest regarding the publication of this paper.

## References

- [1] J. Abduo, M. Tennant, and J. Mcgeachie, "Lateral occlusion schemes in natural and minimally restored permanent dentition: a systematic review," *Journal of Oral Rehabilitation*, vol. 40, no. 10, pp. 788–802, 2013.
- [2] M. A. Versiani, J. D. Pécora, and M. D. Sousa-Neto, "Micro-computed tomography analysis of the root canal morphology of single-rooted mandibular canines," *International Endodontic Journal*, vol. 46, no. 9, pp. 800–807, 2013.
- [3] F. J. Vertucci, "Root canal anatomy of the human permanent teeth," *Oral Surgery, Oral Medicine, Oral Pathology*, vol. 58, no. 5, pp. 589–599, 1984.
- [4] M. Aminsobhani, M. Sadegh, N. Meraji et al., "Evaluation of the root and canal morphology of mandibular permanent anterior teeth in an Iranian population by conebeam computed tomography," *Journal of Dentistry*, vol. 10, no. 4, pp. 358–366, 2013.
- [5] M. Altunsoy, E. Ok, B. G. Nur, O. S. Aglarci, E. Gungor, and M. Colak, "A cone-beam computed tomography study of the root canal morphology of anterior teeth in a Turkish population," *European Journal of Dentistry*, vol. 8, no. 3, pp. 302–306, 2014.
- [6] T. Han, Y. Ma, L. Yang, X. Chen, X. Zhang, and Y. Wang, "A study of the root canal morphology of mandibular anterior teeth using cone-beam computed tomography in a Chinese subpopulation," *Journal of Endodontics*, vol. 40, no. 9, pp. 1309–1314, 2014.
- [7] E. J. N. L. da Silva, R. W. Q. de Castro, Y. Nejaim et al., "Evaluation of root canal configuration of maxillary and mandibular anterior teeth using cone beam computed tomography: An in-vivo study," *Quintessence International*, vol. 47, no. 1, pp. 19–24, 2016.
- [8] A. Soleymani, N. Namaryan, E. Moudi, and A. Gholinia, "Root canal morphology of mandibular canine in an Iranian population: A CBCT assessment," *Iranian Endodontic Journal*, vol. 12, no. 1, pp. 92–95, 2017.
- [9] F. Pineda and Y. Kuttler, "Mesiodistal and buccolingual roentgenographic investigation of 7,275 root canals," *Oral Surgery, Oral Medicine, Oral Pathology*, vol. 33, no. 1, pp. 101–110, 1972.
- [10] D. Green, "Double canals in single roots," *Oral Surgery, Oral Medicine, Oral Pathology*, vol. 35, no. 5, pp. 689–696, 1973.
- [11] K. Kerekes and L. Tronstad, "Morphometric observations on root canals of human anterior teeth," *Journal of Endodontics*, vol. 3, no. 1, pp. 24–29, 1977.
- [12] R. W. Hession, "Endodontic morphology. II. A radiographic analysis," *Oral Surgery, Oral Medicine, Oral Pathology*, vol. 44, no. 4, pp. 610–620, 1977.
- [13] R. W. Hession, "Endodontic morphology. IV. A comparative study," *Oral Surgery, Oral Medicine, Oral Pathology*, vol. 44, no. 6, pp. 915–930, 1977.
- [14] F. J. Vertucci, "Root canal anatomy of the mandibular anterior teeth," *The Journal of the American Dental Association*, vol. 89, no. 2, pp. 369–371, 1974.
- [15] J. D. Pécora, M. D. Sousa Neto, and P. C. Saquy, "Internal anatomy, direction and number of roots and size of human mandibular canines," *Brazilian dental journal*, vol. 4, no. 1, pp. 53–57, 1993.
- [16] J. A. Matzer, *Internal and external anatomy study of the teeth of indian Maya descendents from Guatemala Republic [M.sc. Thesis]*, University of São Paulo, Faculty of Odontology of Ribeirão Preto, Department of Restorative Dentistry, 1993, <http://www.forp.usp.br/restauradora/Teses/Matzer/matzerm.html>.
- [17] M. K. Calişkan, Y. Pehlivan, F. Sepetcioglu, M. Turkun, and S. Ş. Tuncer, "Root canal morphology of human permanent teeth in a Turkish population," *Journal of Endodontics*, vol. 21, no. 4, pp. 200–204, 1995.
- [18] V. Sikri and V. Kumar, "Permanent human canines: configuration and deviations of root canals: an in-vitro study," *Journal of Conservative Dentistry*, vol. 6, no. 4, pp. 151–152, 2003.
- [19] S. Sert and G. S. Bayirli, "Evaluation of the root canal configurations of the mandibular and maxillary permanent teeth by gender in the Turkish population," *Journal of Endodontics*, vol. 30, no. 6, pp. 391–398, 2004.
- [20] S. Sert, V. Aslanalp, and J. Tanalp, "Investigation of the root canal configurations of mandibular permanent teeth in the Turkish population," *International Endodontic Journal*, vol. 37, no. 7, pp. 494–499, 2004.

- [21] G. S. H. Oliveira and L. S. Lorio, "Internal anatomy study of mandibular canines," *Ciência Odontológica Brasileira*, vol. 10, no. 4, pp. 37–42, 2007.
- [22] S. Rahimi, A. S. Milani, S. Shahi, Y. Sergiz, S. Nezafati, and M. Lotfi, "Prevalence of two root canals in human mandibular anterior teeth in an Iranian population," *Indian Journal of Dental Research*, vol. 24, no. 2, pp. 234–236, 2013.
- [23] N. S. Amardeep, S. Raghu, and V. Natanasabapathy, "Root canal morphology of permanent maxillary and mandibular canines in indian population using cone beam computed tomography," *Anatomy Research International*, vol. 2014, pp. 1–7, 2014.
- [24] G. A. Vawter, "Dental anomalies," *Dental Cosmos*, vol. 28, no. 1, p. 64, 1886.
- [25] G. A. Koskins, "Cuspids with two roots," *Dental Cosmos*, vol. 68, no. 7, p. 403, 1926.
- [26] R. R. Slowey, "Radiographic aids in the detection of extra root canals," *Oral Surgery, Oral Medicine, Oral Pathology*, vol. 37, no. 5, pp. 762–772, 1974.
- [27] M. Rahmatulla and A. H. Wyne, "Bifid roots in a mandibular canine: report of an unusual case," *The Saudi Dental Journal*, vol. 5, no. 2, pp. 77–78, 1993.
- [28] C. D'Arcangelo, G. Varvara, and P. De Fazio, "Root canal treatment in mandibular canines with two roots: A report of two cases," *International Endodontic Journal*, vol. 34, no. 4, pp. 331–334, 2001.
- [29] L. Wang, R. Zhang, and B. Peng, "Clinical features and treatment of mandibular canines with two root canals: two case reports," *Chinese Journal of Dental Research*, vol. 12, no. 1, pp. 61–62, 2009.
- [30] F. R. Victorino, R. A. Bernardes, J. V. Baldi et al., "Bilateral mandibular canines with two roots and two separate canals - Case report," *Brazilian Dental Journal*, vol. 20, no. 1, pp. 84–86, 2009.
- [31] G. H. Oporto V., R. E. Fuentes F., and C. C. Soto P., "Tooth root and pulp canal anatomical variations," *International Journal of Morphology*, vol. 28, no. 3, pp. 945–950, 2010.
- [32] M. Maden, A. Savgat, and G. Görgül, "Radiculomegaly of permanent canines: Report of endodontic treatment in OFCD syndrome," *International Endodontic Journal*, vol. 43, no. 12, pp. 1152–1161, 2010.
- [33] O. C. Andrei, R. Margarit, L. Daguci, R. Mărgărit, and L. Dăguci, "Treatment of a mandibular canine abutment with two canals," *Romanian Journal of Morphology and Embryology*, vol. 51, no. 3, pp. 565–568, 2010.
- [34] A. Gaikwad, "Endodontic treatment of mandibular canine with two canals - a case report," vol. 3, pp. 118–119, 2011.
- [35] D. R. Fonseca, L. G. Sena, M. H. Santos, and P. F. Goncalves, "Furcation lesion in a mandibular canine," *General Dentistry*, vol. 59, no. 4, pp. e173–e177, 2011.
- [36] A. Bhardwaj and A. Bhardwaj, "Mandibular canines with two roots and two canals. A case report," *International Journal of Dental Clinics*, vol. 33, pp. 77–78, 2011.
- [37] O. C. Andrei, R. Mărgărit, and I. M. Gheorghiu, "Endodontic treatment of a mandibular canine with two roots," *Romanian Journal of Morphology and Embryology*, vol. 52, no. 3, pp. 923–926, 2011.
- [38] N. Saberi, "Mandibular canine with two roots and two apically separating canals," *Endodontic Practice*, vol. 14, no. 3, pp. 19–23, 2011.
- [39] P. P. Moogi, R. S. Hegde, B. R. Prashanth, G. V. Kumar, and N. Biradar, "Endodontic treatment of mandibular canine with two roots and two canals," *Journal of Contemporary Dental Practice*, vol. 13, no. 6, pp. 902–904, 2012.
- [40] R. Batra, A. Kumar, and K. Bhardwaj, "Root canal treatment in mandibular canines with two roots: A case report," vol. 3, pp. 54–56, 2012.
- [41] L. R. Ramírez-Sotelo, F. Sampaio, G. D. Roque-Torres et al., "Mandibular canine with two roots," *Revista Cubana de Estomatología*, vol. 49, no. 2, pp. 211–218, 2013.
- [42] K. Mithunjith and B. J. Borthakur, "Endodontic management of two rooted mandibular canine," *e-Journal of Dentistry*, vol. 3, no. 1, pp. 339–342, 2013.
- [43] R. Fuentes and E. Borie, "Bilateral two-rooted mandibular canines in the same individual: a case report," *International Journal of Odontostomatology*, vol. 7, pp. 471–473.
- [44] I. Stojanac, M. Premović, M. Drobac, B. Ramić, and L. Petrović, "Clinical features and endodontic treatment of two-rooted mandibular canines: Report of four cases," *Srpski Arhiv za Celokupno Lekarstvo*, vol. 142, no. 9–10, pp. 592–596, 2014.
- [45] R. Mukhaimer and N. Arandi, "Endodontic treatment of a mandibular canine with two separate roots and root canals: a case report," *Open Journal of Dentistry and Oral Medicine*, vol. 2, no. 2, pp. 38–41, 2014.
- [46] B. Ganesh, D. Sonal, S. Aditya, and H. Mithra, "Root and root canal morphology and its variation of the human mandibular canine: a literature review," *International Research Journal of Pharmacy*, vol. 5, no. 3, pp. 136–142, 2014.
- [47] A. Gandhi and S. Bhat, "A rare morphology of lower mandibular canine with two root and two root canal-a case report," *Scholars Journal of Medical Case Reports*, vol. 2, no. 6, pp. 368–370, 2014.
- [48] G. Fumei, G. Ferretti, D. Augusti, G. Augusti, and D. Re, "Endodontic retreatment of a lower canine associated with a periapical lesion: Case report of an unusual anatomy," *Giornale Italiano di Endodonzia*, vol. 28, no. 1, pp. 17–22, 2014.
- [49] N. R. Kulkarni, S. B. Kamat, S. I. Hugar, and G. S. Nanjannawar, "Mandibular canine with two roots and two root canals – a rare case," *Journal of Clinical and Diagnostic Research*, vol. 10, no. 9, pp. ZJ07–ZJ08, 2016.
- [50] W. Hess, "Formation of root canals in human teeth," *The Journal of the American Dental Association*, vol. 8, no. 9, pp. 704–734, 1921.
- [51] W. Hess, *The Anatomy of the Root-Canals of the Teeth of the Permanent Dentition*, Sons & Danielsson, London, UK, 1925.
- [52] C. Lee and G. R. Scott, "Brief communication: two-rooted lower Canines-A European trait and sensitive indicator of admixture across Eurasia," *American Journal of Physical Anthropology*, vol. 146, no. 3, pp. 481–485, 2011.
- [53] K. Gulabivala, A. Opananon, Y.-L. Ng, and A. Alavi, "Root and canal morphology of Thai mandibular molars," *International Endodontic Journal*, vol. 35, no. 1, pp. 56–62, 2002.
- [54] R. Sharma, J. D. Pécora, P. J. Lumley, and A. D. Walmsley, "The external and internal anatomy of human mandibular canine teeth with two roots," *Endodontics and Dental Traumatology*, vol. 14, no. 2, pp. 88–92, 1998.
- [55] M. A. Versiani, J. D. Pécora, and M. D. Sousa-Neto, "The anatomy of two-rooted mandibular canines determined using micro-computed tomography," *International Endodontic Journal*, vol. 44, no. 7, pp. 682–687, 2011.
- [56] F. J. Vertucci, "Root canal morphology and its relationship to endodontic procedures," *Endodontic Topics*, vol. 10, no. 1, pp. 3–29, 2005.



- [57] L. R. G. Fava and P. M. H. Dummer, "Periapical radiographic techniques during endodontic diagnosis and treatment," *International Endodontic Journal*, vol. 30, no. 4, pp. 250–261, 1997.
- [58] M. A. Martinez-Lozano, L. Forner-Navarro, and J. L. Sanchez-Cortes, "Analysis of radiologic factors in determining premolar root canal systems," *Oral Surgery, Oral Medicine, Oral Pathology, Oral Radiology, and Endodontics*, vol. 88, no. 6, pp. 719–722, 1999.
- [59] S. Patel, C. Durack, F. Abella, H. Shemesh, M. Roig, and K. Lemberg, "Cone beam computed tomography in Endodontics—a review," *International Endodontic Journal*, vol. 48, no. 1, pp. 3–15, 2015.
- [60] American Association of Endodontists, American Academy of Oral, and Maxillofacial Radiologist, "AAE and AAOMR Joint Position Statement," *Journal of Endodontics*, vol. 41, no. 9, pp. 1393–1396, 2015.
- [61] E. Park, Y. Shen, and M. Haapasalo, "Irrigation of the apical root canal," *Endodontic Topics*, vol. 27, no. 1, pp. 54–73, 2012.
- [62] M. Natera, R. Pileggi, and U. Nair, "A comparison of two gutta-percha obturation techniques to replicate canal irregularities in a split-tooth model," *Oral Surgery, Oral Medicine, Oral Pathology, Oral Radiology and Endodontology*, vol. 112, no. 5, pp. e29–e34, 2011.