

# Dermatological manifestation can be an early sign in Covid-19: Report of three cases with a novel manifestation masquerading Steven Johnson syndrome

Bhupen Barman<sup>1</sup>, Anita Marak<sup>2</sup>, Md Jamil<sup>1</sup>, Patrick S. R. Marak<sup>1</sup>,  
Gwenette Andrea War<sup>1</sup>, Arup Baruah<sup>3</sup>, Polina Boruah<sup>4</sup>

<sup>1</sup>Departments of General Medicine, <sup>2</sup>Dermatology, <sup>3</sup>General Surgery and <sup>4</sup>Biochemistry, North Eastern Indira Gandhi Regional Institute of Health and Medical Sciences (NEIGRIHMS), Shillong, Meghalaya, India

### ABSTRACT

Various dermatological manifestations have been observed in patients with Coronavirus disease (COVID-19) infection ranging from maculopapular rashes, urticaria, chickenpox-type lesions, chilblain-like, distal-limb ischemia, and livedo racemosa. While most of these cutaneous findings are self-resolving, they may aid in the timely diagnosis of this infection. We are reporting three patients presenting with dermatological features resembling (i) varicella zoster, (ii) herpes labialis, and (iii) Steven Johnson Syndrome (SJS) who were subsequently diagnosed with Covid-19 infection. The skin lesions disappeared after successful treatment of Covid-19.

**Keywords:** Clinical dermatology, Covid-19, herpes zoster (shingles, VZV)

### Introduction

As of April 10, 2021, Coronavirus disease (COVID-19) initially reported in Wuhan, China in December 2019 has been diagnosed in more than 134 million people globally.<sup>[1]</sup> The disease soon turned into a pandemic, spreading all across the boundaries because of its high rate of infectivity, high virulence, and asymptomatic transmission. On January 30, 2020, the World Health Organization (WHO) stated the outbreak of COVID-19 as a Public Health Emergency International Concern (PHEIC) and stated that it presents a great challenge for the health care communities worldwide. Coronavirus is an enveloped, positive-sense, single-stranded RNA virus and

belongs to the coronavirus family and has subgroups, namely, alpha ( $\alpha$ ), beta ( $\beta$ ), gamma ( $\gamma$ ), and delta ( $\delta$ ).<sup>[2]</sup> The virus enters cells via angiotensin-converting enzyme 2 (ACE2) receptors found on the surface of cells. The lungs are the primary site of infection for COVID-19, with protean manifestations ranging from flu-like symptoms to severe respiratory tract infection and potentially lethal acute respiratory distress syndrome (SARS-CoV-2). Interestingly, there have been significant numbers of COVID-19 cases reporting cutaneous manifestations.<sup>[3-7]</sup>

We report three patients with presentations resembling varicella zoster, herpes labialis, and Steven Johnson Syndrome (SJS) who were subsequently diagnosed with Covid-19 infection [Table 1]. Skin lesions, such as erythematous rashes, urticaria, and chicken pox-like vesicles, were reported in previous studies.<sup>[3-7]</sup> These symptoms developed at the onset of Covid-19 infection or

**Address for correspondence:** Dr. Bhupen Barman,  
Department of General Medicine, North Eastern Indira Gandhi  
Regional Institute of Health and Medical Sciences (NEIGRIHMS),  
Shillong - 793 018, Meghalaya, India.  
E-mail: drbhupenb@gmail.com

Received: 11-04-2021

Revised: 05-07-2021

Accepted: 09-07-2021

Published: 29-11-2021

#### Access this article online

##### Quick Response Code:



Website:  
www.jfmpc.com

DOI:  
10.4103/jfmpc.jfmpc\_690\_21

This is an open access journal, and articles are distributed under the terms of the Creative Commons Attribution-NonCommercial-ShareAlike 4.0 License, which allows others to remix, tweak, and build upon the work non-commercially, as long as appropriate credit is given and the new creations are licensed under the identical terms.

For reprints contact: WKHLRPMedknow\_reprints@wolterskluwer.com

**How to cite this article:** Barman B, Marak A, Jamil M, Marak PS, War GA, Baruah A, et al. Dermatological manifestation can be an early sign in Covid-19: Report of three cases with a novel manifestation masquerading Steven Johnson syndrome. J Family Med Prim Care 2021;10:4299-302.

**Table 1: Principal characteristics of our patients**

Patient's no	Age	Sex	Onset of dermatological manifestation	Treatment	RT-PCR for Covid-19	Lymphocyte count ( $10^9/l$ ) n.v. 0.71-4.53
1	34	Male	Day 3	HCQS Acyclovir	Positive	1.24
2	33	Male	Day 3	HCQS Acyclovir	Positive	1.28
3	70	Male	Day 5	Remdesivir Dexamethasone Tocilizumab LMWH	Positive	0.42

HCQS: Hydroxychloroquine; LMWH: Low molecular weight heparin; RT-PCR: Real-time polymerase chain reaction; n.v.: normal value

during the hospital stay. One patient had severe and very unique cutaneous manifestations.

### Case Report

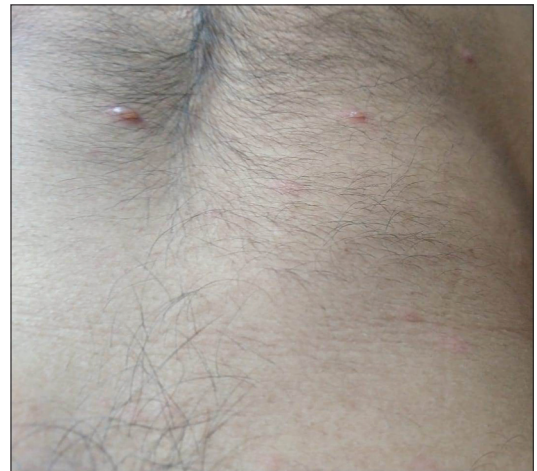Patient 1 was a 34-year-old health worker who presented to the hospital with fever ( $39^{\circ}\text{C}$ ), sore throat, and generalized weakness for two days. He had contact history with SARS-CoV-2 positive patient admitted to the hospital. He underwent nasopharyngeal swab culture and was found positive for SARS-CoV-2 on RT-PCR. On day 3, he developed asymptomatic faintly erythematous macules involving the trunk and both limbs and few discrete vesicular eruptions over an erythematous base present on the chest and back [Figure 1]. He had a history of childhood chickenpox. However, he denied having taken any drug, except paracetamol for fever. The lesions disappeared within seven days.

Patient 2 was a 33-year-old health worker with known contact with COVID-19 cases admitted because of fever, sore throat, and weakness. Nasopharyngeal swab done on day 5 was positive for Covid-19. On day 3, following fever he developed grouped vesicles over the left corner of the mouth, suggestive of herpes labialis [Figure 2]. He denied the presence of similar skin lesions previously in the past. He was started with acyclovir 400 thrice daily for five days.

Patient 3 was a 70-year-old man who presented with high-grade fever with respiratory distress for three days. He was admitted to the intensive care unit and treated with intravenous antibiotics, injection Remdesivir, and put on ventilator support. Gradually, he was weaned from the ventilator support and was put on oxygen support only. Dermatological examination revealed the presence of a few discrete to coalescent intact bullas over the back. Additionally, there were three erosions varying in size from  $1 \times 1$  cm to  $4.5 \times 3.5$  cm. Peeling of skin in a serpinginous pattern was also noted just below and above the largest erosion [Figure 3]. Nikolsky sign at the site was not performed.

### Discussion

Although the cutaneous manifestations are uncommon in COVID-19 infection, it is still evolving as more and more anecdotal case reports and case series are being reported



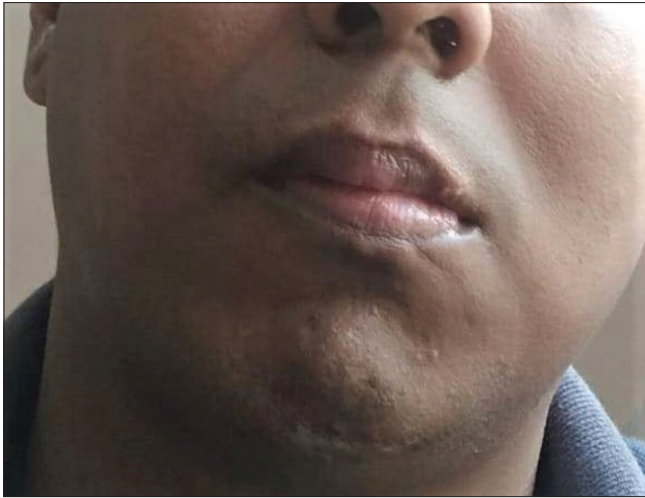
**Figure 1:** Vesicles on an erythematous base and faint erythematous macules over the chest

throughout the world with common clinical features, including fever, sore throat, dry cough, shortness of breath, easy fatigability, myalgia, and weakness seen in relatively large-scale of COVID-19 pneumonia patients.<sup>[8]</sup>

The most prominent case study of various skin manifestations of 88 confirmed COVID-19 patients from Italy was published by Recalcati *et al.* and the authors reported dermatologic manifestations in 20.4% of COVID-19 patients (18/88). The most common dermatologic presentations observed were erythematous rash (14 patients; 77.8%) with few cases of urticaria (3 patients; 16.7%) and chickenpox-like vesicle formation (1 patient; 5.6%).<sup>[9]</sup>

Our finding suggests that the most consistent cutaneous eruptions associated with COVID-19 is the vesicular eruption in all three patients with only one presenting additionally as erythematous macular rash. However, more cases are required to be observed to know the common clinical manifestations. As these lesions appeared almost within three days of onset of fever, it may be hypothesized that cutaneous manifestations can also serve as a clue in addition to fever and upper respiratory tract symptoms and prompt the clinician to consider the diagnosis and investigate early.

In the case of the second patient, whether the herpes labialis occurred concomitantly with the current infection or whether



**Figure 2:** Grouped vesicles over the corner of the upper lip on the left side

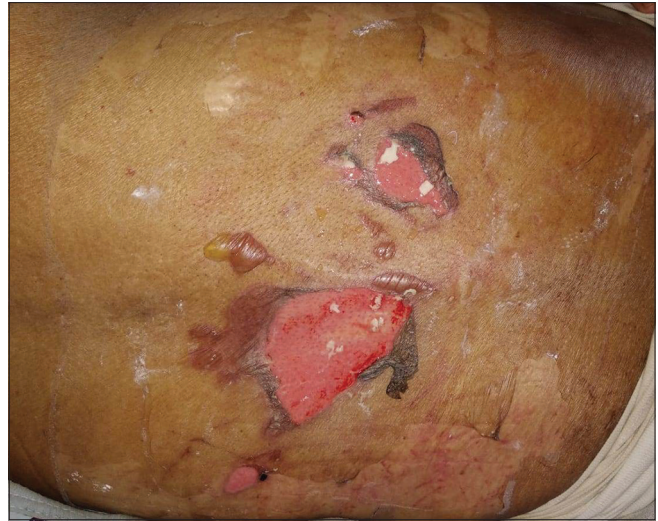it truly represents COVID-19 infection is still doubtful as we could not do a serological test to determine herpes simplex virus.

The third patient had a rather unique presentation never mentioned before in the literature. The bullas, erosions, and epidermolysis mimicked the lesions of Steven Johnson Syndrome, except that it was localized to the back. It is to be noted that this patient had a more severe form of the disease as compared to the others and this cutaneous manifestation could also be a marker of disease severity. However, it is too early to make such assumptions as more observations are required in the future.

Although the pathophysiology of COVID-19 cutaneous disturbances is not yet well known, some common theories have been described for lesions suggestive of vascular occlusions like petechiae transient livedoid eruptions, or acral ischemia presenting as perniosis-like lesions. However, determining the mechanism behind the vesicular eruptions caused by this virus is still an enigma and challenging because of its novelty. Whether this virus shares a tropism to epithelial cells in the skin with varicella zoster virus is still unknown. Speculations of the virus being transferred to the skin from respiratory sites by the lymphocytic cells and causing ballooning degeneration of the keratinocytes are preliminary as neither tzanck (or culture) nor PCR of the fluid has been done in any of the case reports of COVID-19 patients who presented with vesicles to prove that the virus is present in the skin. Additionally, although the bullas with erosions and peeling of the skin clinically mimic SJS, it is still unclear if they cause keratinocyte apoptosis.

## Conclusion

Although rare, cutaneous manifestations may represent an important feature and may occur early in COVID-19, and these lesions may be missed because of the lack of routine dermatology evaluation during the outbreak. Primary-care physicians play an



**Figure 3:** Bullas and erosions with peeling of the skin at the periphery of the erosions

important role by differentiating patients with skin lesions from those with Covid-19, making an early diagnosis and proper management at the primary-care level during the COVID-19 pandemic. Further research is required to validate and elucidate an understanding of different COVID-19-related cutaneous manifestations.

## Declaration of patient consent

The authors certify that they have obtained all appropriate patient consent forms. In the form, the patient(s) has/have given his/her/their consent for his/her/their images and other clinical information to be reported in the journal. The patients understand that their names and initials will not be published and due efforts will be made to conceal their identity, but anonymity cannot be guaranteed.

## Financial support and sponsorship

Nil.

## Conflicts of interest

There are no conflicts of interest.

## References

1. World Health Organization, Coronavirus Disease (COVID-19) Outbreak Situation. World Health Organization. 2020. Available from: <https://covid19.who.int/>. [Last accessed on 2021 Apr 10].
2. Guo YR, Cao QD, Hong ZS, Tan YY, Chen SD, Jin HJ, *et al.* The origin, transmission and clinical therapies on coronavirus disease 2019 (COVID-19) outbreak-an update on the status. *Mil Med Res* 2020;7:11.
3. Tartari F, Spadotto A, Zengarini C, Zanoni R, Guglielmo A, Adorno A, *et al.* Herpes zoster in COVID-19-positive patients. *Int J Dermatol* 2020;59:1028-9.
4. Guarneri C, Rullo EV, Pavone P, Berretta M, Ceccarelli M, Natale A, *et al.* Silent COVID-19: What your skin can reveal.

- Lancet Infect Dis 2020;21:24-5.
5. Marzano AV, Genovese G, Fabbrocini G, Pigatto P, Monfrecola G, Piraccini BM, *et al.* Varicella-like exanthem as a specific COVID-19-associated skin manifestation: Multicenter case series of 22 patients. J Am Acad Dermatol 2020;83:280-5.
  6. Sachdeva M, Gianotti R, Shah M, Bradanini L, Tosi D, Veraldi S, *et al.* Cutaneous manifestations of COVID-19: Report of three cases and a review of literature. J Dermatol Sci 2020;98:75-81.
  7. Gianotti R, Zerbi P, Dodiuk-Gad RP. Clinical and histopathological study of skin dermatoses in patients affected by COVID-19 infection in the Northern part of Italy. J Dermatol Sci 2020;98:141-3.
  8. Huang C, Wang Y, Li X, Ren L, Zhao J, Hu Y, *et al.* Clinical features of patients infected with 2019 novel coronavirus in Wuhan, China. Lancet 2020;395:497-506.
  9. Recalcati S. Cutaneous manifestations in COVID-19: A first perspective. J Eur Acad Dermatol Venereol 2020;34:e212-3.