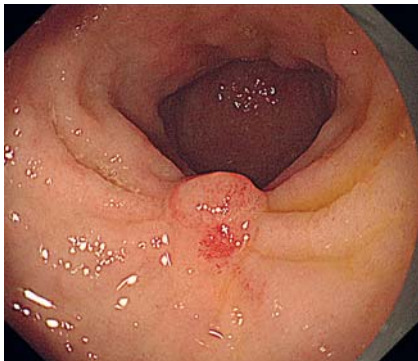
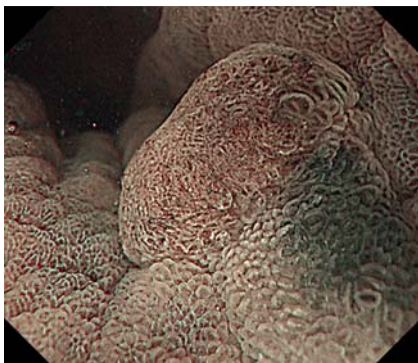


## Salvage underwater endoscopic mucosal resection for recurrent gastric cancer after endoscopic submucosal dissection

OPEN  
ACCESS



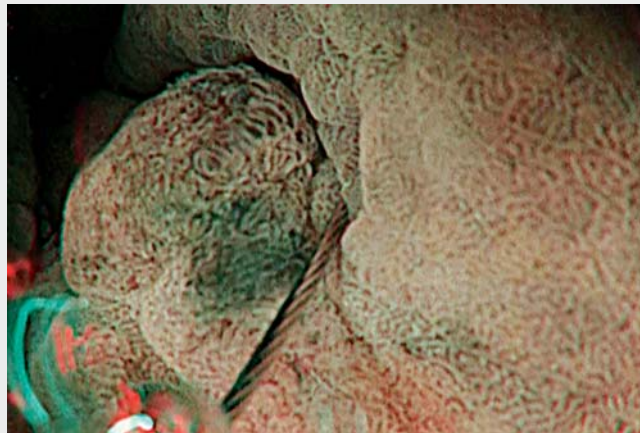
► **Fig. 1** The endoscopic image of the reddish elevated lesion at the center of the endoscopic submucosal dissection scar in the antrum.



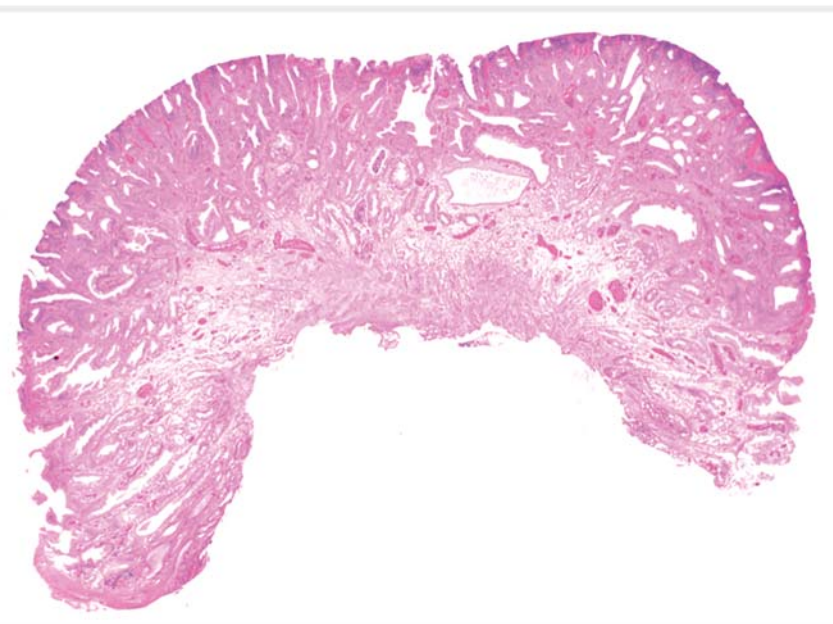► **Fig. 2** Magnifying narrow-band imaging showing an irregular micro-surface and micro-vessels.

Salvage endoscopic treatment of recurrent early gastric cancer (EGC) in scars after endoscopic submucosal dissection (ESD) is cumbersome. Conventional endoscopic mucosal resection (EMR) is usually difficult since submucosal fibrosis caused by previous treatments hinders the lifting of the lesion. ESD can be used as an alternative; however, it requires expertise. Underwater EMR was invented by Binmoeller et al. [1] and has been useful in treating recurrent colorectal polyps [2].

An 83-year-old man underwent esophagogastroduodenoscopy (EGD) for sur-



► **Video 1** A recurrent early gastric cancer treated with underwater endoscopic mucosal resection.



► **Fig. 3** The pathological image of the recurrent intramucosal well-differentiated tubular adenocarcinoma, which was completely resected.

veillance after curative endoscopic treatment for EGC. Two and a half years before the current presentation, he had undergone ESD for EGC, which was Paris 0-IIa,

5 mm in diameter, and located in the antrum. Pathological diagnosis revealed a completely resected mucosal adenocarcinoma. EGD revealed a tiny, reddish,


elevated lesion at the ESD scar center with apparent concentrations of folds in the antrum (► **Fig. 1**). On close observation using magnifying narrow-band imaging (NBI), an irregular micro-surface and micro-vessels were observed, and local recurrence was suspected (► **Fig. 2**). Biopsies were performed, and pathology revealed tubular adenocarcinoma. Time-consuming ESD was considered a burden for the patient. Underwater EMR (► **Video 1**) was performed. An upper gastrointestinal endoscopy with waterjet function (Olympus, Tokyo, Japan) was used. The intraluminal gas was evacuated, and the lumen was filled with normal saline. During snaring, NBI was used to precisely delineate the border of the lesion. After water immersion, the lesion and the surrounding mucosa floated. The lesion with sufficient margin was easily grasped with a 10-mm snare (Olympus) and cut using the Endocut Q mode with an electrosurgical unit (ERBE, Tübingen, Germany). The procedure time was 6 min. Pathological examination revealed intramucosal a well-differentiated tubular adenocarcinoma, which was completely resected (► **Fig. 3**). No adverse events were observed. Gastric underwater EMR is a useful salvage measure for treating recurrent EGC.

Endoscopy\_UCTN\_Code\_TTT\_1AO\_2AG

## Competing interests

Y. Takeuchi received honoraria for lectures from Olympus, Japan. The other authors disclose no financial relationships or conflicts of interest relevant to this publication.

## The authors

**Gentarō Tanabe<sup>1</sup>, Shunsuke Yamamoto<sup>1</sup> , Yoji Takeuchi<sup>2</sup>, Eiji Mita<sup>1</sup>**

- 1 Department of Gastroenterology and Hepatology, National Hospital Organization Osaka National Hospital, Osaka, Japan
- 2 Department of Gastrointestinal Oncology and Department of Genetic Oncology, Division of Hereditary Tumors, Osaka International Cancer Institute, Osaka, Japan

## Corresponding author

**Shunsuke Yamamoto, MD, PhD**

Department of Gastroenterology and Hepatology, National Hospital Organization Osaka National Hospital, 2-1-14 Houenzaka, Chuo-ku, Osaka, 540-0006, Japan  
shun0515suke@gmail.com

## References

- [1] Binmoeller KF, Weilert F, Shah J et al. “Underwater” EMR without submucosal injection for large sessile colorectal polyps (with video). *Gastrointest Endosc* 2012; 75: 1086–1091
- [2] Kim HG, Thosani N, Banerjee S et al. Underwater endoscopic mucosal resection for recurrences after previous piecemeal resection of colorectal polyps (with video). *Gastrointest Endosc* 2014; 80: 1094–1102

## Bibliography

Endoscopy 2022; 54: E792–E793

DOI 10.1055/a-1806-1860

ISSN 0013-726X

published online 25.4.2022

© 2022. The Author(s).

This is an open access article published by Thieme under the terms of the Creative Commons Attribution-NonDerivative-NonCommercial License, permitting copying and reproduction so long as the original work is given appropriate credit. Contents may not be used for commercial purposes, or adapted, remixed, transformed or built upon. (<https://creativecommons.org/licenses/by-nc-nd/4.0/>)

Georg Thieme Verlag KG, Rüdigerstraße 14, 70469 Stuttgart, Germany



## ENDOSCOPY E-VIDEOS

<https://eref.thieme.de/e-videos>



*Endoscopy E-Videos* is an open access online section, reporting on interesting cases and new techniques in gastroenterological endoscopy. All papers include a high quality video and all contributions are freely accessible online. Processing charges apply (currently EUR 375), discounts and waivers acc. to HINARI are available.

This section has its own submission website at <https://mc.manuscriptcentral.com/e-videos>