

Effects of the oral administration of nonpolar extract from *Ardisia squamulosa* Presl (Myrsinaceae) leaves on spermatogenesis in rats

Dennis D. Raga^{1,2}, Glorina N. Pocsidio², Annabelle A. Herrera²

¹Biology Department, School of Science and Engineering, Ateneo de Manila University, Loyola Heights Quezon City 1101 Philippines,

²Institute of Biology, College of Science, University of the Philippines, Diliman Quezon City 1101 Philippines

Submitted: 20-04-2011

Revised: 14-05-2011

Published: 15-11-2011

ABSTRACT

Background: Several *Ardisia* species have been found to possess numerous bioactivities but their reproductive toxicity has been poorly explored. In the present study, the effects of the leaf hexane extract of Philippine indigenous *Ardisia squamulosa* on epididymal sperm count, %viability and %aberration of sperms and weights of seminal vesicle, cauda epididymis, and testes in addition to the weights of liver, kidney, and body were evaluated. **Methods:** The extracts at daily dose levels of 1, 10, and 100 mg/Kg BW in 10% polysorbate-80 in corn oil were administered by gavage for 8 successive days to 8-10 weeks old male SD rats and sacrificed after 9 days. Daily body weights and final organ weights were measured. Sperm from the *cauda* epididymis was extracted and measured according standard sperm parameters (sperm count, morphology, viability and membrane integrity). **Results:** Significant findings were the decline of left epididymal sperm count to testis weight ratio and increase in %sperm morphological aberration from both *cauda* epididymis obtained with the 10 mg/Kg BW dose. **Conclusion:** The hexane extract from *Ardisia squamulosa* had significant effect on sperm count but with negligible effect on sperm morphology and viability.

Key words: Myrsinaceae, spermatogenesis, sperm count, sperm morphology

Access this article online

Website:

www.phcogres.com

DOI:

10.4103/0974-8490.89747

Quick Response Code:



INTRODUCTION

The genus *Ardisia* Swartz belongs to the family Myrsinaceae. *Ardisia* has 68 recorded species in the Philippines,^[1] 60 of which are endemic. These are primarily distributed in Mindoro, Polilio, Samar, Panay, Mindanao, Palawan, Leyte, Biliran, Nueva Ecija, Laguna, Bicol, Ilocos Sur, Ilocos Norte, Sambali, Negros Occidental, Negros Oriental, Cebu, Agusan, Pampanga, Batangas, Cagayan, and some other areas in Luzon. It is commonly known as Tagpo. It is identified, however, into several vernacular names, such as *Tagpong pugot* (*A. brevipetiolata* Merr.), *Puyakang mangyan* (*A. calavitensis* Merr.), *Tagpong lumotan* (*A. geissanthoides* Mez.), *Dapui* (*A. saligna* Mez.), *Panabon* (*A. serrata* Pers.), *Sagoi* (*A. verrucosa* Presl.), *Katipu* (*A. warburgiana* Mez.),

Tagpo (*A. whitfordii* Mez., and *Ardisia squamulosa* Presl.), *Aumasin* (*Ardisia pyramidalis* Pers.).^[2] *Ardisia* leaves are eaten as vegetable, used as greens for salad, or cooked with meat or fish.^[2] The flowers and fruits may be cooked and used as flavoring for fish. Young leaves are also eaten by ruminants, while the fruits are eaten by monkeys and wild pigs and birds.^[2] *A. pyramidalis* fruit approximate analysis (Catibog, 1978) revealed high fiber content (37.99%), crude protein (13.50%), crude fat (0.41%), and some minerals, such as Ca (0.96%), P (0.21%), K (1.90%), and N (2.16%). Chemical analysis on the Dichloromethane (DCM) extract of leaves afforded spinasterul acetate, spinasterol, α -amyrin, β -amyrin, bauerenol, squalene, and lutein.^[3]

The genus *Ardisia* is a good source of health promoting compounds and potent phytopharmaceuticals.^[4] Recent studies revealed high anticancer properties in a number of *Ardisia* species tested. Gonzales De Mejia *et al.* reported that the polyphenolic compounds and flavonoids present in *A. compressa* tea were cytotoxic on human colorectal carcinoma (HT-29 and Caco-2. LC-MS) by catalytic

Address for correspondence:

Mr. Dennis D. Raga, Biology Department, School of Science and Engineering, Ateneo de Manila University, Loyola Heights Quezon City 1101 Philippines.
E-mail: dennis.diana.raga@gmail.com

inhibition of DNA topoisomerase.^[5] The aqueous extracts (tea) of *A. compressa* leaves was found to be cytotoxic on HepG2 cells by the inhibition of topoisomerase II acting as catalytic inhibitors,^[6] *in vitro* antioxidant defense against 1-nitropyrene and benomyl-induced cytotoxicity in rat hepatocytes,^[7,8] anticarcinogenesis in the liver.^[6] In addition, *A. compressa* also has hepatoprotective property.^[7] *Ardisia arborescens* was found to have antipyretic properties,^[9] while *A. colorata* have been found to be hepatoprotective, mucolytic, and antidiarrheal.^[10] A number of biological activities have been reported for *Ardisia crenata* where it was found to induce uterine contraction,^[11] platelet aggregation, and induce blood pressure lowering,^[12] cAMP inhibition (Jia *et al.*, 1994),^[13] and antithrombin activity.^[14] The methylene chloride:methanol extracts from the leaves of *A. crenata* was found to have antithrombin activity.^[14] Horgen *et al.*, reported the presence of a novel compound ardisenone isolated from twigs and leaves of *A. ivahigensis*. Furthermore, Ardisenone was found to have significant cytotoxic activity in murine cells and later identified to have anticancer property as well. Spinasterol, a mixture of α -amyrin, β -amyrin, and bauerenol and triglycerides from *A. pyramidalis* have been found to have positive vascular damage in duck chorioallantoic membrane.^[3] *Ardisia squamulosa* (Myrsinaceae) and was found to be anti-HSV and anti-ADV but was most effective in inhibiting ADV-8 replication.^[15]

The leaves of *A. squamulosa* is commonly consumed as tea preparations as a traditional medicinal plant in Taiwan.^[13] Despite the numerous bioactivities of this genus, there have been no reports on the reproductive toxicity, anti-androgenic and antispermatogenic potentials of Philippine endemic *Ardisia* species particularly *A. squamulosa*. The main purpose of this study is to elucidate on the male reproductive toxicity assessment of the nonpolar extract from *A. squamulosa*.

MATERIALS AND METHODS

Plant material and preparation of nonpolar extract

A. squamulosa leaves from Kanawan, Bataan, was collected in April, 2008, and identified at the Jose Vera Santos Herbarium Collection of the Institute of Biology, College of Science, University of the Philippines Diliman, Quezon City. The air-dried leaves (800 g) were pulverized and soaked in 2 L *n*-hexane (Ajax FineChem, Taren Point, NSW, Australia) for 3 days, then filtered. The nonpolar extract was obtained to specifically investigate on the nonpolar constituents that might have solubilized in a solution in traditional preparations. The filtrate was then concentrated under vacuum to afford 10.38 g of nonpolar extract. The extract was further liberated from the extracting solvent

by desiccation. Ten percent polysorbate 80 (10% P80, Ajax FineChem, Taren Point, NSW, Australia) in corn oil was used as vehicle and kept in cold storage until time of use.

Animals

A total of 24 male (8–10 weeks old) laboratory-bred Sprague–Dawley rats (*Rattus norvegicus*) weighing an average of 166.56 ± 20.74 g at the beginning of the study from parent stocks obtained from the Experimental Animal House of the Bureau of Food and Drugs, Muntinlupa City, Philippines, were used in the study. The animals were acclimatized for 14 days under normal conditions with 12 h daylight and 12 h darkness, with free access to food pellets (28% Crude Protein, 14% Crude Fat) and water.

Doses and treatments

The animals were randomized into 4 groups ($n = 6$). Control (27 ml/kg BW 10% P80) and the 3 different doses of the extract (1, 10, and 100 mg/kg BW) were administered orally for 8 days. All procedures regarding handling of the test animals were in accordance with the existing guidelines of the Philippine Association of Laboratory Animal Science^[16] for care and use of laboratory animals and with Administrative Order 40 of the Bureau of Animal Industry relative to Republic Act No. 8485.

Testes to body weight ratio

The rats were weighed individually everyday and before the test animals were sacrificed. The rats were dissected under light ether anesthesia to excise the testes from the animals. Testes were cleaned of superficial fatty layer, weighed, and then transferred into 10% formalin solution. The testes–body weight ratio was determined according to the equation given by Yakubu *et al.* Organ:BW ratio = weight of testes/weight of the animal.^[17]

Sperm number, morphology, viability, and membrane integrity

The cauda epididymis was dissected and homogenated in 1 mL cold Phosphate Buffer Glucose Saline (PBGS: NaCl, 50 mM/L; Na_2HPO_4 , 200 mM/L; glucose, 20 mM/L; KH_2PO_4 , 26 mM/L) and stored at 4°C for 24 h to allow sperm to be released from the walls. Sperm number was estimated using Neubauer hemocytometer by counting the number of cells in the five 1 mm squares in 10^1 dilution (10 μL sperm suspension in 1 mL PBGS) and computed as concentration/mL = dilution factor \times count in 5 squares \times 0.05×10^6 . Sperm viability and morphology was evaluated according to the procedure of Bjorndahl *et al.* by staining 15 μL of epididymal sperm suspension with eosin counter stained with nigrosin spread on a microscope slide.^[18] The percentages of alive (white) and dead (red) cells were calculated by at least counting 200 cells. Sperms with intact membrane do not undergo staining, which shows the integrity of cell membrane.^[19]

Statistics

The results were analyzed by one-way analysis of variance using SPSS version 13 for Windows. Significant differences within group variables were determined by Tukey's multiple comparison test. Results were considered significant at 5% level of probability ($P < 0.05$). The data were presented as mean \pm SD at 0.05 level of significance.

RESULTS

General observations

The test animals did not exhibit any sign of toxicity, such as weight loss, poor grooming, depression, slow reflex response, and other behavioral manifestations described by Guevarra *et al.* The animals did not reveal any sign of intoxication as well. The rats did not reveal observable signs of central nervous system (CNS) depression and zero mortality. There was also a significant increase in the average daily body weights [Figure 1], indicating that the test animals were in good condition at the start and at the end of the study. This indicates that the dosages administered were below toxic level. In addition, none of the animals died from the time of acclimatization until the end of the experiment.

Analysis of the liver to body weight ratio reveals that there was no significant difference ($P = 0.702$) between the control and the experimental groups. The same is true for both right ($P = 0.345$) and left ($P = 0.594$) kidney to body weight ratios [Table 1]. This further indicates that *A. squamulosa* is not toxic at the dose levels tested. Histological analysis however was not performed.

After daily oral dose administrations of *A. squamulosa* nonpolar extract, the rats given an oral dose of 10 and 100 mg/kg BW/day obtained slightly lower seminal vesicle

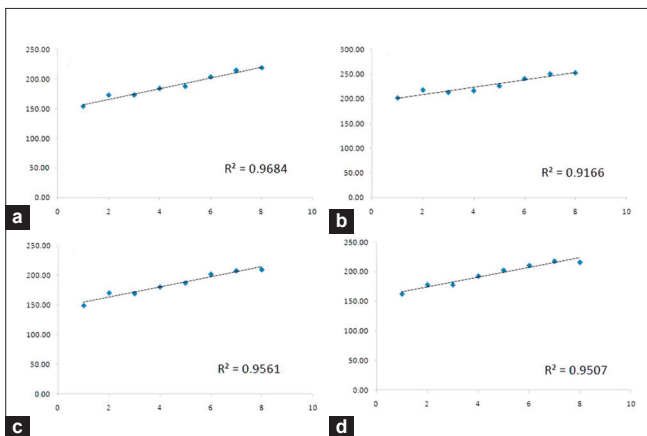


Figure 1: Body weight gain of male SD rats administered with (a) corn oil, (b) 1 mg/kg BW/d, (c) 10 mg/kg BW/d, and (d) 100 mg/kg BW/d *A. squamulosa* extract for 7 days.

to BW ratios as compared to the 1 mg dose and control. The ratios however revealed no significant differences ($P = 0.058$) with that of the control. The right ($P = 0.503$) and the left testes ($P = 0.538$) also revealed no significant differences with that of the control. The right ($P = 0.068$) and left ($P = 0.081$) cauda epididymis of the experimental group revealed slightly lower ratios but the differences were too little to attain statistical significance [Table 2]. A net increase in the ratio may indicate increased activity of the reproductive organ relative to spermatogenesis. It is evident that the reduction of organ to BW ratio compared to the control was not totally different at all which indicates that the organ was not affected by oral administration of the extract.

Sperm count in the left cauda epididymis indicates that the number of sperm was significantly affected ($P = 0.02$) by the nonpolar extract. The right cauda epididymis, however, was not affected by the oral administration of the extract ($P = 0.058$). Table 3 presents the sperm count in the left and right cauda epididymis, %viability, and %aberration. Rats administered with the lowest dose in both right ($41.50 \times 10^6 \pm 5.82$ cells/mL) and left ($49.58 \times 10^6 \pm 6.01$ cells/mL) epididymis obtained a slightly higher mean compared to the control (right: $35.75 \times 10^6 \pm 7.34$ cells/mL, left: $43.67 \times 10^6 \pm 5.33$ cells/mL) but such difference was not enough to obtain significant statistical difference. Those treated with the median dose obtained the lowest sperm count ($27.42 \times 10^6 \pm 7.14$ cells/mL and $20.83 \times 10^6 \pm 7.1$ cells/mL, right and left, respectively), which is significantly different ($P = 0.062$) with that of the control but may or may not be different with that of the highest dose ($33.25 \times 10^6 \pm 7.42$ cells/mL, $33.42 \times 10^6 \pm 7.09$ cells/mL, right and left, respectively). Analysis of sperm production compared to testes weight is concomitant with the sperm count data in the right sperm count versus testes weight, which was not affected by the nonpolar extract ($P = 0.0716$) but the sperm count in the left epididymis, however, was significantly affected ($P = 0.02$). The control (32.30 ± 3.94) and the lowest (32.62 ± 3.8) dose are not significantly different while the median (14.05 ± 5.09) and the highest

Table 1: Liver and kidney to body weight ratio

Treatment	Average BW increase	Liver	Kidney	
			Right	Left
10% P80	4.7 \pm 0.36 ^a	4.35 \pm 0.35	0.40 \pm 0.02	0.38 \pm 0.03
1 mg/kg BW extract	3.07 \pm 0.25 ^b	3.95 \pm 0.18	0.37 \pm 0.02	0.38 \pm 0.02
10 mg/kg BW extract	4.9 \pm 0.34 ^a	4.22 \pm 0.27	0.42 \pm 0.02	0.41 \pm 0.04
100 mg/kg BW extract	4.16 \pm 0.38 ^{ab}	4.04 \pm 0.20	0.40 \pm 0.02	0.34 \pm 0.04

Means followed by the same letter superscript are not significantly different using Tukey's test ($P > 0.05$) at $\alpha = 0.05$

Table 2: Reproductive organ to body weight ratio

Treatment	Seminal vesicle	Testes		Cauda epididymis	
		Right	Left	Right	Left
10% P80	0.46 ± 0.06	0.63 ± 0.01	0.62 ± 0.02	0.11 ± 0.01	0.11 ± 0.01
1 mg/kg BW extract	0.44 ± 0.04	0.63 ± 0.02	0.60 ± 0.03	0.08 ± 0.00	0.08 ± 0.00
10 mg/kg BW extract	0.29 ± 0.04	0.66 ± 0.03	0.67 ± 0.04	0.09 ± 0.01	0.12 ± 0.01
100 mg/kg BW extract	0.33 ± 0.05	0.60 ± 0.04	0.64 ± 0.04	0.08 ± 0.01	0.09 ± 0.01

There was no significant difference ($P > 0.05$) at $\alpha = 0.05$

Table 3: Sperm production profile

Treatment	Sperm count ($n \times 10^6$ cells/mL)		Sperm count to testes weight ratio	
	Right	Left	Right	Left
10% P80	35.75±7.34	43.67±5.33 ^b	25.80±6.26	32.3±3.94 ^a
1 mg/kg BW extract	41.50±5.82	49.58±6.01 ^a	26.38±3.7	32.62±3.8 ^a
10 mg/kg BW extract	27.42±7.14	20.83±7.1 ^b	18.90±4.79	14.05±5.09 ^b
100 mg/kg BW extract	33.25±7.4	33.42±7.09 ^{ab}	24.35±5.13	23.43±4.76 ^{ab}

Means followed by the same letter superscript are not significantly different using Tukey's test at $\alpha = 0.05$

(23.43±4.76) dose may have overlapping similarities. Although statistical results indicate that sperm production may have been partially inhibited by the increase in dosage of the extract [Table 3], an unclear dose response is still evident between 10 and 100 mg/kg BW, which may be due to the crude nature of the compound.

Eosin and nigrosin cell viability staining reveals that there is no significant ($P > 0.05$) difference between the number of living and dead cells at the time of eosin infiltration with 100% living cells observed in 200 cells counted. The occurrence of specific aberrations such as curled distal part of the flagella were noted and found to have significantly ($P = 0.001$) different with the control. There were no observable signs of aberration at the lowest dose (0.0% ± 0.0%) in both right and left *cauda* epididymis. The median dose, however, revealed 1.25% ± 0.11% aberration in the right and 1.67% ± 0.11% in the left *cauda* epididymis, while 0.92% ± 0.38% was observed at the right *cauda* epididymis. The observed values, however, are below the normal threshold level for abnormal sperm, which is 30% [Table 4].

DISCUSSION

The oral treatment of *A. squamulosa* nonpolar extract reveals no observable signs of toxicity on male rats. This was particularly based on the net change in daily body weights along with liver, kidney and reproductive organ weights. A significant decline in organ and body weights correlates to the impairment of reproductive functions.^[20] The current study reports that the nonpolar extract from *A. squamulosa*, there was a regular increase in daily body weights in all of the test organisms for a total of 8 treatment

Table 4: Sperm quality assessment

Treatment	% Viability		% Aberration	
	Right	Left	Right	Left
10% P80	100±0.0	100±0.0	0.0±0.0 ^b	0.0±0.0 ^b
1 mg/kg BW extract	100±0.0	100±0.0	0.0±0.0 ^b	0.0±0.0 ^b
10 mg/kg BW extract	100±0.0	100±0.0	1.25±0.11 ^a	1.67±0.11 ^a
100 mg/kg BW extract	100±0.0	100±0.0	0.92±0.38 ^a	0.0±0.0 ^b

Means followed by the same letter superscript are not significantly different using Tukey's test at $\alpha = 0.05$

days. The extract did not show any toxic effects that may have been observable in the rat behavioral activity for 24 h or during the treatment periods. There was neither sign of CNS toxicity nor any signs of depression. Rats from the median and highest dose, however, revealed signs of diarrhea at the beginning of treatment but eventually recovered during the succeeding days. The same was observed in one of our preliminary experiments on the assessment of reproductive and developmental toxicity in female mice (data not shown). The ratio of reproductive organ weight to body weight remained similar with the control.

There was a slight reduction of sperm number in the median and the highest dose but such are enough to attain statistical significance. The unclear dose response, however, between 10 and 100 mg/kg BW of the crude sample was most probably due to the crude nature of the extract limiting the relative solubility of the substance. The extract on the other hand may contain possible antispermatogenic compounds similar to what was reported by Calle *et al.* when he isolated rapanone and tested it on male mice. Rapanone and embelin are major compounds in the genus *Ardisia*. Embelin is particularly found in *A. crenata* and

A. japonica,^[21,22] whereas rapanone is present in *A. macrocarpa*,^[23] *A. crenata*,^[21] and *A. japonica*.^[21] Rapanone and embelin have similar antifertility and abortive effects on mice.^[24] Similarly, Gupta and colleagues (1989) reported embelin to be antispermatogenic in rats.^[25] Embelin also had little effect on normal prostate epithelial cells while inhibition of cell growth was reported along with apoptosis and activation of caspase-a in human prostate cancer cells.^[26] This may partly explain why there was slight decline in organ weights of those rats given 10 and 100 mg/kg BW/day. The anticancer properties of the genus *Ardisia* may be one of the reasons for the decline of spermatogenic activity in the median and high dose treatments. *Ardisia crispa*^[27] and *A. japonica*^[26] have been reported to have antimetastatic and antitumor activities. Ardisin is a major component found in *A. compressa* (Ramirez-Mares and Gonzalez de Mejia, 2003)^[5] and *A. japonica*^[23] (Liang et al, 1979 In Kobayashi et al) Horgen et al. reported the presence of a novel compound ardisenone isolated from twigs and leaves of *A. imahigensis*.^[28] Furthermore, ardisenone was found to have significant cytotoxic activity in murine cells and later was identified to have anticancer property as well.

CONCLUSIONS

The current study presents that the nonpolar extract from *A. squamulosa* has no toxic effects on rats administered orally. This was particularly based on the observation of the daily body weight increase and liver and kidney weights to body weight ratio which are not significantly different with the control. Although there was a slight decline in the reproductive organ weight to body weight ratio, reproductive organs in general were unaffected by oral administration of the nonpolar extract. These findings are complimented by 100% viability of cells assayed for membrane integrity. Aberration was affected by 10 and 100 mg/kg BW but is still far below the normal threshold for the level of abnormal sperm morphology. There was an obvious decline in the spermatogenic activity, which may be accounted for the antitumor properties of rapanone and embelin, which are major constituents of the genus *Ardisia*. Further tests, however, should be conducted to confirm the specific effects on spermatogenesis. It is suggested that histological analysis be conducted to determine the effects of the extract on A and B spermatogonia, epithelialization of spermatogonial cells, and lumen diameter. *A. squamulosa* extracts obtained from solvents of higher polarity, such as dichloromethane and methanol may be tested as well to determine the probable activities of other compounds that are relatively insoluble in *n*-hexane.

REFERENCES

- Merrill ED. An enumeration of Philippine flowering plants. Vol 3. Manila Bureau of Printing; 1967. p. 256-66.
- Food and Agriculture (FAO) Forestry Paper. Food and fruit-bearing forest species 2: Examples from Southeastern Asia. United Nations, 1984.
- Raga DD, Alimboyoguen AB, Shen CC, Ragasa CY. Triterpenoids and an anti-angiogenic sterol from *Ardisia pyramidalis* Cav. Pers. Philipp Agric Sci 2011;94:2, 103-110.
- Kobayashi H, Gonzalez De Mejia E. The genus *Ardisia*: A novel source of health promoting compounds and phytopharmaceuticals. J Ethnopharmacol 2005;96:347-54.
- Gonzales De Mejia E, Chandra S, Ramirez-Mares MV, Wang W. Catalytic inhibition of human DNA topoisomerase by phenolic compounds in *Ardisia compressa* extracts and their effect on human colon cancer cells. Food Chem Toxicol 2006;44: 1191-203.
- Ramirez-Mares MV, Chandra S, Gonzalez De Mejia E. *In vitro* chemopreventive activity of *Camellia sinensis*, *Ilex paraguariensis* and *Ardisia compressa* tea extracts and selected polyphenols. Mutat Res 2004;554:53-65.
- Ramirez-Mares MV, Fatell S, Villa-Trevino S, Gonzalez De Mejia E. Protection of extract from leaves of *A. Compressa* against benomyl-induced cytotoxicity and genotoxicity in cultured rat hepatocytes. Toxicol In Vitro 1999;13:889-96.
- Gonzalez de Mejia E, Ramirez-Mares MV, Nair MG. Topoisomerase I and II enzyme inhibitory aqueous extract of *Ardisia compressa* and ardisin protect against benomyl oxidation of hepatocytes. J Agric Food Chem 2002;50:7714-9.
- Wu ZY, Zhou TY, Xiao PG. Xingua Bencao Gangyao (In Chinese). List of Chinese Medicine Herb. Vol 1. Shanghai: Shanghai Scientific and Technological Press; 1988. p. 382.
- Sumino M, Sekine T, Ruangrunsi N, Igarashi K, Ikegami F. Ardisiphenols and other antioxidant principles from the fruits of *Ardisia colorata*. Chem Pharm Bull (Tokyo) 2002;50:1484-7.
- Jansakul C, Baumann H, Kenne L, Samuelsson G. Ardisiacrispin A and B, two utero-contracting saponins from *Ardisia crispa*. Planta Med 1987;53:405-9.
- Fujioka M, Koda S, Morimoto Y, Biemann K. Structure of FR-900359: A cyclic despeptide from *Ardisia crenata* Sims. J Org Chem 1988;53:2820-5
- Jia Z, Koike, Ohmoto T, Ni M. 1994b. Triterpenoid saponins from *Ardisia crenata* and their inhibitory activity on cAMP phosphodiesterase. Chem Pharma Bull. 42(11): 2309-2314.
- Chistokhodova N, Nguyen C, Calvino T, Kachirskaia I, Cunningham G, Miles DH. Antithrombin activity of medicinal plants from central Florida. J Ethnopharmacol 2001;81:277-80.
- Chiang LC, Cheng HY, Liu MC, Chiang W, Lin CC. *In vitro* anti-herpes simplex viruses and anti-denoviruses activity of twelve traditionally used medicinal plants in Taiwan. Biol Pharm Bull 2003;26:1600-4.
- PALAS. Code of Practice for the Care and Use of Laboratory Animals in the Philippines. The Committee on Code of Practice of the Philippine Association for Laboratory Animal Sciences. Manila, 2002.
- Yakubu MT, Akanji MA, Oladiji AT. Effect of oral administration of aqueous extract of *Fadogia agrestis* stem on some testicular function indices of male rats. J Ethnopharmacol 2008;111: 288-92.
- Bjorndahl, L., Soderlund, I., Johansson, S., Mohammad, M., Pourian, M. & Kvist, U. 2004. Why the WHO recommendations for eosin-nigrosin staining techniques for human sperm viability assessment must change. Journal of Andrology, 671-677.
- Juhasz JN and Kulcsar M. Methods for semen and endocrinological evaluation of the stallion: A review. Acta Vet Brno 2000;69:247-59.

20. Jain GC, Pareek H, Sharma S, Bhardwaj M, Khajja BS. Reproductive toxicity of vanadyl sulphate in male rats. *J Health Sci* 2007;53:137-41.
21. Ogawa H, Natori S. Hydroxybenzoquinones from Myrsinaceae plants. II. Distribution among Mysinaceae plants in Japan. *Phytochemistry* 1968;7:773-82.
22. Feresin GE, Tapia A, Sortino M, Zacchino S, Rojas de Arias A, Inchausti A, et al. Bioactive alkyl phenols and embelin from *Oxalis erythrorhiza*. *J Ethnopharmacology* 2003;88:241-7.
23. Murthy VK, Rao TV, Venkateswarlu V. Chemical examination of *A. macropcarpa* Wall. *Tetrahedron* 1965;21:1445-7.
24. Calle J, Olarte J, Pinzon R, Ospina LF, Mendoza MP, Orozco MJ. Alteration in the reproduction of mice induced by rapanone. *J Ethnopharmacol* 2000;71:521-5.
25. Gupta S, Sanyal SN, Kanwar U. Antispermatogetic effect of embelin: A plant benzoquinone, on male albion rats *in vivo* and *in vitro*. *Contraception* 1989;39:307-20.
26. Nikolovska-Coleska Z, Xu L, Hu Z, Tomita Y, Li P, Roller PP. Discovery of embelin as a cell-permeable, small molecular weight inhibitor of XIAP through structure-based computational screening of traditional herbal medicine three-dimentional structure database. *J Med Chem* 2004;47:2430-40.
27. Kang YH, Kim WH, Park MK, Han BH. Antimetastatic and antitumor effects of benzoquinonoid AC7-1 from *A. crispa*. *Int J Cancer* 2001;93:736-40.
28. Horgen FD, Guinaudeau H, Pezzuto JM, Soejarto DD, Farnsworth NR, Agcaoili F, et al. Isolation and structure elucidation of ardisenone: A new cytotoxic alkenylphenol from *Ardisia iwahigensis*. *J Nat Prod* 1997;60:533-5.

Cite this article as: Raga DD, Pocsidio GN, Herrera AA. Effects of the oral administration of nonpolar extract from *Ardisia squamulosa* Presl (Myrsinaceae) leaves on spermatogenesis in rats. *Phcog Res* 2011;3:260-5.

Source of Support: Nil, **Conflict of Interest:** None declared.